



RESEARCH ARTICLE

Ophthalmic features of HIV associated cryptococcal meningitis in Malawian Adults: an observational study [version 1; peer review: awaiting peer review]

Jayne P. Ellis ^{1,3}, Kate Gaskell ^{1,4}, Mary Peirse¹, Jack Gormley ^{1,5}, Newton Kalata^{1,6}, Philip I. Burgess⁵, Patty Mopamboli⁶, Chatonda A. Manda⁶, Christine A. Kiire^{1,7}, Ian Maccormick ^{1,5}, Ebbie Gondwe¹, Sile Molloy ⁸, Thomas S. Harrison⁸, David G. Lalloo ⁹, Robert S. Heyderman ^{1,3}

¹Malawi-Liverpool-Wellcome Trust Clinical Research Programme, Blantyre, Malawi

²University College London Hospitals NHS Trust, London, UK

³Division of Infection and Immunity, University College London, London, UK

⁴London School of Hygiene & Tropical Medicine, London, UK

⁵Department of Eye and Vision Science, University of Liverpool, Liverpool, UK

⁶University of Malawi College of Medicine, Blantyre, Malawi

⁷Oxford Eye Hospital, John Radcliffe Hospital, Oxford, UK

⁸Institute for Infection and Immunity, St George's, University of London, London, UK

⁹Department of Clinical Sciences, Liverpool School of Tropical Medicine, Liverpool, UK

v1 First published: 20 May 2019, 4:83 (<https://doi.org/10.12688/wellcomeopenres.15067.1>)

Latest published: 20 May 2019, 4:83 (<https://doi.org/10.12688/wellcomeopenres.15067.1>)

Abstract

Background: Cryptococcal meningitis (CM) is the commonest neurological complication in patients with advanced HIV. Visual disturbance is a frequent presenting symptom. Papilloedema is commonly reported but other ophthalmic findings are not well described.

Methods: We performed an observational study comparing severely immunocompromised HIV-infected patients with and without CM to determine the nature and prevalence of retinal pathology attributable to CM. 70 adult patients were enrolled in Blantyre Malawi, 35 with CM and 35 HIV-infected patients without CM.

Results: 79% (19/24) of CM patients examined on day one had evidence of retinal abnormalities compared to 17% (6/35) of HIV-infected controls ($p < 0.001$). In the CM group, retinal whitening was the commonest abnormality (50%), followed by optic disc swelling (29%), haemorrhage (25%) and vascular abnormalities (7%). Retinal whitening was the only abnormality observed in the comparator group (17%). In CM, there was no significant difference between those with and without retinal abnormalities in fungal burden (13,550 cfu/ml vs. 9,150 cfu/ml; $p = 0.65$), CD4 count (28 cells/ μ l vs. 76 cells/ μ l; $p = 0.79$) or CSF opening pressure (21cm H₂O vs. 27cm H₂O; $p = 0.5$). There was no association between presence/absence of retinal abnormalities and death (40% 10-week mortality vs. 26%; $p = 0.6$).

Conclusions: Whether the presence of CM retinopathy could be used as a

Open Peer Review

Reviewer Status AWAITING PEER REVIEW

Any reports and responses or comments on the article can be found at the end of the article.

marker of disease severity warrants further investigation. The observed ophthalmic findings provide a descriptive framework for CM retinopathy to be utilised in future CM studies.

Trial registration: ISRCTN ([ISRCTN45035509](https://www.isrctn.com/ISRCTN45035509)) 19/06/2012.

Keywords

HIV, cryptococcal meningitis, retinopathy, ophthalmic signs, Africa



This article is included in the [Malawi-Liverpool Wellcome Trust Clinical Research Programme gateway](#).

Corresponding author: Jayne P. Ellis (j.ellis@doctors.org.uk)

Author roles: **Ellis JP:** Conceptualization, Data Curation, Formal Analysis, Investigation, Methodology, Project Administration, Writing – Original Draft Preparation, Writing – Review & Editing; **Gaskell K:** Conceptualization, Data Curation, Investigation, Methodology, Project Administration, Writing – Review & Editing; **Peirse M:** Conceptualization, Data Curation, Formal Analysis, Investigation, Methodology, Project Administration, Writing – Review & Editing; **Gormley J:** Data Curation, Formal Analysis, Project Administration, Writing – Original Draft Preparation, Writing – Review & Editing; **Kalata N:** Conceptualization, Data Curation, Investigation, Methodology, Project Administration, Writing – Review & Editing; **Burgess PI:** Conceptualization, Data Curation, Investigation, Writing – Review & Editing; **Mopamboli P:** Data Curation, Investigation, Writing – Review & Editing; **Manda CA:** Data Curation, Investigation; **Kiire CA:** Data Curation, Investigation, Writing – Review & Editing; **Maccormick I:** Conceptualization, Data Curation, Investigation, Methodology, Writing – Review & Editing; **Gondwe E:** Data Curation, Project Administration; **Molloy S:** Formal Analysis, Writing – Review & Editing; **Harrison TS:** Conceptualization, Funding Acquisition, Resources, Supervision, Writing – Review & Editing; **Lalloo DG:** Conceptualization, Funding Acquisition, Resources, Supervision, Writing – Review & Editing; **Heyderman RS:** Conceptualization, Funding Acquisition, Methodology, Resources, Writing – Original Draft Preparation, Writing – Review & Editing

Competing interests: No competing interests were disclosed.

Grant information: This work was supported by the Wellcome Trust through a strategic award to the Malawi-Liverpool-Wellcome Trust Clinical Research Programme [101113] The Advancing Cryptococcal meningitis Treatment for Africa (ACTA) trial was funded by the Medical Research Council UK [100504], and Agence Nationale de Recherches sur le Sida et les Hépatites Virales [ANRS12275].

The funders had no role in study design, data collection and analysis, decision to publish, or preparation of the manuscript.

Copyright: © 2019 Ellis JP *et al.* This is an open access article distributed under the terms of the [Creative Commons Attribution Licence](#), which permits unrestricted use, distribution, and reproduction in any medium, provided the original work is properly cited.

How to cite this article: Ellis JP, Gaskell K, Peirse M *et al.* **Ophthalmic features of HIV associated cryptococcal meningitis in Malawian Adults: an observational study [version 1; peer review: awaiting peer review]** Wellcome Open Research 2019, 4:83 (<https://doi.org/10.12688/wellcomeopenres.15067.1>)

First published: 20 May 2019, 4:83 (<https://doi.org/10.12688/wellcomeopenres.15067.1>)

Background

Cryptococcal meningitis (CM) remains a leading cause of death in patients with advanced HIV, accounting for 15% of AIDS-related deaths in 2014¹. Visual disturbances associated with cryptococcal meningitis are common including reduced visual acuity, blurred vision, diplopia and photophobia. In a South African study of patients with HIV-associated CM due to *Cryptococcus neoformans*, 46.5% (40/86) had decreased visual acuity². Visual loss was also reported frequently in CM caused by *Cryptococcus gattii*, in 82 immunocompetent patients from Papua New Guinea, visual loss occurred in 52.6% of survivors³. Visual loss may occur secondary to raised intracranial pressure or be due to direct fungal invasion of the optic nerve, optic chiasm or optic tracts⁴. Retinal features associated with CM have not been well-described.

Intracranial hypertension occurs in up to 75% of patients with CM⁵ and papilloedema is reported to be the commonest retinal finding, ranging between 33% and 48% of patients^{6–9}. In a study of CM patients with catastrophic visual loss, papilloedema was observed in 70% (33/47)¹⁰. Other ophthalmic features reported to be associated with CM in case reports include: retinal haemorrhages⁶, neuroretinitis⁵, multi-focal choroiditis¹¹, optic atrophy¹², vascular tortuosity¹³, exudative retinal detachment¹⁴, cloudy vitreous¹⁵, and endophthalmitis¹⁶. To what extent these changes were attributable to CM rather than HIV retinopathy, or other opportunistic infections e.g. CMV retinitis⁷, is uncertain.

We performed an observational study comparing severely immunocompromised HIV-infected Malawian adults with and without CM to determine the nature and prevalence of retinal pathology attributable to CM. This study was nested within the Advancing Cryptococcal meningitis Treatment for Africa (ACTA) trial¹⁷.

Methods

The ACTA trial was a Phase III multi-centre randomised controlled trial which aimed to identify the optimal treatment of HIV-associated CM in resource limited settings (ISRCTN45035509)¹⁷. HIV-infected adults with CM were randomised to one of five anti-fungal treatment arms and followed up for 10 weeks. The Queen Elizabeth Central Hospital (QECH), Blantyre, Malawi, was the largest recruiting centre. Patients were treated with anti-retroviral therapy (ART) according to national guidelines.

QECH is a large tertiary referral hospital in Southern Malawi. Between March 2014 and July 2015, a subset of consecutive consenting adults from the ACTA trial were recruited into the ophthalmology sub-study. This subset comprised all ACTA patients who were sufficiently stable to comply with a full ophthalmology assessment and able to consent.

Baseline clinical and laboratory data was collected including: duration of ART, CD4 count using case report forms (CRFs); cerebrospinal fluid (CSF) opening pressure was measured using manometers used during lumbar puncture and quantitative cryptococcal culture (QCC) was performed as described previously¹⁸. Dilated indirect ophthalmoscopy using a hand-held ophthalmoscope was performed by a trained ophthalmologist. Visual

acuity was tested using the logMAR (logarithm of the minimum angle of resolution) scale. Low vision was defined as a visual acuity less than +0.50 logMAR but equal to or better than +1.3 logMAR¹⁹. The team aimed to re-examine participants at day 7, week 4 and week 10. Additional examinations however depended upon patient consent, clinical status and availability of an ophthalmologist.

From November 2015 to June 2016, 35 HIV-infected otherwise healthy patients with CD4 <100 cells/μl were recruited by convenience sampling from QECH antiretroviral clinic as a comparator group. Exclusion criteria were: previous episode of CM or current symptoms or signs of meningitis. Baseline clinical data were collected including: CD4 count, ART use and co-morbidities using standardised CRFs. Visual acuity testing using the logMAR scale and dilated indirect ophthalmoscopy using a hand-held ophthalmoscope, was performed at recruitment only.

Ethics: The ACTA trial protocol was approved by the London School of Hygiene and Tropical Medicine Research Ethics Committee (REC) (8854 – 5) and the University of Malawi, College of Medicine Research Ethics Committee (COMREC) (P.11/11/1149). The sub-study protocol was approved by COMREC (P.11/11/1149). Written informed consent was obtained from all participants.

Statistical analysis: Descriptive summaries were used to analyse the observational data as proportions or medians with ranges. We used SAS (version 9.3) to calculate Fisher's exact or the Mann Whitney tests to compare groups. For the descriptive analysis, ophthalmic abnormalities were divided into 4 groups: (i) retinal whitening which included retinal discolouration, cotton wool spots, white plaques and choroidal lesions (ii) optic disc swelling (iii) haemorrhage and (iv) vascular abnormalities including vascular tortuosity and dilated vessels.

Results

46 CM patients recruited to the ACTA study were screened for recruitment to the ophthalmology sub-study. Eight patients died before an ophthalmological examination could be performed, one patient was deemed too unwell, one patient was subsequently excluded from the ACTA trial and one patient was lost to follow up. 35 HIV-infected patients without CM were also recruited (see underlying data²⁰).

Baseline characteristics

The median age was 35 years in both groups (range 29 – 51 in CM group, 23–62 in HIV-infected comparator group), 71% (25/35) were male in the CM group compared with 51% (18/35) in the HIV-infected comparator group ($p = 0.06$). All participants had advanced HIV and there was no difference in the median CD4 counts between groups: 28 cells/μl in the CM group vs. 44 cells/μl in the HIV-infected comparator group ($p = 0.21$). There was no difference in the proportion of patients on ART between groups (16/35, 46% and 14/35, 43%, $p = 0.63$). 11% (4/35) of CM patients reported visual loss at recruitment, but on formal logMAR testing 39% (7/18) had evidence of reduced visual acuity, 2/18 (11%) were blind. Patients with CM were

more likely to have reduced visual acuity compared to the HIV-infected comparator group (39% vs. 9%, $p = 0.02$).

Ophthalmic signs

79% (19/24) of CM patients examined on day one had evidence of retinal abnormalities compared to 17% (6/35) of the HIV-infected controls ($p < 0.001$) (Table 1).

82% (23/28) of CM patients examined within one week of CM diagnosis had evidence of retinopathy. In this first week, retinal whitening was the commonest abnormality observed (14/28,

50%), followed by optic disc swelling (8/28, 29%), haemorrhage (7/28, 25%), vascular abnormalities (2/28, 7%) and cloudy vitreous (2/28, 7%) (Table 1, Figure 1). 75% (6/8) of patients with optic disc swelling had raised intracranial pressure (CSF opening pressure $> 20\text{cm H}_2\text{O}$) and 35% (6/17) of patients with raised intracranial pressure had optic disc swelling. To investigate the relationship between retinopathy and CM disease severity, an association between the following indicators and the presence or absence of retinopathy (observed \leq one week after CM diagnosis) was explored. There was no significant difference in fungal burden (median QCC: 13,550 cfu/ml vs.

Table 1. Prevalence of retinal pathology in Cryptococcal Meningitis (CM) patients.

Time of fundoscopy	Abnormal fundoscopy N (%)	Retinal whitening N (%)	Optic disc swelling N (%)	Retinal haemorrhage N (%)	Vascular abnormality N (%)	Other* N (%)
CM Week 1	23/28 (82)	14/28 (50)	8/28 (29)	7/28 (25)	2/28 (7)	2/28 (7)
CM Week 4 – 10	8/13 (61)	6/13 (46)	1/13 (8)	1/13 (8)	1/13 (8)	0/7 (0)
HIV-infected controls	6/35 (17)	6/35 (17)	0/35 (0)	0/35 (0)	0/35 (0)	0/35 (0)

Other* = cloudy vitreous.

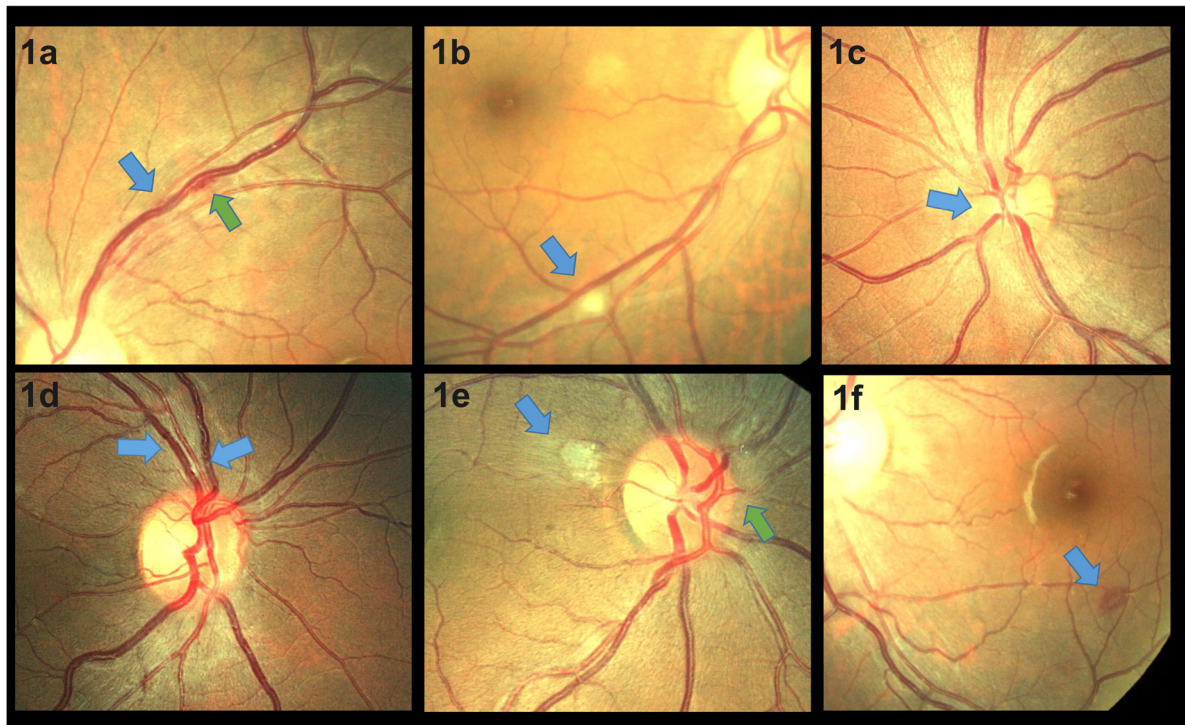


Figure 1: Retinal photographs taken from patients with HIV associated cryptococcal meningitis. **1a** shows localised vascular tortuosity (blue arrow) with associated haemorrhage (green arrow). **1b** shows a cotton wool spot (blue arrow). **1c** shows swelling of the nasal optic disc margin (blue arrow). **1d** shows vascular engorgement and focal tortuosity (blue arrows). **1e** shows atypical retinal whitening (blue arrow) and nasal disc swelling (green arrow). **1f** shows a white centred haemorrhage (blue arrow).

9,150 cfu/ml $p = 0.65$) or CD4 count (median CD4 count: 28 cells/ μ l vs. 76 cells/ μ l, $p = 0.79$). There was no association between CSF opening pressure at diagnosis (21cm H2O vs. 27cm H2O; $p = 0.5$), ART use (12/23, 52% vs. 2/5, 40%; $p = 1.0$) or baseline haemoglobin (11.2g/dL vs. 11.1g/dL; $p = 0.4$) and the presence of retinal abnormalities. There was no association between presence of retinal abnormalities and death (40% 10-week mortality vs. 26%; $p = 0.6$).

In contrast to the range of retinal signs seen in the CM patients, retinal whitening was the only abnormality observed in the HIV-infected comparator group (6/35, 17%; [Table 1](#)). A subset of CM patients (13/35) had indirect ophthalmoscopy performed between 4–10 weeks after diagnosis and commencement of anti-fungal therapy. Six of these patients had undergone an earlier ophthalmological examination during the first week and seven patients were examined for the first time between week 4 – 10. Some of these patients (8/13, 61%) had evidence of retinopathy. Retinal whitening remained the most frequent abnormality observed (6/13, 46%). Optic disc swelling, retinal haemorrhages and vascular abnormalities were seen in one patient each (8%). Of the six patients who had previously undergone ophthalmic examination during week one of their CM episode, two patients (33%) had complete resolution of their retinopathy, two patients (33%) had evidence of persistent retinal whitening, one patient (17%) had persistent mild optic disc swelling and one patient (17%) had a normal examination at both time points.

Discussion

Our observational study highlights the range and relative frequency of ophthalmic abnormalities that are associated with acute CM. Retinal whitening was the most common abnormality observed, followed by optic disc swelling, haemorrhage and vascular abnormalities; these features have each been documented previously in case reports^{7,9,10}. Among CM patients who were examined within one week of CM diagnosis, optic disc swelling was observed in 29% which is in line with other CM case series (range 32.5% – 37.5%)^{7–9}. Previous CM studies have clearly demonstrated an association between the presence of optic disc swelling and raised ICP²¹. Although most patients in our cohort with optic disc swelling had raised intracranial pressure, importantly only a third of patients with raised intracranial pressure had optic disc swelling.

Retinal whitening may be due to oncotic cell swelling in response to reduced perfusion or occlusion caused by microthrombi²², both of these mechanisms may be important in patients with CM due to the pro-inflammatory, vasculitic nature of the disease^{23,24}. However, retinal whitening was also observed in the HIV-infected comparator group and has previously been described in association with HIV retinopathy²⁵. Indeed, retinal whitening is observed in a range of retinal vascular disorders including cerebral malaria, retinal arterial occlusion and retinal vein occlusion²². In some patients retinal whitening may have predated the onset of CM.

The highest prevalence (82%) of retinopathy in CM was observed during the first week after diagnosis. In a subset of patients

examined between week 4–10, fewer (61%) had evidence of retinopathy. The resolution of the ophthalmic features associated with CM has not been reported previously^{6–8,13} and therefore needs to be investigated in larger cohorts.

Although patients with evidence of CM retinopathy had lower median CD4 counts and higher fungal burdens, our study was underpowered to detect a clear association with these features or indeed death. In a study of 80 HIV-associated CM cases from Rwanda, there was a non-significant trend towards shorter median survival times in patients with cotton wool spots (102 days) compared to those without cotton wool spots (186 days)⁷. Future larger studies of CM should determine whether the retinal abnormalities associated with CM could be used as a marker of disease severity.

The strength of this study was that it was nested within a randomized controlled trial which provided standardized data collection, diagnosis and treatment. All patients were examined by a trained ophthalmologist and in contrast to other case series, we had a severely immunocompromised HIV-infected comparator group. This study was limited by the relatively small number of participants, many of whom were only examined at a single time point. Although the cohort characteristics were similar to the main ACTA trial¹⁵, we have inevitably sampled patients with less severe CM, who were able to tolerate and consent to an ophthalmological assessment.

Conclusion

Optic disc swelling, retinal haemorrhages and vascular abnormalities are commonly observed in patients with acute CM, with the highest prevalence in the first week following diagnosis. Whether the presence of CM retinopathy could be used as a marker of CM severity warrants further investigation. The observed ophthalmic findings provide a descriptive framework for CM retinopathy to be utilised in future CM studies.

Data availability

Figshare: Ophthalmic features and clinical data of HIV-infected Malawian adults with and without cryptococcal meningitis. <https://doi.org/10.6084/m9.figshare.808227520>

This project contains the following underlying data:

- RDS-SPRN-00282 resubmission.xlsx (Spreadsheet containing demographic, clinical, lab and ophthal data for all participants)

Data are available under the terms of the [Creative Commons Zero “No rights reserved” data waiver](#) (CC0 1.0 Public domain dedication).

Grant information

This work was supported by the Wellcome Trust through a strategic award to the Malawi-Liverpool-Wellcome Trust Clinical Research Programme [101113]

The Advancing Cryptococcal meningitis Treatment for Africa (ACTA) trial was funded by the Medical Research Council UK [100504], and Agence Nationale de Recherches sur le Sida et les Hépatites Virales [ANRS12275].

The funders had no role in study design, data collection and analysis, decision to publish, or preparation of the manuscript.

Acknowledgements

We would like to acknowledge Professor Simon Harding (Department of Eye and Vision Science, University of Liverpool) for the ophthalmological mentorship and support he offered during the course of this study. We thank all the participants and their families, and gratefully acknowledge the support offered by the staff at all trial sites.

References

- Rajasingham R, Smith RM, Park BJ, *et al.*: **Global burden of disease of HIV-associated cryptococcal meningitis: an updated analysis.** *Lancet Infect Dis.* 2017; **17**(8): 873–881.
[PubMed Abstract](#) | [Publisher Full Text](#) | [Free Full Text](#)
- Moodley A, Rae W, Bhigjee A, *et al.*: **Early clinical and subclinical visual evoked potential and Humphrey's visual field defects in cryptococcal meningitis.** *PLoS One.* 2012; **7**(12): e52895.
[PubMed Abstract](#) | [Publisher Full Text](#) | [Free Full Text](#)
- Seaton RA, Verma N, Naraqi S, *et al.*: **Visual loss in immunocompetent patients with *Cryptococcus neoformans* var. *gattii* meningitis.** *Trans R Soc Trop Med Hyg.* 1997; **91**(1): 44–49.
[PubMed Abstract](#) | [Publisher Full Text](#)
- Merkler AE, Gaines N, Baradaran H, *et al.*: **Direct Invasion of the Optic Nerves, Chiasm, and Tracts by *Cryptococcus neoformans* in an Immunocompetent Host.** *Neurohospitalist.* 2015; **5**(4): 217–222.
[PubMed Abstract](#) | [Publisher Full Text](#) | [Free Full Text](#)
- Espino Barros Palau A, Morgan ML, Foroozan R, *et al.*: **Neuro-ophthalmic presentations and treatment of Cryptococcal meningitis-related increased intracranial pressure.** *Can J Ophthalmol.* 2014; **49**(5): 473–477.
[PubMed Abstract](#) | [Publisher Full Text](#)
- Battu RR, Biswas J, Jayakumar N, *et al.*: **Papilloedema with peripapillary retinal haemorrhages in an acquired immunodeficiency syndrome (AIDS) patient with cryptococcal meningitis.** *Indian J Ophthalmol.* 2000; **48**(1): 47–9.
[PubMed Abstract](#)
- Kestelyn P, Taelman H, Bogaerts J, *et al.*: **Ophthalmic manifestations of infections with *Cryptococcus neoformans* in patients with the acquired immunodeficiency syndrome.** *Am J Ophthalmol.* 1993; **116**(6): 721–727.
[PubMed Abstract](#) | [Publisher Full Text](#)
- Mao F, Sun H, Li D: **[Ophthalmic manifestations in acquired immune deficiency syndrome patients with cryptococcal meningitis].** *Zhonghua Yan Ke Za Zhi.* 2015; **51**(5): 364–368.
[PubMed Abstract](#) | [Publisher Full Text](#)
- Okun E, Butler WT: **Ophthalmologic Complications Of Cryptococcal Meningitis.** *Arch Ophthalmol.* 1964; **71**: 52–57.
[PubMed Abstract](#) | [Publisher Full Text](#)
- Rex JH, Larsen RA, Dismukes WE, *et al.*: **Catastrophic visual loss due to *Cryptococcus neoformans* meningitis.** *Medicine (Baltimore).* 1993; **72**(4): 207–224.
[PubMed Abstract](#) | [Publisher Full Text](#)
- Andreola C, Ribeiro MP, de Carli CR, *et al.*: **Multifocal choroiditis in disseminated *Cryptococcus neoformans* infection.** *Am J Ophthalmol.* 2006; **142**(2): 346–348.
[PubMed Abstract](#) | [Publisher Full Text](#)
- Espino Barros Palau A, Morgan ML, Foroozan R, *et al.*: **Neuro-ophthalmic presentations and treatment of Cryptococcal meningitis-related increased intracranial pressure.** *Can J Ophthalmol.* 2014; **49**(5): 473–7.
[PubMed Abstract](#) | [Publisher Full Text](#)
- Aderman CM, Gorovoy IR, Chao DL, *et al.*: **Cryptococcal choroiditis in advanced AIDS with clinicopathologic correlation.** *Am J Ophthalmol Case Rep.* 2018; **10**: 51–54.
[PubMed Abstract](#) | [Publisher Full Text](#) | [Free Full Text](#)
- Chen J, Chai C, Teoh SC: **Cryptococcal-related exudative retinal detachment.** *Eye (Lond).* 2011; **25**(9): 1234–1235.
[PubMed Abstract](#) | [Publisher Full Text](#) | [Free Full Text](#)
- Stone SP, Bendig J, Hakim J, *et al.*: **Cryptococcal meningitis presenting as uveitis.** *Br J Ophthalmol.* 1988; **72**(3): 167–70.
[PubMed Abstract](#) | [Publisher Full Text](#) | [Free Full Text](#)
- Denning DW, Armstrong RW, Fishman M, *et al.*: **Endophthalmitis in a patient with disseminated cryptococcosis and AIDS who was treated with itraconazole.** *Rev Infect Dis.* 1991; **13**(6): 1126–30.
[PubMed Abstract](#) | [Publisher Full Text](#)
- Molloy SF, Kanyama C, Heyderman RS, *et al.*: **Antifungal Combinations for Treatment of Cryptococcal Meningitis in Africa.** *N Engl J Med.* 2018; **378**(11): 1004–1017.
[PubMed Abstract](#) | [Publisher Full Text](#)
- Bicanic T, Meintjes G, Wood R, *et al.*: **Fungal burden, early fungicidal activity, and outcome in cryptococcal meningitis in antiretroviral-naïve or antiretroviral-experienced patients treated with amphotericin B or fluconazole.** *Clin Infect Dis.* 2007; **45**(1): 76–80.
[PubMed Abstract](#) | [Publisher Full Text](#)
- CONSULTATION ON DEVELOPMENT OF STANDARDS FOR CHARACTERIZATION OF VISION LOSS AND VISUAL FUNCTIONING. Geneva, 4-5 September 2003.
[Reference Source](#)
- Ellis J, Gaskell K, Pierce M, *et al.*: **Ophthalmic features and clinical data of HIV-infected Malawian adults with and without cryptococcal meningitis.** *figshare.* Dataset. 2019.
<http://www.doi.org/10.6084/m9.figshare.8082275>
- Graybill JR, Sobel J, Saag M, *et al.*: **Diagnosis and management of increased intracranial pressure in patients with AIDS and cryptococcal meningitis. The NIAID Mycoses Study Group and AIDS Cooperative Treatment Groups.** *Clin Infect Dis.* 2000; **30**(1): 47–54.
[PubMed Abstract](#) | [Publisher Full Text](#)
- MacCormick IJ, Beare NA, Taylor TE, *et al.*: **Cerebral malaria in children: using the retina to study the brain.** *Brain.* 2014; **137**(Pt 8): 2119–2142.
[PubMed Abstract](#) | [Publisher Full Text](#) | [Free Full Text](#)
- Leite AG, Vidal JE, Bonasser Filho F, *et al.*: **Cerebral infarction related to cryptococcal meningitis in an HIV-infected patient: case report and literature review.** *Braz J Infect Dis.* 2004; **8**(2): 175–179.
[PubMed Abstract](#) | [Publisher Full Text](#)
- Mishra AK, Arvind VH, Muliylil D, *et al.*: **Cerebrovascular injury in cryptococcal meningitis.** *Int J Stroke.* 2018; **13**(1): 57–65.
[PubMed Abstract](#) | [Publisher Full Text](#)
- Jabs DA: **Ocular manifestations of HIV infection.** *Trans Am Ophthalmol Soc.* 1995; **93**: 623–83.
[PubMed Abstract](#) | [Free Full Text](#)