

Global guideline for the diagnosis and management of rare mold infections: An initiative of the ECMM in cooperation with ISHAM and ASM*

Authors

Martin Hoenigl (FECMM)^{1,2,3,54,55#}, Jon Salmanton-García^{4,5,30,55}, Thomas J. Walsh (FECMM)⁶, Marcio Nucci (FECMM)⁷, Chin Fen Neoh (FECMM)^{8,9}, Jeffrey D. Jenks^{2,3,10}, Michaela Lackner (FECMM)^{11,55}, Rosanne Sprute^{4,5,55}, Abdullah Al-Hatmi (FECMM)¹², Matteo Bassetti¹³, Fabianne Carlesse (FECMM)^{14,15}, Tomas Freiburger¹⁶, Philipp Koehler (FECMM)^{4,5,17,30,55}, Thomas Lehrnbecher¹⁸, Anil Kumar (FECMM)¹⁹, Juergen Prattes (FECMM)^{1,55}, Malcolm Richardson (FECMM)^{20,21,55}, Sanjay Revankar²², Monica A. Slavin^{23,24}, Jannik Stemler^{4,5,55}, Birgit Spiess²⁵, Saad J. Taj-Aldeen²⁶, Adilia Warris (FECMM)²⁷, Patrick C.Y. Woo (FECMM)²⁸, Jo-Anne H. Young²⁹, Kerstin Albus^{4,30,55}, Dorothee Arenz^{4,30,55}, Valentina Arsic-Arsenijevic (FECMM)^{31,54}, Jean-Philippe Bouchara^{32,33}, Terrence Rohan Chinniah³⁴, Anuradha Chowdhary (FECMM)³⁵, Sybren de Hoog (FECMM)³⁶, George Dimopoulos (FECMM)³⁷, Rafael F. Duarte³⁸, Petr Hamal (FECMM)^{39,54}, Jacques F. Meis (FECMM)^{40,54,55}, Sayoki Mfinanga^{41,42,43,44}, Flavio Queiroz-Telles (FECMM)^{45,46}, Thomas F. Patterson⁴⁷, Galia Rahav⁴⁸, Thomas R. Rogers (FECMM)⁴⁹, Coleman Rotstein (FECMM)⁵⁰, Retno Wahyuningsih^{51,52}, Danila Seidel^{4,5,30,55}, Oliver A. Cornely (FECMM)^{4,5,30,53,54,55}

* The American Society for Microbiology's contribution to this document was a review conducted by Stuart M. Levitz, MD, University of Massachusetts, Worcester, Audrey N. Schuetz, MD, Mayo Clinic, Rochester, MN, and Sean X. Zhang, MD, PhD, Johns Hopkins University, Baltimore, MD.

- 1) Section of Infectious Diseases and Tropical Medicine, Medical University of Graz, Graz, Austria
- 2) Division of Infectious Diseases and Global Public Health, Department of Medicine, University of California San Diego, San Diego, USA
- 3) Clinical and Translation Fungal Research Working Group, University of California San Diego, San Diego, USA
- 4) Department I of Internal Medicine, University Hospital of Cologne, Cologne, Germany
- 5) German Centre for Infection Research (DZIF) partner site Bonn-Cologne, Cologne, Germany
- 6) Departments of Medicine, Pediatrics, Microbiology & Immunology, Weill Cornell Medicine, and New York Presbyterian Hospital, New York, NY, USA
- 7) Department of Internal Medicine, Universidade Federal do Rio de Janeiro, Rio de Janeiro, Brazil
- 8) Faculty of Pharmacy, Universiti Teknologi MARA, Puncak Alam Campus, Selangor, Malaysia
- 9) Collaborative Drug Discovery Research (CDDR) Group, Pharmaceutical and Life Sciences, Community of Research, Universiti Teknologi MARA, Shah Alam, Selangor, Malaysia
- 10) Division of General Internal Medicine, Department of Medicine, University of California San Diego, San Diego, CA, USA
- 11) Institute of Hygiene and Medical Microbiology, Department of Hygiene, Medical Microbiology and Public Health, Medical University Innsbruck, Innsbruck, Austria
- 12) Ministry of Health, Directorate General of Health Services, Ibri, Oman

- 41 13) Clinica Malattie Infettive, Ospedale Policlinico San Martino – IRCCS and Department of Health Sciences, University of Genoa, Genoa, Italy
- 42
- 43 14) Department of Pediatrics Federal University of Sao Paulo (UNIFESP), Sao Paulo, Brazil
- 44 15) Oncology Pediatric Institute IOP-GRAACC-UNIFESP, Sao Paulo, Brazil
- 45 16) Centre for Cardiovascular Surgery and Transplantation, Brno, and Medical Faculty, Masaryk University, Brno, Czech Republic
- 46
- 47 17) Center for Integrated Oncology Aachen Bonn Cologne Duesseldorf (CIO ABCD), Cologne, Germany
- 48 18) Division of Pediatric Hematology and Oncology, Hospital for Children and Adolescents, University Hospital, Frankfurt, Germany
- 49
- 50 19) Department of Microbiology, Amrita Institute of Medical Sciences & Research Centre, Amrita Vishwa Vidyapeetham, Kerala, India
- 51
- 52 20) Division of Infection, Immunity and Respiratory Medicine, University of Manchester, UK
- 53 21) UK NHS Mycology Reference Centre, Manchester University NHS Foundation Trust, Manchester, UK
- 54 22) Division of Infectious Diseases, Wayne State University, Detroit, MI, USA
- 55 23) University of Melbourne, Melbourne, Australia
- 56 24) The National Centre for Infections in Cancer, Peter MacCallum Cancer Centre, Melbourne, Australia
- 57 25) Department of Hematology and Oncology, University Hospital Mannheim, Heidelberg University, Mannheim, Germany
- 58
- 59 26) Department of Laboratory Medicine and pathology, Hamad Medical Corporation, Doha, Qatar
- 60 27) MRC Centre for Medical Mycology, University of Exeter, Exeter, UK
- 61 28) Department of Microbiology, The University of Hong Kong, Hong Kong, China
- 62 29) University of Minnesota, Minneapolis, Minnesota, USA
- 63 30) Cologne Excellence Cluster on Cellular Stress Responses in Aging-Associated Diseases (CECAD) Cluster of Excellence, University of Cologne, Cologne, Germany
- 64
- 65 31) University of Belgrade, Faculty of Medicine, Institute of Microbiology and Immunology, National Reference Laboratory for Medical Mycology, Belgrade, Serbia
- 66
- 67 32) Host-Pathogen Interaction Study Group, Angers University, Angers, France
- 68 33) Laboratory of Parasitology and Mycology, Angers University Hospital, Angers, France
- 69 34) Department of Microbiology, University of Colombo, Colombo, Sri Lanka
- 70 35) Department of Medical Mycology, Vallabhbai Patel Chest Institute, University of Delhi, Delhi, India
- 71 36) Center of Expertise in Mycology of Radboud University Medical Center / Canisius Wilhelmina Hospital, Nijmegen, The Netherlands
- 72
- 73 37) Critical Care Department, University Hospital ATTIKON, National and Kapodistrian University of Athens, Greece
- 74
- 75 38) Hospital Universitario Puerta de Hierro Majadahonda, Madrid, Spain
- 76 39) Department of Microbiology, Palacky University Olomouc and University Hospital Olomouc, Czech Republic
- 77
- 78 40) Department of Medical Microbiology and Infectious Diseases, Centre of Expertise in Mycology Radboudumc/Canisius Wilhelmina Hospital, Nijmegen, The Netherlands
- 79
- 80 41) National Institute for Medical Research, Tanzania
- 81 42) Muhimbili University of Health and Allied Sciences, Tanzania
- 82 43) Nelson Mandela Institute of Science and Technology, Tanzania
- 83 44) Liverpool School of Tropical Medicine, UK
- 84 45) INFOCUS LATAM, ISHAM Working Group
- 85 46) Department of Public Health, Hospital de Clinicas, Federal University of Parana, Curitiba, Brazil

- 86 47) UT Health San Antonio and South Texas Veterans Health Care System, San Antonio, TX USA
87 48) Sheba Medical Center, Tel-Hashomer, and Sackler School of Medicine, Tel Aviv University, Israel
88 49) Department of Clinical Microbiology, Trinity College Dublin, St James's Hospital Campus, Dublin, Ire-
89 land
90 50) Division of Infectious Diseases, University of Toronto, Toronto, Canada
91 51) Department of Parasitology, Universitas Indonesia, Faculty of Medicine, Jakarta, Indonesia
92 52) Department of Parasitology, Universitas Kristen Indonesia, Faculty of Medicine, Jakarta, Indonesia
93 53) Clinical Trials Center Cologne, University Hospital of Cologne, Cologne, Germany
94 54) European Confederation of Medical Mycology (ECMM) Council
95 55) Excellence Center (EC) for Medical Mycology of the European Confederation of Medical Mycology
96 (ECMM)

97

98

99

100

101 **# Corresponding author:**

102 Martin Hoenigl, M.D.,

103 Division of Infectious Diseases and Global Public Health, Department of Medicine,

104 University of California, San Diego,

105 200 West Arbor Drive #8208

106 San Diego, CA 92103, United States of America

107 Phone: +1 6195435605

108 E-mail: hoeniglmartin@gmail.com

109

110 **Introduction and Methods**

111 Invasive aspergillosis and mucormycosis have been the most commonly documented invasive mold infec-
112 tions over recent decades¹⁻⁴, but mycoses caused by rare molds are on the rise⁵. Mold-active antifungal
113 prophylaxis in those at highest risk for invasive aspergillosis has proven effective in preventing invasive
114 aspergillosis, and to a lesser extent also mucormycosis^{6,7}. However, the selective pressure of antifungal
115 prophylaxis also may be contributing to the emergence of less common invasive mold infections, caused
116 by molds that are often intrinsically resistant against classes of antifungals, and include *Fusarium*, *Lomen-*
117 *tospora* and *Scedosporium* species as well as even less common emerging molds such as *Rasamsonia*,
118 *Scopulariopsis* and *Paecilomyces* spp., which have been described as opportunistic pathogens in patients
119 with a variety of underlying diseases⁸⁻¹⁰. Intrinsic resistance of the fungal pathogens to many of the avail-
120 able antifungals limits successful therapeutic options. The prevalence of infection due to these fungal
121 pathogens varies widely among geographic regions¹¹. Readily available guidance on recognizing different
122 disease patterns and the diagnostic and therapeutic options available, which differ across the regions of
123 the world, is important to optimize patient management¹². Current guidelines are limited to individual
124 rare mold pathogens¹³⁻¹⁵, focusing on specific groups of patients such as those with hematological malig-
125 nancies¹⁵, or are missing altogether for infections caused by many of the very rare, but emerging patho-
126 genic molds.

127 Therefore, the European Confederation of Medical Mycology (ECMM)¹⁶, together with the International
128 Society for Human and Animal Mycology (ISHAM) and the American Society for Microbiology (ASM), issue
129 this comprehensive guidance document as part of their “One World – One Guideline” initiative^{12,17}, to
130 facilitate clinical decision-making, and simultaneously provide an overview of the areas of uncertainty for
131 invasive mold infections caused by *Fusarium* spp., *Lomentospora* spp., *Scedosporium* spp., dematiaceous
132 molds causing phaeohyphomycosis, *Rasamsonia* spp., *Scopulariopsis* spp., *Penicillium* spp., *non-marneffeii*
133 *Talaromyces* spp., *Paecilomyces* spp., *Purpureocillium* spp., and *Schizophyllum* spp. as well as other basid-
134 iomycetes. We aimed to address the limitations of previous recommendations by engaging physicians and
135 scientists involved in all aspects of the management of rare mold infection, representing the fields of

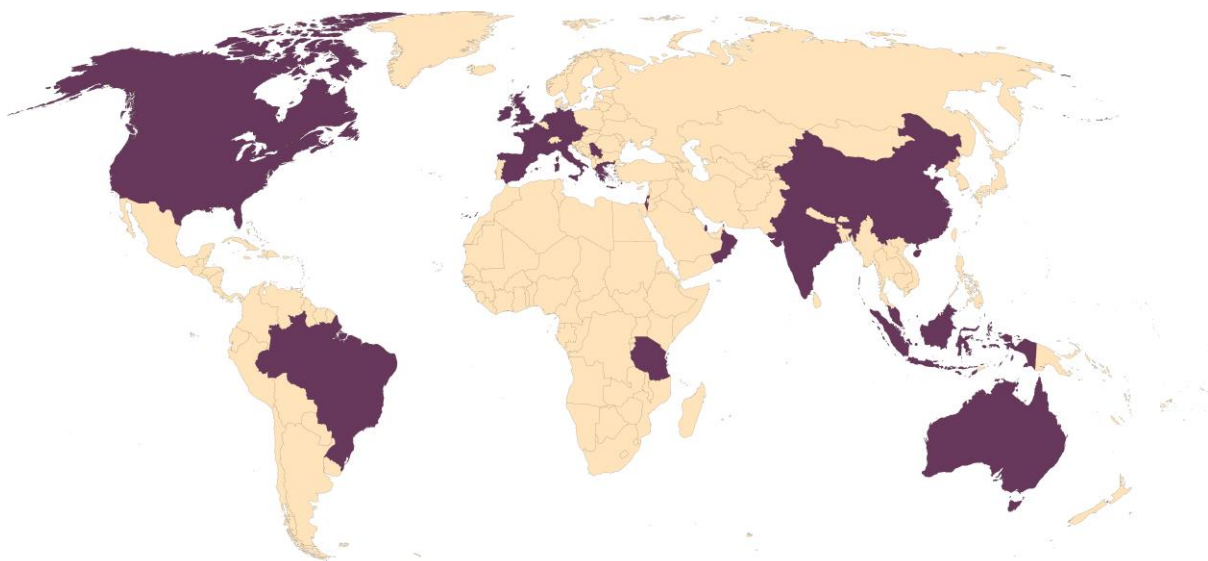
136 microbiology, mycology, pathology, radiology, infectious diseases, pharmacology, surgery, pediatrics,
137 haematology, intensive care, and dermatology.

138

139 **Panel: How the guideline group worked**

140 In January 2018, experts were identified based on their publication activity in the field of rare mold infec-
141 tions in the previous five years, their involvement in patient management, and their distribution across
142 the world regions as defined by the United Nations (**Figure 1**).

143 **Figure 1. Worldwide distribution of the authors of the Rare Mold Guideline**



144

145 Experts were invited in February 2018 to develop this guideline. From February to March 2018, videocon-
146 ferences on the methodology were held, and a mandatory video tutorial added in March 2018. Supervi-
147 sion of the group was provided by the coordinators (MH, DS, OAC). Documents were shared among the
148 authors on a password-protected OneDrive (Microsoft Corp, Redmond, WA, USA) repository, and were
149 centrally managed and kept up-to-date with any new developments. Updates on PICO (population, inter-
150 vention, comparison, and outcome) tables were written in red font; after spelling check and formatting,
151 font color was changed to blue for evaluation by the group. Following discussion of contents and consen-
152 sus, the font was changed to black. Once all tables were finalized, a writing group (MH, JSG, TJW, MN,
153 CFN, JDJ, ML, MB, FC, TF, PK, TL, AK, JP, MR, SR, MS, JSt, BS, RS, ST, AW, PW, JY, DS, and OAC) contributed

154 the first draft, which was circulated to all participants for approval in January 2020. Recommendations
155 were consensus-based. If no consensus was found, the majority vote was used.

156
157 In April 2020, a four-week public consultation phase ensued. Comments received were evaluated, and
158 used to modify the manuscript as appropriate, resulting in a final author review in June 2020. 54 scientific
159 societies, including national societies from 38 countries and several international societies reviewed and
160 endorsed the guidance document.

161
162 The following societies have endorsed the guideline:

163 International

- 164 • International Immunocompromised Host Society (ICHS)
- 165 • The International Society for Human & Animal Mycology (ISHAM)

166 Africa

- 167 • Ghana Medical Mycology Group
- 168 • Federation of Infectious Diseases Societies of Southern Africa (FIDSSA)

169 Americas

- 170 • Medical Mycology Society of the Americas (MMSA)

171 Americas, Canada

- 172 • Association of Medical Microbiology and Infectious Disease (AMMI)

173 Americas, Latin America/Caribbean

- 174 • Asociación Argentina de Microbiología (AAM), Subcomisión de Micología Clínica
- 175 • Brazilian Association of Hematology, Hemotherapy and Cell Therapy (ABHH)
- 176 • Brazilian Society of Infectious Diseases
- 177 • Latin American Forum for Fungal Infections

178 Americas, United States

- 179 • American Society for Microbiology (ASM)

180 Asia

- 181 • Asia Fungal Working Group (AFWG)

182 Asia Central/Southern

- 183 • Medical Microbiology & Infectious Diseases Society of Pakistan (MMIDSP)
- 184 • Indian Society of Medical Mycologist (MSI)
- 185 • Iranian Society of Infectious Diseases and Tropical Medicine (ISIDTM)
- 186 • Iranian Society for Medical Mycology (ISMM)

187 Asia, Eastern/South-Eastern

- 188 • Indonesia Society for Medical Mycology
- 189 • Malaysian Society of Infectious Diseases and Chemotherapy (MSIDC)
- 190 • Infectious Diseases Society of Taiwan (IDST)
- 191 • Infectious Diseases Society of Thailand (IDAT) with Thai Medical Mycology Forum (TMMF)

- 192 Asia, Western
- 193 • Israeli Society for Infectious Diseases (ISID)
- 194 • Lebanese Society of Infectious Diseases and Clinical Microbiology (LSIDCM)
- 195 • Omani Society of Medical Microbiology and Infectious Diseases
- 196 • Infectious Diseases and Clinical Microbiology Speciality Society of Turkey (EKMUD)
- 197 • Turkish Society of Hospital Infection and Control (TSHIC)
- 198 • Turkish Febrile Neutropenia Society
- 199 • Turkish Society of Medical Mycology
- 200 Europe
- 201 • European Hematology Association (EHA)
- 202 • European Paediatric Mycology Network (EPMYn)
- 203 Europe, Eastern
- 204 • Czech Society for Medical Microbiology (SPLM)
- 205 • Hungarian Society of Infectious Diseases and Clinical Microbiology (MIFKMT)
- 206 • Romanian Society for Medical Mycology and Mycotoxicology (SRMMM)
- 207 • The Interregional Association for Clinical Microbiology and Antimicrobial Chemotherapy (IAC-
- 208 MAC)
- 209 • Serbian Society of Medical Mycology (SSMM)
- 210 • Slovak Society of Chemotherapy
- 211 • Slovenian Society for Clinical Microbiology and Hospital Infections of SMC
- 212 Europe, Northern
- 213 • Nordic Society for Medical Mycology (NSMM)
- 214 • Finnish Society for Medical Mycology (FSMM)
- 215 • Irish Fungal Society (IFS)
- 216 • Swedish Society for Clinical Mycology (SSKM)
- 217 • British Infection Association (BIA)
- 218 • British Society for Medical Mycology (BSMM)
- 219 Europe, Southern
- 220 • Hellenic Society of Medical Mycology (HSMM)
- 221 • La Federazione Italiana di Micopatologia Umana ed Animale (FIMUA)
- 222 • Sorveglianza Epidemiologica Infezioni nelle Emopatie (SEIFEM)
- 223 • Società Italiana Terapia Antinfettiva (SITA)
- 224 • Associação Portuguesa de Micologia Médica (ASPOMM)
- 225 • Asociación Española de Micología (AEM), Sección de Micología Médica
- 226 Europe, Western
- 227 • Austrian Society for Medical Mycology (ÖGMM)
- 228 • Belgian Society for Human and Animal Mycology (BSHAM)
- 229 • French Society for Medical Mycology (SFMM)
- 230 • German Society for Hematology and Medical Oncology (AGIHO)
- 231 • German Speaking Mycological Society (DMykG)
- 232 • Paul-Ehrlich-Society for Chemotherapy (PEG)
- 233 Oceania
- 234 • ASID Australasian Society for Infectious Diseases
- 235

236 This guideline follows the structure and definitions of previous guidelines on invasive fungal infections
237 which are in accordance with the Grading of Recommendations Assessment, Development and Evaluation
238 (GRADE) and Appraisal of Guidelines for Research & Evaluation (AGREE) systems. The tables reflect the
239 PICO approach, and the methodology including strength of recommendation (SoR), quality of evidence
240 (QoE), and indexes (t, transferred evidence; h comparator group: historical controls; u, uncontrolled trials)
241 as previously described^{12,17}.

242

243 1. Fusariosis

244 Epidemiology of fusariosis

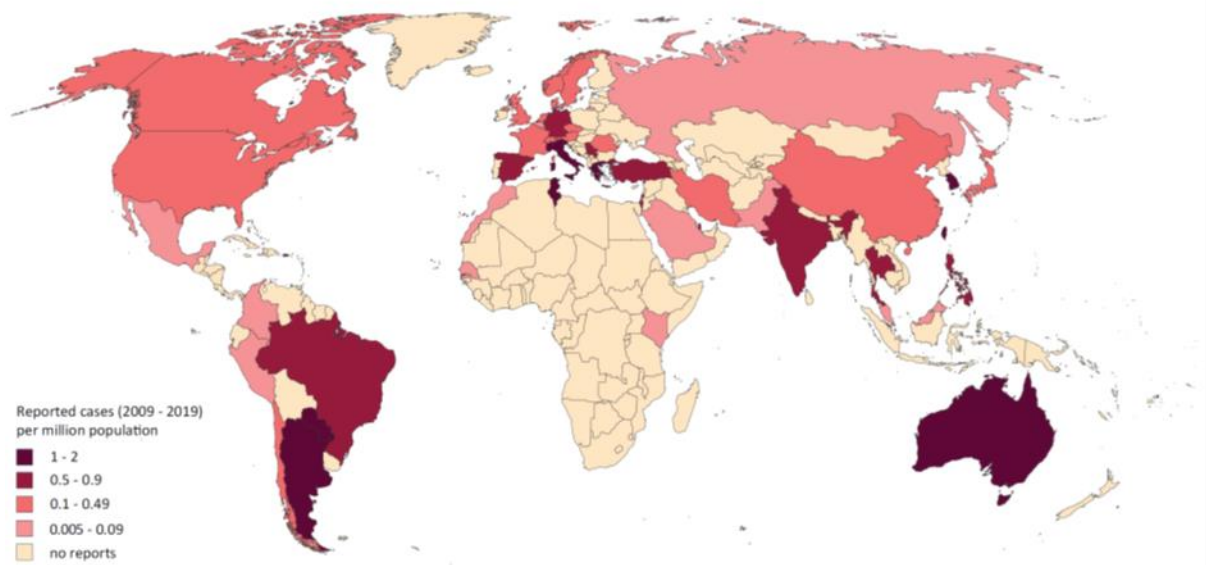
245 Only a relatively small proportion of the more than 300 *Fusarium* species are opportunistic pathogens in
246 humans¹⁹. *Fusarium solani* and *Fusarium oxysporum* spp. complexes are especially important, causing
247 more than 50% and about 20% of severe fusariosis cases, respectively^{18,20}. Other species causing infections
248 are those from the *Fusarium fujikuroi* spp. complex [mainly *Fusarium verticillioides* (formerly *Fusarium*
249 *moniliforme*), *F. fujikuroi*, *Fusarium subglutinans*, *Fusarium proliferatum*], and *Fusarium dimerum* spp.
250 complex²⁰. The main routes of infection are inhalation of airborne microconidia or direct inoculation
251 through traumatic injury, including burns. In immunocompetent patients, fusariosis mostly results from
252 direct contact with contaminated material and frequently presents as superficial infection, such as ony-
253 chomycosis or fungal keratitis, that may become locally invasive²¹⁻²³. Eye infections are mainly caused by
254 species of the *F. solani* complex²⁴. *Fusarium* spp. can adhere to plastic substrates such as catheters and
255 soft contact lenses, predisposing those exposed to contaminated devices and material to associated in-
256 fections²⁵. Hospital water distribution systems may harbor *Fusarium* spp. and serve as a potential source
257 of nosocomial transmission to hospitalized immunocompromised patients²⁶. Outbreaks of *Fusarium*-re-
258 lated keratitis in contact lens wearers have been associated with contaminated lens cleaning solution²⁷.
259 In immunocompromised hosts, especially neutropenic patients with hematological malignancy or those
260 undergoing hematopoietic stem cell transplantation (HSCT) or solid organ transplantation (SOT), fusariosis
261 manifests as invasive infection mainly affecting skin and deep soft tissue, lungs and sinuses^{20,28}. Infections

262 in SOT patients tend to be locally invasive²⁹. *Fusarium* spp. frequently disseminate, with positive blood
263 cultures in as much as 70% of cases in immunocompromised patients²⁸. This is in contrast to infections
264 caused by many other molds, where blood cultures remain negative despite disseminated infection³⁰. This
265 distinctive clinical characteristic of positive blood cultures in disseminated fusariosis may be related to
266 the ability of some *Fusarium* spp. to form *in vivo* adventitious conidia or aleurioconidia, which may then
267 break away from invading hyphae and enter the blood stream³¹. Necrotic erythematous papular or nod-
268 ular skin lesions are often evident in immunocompromised patients with systemic fusariosis and are a
269 distinctive characteristic of these infections³⁰. Dissemination to the central nervous system (CNS) and also
270 hepatosplenic fusariosis have been described in isolated reports only³²⁻³⁴. Fusarial paronychia infection in
271 neutropenic patients may result in a painful, erythematous infection of the great toe, which may serve as
272 an important portal of entry for disseminated fusariosis³⁵.

273 Incidence and prevalence of *Fusarium* infections vary depending on the underlying disease and geograph-
274 ical region. Comparable incidence of fusariosis in HSCT recipients has been identified in centers in Brazil
275 and the United States, where ~6 cases per 1,000 transplants have been affected, ranging between
276 1.4 and 2 per 1,000 autologous HSCT recipients, and reaching 20 per 1,000 allogeneic HSCT recipients with
277 HLA-mismatched related donors³⁶. In Brazil, the 1-year cumulative incidence of fusariosis after allogeneic
278 HSCT was 3.2%, and 0.6% after autologous HSCT³⁷. In that study, fusariosis accounted for 29% of all inva-
279 sive fungal infections. Similarly, an incidence of fusariosis of 14.8 cases per 1,000 patients with acute lym-
280 phoblastic leukemia and 13.1 cases per 1,000 patients with acute myeloblastic leukemia have been re-
281 ported from another center in Brazil³⁸. In contrast, a Spanish multicentre study analysing respiratory,
282 blood and tissue samples, identified *Fusarium* spp. in 1.2% of all clinical isolates tested³⁹. In a Spanish
283 tertiary teaching hospital, median incidence of invasive fusariosis was 0.074 episodes per 10,000 admis-
284 sions in hematological patients. The incidence increased during the study period⁴⁰. Other centers in Eu-
285 rope, Asia and South America have also reported an increase in fusariosis cases in recent years⁴¹⁻⁴³. A
286 pediatric cancer center in Canada diagnosed five fusariosis cases over a period of 15 years⁴⁴.

287 *Fusarium* keratitis, often associated with contact lenses, is one of the most common fungal infections of
288 the cornea⁴⁵. In a Danish study, 20% of all cases of fungal keratitis were due to *Fusarium* spp. In this study,
289 a mean incidence of 0.6 per million per year was estimated, ranging between 0 and 2 per million in 14
290 years (Figure 2)⁴⁶.

291
292 **Figure 2. Worldwide distribution of fusariosis (reported cases between 2009 and 2019 per million pop-**
293 **ulation)**



294
295 Cases of *Fusarium*-related infections reported in the medical literature were identified in a PubMed search
296 on October 30, 2019 using the search string (*Fusarium* OR fusariosis) that yielded 1,850 publications. In
297 total, 2,435 cases were selected from 48 countries, ~80% related to eye infections. Overall, the vast ma-
298 jority of cases were reported from India (n>1,200, more than 95% related to eye infections), China
299 (n=189), Brazil (n=109), the United States of America (n=100), Philippines (n=94), Argentina (n=83), Italy
300 (n=67), Germany (n=58), and Turkey (n=52)^{13,18,21-24,32-34,37,38,41,42,46-320}. Outbreaks related to contaminated
301 contact lens solution, tap water or other causes were not included. The number of cases reported be-
302 tween 2009 and 2019 is presented as cases per million population per country. The resident population
303 per country was obtained from www.worldometers.info³²¹. Of note, the maps in this guideline document
304 are an underestimation of the true prevalence and only reflecting the reported prevalence. Reporting of

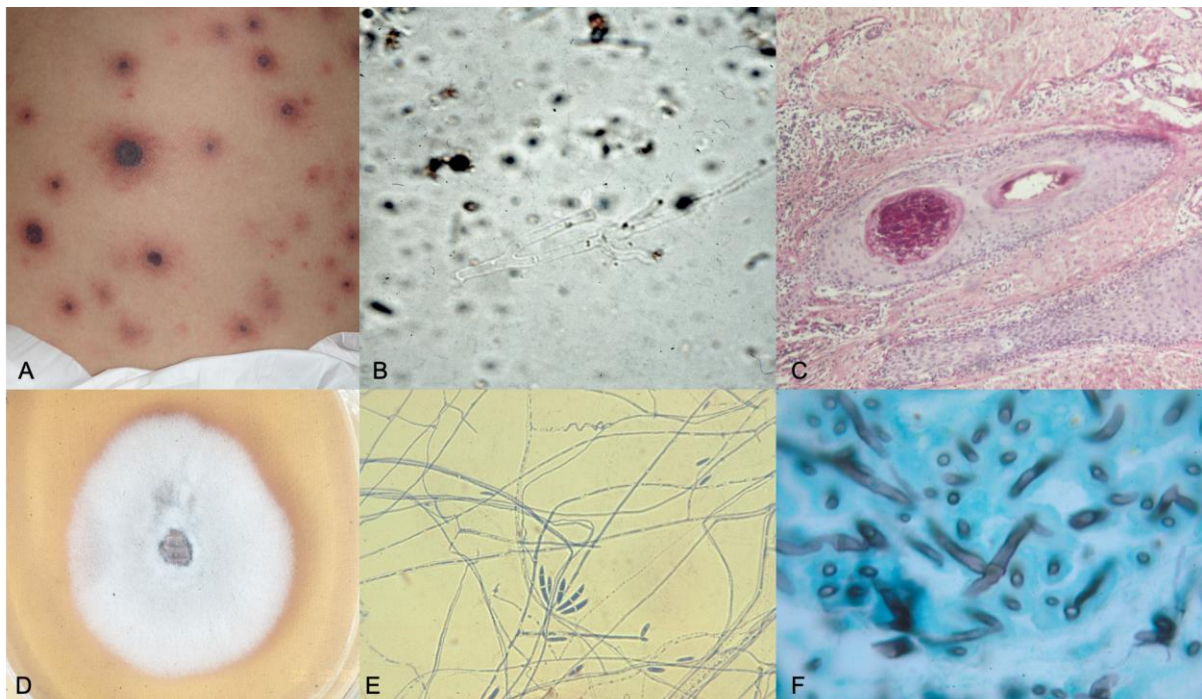
305 cases and case series is highly depending on the ability diagnose those rare fungal infections and the abil-
306 ity to publish.

307
308 *Fusarium* spp. are also the cause of human and animal exposure to serious life-threatening toxins, espe-
309 cially in agricultural settings. For example ingestion of trichothecene toxins may result in fatal toxic ali-
310 mentary aleukia which can cause pancytopenia, gastrointestinal distress, seizures, and death³²².

311

312 **Diagnosis of fusariosis**

313 **Figure 3. Clinical, mycologic and histologic characteristics of invasive *Fusarium* infections (owned by co-
314 author S. Taj-Aldeen)**



315
316 **Panel A.** Cutaneous lesions resulting from fungemia in a hematopoietic allogeneic stem cell transplant
317 pediatric patient. The lesions are painful and may depict different aspects according to the clinical pro-
318 gression. Skin lesions with ulcerated center, crusted necrotic center and surrounded by an erythematous
319 halo (“target lesions”) are suggestive and mostly observed on the trunk and extremities. **Panel B.** Imme-
320 diate examination of potassium hydroxide digested cutaneous biopsies, may reveal hyaline septate 45°
321 branching hyphae similar to other hyalohyphomycoses, although irregular branching patterns with up to
322 90° branching do occur. **Panel C.** Histopathology of skin lesions resulting from fungemia, shows vasculitis,

323 the proliferation of capillary vessels with ectasiated lumen and intravascular thrombi containing fibrin and
324 hyphae (PAS staining x 200). **Panel D.** Colony with cottony appearance surrounded by a tan pigment.
325 **Panel E.** On slide culture, characteristically curved macroconidia (“banana-shaped”) and thin hyaline hy-
326 phae are depicted (lactophenol cotton blue x400). **Panel F.** Histopathologic aspects are nonspecific and
327 similar to other hyalohyphomycoses (Gomori’s methenamine silver staining x 1000).

328

329 ***Diagnosis – Microscopy, culture and histopathology***

330 **Evidence** – Blood cultures are positive in 40% of invasive cases²³⁰, with faster detection of growth in fungal
331 blood culture bottles compared to standard aerobic bottles³²³. This is true specifically for low inocula (10²
332 and 10³ CFU/ml) which are detected earlier in fungal media than in bacteriological media (10 hours earlier
333 for *F. dimerum*, 14 hours for *F. solani*, and 35 hours for *F. verticillioides*)^{230,323}. Although members of the
334 genus *Fusarium* can be identified by the production of hyaline hyphae and pigmented, banana-shaped
335 multicellular macroconidia with a foot cell at the base, species identification is difficult morphologically³²⁴.
336 Microscopy has a very important role for diagnosing *Fusarium*-related infection particularly in many low
337 and middle income countries, where culture may not be available and histopathology is only accessible in
338 some tertiary facilities⁴⁵.

339 Direct examination of tissue, especially skin biopsy, allows for a rapid evaluation prior to culture results if
340 the tissue sample can be examined in a timely fashion²³⁰ (**Figure 3**). In particular, to diagnose fungal ker-
341 atitis, histopathologic examination and culture of corneal scrapings are employed³⁰. In fresh tissue, hy-
342 phae are morphologically similar to those of *Aspergillus* spp., e.g. appearing as hyaline septate filaments
343 that typically dichotomize in acute to 45° and sometimes even 90° angles. Adventitious sporulation may
344 be present and the finding presence of reniform adventitious conidia is highly suggestive of fusariosis³²⁴.

345

346

347 Hyphae are often difficult to visualize in tissue with routine haematoxylin-eosin (H&E) staining but can be
 348 easily identified with Grocott-Gomori's methenamine silver (GMS) or periodic acid-Schiff (PAS) staining.
 349 In the absence of microbial growth, distinguishing fusariosis from other hyalohyphomycosis may be diffi-
 350 cult and requires the use of *in situ* hybridization of paraffin-embedded tissue specimens³²⁵. Matrix assisted
 351 laser desorption/ionization-time of flight mass spectrometry (MALDI-TOF MS) is also increasingly used
 352 for the identification of molds^{326,327,328,329} (Table 1).

353 **Table 1. Microbiological, histopathological and imaging diagnostics of *Fusarium* spp. infections**

Population	Intention	Intervention	SoR	QoE	Reference	Comment
Microscopy, culture, MIC testing						
Any	To diagnose	Direct microscopy of skin biopsy	A	IIu	Nucci PLOSONE 2014 ²³⁰	Allows rapid presumptive diagnosis much earlier than culture
Any	To diagnose	Histopathology	A	II	Hayden DMP 2003 ³²⁵	Hyphae similar to <i>Aspergillus</i> spp., hyaline, septate filaments, dichotomizing in acute angles
Any	To diagnose	Blood culture	A	IIu	Nucci PLOSONE 2014 ²³⁰	Blood cultures positive in 40% of cases with disseminated infection
Any	To diagnose	Fungal blood culture bottles	B	IIIu	Hennequin EJCMI 2002 ³²³ Nucci CMR 2007 ³⁰	Faster detection of growth compared with aerobic bottles Low inocula (10 ² and 10 ³ CFU/ml) detected earlier in fungal medium
Any with keratitis	To diagnose	Culture	A	III	Nucci CMR 2007 ³⁰	
Any	To determine MICs	Antifungal susceptibility testing, E-test	B	III	Dannaoui JFungi 2019 ³³⁰	
Any	To establish epidemiologic knowledge	MIC testing (CLSI or EU-CAST)	A	IIu	Espinel-Ingroff AAC 2016 ³³¹	
Any	To inform antifungal choice	MIC testing (CLSI or EU-CAST)	C	IIu	Stempel OFID 2015 ²⁸⁵ Lamoth JCM 2016 ³³²	N=9 N=12
Antigen-based assays						
Hematological malignancy	To diagnose	GM (Platelia, Bio-Rad) in serum	B	IIu	Nucci PLOSONE 2014 ²³⁰	83% sens., 67% spec., 73% serum GM positive before 1 st clinical manifestation
Any	To diagnose	BDG (Fugitell, Assoc Cape Cod) in serum	C	IIa	Nucci Mycoses 2019 ³³³	For 2 tests >80 pg/ml, 90% sens. and 61% spec., high NPV, low PPV
Hematological malignancy with fever	To distinguish aspergilliosis and fusariosis	GM (Platelia, Bio-Rad) in serum	D	II	Nucci CMI 2018 ³³⁴	GM positive 89% in IA, 73% in fusariosis
Any with GM-pos. fusariosis	To monitor response	Repeat GM (Platelia, Bio-Rad) in serum	A	II	Nucci PLOSONE 2014 ²³⁰	Persistently positive GM associated with worse outcome
Any	To rule out fusariosis	<i>Aspergillus</i> -specific LFD (OLM)	C	III	Thornton CVI 2008 ³³⁵ Hoenigl JCM 2014 ³³⁶	LFD highly specific, results negative in samples from patients with invasive fusariosis
Nucleic acid-based assays/MALDI-TOF MS						
Any	To diagnose	Multifungal DNA microarray	C	III	Boch Mycoses 2015 ³³⁷	
Any	To diagnose	Multiplex tandem PCR on blood cultures	C	III	Lau JCM 2008 ³³⁸	
Any	To diagnose	Panfungal semi-nested PCR	C	III	Landlinger JCM 2009 ³³⁹	ITS2 target + Luminex xMAP technology
Any	To diagnose	Panfungal semi-nested PCR	C	III	Landlinger EJCMI 2009 ³⁴⁰	ITS2 target + AFLP on different materials, N=60 species incl. N=4 <i>Fusarium</i> spp.
Any	To diagnose	Panfungal PCR + sequencing on fresh tissues and FFPE	C	III	Lau JCM 2007 ³⁴¹	ITS1 target, 1/1 <i>Fusarium</i> spp. detected

Any	To diagnose	MLST, RT-PCR, LAMP	B	IIu	De Souza Mycopathol 2017 ³⁴²	
Neutropenic pediatric	To diagnose	Panfungal 28S qPCR	C	II	Landlinger Leukemia 2010 ³⁴³	96% sens., 77% spec.
Neutropenic patients	To diagnose	Multiplex PCR + DNA microarray hybridization	C	III	Spieß JCM 2007 ³⁴⁴	
Any	To detect and identify <i>Fusarium</i> spp.	Genus specific PCR	C	III	Hennequin JCM 1999 ³⁴⁵ Hue JCM 1999 ³⁴⁶	includes <i>Acremonium</i> and <i>Cylindrocarpon</i> ; 28S target, N=6 <i>Fusarium</i> spp.
Hematology/oncology	To identify <i>Fusarium</i> spp.	DNA microarray, qPCR, LAMP and EF1 α sequencing	A	III	De Souza Mycopathol 2017 ³⁴²	N=20 isolates
Any	To identify	TEF1 α sequencing	A	IIu	Herkert FrontMicrobiol 2019 ³⁴⁷	N=43 isolates
Any	To identify	28S rDNA and TEF1 α sequencing, 28S rDNA specific PCR	B	III	Gaviria-Rivera RSP 2018 ³⁴⁸	
Hematology/oncology	To identify	MLST with RPB2, TEF1 α , ITS sequencing	B	III	Dalle Rosa JMM 2018 ³⁴⁹	N=1, new species <i>F. riograndense</i>
Keratitis	To identify	TEF1 α sequencing	A	IIu	Boral Mycopathol 2018 ²⁴ Walther JCM 2017 ²¹	N=3 N=22
Eumycetoma	To identify	Culture + histopathology + TEF1 α sequencing	B	III	Al-Hatmi Mycoses 2017 ³⁵⁰	N=2
Any	To identify species	Automated repetitive element sequence-based PCR	C	IIu	Healy JCM 2005 ³⁵¹	N=26 isolates, web-based data analyses (Diversi-Lab)
Any	To identify species	ITS from primary clinical sample, EF1 α from culture	A	IIu	Thomas JMM 2019 ³⁵²	N=33 isolates, retrospective
Any	To identify	MALDI-TOF MS	B	IIu	Triest JCM 2015 ³²⁹ Chalupova BiotechAdv 2014 ³²⁸	
Any	To detect and investigate an outbreak	Molecular genotyping	B	IIu	O'Donnell JCM 2004 ³⁵³	N=33 isolates, geographically widespread clonal lineage
Imaging studies						
Hematological malignancies	To differentiate fusariosis from aspergillosis	Chest CT	C	IIh	Nucci CMI 2018 ³³⁴	Similar images including macronodules with or without halo
Any	To differentiate fusariosis from other invasive mold diseases	Chest CT	C	III	Nucci SRCCM 2015 ³⁵⁴ Sassi Mycoses 2016 ²⁶⁵ Marom AJR 2008 ³⁵⁵	Fusariosis suspected if hypodense sign w/o halo or vessel occlusion; search for sinusitis

AFLP, amplified fragment-length polymorphism; BDG: Beta-D-glucan; CFU, colony-forming unit; CT, computed tomography; DNA, deoxyribonucleic acid; EF1 α , elongation factor 1 α ; FFPE, formalin-fixed paraffin-embedded tissue; GM, galactomannan; IA, invasive aspergillosis; ITS, internal transcribed spacer; LAMP, loop-mediated isothermal amplification; LFD, Lateral Flow Device; MALDI-TOF MS, matrix assisted laser desorption ionization-time of flight mass spectrometry; MIC, minimal inhibitory concentration; MLST, multilocus sequence typing; NPV, negative predictive value; PCR, polymerase chain reaction; PPV, positive predictive value; QoE, quality of evidence; qPCR, quantitative polymerase chain reaction; rDNA, ribosomal DNA; RPB2, ribonucleic acid polymerase II gene; RT-PCR, real time polymerase chain reaction; sen., sensitivity; spec., specificity; SoR, strength of recommendation; TEF1 α , translation elongation factor 1 α ; w/o without.

354

355 **Recommendations** – Conventional methods are strongly recommended for the diagnosis of fusariosis and

356 include direct microscopy, culture and histopathology. *Fusarium* spp. grow rapidly in most culture media

357 without cycloheximide. The guideline group strongly recommends obtaining infected tissue or body fluids

358 for histological or cytological evaluation and culture. Use of both culture and histopathology together

359 should increase the yield of diagnostic testing.

360 **Diagnosis – microbiology - serological testing**

361 **Evidence** – Prior to establishing *Fusarium* spp. as the fungal cause of infection, other blood tests such as
362 the *Aspergillus* galactomannan antigen test (GM; Platelia *Aspergillus* EIA BioRad) or (1→3)-β-D-glucan
363 (BDG; Fungitell®, Associates of Cape Cod Diagnostics) assay, may be ordered. Knowledge of their perfor-
364 mance in the setting of an active *Fusarium* infection is helpful. Serum GM antigen detection has 83% sen-
365 sitivity and 67% specificity during *Fusarium* infection in the neutropenic immunocompromised host²³⁰,
366 with 73% of tests positive prior to the first clinical manifestation observed²³⁰. In a later study, *Aspergillus*
367 serum GM antigen was positive in 89% of cases of invasive aspergillosis, while it was positive in 73% of
368 cases of fusariosis³³⁴. In any patient with fusariosis with a positive *Aspergillus* serum GM antigen test,
369 repeated testing over time (e.g., once weekly) may help with treatment stratification and outcome pre-
370 diction, as continuously positive GM test results correlate with negative outcome²³⁰. When the BDG assay
371 is used and two sequential tests are both >80 pg/ml, sensitivity is 90% and specificity 61% for *Fusarium*
372 infections, since positive results may also indicate infections caused by *Aspergillus*, *Candida* and other
373 fungal pathogens³³³. The *Aspergillus*-specific Lateral Flow Device (LFD) Test (OLM Diagnostics) is highly
374 specific for aspergillosis, while results have been found negative in samples from patients with invasive
375 fusariosis, which may therefore differentiate between aspergillosis and fusariosis^{335,336}.

376 **Recommendations** – Galactomannan (GM) testing is moderately recommended and BDG marginally rec-
377 ommended as part of the diagnostic evaluation for fusariosis. Monitoring serum GM during treatment is
378 strongly recommended for those patients with positive serum GM results.

379 **Diagnosis – Microbiology – Molecular testing**

380 **Evidence** – Molecular testing is used for genotyping and species identification of clinical isolates, although
381 this information is not usually useful in practice^{347,351-353}. Investigators have used murine models to de-
382 velop these molecular assays^{356,357}. Molecular genetic methods include amplified fragment length poly-
383 morphisms (AFLP), loop mediated isothermal amplification (LAMP), multilocus sequence typing (MLST),
384 and real-time polymerase chain reaction (RT-PCR). Accurate identification of *Fusarium* to the species level
385 was often achieved by using *TEF1-α* sequencing, which allowed detection of various species including *F.*

386 *oxysporum*, *F. solani*, *F. keratoplasticum*, *F. petroliphilum*, *F. napiforme*, *Fusarium falciforme*, *F. pseudensi-*
387 *forme*, *F. dimerum* and the new species *Fusarium riograndense*^{21,24,342,350}.

388 When *TEF1-α* was used as part of a multiplex PCR and DNA microarray hybridization panel used for species
389 identification primarily in neutropenic cancer patients, *F. solani* and *F. oxysporum* could be reliably iden-
390 tified, but these tests are not validated for clinical implementation^{337,344}. If *TEF1-α* was included in a
391 panfungal semi-nested PCR (ITS2 target) and Luminex xMAP technology approach analysing various clini-
392 cal specimens, *F. solani*, *F. oxysporum*, *F. verticillioides*, and *F. proliferatum* could be identified. These
393 assays can be considered pan-*Fusarium*³³⁹. PCR has been used with a variety of specimen sources³³⁸⁻
394 ^{340,343,344}, including blood^{338,343}, spinal fluid, and tissue material^{341,343}. Accurate identification of *Fusarium*
395 spp. from invasive infections to species level is important not only from an epidemiological standpoint,
396 but also for choosing the appropriate antifungal treatment. For example *F. solani* spp. complex show
397 higher MICs to VCZ and AmB than *F. oxysporum* spp. complex. Within *F. solani* spp. complex, *F. kerato-*
398 *plasticum* had higher MICs than *F. falciforme* and *F. petroliphilum* in one study from Brazil³⁴⁷.

399 **Recommendations** – Molecular-based diagnostic testing is not widely available; it is mainly based on in-
400 house tests at centers where there is expertise in this area. If available, these tests are strongly recom-
401 mended for species identification, which may have implications for antifungal susceptibility, and margin-
402 ally recommended directly from clinical specimens.

403 **Diagnosis – microbiology – susceptibility testing**

404 **Evidence** – Susceptibility testing of isolates recovered in culture should be used for epidemiologic pur-
405 poses in defining the range of minimal inhibitory concentrations (MIC) distributions for *Fusarium* spp.³³¹.
406 However, studies demonstrating that susceptibility testing results should be utilized to inform antifungal
407 drug choice are lacking^{285,332}. In one case series, there was a high rate of treatment failure (11/12) among
408 patients with disseminated fusariosis who received VCZ as first-line treatment, where susceptibility test-
409 ing showed a lack of *in vitro* activity of this drug (MIC ≥16 µg/mL)³³². Conversely, in another study, among
410 nine clinical isolates tested, there was no correlation between MIC and clinical outcome, and some cases

411 responded well to VCZ treatment despite high MICs²⁸⁵. These discrepancies between MIC and outcome
412 may be related to the critical role that host factors play in treatment of fusariosis in immunocompromised
413 patients. Although there are no interpretative breakpoints for antifungal agents against *Fusarium* spp.,
414 compounds with MICs that are off-scale, such as >16 µg/ml, at the highest range of concentrations are
415 unlikely to be active in patients. While susceptibility testing according to EUCAST or CLSI is primarily rec-
416 ommended, the E-test® (bioMérieux) is a good alternative method for testing of *Fusarium* spp., but unu-
417 sually high MICs should be confirmed by the CLSI method³³⁰.

418 **Recommendations** – Susceptibility testing of isolates is strongly recommended for epidemiologic pur-
419 poses and marginally recommended for informing antifungal drug choice for fusariosis. Although there is
420 little correlation between MIC and clinical success, knowing the causative species and its resistance pat-
421 tern may help with some decisions such as combination therapy and duration of therapy.

422 **Diagnosis – Imaging**

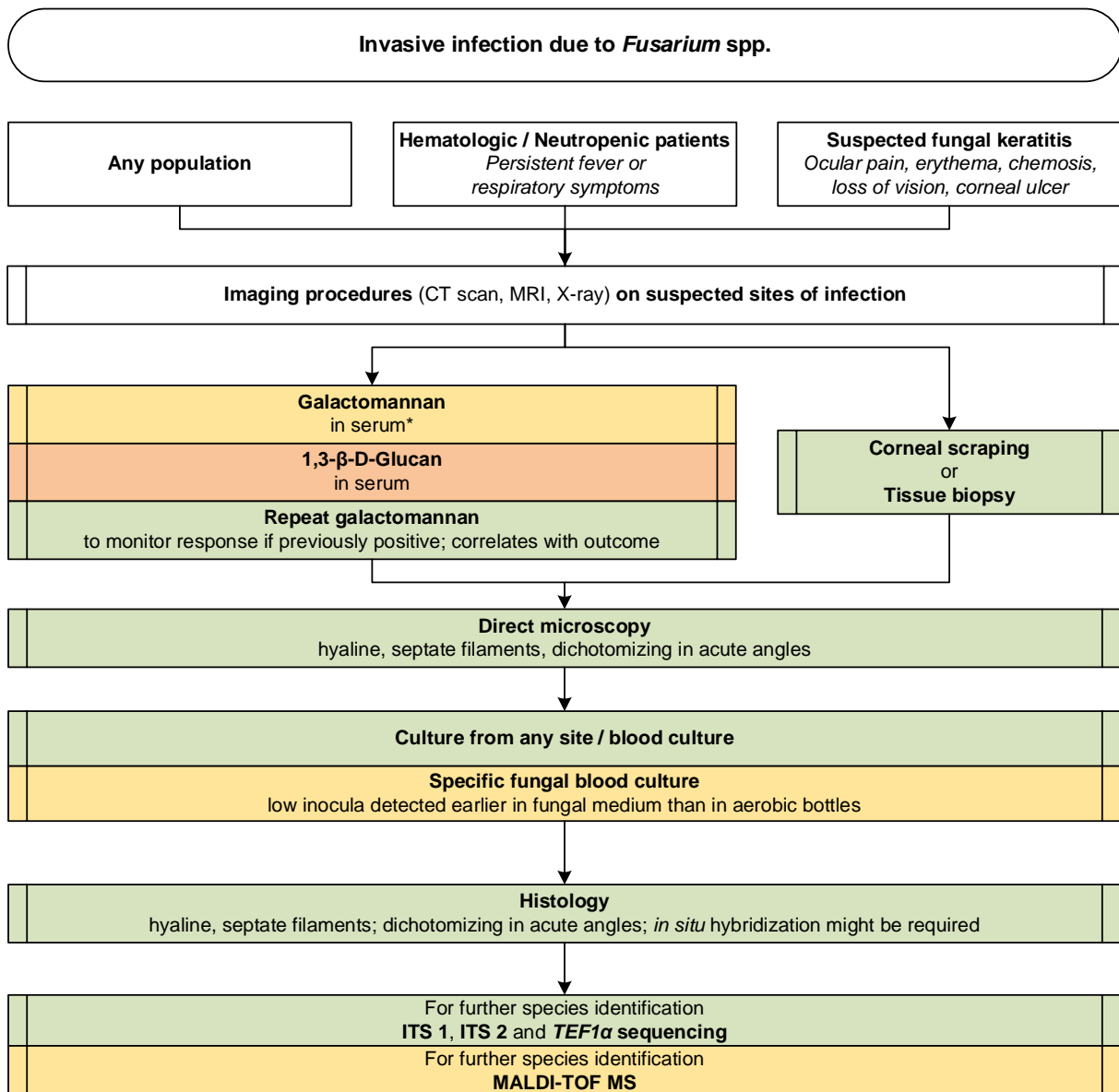
423 **Evidence** – Imaging studies may produce subtle findings that help differentiate fusariosis from aspergillo-
424 sis^{231,265,334,355}. Both fusariosis and aspergillosis present with macronodules on imaging. Cases of aspergil-
425 losis may have a halo sign, while cases of fusariosis are less likely to have a halo sign^{231,334}. Invasive fusari-
426 osis should be suspected if chest computed tomography (CT) imaging demonstrates pulmonary infiltrates
427 with a hypodense sign, but without the halo or the occluded-vessel signs. Suspicion is greater in the pres-
428 ence of hyperdense maxillary and ethmoid sinusitis.

429 **Recommendations** – CT imaging is marginally to moderately recommended for differentiating fusariosis
430 from other invasive mold diseases including aspergillosis. Proceed with imaging for any suspected lung or
431 sinus infection, since those body sites can have fluids or tissues to be examined by both culture and his-
432 topathology. As with other invasive fungal infections, imaging studies may assist in recognizing that there
433 is a fungal infection, and may assist in the procurement of infected tissue or body fluids for further analysis
434 when needed. No radiological findings reliably discriminate between different mold infections.

435 ***Diagnosis – Summary***

436 Proceed with imaging for any suspected sinus, lung or liver involvement, since those body sites can have
437 fluids or tissues to be examined by both culture and histopathology. Proceed with corneal scrapings of
438 any corneal lesions. Proceed with biopsy of any skin lesions, particularly among neutropenic patients.
439 While it is helpful to perform MIC testing of isolates recovered in culture, MIC results may not always
440 correlate with clinical outcome. Additional molecular workup of organisms recovered from cultures will
441 depend on the resources available at a particular center (**Figure 4**).

442 **Figure 4. Optimal diagnostic pathway for fusariosis, when all imaging and assay techniques are available**
 443



Legend:

strongly recommended ■
 moderately recommended ■
 marginally recommended ■
 recommended against ■

CT, computed tomography; ITS, internal transcribed spacer; MALDI-TOF MS, matrix-assisted laser desorption/ionization time-of-flight mass spectrometry; MRI, magnetic resonance imaging; *TEF1α*, translational elongation factor 1α

* Serum galactomannan has been shown to have reduced sensitivity in the absence of neutropenia, and may therefore be less reliable as diagnostic in the non-neutropenic host

445 **Treatment approaches for infections caused by rare molds – Standard Dosing recommendations for**
 446 **adults**

447 Standard dosages of antifungals recommended in this guideline for treatment of rare mold infections in
 448 adults are outlined in **Table 2**.

449 **Table 2. Standard dosing recommendations for adults with rare mold infections***

	Standard Dosage	Route of Administration	Therapeutic Drug Monitoring
Voriconazole(VCZ)³⁵⁸	2x 6 mg/kg d1, 2x 4 mg/kg from d2	iv; po	Yes, target trough level > 1.5-2 mg/l and <6mg/l
Posaconazole (PCZ)^{7,359,360}	Suspension: 4x 200 mg or 2x 400 mg (lower exposure than 4x 200 mg) Delayed-release tablet/iv: 2x 300 mg on d1, 1x 300 mg from d2	iv; po (tablet preferable over suspension)	Yes (when used for treatment; target trough level > 0.7 mg/l)
Isavuconazole (ISA)^{7,361}	3x 200 mg on d1+2; 1x 200 mg/d thereafter	iv; po	No
Itraconazole (ICZ)³⁶²	iv: 200-400 mg/d po: 100-400 mg/d SUBA-ICZ: 50-100 mg/d	iv; po; for po consider SUBA-ICZ	Yes
Liposomal amphotericin B (L-AmB)³⁶³	3-5 mg/kg qd	iv	No
Amphotericin B Lipid Complex (ABLC)³⁶⁴	3-5 mg/kg qd	iv	No
Amphotericin B colloidal dispersion (ABCD)³⁶⁵	6 mg/kg qd	iv	No
Amphotericin B deoxycholate (D-AmB)³⁶³	1 mg/kg qd	iv	No
Caspofungin (CASPO)³⁶⁶	70 mg on d1, 50 mg from d2	iv	No
Anidulafungin (ANID)³⁶⁶	200 mg on d1, 100 mg from d2	iv	No
Micafungin (MICA)³⁶⁶	100 mg/d	iv	No
Terbinafine (TRB)^{367,368}	2x 250-500 mg/d	po	No
5-Flucytosine (5-FC)³⁶⁹	po: 50-150 mg/kg qd in divided doses every 6 hours iv: 70-150 mg/kg qd in divided doses every 6 hours	iv; po	Yes, target trough level 25-50 µg/ml, peak level 50-100 µg/ml
* For definitions of conditions that may require treatment stop/salvage treatment, including persistent, refractory, relapsed or breakthrough IFI, please refer to ³⁷⁰ d, day(s); iv, intravenous; po, orally; qd, once a day; SUBA, super bioavailability			

450

451

452

453

454 **Treatment approaches to fusariosis**

455 Treatment in adults

456 **Primary prophylaxis**

457 **Evidence** – While mold active prophylaxis that covers also *Fusarium* spp. has become standard of care in
458 many high-risk settings, primary prophylaxis specifically for invasive fusariosis has been evaluated in one
459 study only, in a subset of patients³⁰². A previous study from the same group showed that high-risk hema-
460 tological patients (acute leukemia or HSCT) with superficial skin lesions on the feet (interdigital intertrigo
461 and / or onychomycosis) on hospital admission with positive culture for *Fusarium* spp. were at an in-
462 creased risk of developing invasive fusariosis²². In this non-randomized trial, mold active prophylaxis
463 (VCZ or PCZ) was given in 20 episodes at risk (neutropenia or graft versus host disease), while flucona-
464 zole or no prophylaxis was administered in 219 episodes³⁰². Invasive fusariosis occurred in a similar pro-
465 portion, namely 5.9% of the patients without and in 5% with anti-mold prophylaxis. However, in the sub-
466 group of patients with superficial skin lesions with positive cultures for *Fusarium* spp., four out of five
467 patients who had not received anti-mold prophylaxis developed invasive fusariosis vs. none out of six
468 who received VCZ or PCZ ($p=0.01$). Cases of breakthrough invasive fusariosis have been reported in pa-
469 tients receiving primary mold-active prophylaxis with PCZ, VCZ or isavuconazole (ISA)^{9,194,370-373} (**Table 3**).

470 **Recommendations** – Primary prophylaxis with a mold-active triazole (VCZ or PCZ) is moderately recom-
471 mended in high-risk hematological patients who present with superficial skin lesions with positive cultures
472 for *Fusarium* spp. There are no data to support mold-active primary prophylaxis specifically to prevent
473 fusariosis in other settings.

474 **Secondary prophylaxis**

475 **Evidence** – Secondary prophylaxis for invasive fusariosis was evaluated in a multicenter retrospective
476 study of 40 patients who were successfully treated for invasive fusariosis and were exposed to subsequent
477 periods of immunosuppression (neutropenia in 35 patients and graft versus host disease in five pa-
478 tients)²³¹. Overall, 32 patients received secondary prophylaxis (VCZ in 24 patients, PCZ in two patients and
479 a lipid formulation of amphotericin B (AmB) in six patients). Relapse of invasive fusariosis occurred in two
480 of the eight patients (25%) who were not on secondary prophylaxis and in three out of 32 (9.4%) patients
481 who received secondary prophylaxis ($p=0.26$). Considering only patients who had disseminated fusariosis,

482 relapse occurred in both patients not on secondary prophylaxis and in three out of 26 (11.5%) patients
483 who had received secondary prophylaxis ($p=0.03$) (**Table 3**).

484 **Recommendations** – Secondary prophylaxis with a mold-active triazole or a lipid formulation of AmB is
485 moderately recommended in patients with prior invasive fusariosis who will be exposed to subsequent
486 periods of immunosuppression, especially if the previous disease was disseminated.

487

488 ***Diagnostic-driven treatment***

489 **Evidence** – Patients with invasive fusariosis may frequently present with positive serum GM or BDG. In a
490 multicenter study, 15 out of 18 patients with invasive fusariosis had at least one positive serum GM test.
491 In one study, serum GM was positive at a median of 10 days before the first clinical manifestation of
492 fusariosis in 73% of patients²³⁰. In another study, 12 out of 13 patients with invasive fusariosis had a pos-
493 itive BDG, in 11 the test was positive prior to the diagnosis of invasive fusariosis. However, the test lacked
494 specificity and the positive predictive value for 2 consecutive positive BDG tests was 7% only³³³. Another
495 study evaluated the strategy of using the area over the neutrophil curve (D-index) to stratify the risk for
496 invasive mold disease in 29 high-risk neutropenic patients³⁷⁴. A cumulative index above 5,800 identified a
497 group at higher risk, with a rate of invasive mold disease (including fusariosis) of 67%, 45.5% and 0% in
498 high-, intermediate- and low-risk patients, respectively (**Table 3**).

499 **Recommendations** – Serum GM, serum BDG and the cumulative D-index may be of help to establish a
500 diagnostic-driven approach in high risk neutropenic patients. However, these tests lack specificity for the
501 diagnosis of invasive fusariosis. Therefore, the guideline marginally supports the use of these tools for
502 initiating specific treatment for invasive fusariosis.

503 ***First line treatment***

504 **Evidence** – There are no randomized trials evaluating antifungal drugs for the treatment of invasive fusa-
505 riosis. The largest series published to date is a multicenter retrospective study of 236 patients with inva-
506 sive fusariosis diagnosed between 1985 and 2011 in 44 centers from 11 countries all over the world²⁸.
507 Among 206 patients who received treatment for invasive fusariosis, 110 received AmB deoxycholate (D-

508 AmB), 38 were treated with VCZ, 34 with a lipid formulation of AmB (liposomal 20, lipid complex 8, colloidal dispersion 6; in a previous study lipid complex was less well tolerated than the liposomal formulation
 509 dal dispersion 6; in a previous study lipid complex was less well tolerated than the liposomal formulation
 510 with more acute infusion-toxicity³⁷⁵), 21 received combination therapy (mainly VCZ plus AmB), and three
 511 received other therapies. The 90-day probability of survival was 27% for patients treated with D-AmB,
 512 53% for patients receiving VCZ, and 48% for those receiving a lipid formulation of AmB.

513 Other studies reported lower numbers of patients receiving primary treatment with a single agent for
 514 invasive fusariosis with either VCZ (54 patients, response rates ranging from 44 to 100%, including local-
 515 ized disease)^{18,201,285,376,377}, AmB lipid complex (ABLC; 28 patients, 43% response rate)³⁷⁸, liposomal AmB
 516 (L-AmB; 10 patients, response rates from 0 to 100%)^{9,371,379,380}, and D-AmB (5 patients, 20% response
 517 rate)³⁷⁹. A few patients received treatment with either ISA, echinocandins, terbinafine (TRB) or PCZ<sup>285,381-
 518 383</sup>.

519 Combination therapy with VCZ plus L-AmB or another agent was reported in the majority of studies, and
 520 is the preferred initial approach in many specialized centers because of high VCZ MICs, while other centers
 521 prefer monotherapy^{18,28,159,201,285,377,382,384,385}. Response rates with combination therapy overall were sim-
 522 ilar to monotherapy, and randomised controlled trials comparing monotherapy with combination therapy
 523 are lacking. In one study, combination therapy was used in 21 out of 236 patients (including VCZ plus L-
 524 AmB in 12 cases and VCZ plus D-AmB in 5 cases). Response rates were not significantly different than for
 525 monotherapy and receipt of combination therapy was not significantly associated with 90-day survival²⁸.
 526 However, as combination therapy may have been used in more critically ill patients, no conclusions can
 527 be drawn from this retrospective study between combination therapy and monotherapy.

528 Removal of indwelling central venous catheters has been associated with improvement in observational
 529 studies and thus should be considered in all cases of fungemia³⁸⁶ (**Table 3**).

530 **Table 3. Prophylaxis and first line treatment of *Fusarium* spp. infections**

Population	Intention	Intervention	SoR	QoE	Reference	Comment
Prophylaxis						
HSCT with superficial skin fusariosis	To prevent invasive disease	Primary prophylaxis with PCZ or VCZ	B	Ilu	Varon AAC 2016 ³⁰²	
					Bose JCM 2011 ³⁸⁷	N=2, breakthrough during PCZ
HSCT after disseminated fusariosis	To prevent recurrence	Secondary prophylaxis with PCZ, VCZ or L-AmB	B	Ilu	Nucci Mycoses 2019 ²³¹	
Fever-driven treatment						

Any	To cure	Initiate treatment upon fever	D	III	No reference found.	
Diagnosis-driven treatment						
Hematological malignancy	To increase survival rate	Apply D-Index for treatment initiation	C	Ilu	Garnica BJID 2016 ³⁷⁴	
First-line treatment						
Any	To cure	L-AmB 3-9 mg/kg qd iv	A	Ilu	Nucci CMI 2014 ²⁸	N=20
					Jensen CMI 2004 ³⁸⁰	N=4
					Musa BJH 2000 ³⁷⁹	N=3
					Jenks IJAA 2018 ³⁸⁴	N=2
					Cudillo AH 2006 ³⁸⁸	N=1
					Lamoth JCM 2016 ³³²	
Any	To cure	VCZ iv, switch to po when stable,	A	Ilu	Nucci CMI 2014 ²⁸	N=38, 92% hematology, 90 d survival 60%
					Stanzani TCRM 2007 ³⁷⁷	N=19, 63% response
					Muhammed Medicine 2013 ¹⁸	N=8, 100% response
					Lortholary AAC 2010 ²⁰¹	N=16, 44% response
					Perfect CID 2003 ³⁷⁶	N=11, 45% response
					Jenks IJAA 2018 ³⁸⁴	N=1, burn patient, success
Any	To cure	VCZ in combination with AmB lipid formulation	A	Ilu	Lortholary AAC 2010 ²⁰¹	N=13, diverse combinations
					Nucci CMI 2014 ²⁸	N=21
					Muhammed Medicine 2013 ¹⁸	N=9
					Stanzani TCRM 2007 ³⁷⁷	N=3
					Horn Mycoses 2014 ³⁸⁵	N=19
					Stempel OFID 2015 ²⁸⁵	N=6
Any	To cure	ABLC	A	Ilu	Nucci CMI 2014 ²⁸	N=34, including ABLC (N=8), and ABCD (N=6); 90 d survival 53%
					Perfect CID 2005 ³⁷⁸	N=26 with ABLC 2-10mg/kg qd; 12 (46%) cured/improved, 3 (12%) stable response
Any	To cure	D-AmB	D	Ilu	Nucci CMI 2014 ²⁸	N=110, poorer response (90 d survival 28%, 95%CI 20-36%) compared with VCZ or AmB lipid formulation
					Musa BJH 2000 ³⁷⁹	N=5, response in 1/5 (20%)
Any	To cure	AmB lipid formulation + triazole/echinocandin/TRB	B	Ilt	Campo Jlnf 2010 ³⁸⁹	N=44, 37/44 (84%) changed to combination; 12 wk mortality 66%
					Muhammed Medicine 2013 ¹⁸	N=2, L-AmB plus CASPO or MICA, 2/2 died
					Rothe AnnHematol 2004 ³⁹⁰	N=1, response to AmB plus TRB
Hematological malignancy	To cure	VCZ	A	Ilt	Stempel OFID 2015 ²⁸⁵	N=15, 5 success
Hematological Malignancy	To cure	ISA	C	III	Cornely Mycoses 2018 ³⁸¹	N=1, success
Hematological malignancy	To cure	Echinocandin	D	III	Stempel OFID 2015 ²⁸⁵	N=1
					Apostolidis CID 2003 ³⁸³	N=1
Hematological malignancy	To cure	TRB	C	III	Stempel OFID 2015 ²⁸⁵	N=1, success
Solid organ transplant	To cure	PCZ	C	III	Herbrecht JHLT 2004 ³⁸²	N=1, success
Hematological malignancy with endophthalmitis	To cure	VCZ for 10 d iv, switch to po +/- VCZ intravitreal +/- AmB intravitreal +/- vitrectomy	B	III	Simon JMM 2018 ²⁸⁰	N=1, success
					Bui JOPT 2016 ⁸²	N=1, success
Hematological malignancy with endophthalmitis	To cure	L-AmB 5-9 mg/kg qd or other AmB formulations iv +/- AmB intravitreal 5 mg/0.1 ml qw +/- vitrectomy	C	III	Ocampo-Garza JEADV 2016 ²³³	N=1, success
					Rezai ArchOphthalmol 2005 ³⁹¹	N=1, failure
					Malavade IDCP 2013 ³⁹²	N=1, failure
					Cudillo AnnHematol 2006 ³⁸⁸	N=1, success
Hematological malignancy with endophthalmitis	To cure	VCZ iv + L-AmB +/- VCZ intravitreal 100 mg/0.1 ml/wk, +/- AmB intravitreal	B	III	Kapp TID 2011 ¹⁷¹	N=1, failure
					Baysal CRH 2018 ⁷¹	N=1, success
					Rizzello Mycoses 2017 ²⁵⁶	N=1, success
					Perini Einstein 2013 ²⁴⁴	N=1, failure
					Malavade IDCP 2013 ³⁹²	N=1, success

		5 mg/0.1 ml/wk +/- vitrectomy			Yoshida Mycopathol 2018 ³¹³	N=1, success
					Bui JOPT 2016 ⁸²	N=1, success
Immunocompetent patient with endophthalmitis	To cure	VCZ, AmB intravitreal, vitrectomy	C	III	Milligan AJOCR 2018 ³⁹³	N=1, failure
Liver transplantation with endophthalmitis	To cure	VCZ iv, intravitreal	C	III	Jørgensen JMCR 2014 ¹⁶⁴	N=1, success
Postoperative endophthalmitis	To cure	VCZ intravitreal, AmB intravitreal, vitrectomy	C	III	Mithal ClinOphthalmol 2015 ³⁹⁴	N=1, success
Postoperative endophthalmitis	To cure	VCZ	C	II	Buchta Mycopathol2014 ³⁹⁵	N=18, response 18/18
Postoperative endophthalmitis	To cure	VCZ, AmB intravitreal, vitrectomy	C	III	Chander Mycopathol 2011 ⁹⁶	N=1, success
Postoperative endophthalmitis	To cure	VCZ + VCZ intravitreal +/- topical + AmB intravitreal +/- topical, surgical intervention	B	II	Gungel Mycoses 2011 ³⁹⁶	N=9, response 4/9
					Cakir CER 2009 ³⁹⁷	N=8, success 6/8
Postoperative endophthalmitis	To cure	AmB 5 µg/0.1 ml intravitreal +/- vitrectomy	C	III	Alves da Costa Pertuiset CROM 2016 ⁵⁴	N=1, failure, salvage treatment, vitrectomy
					Ferrer JCM 2005 ³⁹⁸	N=1, success
Exogenous endophthalmitis	To cure	VCZ iv, switch to po or VCZ po +/- VCZ intraocular	B	III	Troke Infection 2012 ³⁹⁹	N=8, response 5/8
					Comer ClinOphthalmol 2012 ⁴⁰⁰	N=2, failure 2/2
Exogenous endophthalmitis	To cure	PCZ po, topical	C	III	Sponsel BJO 2002 ⁴⁰¹	N=1, success
Exogenous endophthalmitis	To cure	AmB + VCZ topical, po	C	III	Barrios Andrés RIM 2018 ⁶⁹	N=3, success 2/3
Exogenous endophthalmitis	To cure	Ketoconazole 200 mg/d po + natamycin topical 5% + D-AmB topical 0.15%	D	III	Comer ClinOphthalmol 2012 ⁴⁰⁰	N=1, failure

Standard dose unless stated otherwise; ABLC, amphotericin B lipid complex; AmB, amphotericin B; bid, twice a day; CASPO, caspofungin, CI, confidence interval; CF, cystic fibrosis; d, day(s); D-AmB, amphotericin B deoxycholate; po, orally; HSCT, hematopoietic stem cell transplantation; ISA, isavuconazole; iv, intravenous; L-AmB, liposomal amphotericin B; PCZ, posaconazole; qd, once a day; QoE, quality of evidence; qw, once a week, SoR, strength of recommendation; TDM, therapeutic drug monitoring; tid, three times a day; TRB, terbinafine; VCZ, voriconazole; wk, week(s).

531

532 **Recommendations** – Data regarding primary therapy with a lipid formulation of AmB show similar num-

533 bers of patients treated and similar response rates with either L-AmB (doses from 3 to 9 mg/kg qd) or

534 ABLC, which may be slightly worse tolerated than L-AmB. Likewise, data on primary therapy with VCZ

535 show similar response rates compared with a lipid formulation of AmB. We therefore strongly recommend

536 primary treatment for invasive fusariosis with either VCZ or a lipid formulation of AmB (L-AmB or other

537 lipid formulatons of AmB). Given the broad dose range used and the small number of patients treated

538 with the two lipid formulations of AmB, a formal recommendation for the dose of each agent cannot be

539 made. For VCZ, we strongly recommend the standard dose intravenous treatment, with step-down to oral

540 VCZ after disease control and the use of therapeutic drug monitoring (Allu), with a target trough level of

541 1.5 mg/l – 6 mg/l, which has been shown to ensure efficacy and avoid toxicity in patients with invasive
542 aspergillosis^{358,402} (**Table 1**). D-AmB should not be used for treatment of invasive fusariosis when other
543 active antifungal agents are available. For other agents a marginal recommendation is given.

544 Combination therapy is frequently used in the primary treatment of invasive fusariosis because of the
545 severity of the disease, difficulties to achieve VCZ trough levels within the targeted range, and because
546 MICs for azoles and polyenes are often high. Primary combination therapy with a potential early step
547 down to monotherapy later – once MICs come back - is an approach we strongly recommend.

548 ***Endophthalmitis***

549 **Evidence** – Ocular involvement in disseminated fusariosis occurs occasionally and may be associated with
550 loss of vision⁴⁰³. Proposed treatment strategies have relied on the use of systemic and intravitreal anti-
551 fungal agents, with or without vitrectomy. The literature on endophthalmitis in hematological patients is
552 limited to case reports in which patients were treated with either systemic VCZ^{82,280}, AmB^{233,371,391}, or VCZ
553 plus AmB^{71,171,244,256,313}, with or without intravitreal VCZ or AmB, with or without surgery.

554 Outside the setting of hematological patients, endophthalmitis caused by *Fusarium* spp. has been occa-
555 sionally reported in other immunosuppressed patients such as SOT recipients¹⁶⁴, in immunocompetent pa-
556 tients following ocular surgery^{54,96,394-398}, patients with keratitis (which is usually treated with natamycin
557 5% ophthalmic formulation)^{69,105,399,401}, or after dissemination from a primary skin lesion³⁹³. The majority
558 of patients were treated with systemic VCZ plus intravitreal VCZ or AmB and surgery, with variable re-
559 sponses.

560 **Recommendations** – Considering that VCZ is an option for the treatment of invasive fusariosis and that it
561 has good tissue distribution including the eyes, we favor the use of systemic VCZ (with or without AmB)
562 with intravitreal VCZ or AmB (moderately recommended) over systemic AmB (marginally recommended).
563 Surgical intervention (pars plana vitrectomy) should be discussed with an experienced ophthalmologist
564 on a patient to patient basis.

565

566 ***Salvage therapy***

567 **Evidence** – Because the outcome of invasive fusariosis is largely dependent on recovery of host de-
568 fences⁴⁰⁴, poor response to primary therapy does not necessarily mean that the antifungal drug is not
569 active. Nevertheless, patients who fail to respond to treatment should receive salvage therapy. A caveat
570 that must be acknowledged is that severely ill patients may die before a second treatment is offered and
571 therefore response rates with salvage therapy may be inflated because of this selection bias⁴⁰⁵. Another
572 consideration is that the drug chosen for salvage therapy depends on which agent was used for primary
573 treatment. Considering these factors, since most patients with invasive fusariosis have received formula-
574 tions of AmB in the past, the majority of data pertains to the use of a mold-active triazole as salvage
575 therapy. This does not necessarily mean that a lipid formulation of AmB cannot be used as salvage therapy
576 for a patient who received a triazole as primary therapy for invasive fusariosis.

577 The largest series of salvage therapy reported the outcome of 57 patients who received salvage therapy
578 with VCZ²⁰¹. The most frequent prior therapies were AmB (any formulation, 21 patients), an echinocandin
579 (10 patients) and another triazole (10 patients). The overall response rate was 47%. The second largest
580 series reported 21 patients who were refractory (n=17) to or intolerant (n=4) of primary therapy with
581 another drug (lipid formulation of AmB in 20 patients). The overall response rate was 48%⁴⁰⁶. Another
582 series reported 11 patients who received salvage VCZ, with a response rate of 45%³⁷⁶. Salvage therapy for
583 fusariosis with ISA was given to four patients, with one positive response^{381,407} (**Table 4**).

584 **Table 4. Antifungal salvage treatment for *Fusarium* spp. infections**

Population	Intention	Intervention	SoR	QoE	Reference	Comment
Any	To cure	VCZ +/- other antifungal (CASPO, L-AmB, TRB, PCZ, or white blood cell transfusion)	B	IIu	Lortholary AAC 2010 ²⁰¹	N= 57, success in 27
					Baden Transplantation 2003 ⁴⁰⁸	N=3, success in 3
Any	To cure	PCZ tablet or iv formulation preferred	B	IIu	Raad CID 2006 ⁴⁰⁶	N=21, success in 10
					Campo JInfect 2010 ³⁸⁹	N=2 hematology
Any	To cure	VCZ iv for ≥ 3 d, switch to po or VCZ	B	IIu	Perfect CID 2003 ³⁷⁶	N=11, success in 5
Any	To cure	ISA	C	III	Cornely Mycoses 2018 ³⁸¹ Marty Mycoses 2018 ⁴⁰⁷	N=4, success in 1
Any with disseminated fusariosis	To cure	TRB 500-750mg qd + VCZ iv or L-AmB	B	III	Inano JIC 2013 ¹⁵⁹	N=3, success in 3
					Rothe AnnHematol 2004 ³⁹⁰	
					Neuburger TID 2008 ⁴⁰⁹	
Hematological malignancy with skin infection and endophthalmitis	To cure	VCZ + AmB iv, intravitreal + vitrectomy	C	III	Malavade IDCP 2013 ³⁹²	N=1, outcome not reported
	To cure		C	II	Troke Infection 2012 ³⁹⁹	N=16, response in 11

Exogenous endophthalmitis		VCZ +/- VCZ intraocular 1% +/- VCZ intravitreal 2.5 µg/0.1 ml +/- AmB intravitreal 5 µg/0.1 ml +/- vitrectomy			Alves da Costa Pertuiset CROM 2016 ⁵⁴	N=1, success
					Comer ClinOphthalmol 2012 ⁴⁰⁰	N=3, success
Exogenous endophthalmitis	To cure	PCZ	C	III	Tu AJO 2007 ⁴¹⁰	N=2, response
Standard dose unless stated otherwise; AmB, amphotericin B; bid, twice a day; d, days; ISA, isavuconazole; iv, intravenous; L-AmB, liposomal amphotericin B; PCZ, posaconazole; po, orally; qd, once a day; QoE, quality of evidence; SoR, strength of recommendation; tid, three times a day; TRB, terbinafine; VCZ, voriconazole.						

585

586 **Recommendations** – We moderately recommend VCZ as salvage therapy for patients with progressive

587 disease who fail treatment with a lipid formulation of AmB. PCZ is a moderately recommended alterna-

588 tive, especially if the intravenous formulation and/or the modified release tablet formulation are availa-

589 ble, which provide more reliable serum levels than the oral solution. Other moderately recommended

590 options for salvage therapy include the combinations of TRB with VCZ or L-AmB, and combinations of VCZ

591 with other antifungals. ISA as salvage therapy is a marginally recommended alternative, with stronger

592 recommendations pending more data becoming available. Likewise, a lipid formulation of AmB is a rea-

593 sonable alternative for a patient who fails primary treatment with a triazole, but only marginally recom-

594 mended as strong supporting data are lacking.

595

596 **Ancillary therapies**

597 **Evidence** – Ancillary therapies for invasive fusariosis include surgical debridement of infected tissue, also

598 following trauma^{18,411,412}, the use of colony-stimulating factors such as granulocyte colony-stimulating fac-

599 tor (G-CSF) and granulocyte-monocyte colony-stimulating factor (GM-CSF)^{167,403}, and the use of granulo-

600 cyte transfusions^{167,403}.

601 In one study, surgical debridement for localized *Fusarium* infection in bone and joint resulted in control

602 of infection in all six patients⁴¹¹. Similar results were observed in a cohort of immunocompetent patients

603 with fusariosis confined to the skin¹⁸.

604 The use of G-CSF or GM-CSF was evaluated in 17 patients with invasive fusariosis with hematological ma-

605 lignancies, with a response rate of 41%⁴⁰³. The contribution of colony-stimulating factors on the favoura-

606 ble outcome is difficult to evaluate.

607 The best evidence for the use of granulocyte transfusions in patients with invasive fusariosis comes from
 608 a study that analyzed 11 patients, with 10 showing unequivocal signs of clinical response¹⁶⁷. It must be
 609 acknowledged that the use of colony-stimulating factors or granulocyte transfusions are measures under-
 610 taken to allow time for neutrophil recovery. If the patient remains neutropenic, the outcome is very
 611 poor⁴⁰⁴ (Table 5).

612 **Table 5. Other treatment options for *Fusarium* spp. infections**

Population	Intention	Intervention	SoR	QoE	Reference	Comment
Any	To cure	Resection of pulmonary infiltration/lobectomy and AmB	C	III	Lupinetti ATS 1990 ⁴¹²	N=1, success
Hematological malignancies	To cure	Granulocyte transfusion	C	III	Boutati Blood 1997 ⁴⁰³	N=7, response 3/7
Neutropenic	To cure	G-CSF or GM-CSF	B	IIu	Boutati Blood 1997 ⁴⁰³	N=17, response 7/17
					Kadri Transfusion 2015 ¹⁶⁷	N=11, granulocyte transfusion, response in 10; 90 d survival 73%
					Nucci Cancer 2003 ⁴⁰⁴	N=84
Any with fungemia	To cure	Removal of indwelling central venous catheters	B	IIut	Janum CDSR 2016 ⁴¹³	
Any with skin fusariosis	To cure	Surgical debridement	A	IIu	Muhammed Medicine 2013 ¹⁸	N=11
Bone and joint infections	To cure	Surgical debridement and antifungal treatment	A	IIr	Koehler CRM 2016 ⁴¹⁴	N=6, response 6/6

AmB, amphotericin B; d: day(s); G-CSF, granulocyte-colony stimulating factor; GM-CSF, granulocyte-macrophage colony-stimulating factor; QoE, quality of evidence; SoR, strength of recommendation

613
 614 **Recommendations** – We strongly recommend surgical debridement of infected tissue in cases of localized
 615 fusariosis of, for example, the skin following trauma, joints and bone. The use of G-CSF or GM-CSF should
 616 be considered if there is an expectancy of timely bone marrow recovery (moderately recommended).

617
 618 **Duration of treatment**

619 **Evidence** – In the largest series of treatment for invasive fusariosis in severely immunocompromised pa-
 620 tients, treatment was usually given until bone marrow recovery in neutropenic patients, or resolution of
 621 immunosuppression in non-neutropenic patients²⁸ (Table 6).

622 **Table 6. Treatment duration for *Fusarium* spp. infections**

Population	Intention	Intervention	Sor	QoE	Reference	Comment
Hematological malignancies or HSCT	To cure	VCZ or AmB until resolution of neutropenia and of clinical manifestations of infection	A	III	Nucci CMI 2014 ²⁸	
Exogenous endophthalmitis	To cure	VCZ for 4 wk to 4 mo	C	III	Buchta Mycopathol 2013 ³⁹⁵	N=20
					Comer ClinOphthalmol 2012 ⁴⁰⁰	N=2, success

					Alves da Costa Pertuiset CROM 2016 ⁴¹⁵	N=1, success
Hematological malignancy with disseminated fusariosis	To cure	L-AmB +/- VCZ +/- TRB for > 2 mo	B	III	Neuburger TID 2008 ⁴⁰⁹	N=1, success
					Cudillo AnnHematol 2006 ³⁸⁸	N=1, success
Endogenous endophthalmitis	To cure	VCZ iv for 5 d, then 4 mo VCZ po	C	III	Milligan AJOCR 2016 ⁴¹⁶	N=1, retinal detachment
Eye infections	To cure	VCZ for 6 wk to 7 mo	C	III	Troke Infection 2012 ³⁹⁹	N=24
AmB, amphotericin B; d, days; drug application as standard dose unless stated otherwise; HSCT, hematopoietic stem cell transplantation; iv, intravenous; L-AmB, liposomal amphotericin B; mo, month(s); po, orally; QoE, quality of evidence; SoR, strength of recommendation, TRB, terbinafine; VCZ, voriconazole; wk, week(s).						

623

624 **Recommendations** – We strongly recommend continuing treatment for invasive fusariosis until recovery

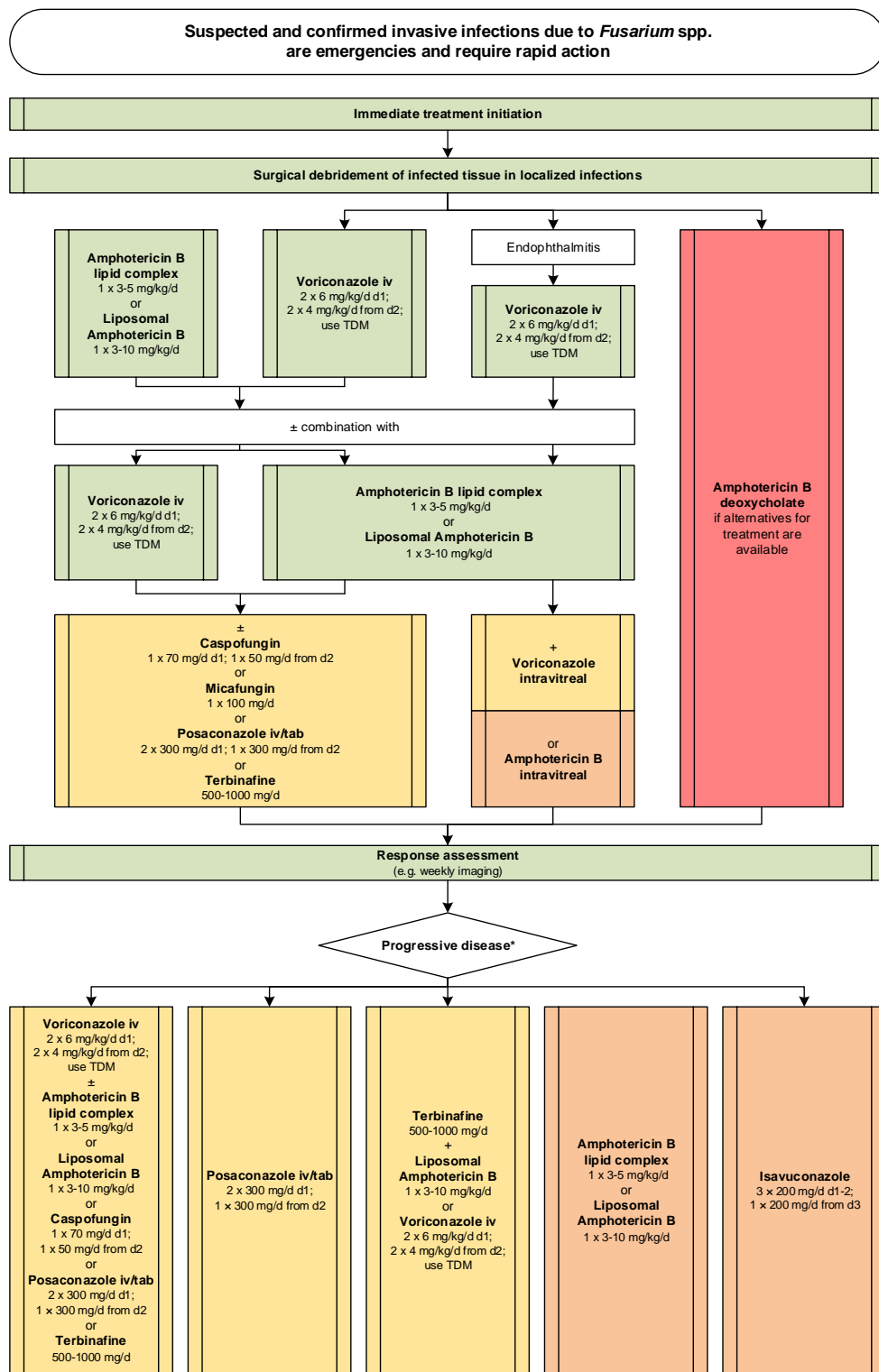
625 of host defences, and moderately recommend for disseminated disease a minimum treatment duration

626 of 2 months.

627

628 Treatment pathways for adults in different settings (**Figure 5, and Figure 6**).

629 **Figure 5. Optimal treatment pathway for fusariosis in adults when all treatment modalities and anti-**
 630 **fungal drugs are available**

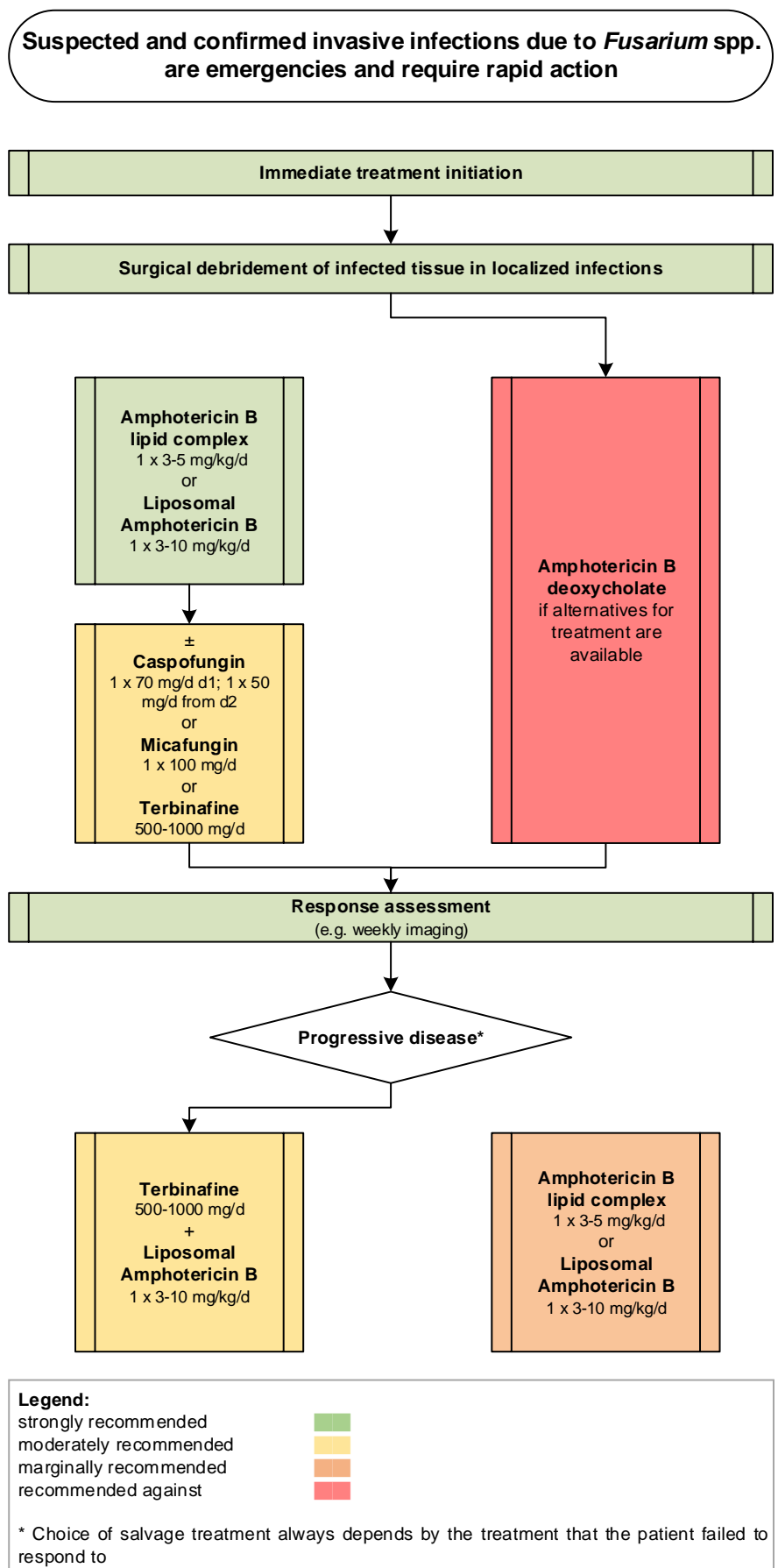


Legend:
 strongly recommended ■
 moderately recommended ■
 marginally recommended ■
 recommended against ■

TDM, therapeutic drug monitoring

* Choice of salvage treatment always depends by the treatment that the patient failed to respond to

632 Figure 6. Optimal treatment pathway for fusariosis in adults when triazoles are not available



634 **Specific considerations on treatment of fusariosis in children**

635 **Evidence** – As in adults, *Fusarium* spp. can cause severe disseminated disease in children, which are asso-
 636 ciated with high mortality. To date, data in the pediatric setting are very limited and based on single cases
 637 or small case series, including in patients with burns^{44,60,417,418}.
 638 Most immunocompromised children received either VCZ monotherapy or as part of combination therapy,
 639 which included any AmB formulation or an echinocandin. The limited data suggest that children receiving
 640 VCZ have better outcomes than those not receiving VCZ (cure rate 40/55 vs. 9/26). Similarly, in the seven
 641 case reports on salvage therapy, children receiving VCZ seemed to have a benefit (**Table 7**). Surgical deb-
 642 ridement can be an essential adjunctive treatment for localized infections.

643 **Table 7. Therapy in children for *Fusarium* spp. infections**

Population	Intention	Intervention	SoR	QoE	Reference	Comment
First-line antifungal therapy						
Hematological malignancy	To cure	AmB + 5-FC	C	III	Richardson RID 1988 ⁴¹⁹	N=1, 7 yrs, failure
Hematological malignancy	To cure	L-AmB 1.5 mg/kg qd + ICZ 2.5 mg/kg qd po	C	III	Hsu PIDJ 1994 ⁴²⁰	N=1, 3 mo, failure
Hematological malignancy	To cure	D-AmB	D	III	Schwartz JPIDS 2015 ²⁶³	N=2, 9 yrs, 8 yrs, failure
					Litvinov CMI 2015 ⁴¹⁷	N=2, 6yrs, 9 yrs, failure
					Albisetti Infection 2004 ⁴²¹	N=1, 2 yrs, success
					Alvarez-Franco PedDermatol 1992 ⁴²²	N=1, 18 yrs, failure
					Ammari CID 1993 ⁴²³	N=1, 13 yrs, success
					Repiso PedDermatol 1996 ⁴²⁴	N=1, 7 yrs, success
Hematological malignancy	To cure	VCZ 4 mg/kg bid or 200 mg bid + D-AmB 1 mg/kg qd	C	III	Litvinov CMI 2015 ⁴¹⁷	N=3, 10 mo-16 yrs, response 1/3
Hematological malignancy	To cure	VCZ + AmB lipid formulation	A	III	Hassler PIDJ 2017 ⁴¹⁸	N=5, 0-13 yrs, success, granulocyte transfusions +/- G-CSF in 3/5
					Seban CNM 2017 ⁴²⁵	N=1, 12 yrs, localized infection, success
					Litvinov CMI 2015 ⁴¹⁷	N=4, 8-16 yrs, response 1/4
					Arnoni Mycopathol 2018 ⁶⁰	N=3, 6-11 yrs, response 2/3
					Uemura PIDJ 2018 ²⁹⁸	N=1, 10 yrs, failure, L-AmB 6 mg/kg
					Silva Mycopathol 2013 ⁴²⁶	N=1, 15 yrs, failure
					Schwartz JPIDS 2013 ²⁶³	N=1, 3 yrs, success
					Schwartz JPIDS 2013 ²⁶³	N=1, 15 yrs, failure
Schwartz JPIDS 2013 ²⁶³	N=1, 1 yr, failure					
Hematological malignancy	To cure	VCZ + echinocandin	C	III	Hassler PIDJ 2017 ⁴¹⁸	N=3, 8-10 yrs, response 1/3
					Litvinov CMI 2015 ⁴²⁷	N=1, 17 yrs, success
Hematological malignancy	To cure	VCZ	A	III	Carlesse AMRIC 2017 ⁴²⁸	N=6, 1-8 yrs, success 6/6
					Hassler PIDJ 2017 ⁴¹⁸	N=2, 3 yrs, 7 yrs, failure 2/2
					Vallerini Infect 2017 ⁴²⁹	N=1, 12 yrs, success
					Arnoni Mycopathol 2018 ⁶⁰	N=1, 9 yrs, success
					Sidhu IJPM 2013 ²⁷⁸	N=1, 12 yrs, survived
Hematological malignancy	To cure	L-AmB	C	III	Carlesse AMRIC 2017 ⁴²⁸	N=1, 9 mo, success
					Vagace BMC ID 2007 ⁴³⁰	N=1, 11 yrs, failure
					Tezcan JCM 2009 ²⁹⁶	N=1, 12 yrs, failure
					Cesaro Mycoses 2010 ⁴³¹	N=1, 8 yrs, failure
					Hol BMT 2014 ⁴³²	N=1, 1 yr, success
					Morel PedDermatol 2013 ⁴³³	N=1, 13 yrs, failure
					Rodriguez BMT 2003 ⁴³⁴	N=1, 3 yrs, success

					Kivivuori EJP 2004 ⁴³⁵	N=2, 5 yrs, 8 yrs, failure 2/2
					Guzman-Cottrill PID 2004 ⁴³⁶	N=1, 3 mo, failure
Hematological malignancy with endophthalmitis	To cure	ABCD 5 mg/kg tid + VCZ intravitreal 100 µg/0.1 ml	C	III	Kah BMCO 2011 ⁴³⁷	N=1, 9 yrs, success
Chronic granulomatous disease	To cure	D-AmB + ketoconazole 150 mg qd	C	III	Bassiri-Jahromi MedMycol 2012 ⁴³⁸	N=1, 15 yrs, success
Chronic granulomatous disease	To cure	VCZ	C	III	Bassiri-Jahromi MedMycol 2012 ⁴³⁸	N=1, 12 yrs, success
Burn	To cure	Voriconazole + amphotericin B deoxycholate + surgical intervention	C	III	Rosanova BJID 2016 ²⁵⁹	N=15 (mean age: 2 yrs; range 1-9 yrs) success 14, failure 1
Burn	To cure	AmB	C	III	Schaal Burns 2015 ²⁶⁷	N=1, 2 yrs, success
Burn	To cure	VCZ	C	III	Muhammed Medicine 2013 ¹⁸	N=3, 4-17 yrs, success 3/3
Burn	To cure	L-AmB, VCZ	C	III	Muhammed Medicine 2013 ¹⁸	N=1, 8 yrs, success
Burn	To cure	L-AmB, MICA	C	III	Muhammed Medicine 2013 ¹⁸	N=1, 4 yrs, failure
Burn	To cure	L-AmB	C	III	Muhammed Medicine 2013 ¹⁸	N=1, 15 yrs, success
Antifungal salvage treatment						
Hematological malignancy	To cure	L-AmB 5-9 mg/kg qd + CASPO 70 mg/m ² qd loading on d1, 50 mg/m ² qd from d2	C	III	Uemura PIDJ 2018 ²⁹⁸	N=1, 10 yrs, ALL, L-AmB (9 mg/kg qd) + CASPO (70 mg/m ² qd as loading dose followed by 50 mg/m ² qd), <i>F. keratoplasticum</i> cultured, success
					Vagace BMCID 2007 ⁴³⁰	N=1, 11 yrs, ALL, L-AmB (5 mg/kg qd) + CASPO, treatment success
Hematological malignancy	To cure	VCZ + CASPO	C	III	Cesaro Mycoses 2010 ⁴³¹	N=1, 8 yrs, ALL, success
Hematological malignancy	To cure	VCZ	C	III	Tezcan JCM 2009 ²⁹⁶	N=1, 12 yrs, HSCT, success
Hematological malignancy	To cure	L-AmB 10 mg/kg qd + VCZ start 4 d after L-AmB	C	III	Rodriguez BMT 2003 ⁴³⁴	N=1, 3 yrs, aplastic anemia, success
					Guzman-Cottrill PIDJ 2004 ⁴³⁶	N=1, 3 mo, L-AmB (10 mg/kg qd) + VCZ (6 mg/kg dose loading dose followed by 4 mg/kg dose) + granulocyte transfusion; AML, success
Hematological malignancy	To cure	AmB + 5-FC	C	III	Richardson RID1988 ⁴¹⁹	N=1, 7 yrs, ALL, failure
Standard pediatric dose unless stated otherwise; 5-FC, 5-fluorocytosine; ABCD, amphotericin B colloidal dispersion; ALL, acute lymphocytic leukemia; AmB, amphotericin B; AML, acute myeloid leukemia; bid, twice a day; CASPO, caspofungin; D-AmB, amphotericin B deoxycholate; d, day(s); FCZ, fluconazole; G-CSF, granulocyte colony-stimulating factor; HLH, hemophagocytic lymphohistiocytosis; HSCT, hematopoietic stem cell transplantation; JMML, Juvenile myelomonocytic leukemia; L-AmB, liposomal amphotericin B; MICA, micafungin; mo, month(s); po, orally; qd, once a day; QoE, quality of evidence; SoR, strength of recommendation; tid, three times a day, TRB, terbinafine; VCZ, voriconazole; yrs, years.						

644

645 **Recommendations** – First-line treatment with VCZ monotherapy or combination therapy with VCZ and a

646 lipid formulation of AmB is strongly recommended. Monotherapy with L-AmB is marginally supported;

647 monotherapy with D-AmB is discouraged. Combination therapy with VCZ plus high-dose L-AmB or an echi-

648 nocandin is recommended as salvage therapy with marginal strength. In line with recommendations in

649 adults, surgical debridement is strongly recommended for localized infections.

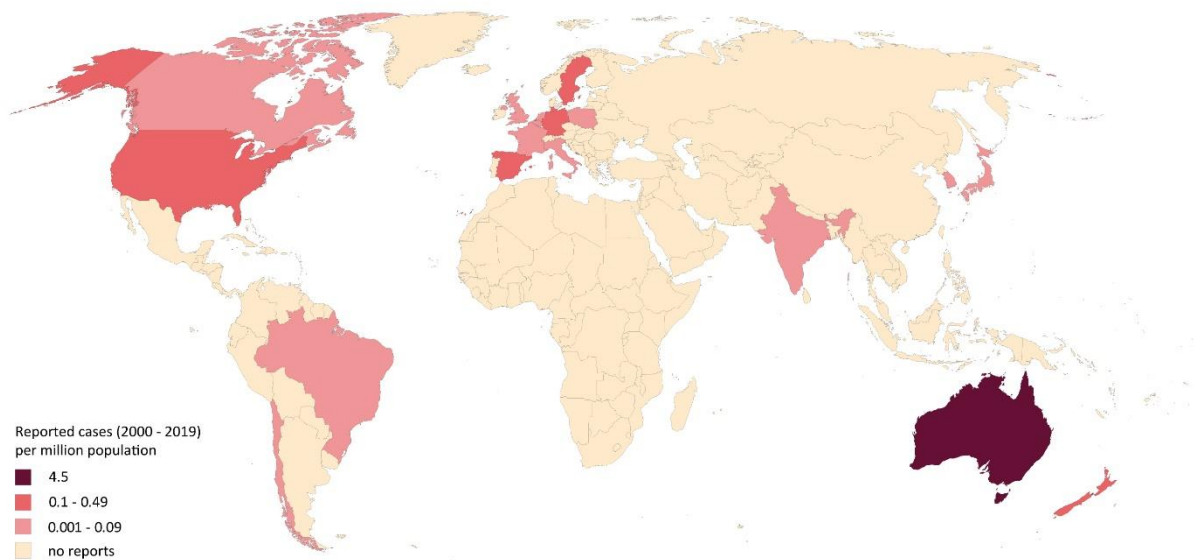
650

651 2. Lomentosporiosis

652 Epidemiology of lomentosporiosis

653 Based on phylogenetic profiling, *Lomentospora prolificans* is now distinguished from *Scedosporium*
654 spp.⁴³⁹. *L. prolificans* is ubiquitously found as a soil saprophyte predominately in arid climates of Australia,
655 south-western US and Spain, reflected by the proportionally higher number of reported cases from these
656 regions^{9,440,441}. Prevalence and incidence data for lomentosporiosis are largely unknown. In a US study, *L.*
657 *prolificans* accounted for 2% of mold infections and 6% of non-*Aspergillus* infections identified in liver and
658 heart transplant recipients⁴⁴². In France, four cases in hematological patients have been reported within
659 6 years⁴⁴³. Another study in the US reported 0.2 lomentosporiosis cases per 100,000 inpatient days in
660 hematological patients (4 patients between 1989 and 2006)⁴⁴⁴. Immunocompromised patients treated for
661 hematological malignancy and those undergoing HSCT or SOT are at highest risk for lomentosporiosis^{11,445}.
662 In more than 80% of hematological patients, *L. prolificans* causes disseminated disease, mostly with fun-
663 gemia, which is associated with a particularly dire outcome^{11,446}. Endocarditis and brain infections are
664 commonly seen in disseminated disease. The risk of dissemination in HSCT and SOT patients depends on
665 the type of transplantation and immunosuppressive regimen⁴⁴⁷. In one review, only 34 of 162 patients
666 (21%) were noted to have no underlying disease⁴⁴¹. Infections after direct inoculation via surgical wounds
667 or after traumatic injuries may also disseminate to non-contiguous organs^{11,440,444,445,448-456} (**Figure 7**).

668 **Figure 7. Worldwide distribution of lomentosporiosis (reported cases between 2000 and 2019 per mil-**
669 **lion population)**



670
671 Cases of *Lomentospora*-related infections reported in the medical literature were identified in a PubMed
672 search on November 15, 2019 using the search string “*Scedospori** OR *Pseudallescheri** OR *Lomen-*
673 *tospori**” that yielded 1,628 publications. In total, 233 cases were identified from 18 coun-
674 tries^{11,162,173,440,443,444,446,456-540}. The vast majority of cases were reported from Australia (n=108), the United
675 States (n=53), followed by Spain (n=20), Germany (n=15), and Japan (n=12). Australia reported ~8-times
676 more lomentosporiosis cases per million population than the average number of all countries. The num-
677 ber of cases reported between 2000 and 2019 is presented as cases per million population per country.
678 The resident population per country was obtained from www.worldometers.info³²¹.

679
680 **Diagnosis of lomentosporiosis**
681 ***Diagnosis – Microbiology – Conventional methods***
682 **Evidence** – The definitive diagnosis of *L. prolificans* infection relies on isolation of the fungus from biop-
683 sies, sterile body fluids and blood cultures^{13,495,516,541,542}. For respiratory tract samples of patients with
684 cystic fibrosis (CF), a special selective medium (SceSel+) has shown improved rates of isolation as it inhibits

685 the overgrowth by aspergilli⁵⁴³⁻⁵⁴⁵. Other selective fungal culture media that have been successfully used
686 are the inhibitory mold agar (IMA), and brain heart infusion (BHI) agar⁵⁴⁶. If all three are not available,
687 specimens can be cultured on sabouraud dextrose agar (SDA), or horse blood agar at 30°C or 37°C^{468,469}.
688 In contrast to *Scedosporium*, *L. prolificans* is not capable to grow in the presence of cycloheximide⁴⁴⁵.
689 Species identification is achieved by identification by macroscopic and microscopic examination of the
690 colonies. *L. prolificans* is usually characterized by the black color of its colonies, and its characteristic flask-
691 shaped and annellated conidiogenous cells (**Table 8**), but identification should be confirmed by subse-
692 quent ITS gene sequencing⁴⁴⁵. In direct microscopy *L. prolificans* may form pigmented hyphae in infected
693 tissue sections, the organism is therefore classified as a cause of phaeohyphomycosis^{13,541}.

694 **Recommendations** – The guideline group strongly recommends obtaining infected tissue and body fluids
695 for histological evaluation and culture. For respiratory tract samples from CF patients, the guideline group
696 strongly supports the usage of SceScel+, IMA or BHI media.

697

698 ***Diagnosis – Microbiology – Serology***

699 **Evidence** – Standardized commercial serological tests for the detection of *L. prolificans* are lacking⁵⁴⁷. Heat
700 shock protein 70 and 90, enolase and immunomes (conidial and hyphal proteins/enzymes) reacting with
701 human IgA have been identified in sera as candidate antigens for serodiagnostic tests⁵⁴⁸⁻⁵⁵⁰ (**Table 8**).

702 **Recommendations** – There is currently no commercial serological test, and in-house tests are only mar-
703 ginally recommended.

704

705 ***Diagnosis – Microbiology – Molecular-based***

706 **Evidence** – Standardized commercial PCR assays are lacking for the diagnosis of *L. prolificans* infection.
707 Various assay formats (oligoarray, multiplex PCR, PCR+reverse line blot hybridization, multiplex+microar-
708 ray, pan-fungal PCR + ITS sequencing, and multiplex tandem PCR) have been published from different
709 groups in the field mainly based on the ITS region^{337,338,341,344,551-554} **(Table 8)**.

710 **Recommendations** – Based on case reports, the use of broad-range PCR with subsequent hybridization
711 or microarray ID is marginally supported as no standardized commercial assay is available.

712

713 **Diagnosis – Microbiology – Species identification**

714 **Evidence** – Based on positive cultures, accurate species identification is mainly achieved by morphological
715 identification or ITS sequencing^{440,484,495,555-557}. On autopsy material broad-range PCR and subsequent hy-
716 bridization or microarray identification is used^{531,558}. MALDI-TOF MS also may identify *L. prolificans* from
717 culture extract³²⁷ **(Table 8)**.

718 **Recommendations** – The guideline group strongly supports obtaining pure cultures for species identifica-
719 tion via morphological characteristics, MALDI-TOF MS or ITS sequencing. Also, establishing a diagnosis
720 based on autopsy samples by culture and histopathology/ITS sequencing is strongly recommended.

721

722 **Microbiology – susceptibility testing**

723 **Evidence** – *L. prolificans* is a highly drug resistant fungus, sometimes even showing high MIC values for all
724 antifungal agents tested [AmB, itraconazole (ICZ), VCZ, PCZ, TRB, caspofungin (CASPO), micafungin (MICA
725), and anidulafungin (ANID)], although occasionally lower MICs are observed against VCZ, sometimes PCZ
726 and rarely for more antifungal classes^{9,151,469,559,560}. Similar results were found using CLSI⁵⁶¹, EUCAST⁵⁵⁹ and
727 Sensititre® YeastOne® YO10 panel (Trek Diagnostic Systems Ltd.) methods^{151,560} **(Table 8)**.

728 **Recommendations** – The guideline group strongly recommends susceptibility testing of *L. prolificans* to
 729 inform susceptibility patterns for epidemiological purposes and moderately for clinical decision making,
 730 despite the fact that clinical breakpoints are not available.

731

732 **Diagnosis - Pathology**

733 **Evidence** – Histological findings include mostly hyaline hyphae, although the cultures can be dark and
 734 hyphae may appear melanized in direct microscopy after KOH treatment, which may be in contrast to
 735 *Scedosporium* spp., *Aspergillus* spp., and *Fusarium* spp., which have hyaline hyphae⁴⁴⁵. Calcufluor white
 736 staining can provide better sensitivity than KOH. In general, however, *Lomentospora* hyphae may not dif-
 737 fer markedly from those of *Scedosporium* spp. Other typical features of *L. prolificans* include irregular
 738 branching patterns and adventitious conidiation in tissue. In contrast, other common hyalohyphomycotic
 739 molds usually present with regular hyphal septation, and dichotomous branching (**Table 8**).

740 **Recommendations** – The guideline group strongly recommends histopathological examination of biopsy
 741 tissue in cases of suspected infection.

742 **Diagnosis – Imaging**

743 **Evidence** – *L. prolificans* may cause CNS disease, usually during disseminated infection^{495,510,536,562,563}. Case
 744 reports have outlined imaging procedures for brain, sinuses, lung, abdomen, heart, bones, and dissemi-
 745 nated infections^{411,446,479,495,510,529,536,562-568}. As with other invasive fungal infections, imaging is important
 746 to detect and localize *L. prolificans* infection and guide microbiological sampling of infected tissue and/or
 747 body fluids (**Table 8**).

748 **Table 8. Microbiological, histopathological and imaging diagnostics of *Lomentospora* spp. infections**

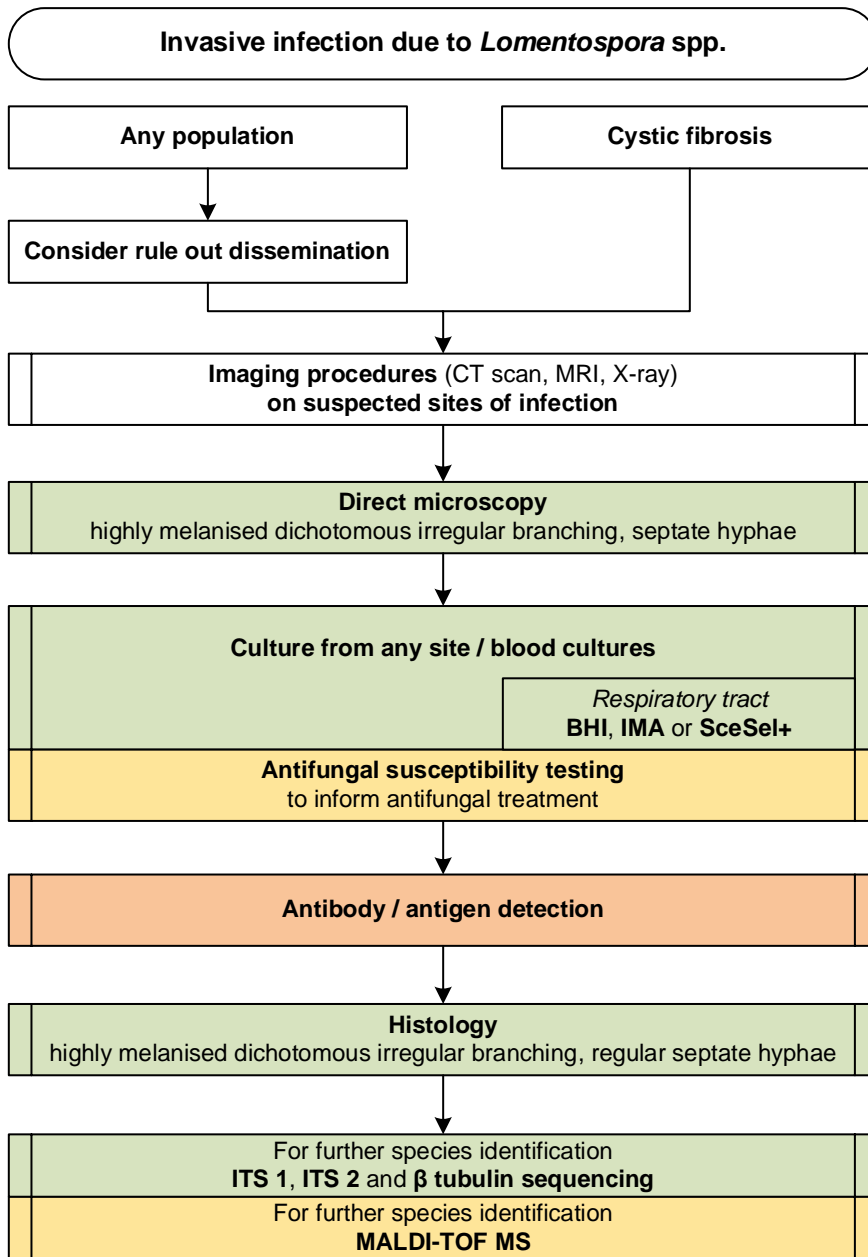
Population	Intention	Intervention	SoR	QoE	Reference	Comment
Microscopy, culture, MIC testing						
Any	To diagnose	Direct microscopy	A	III	Tortorano CMI 2014 ¹³ Cortez CMR 2008 ⁵⁴¹	
Any	To diagnose and identify species	Culture from blood, species identification by morphological characteristics or ITS sequencing	A	III	Tortorano CMI 2014 ¹³ Cortez CMR 2008 ⁵⁴¹ Lackner Mycoses 2011 ⁵⁴² Kelly BMCID 2016 ⁴⁹⁵ Penteado TID 2018 ⁵¹⁶	N=1

Any	To diagnose	Specimen culture, SDA +/- cycloheximide to differentiate from <i>Scedosporium</i>	A	II	Cobo MedMycol 2017 ⁴⁶⁸	N=7	
CF	To diagnose	Culture of respiratory samples; Use SceSel+ selective medium or Inhibitory mold agar or brain heart infusion agar.	A	III	Horre Mycoses 2011 ⁵⁴⁵	SceSel medium better than Mycosel, Sabouraud agar, combination SceSel + Sabouraud best	
					Blyth JCM 2010 ⁵⁴⁴		
					Hong JCM 2017 ⁵⁴⁶		Inhibitory mold agar or brain heart infusion agar.
					Sedlacek JCF 2015 ⁵⁴³		>11600 samples, SceSel+ better than standard media. 150 samples, <i>Scedosporium</i> recovered on SceSel+, Mycosel, and SDA from 91%, 50%, and 47%
Hematology	To diagnose	Culture of respiratory sample, blood, tissue onto SDA and horse blood agar (30° and 37°C)	A	IIu	Cooley EID 2007 ⁴⁶⁹	N=28	
Any	To inform susceptibility patterns and treatment modalities	CLSI method	A	IIu	Jens IJAA 2018 ³⁸⁴	6/7 isolates with MICs > 16 µg/mL against VCZ and/or PCZ	
Any	To inform susceptibility patterns and treatment modalities	EUCAST microdilution method	A	IIu	Alastruey-Izquierdo AAC 2018 ⁵⁵⁹	<i>L. prolificans</i> is panresistant	
Any	To inform susceptibility patterns	Sensititre® YeastOne® YO10 panels (Trek Diagnostic Systems Ltd.) to test susceptibility	A	III	Halliday IJAA 2016 ¹⁵¹	N=4 isolates, MIC ≥4 mg/L for AmB and echinocandins; ≥8 mg/L for FCZ, ICZ and PCZ; and ≥1 mg/L for VCZ	
Any	To guide antifungal treatment	Susceptibility testing with microdilution EUCAST or CLSI method	B	III	Alastruey-Izquierdo AAC 2018 ⁵⁵⁹	No clinical breakpoints available	
Serology assays							
CF or immunocompromise	To diagnose	Antibody detection (Heat shock proteins 70/90, and enolase)	C	III	Pellon JPR 2016 ⁵⁴⁸ Buldain Vaccines 2019 ⁵⁵⁰		
Oncology	To diagnose and identify	Blood cultures, potato dextrose agar	A	III	Kelly BMCID 2016 ⁴⁹⁵		
Any	To diagnose and identify	Culture and histopathology	A	III	Holmes MMCR 2013 ⁴⁸⁴	N=1	
					Guadalajara JCN 2018 ⁵⁶⁹	N=1	
All	To identify candidate antigens	Antibody and antigen detection	C	IIII	Pellon FungalBiol 2014 ⁵⁴⁹		
Nucleic-acid based assays							
Hematology/oncology/ ICU/trauma	To diagnose	Multifungal DNA microarray	C	III	Boch Mycoses 2015 ³³⁷		
Any	To diagnose	Panfungal PCR (ITS1 target) + sequencing on fresh tissues or FFPE	C	III	Lau JCM 2007 ³⁴¹		
Neutropenic patients	To diagnose	Multiplex PCR + DNA microarray hybridization	C	III	Spiess JCM 2007 ³⁴⁴		
Any	To diagnose	Multiplex tandem PCR on blood cultures	C	III	Lau JCM 2008 ³³⁸		
CF	To diagnose from sputum	Oligoarray, ITS2	C	III	Bouchara JCM 2009 ⁵⁵¹	20 isolates, sens. 100% and spec. 99.2%	
CF	To diagnose from sputum	Multiplex PCR, ITS	C	III	Harun JCM 2011 ⁵⁵²	Sens 70%, spec. 99%	
CF	To diagnose from sputum	Reverse line blot hybridization after group-specific PCR	C	III	Lu Mycoses 2011 ⁵⁵⁴	<i>L. prolificans</i> in 2/52 CF patients	
Any with meningitis	To diagnose and identify	Culture, broad-range PCR, not specified further	C	III	Tamaki TID 2016 ⁵³¹		
Any	To identify	Culture and ITS sequencing	A	III	Heath CMI 2009 ⁴⁴⁰	N=49 isolates	
					Ziesing MedMycol 2016 ⁵⁵⁵	<i>L. prolificans</i>	
					Wangchinda MMCR 2018 ⁵⁵⁶		
					Penteado TID 2018 ⁵¹⁶	N=1	
					Elizondo-Zertuche Mycopathol 2017 ⁵⁵⁷	N=11	
Any	To identify	MALDI-TOF MS	B	III	Sitterle CMI 2014 ⁵⁷⁰		
CF	To identify	ITS sequencing/ microarray	C	III	Schwarz PIOSOne 2017 ⁵⁵⁸	N=2	
Tissue-based diagnosis							

Any	To diagnose	Histopathology of biopsies using e.g. KOH treatment or Calcufluor white stain	A	III	Ramirez-Garcia MedMycol 2018 ⁴⁴⁵ Kimura PatholInt 2010 ⁵⁷¹	<i>L. prolificans</i> may be melanised, unlike many other hyphomycetes. <i>Lomentospora</i> and <i>Scedosporium</i> may branch irregularly. Intravascular and intratissue conidiation
Imaging studies						
Any with brain lesions / abscesses	To assess clinical manifestations and imaging characteristics	CT scan of the brain	B	III	Berenguer Medicine 1997 ⁵⁶²	N=3
Any with brain lesions / abscesses	To assess clinical manifestations and imaging characteristics	MRI of the brain	A	III	Kelly BMCID 2016 ⁴⁹⁵	N=1
Any with sinusitis	To assess clinical manifestations and imaging characteristics	CT scan of the sinuses	A	III	Ochi IJH 2015 ⁵¹⁰	N=1
Any with pneumonia	To assess clinical manifestations and imaging characteristics	Chest radiography	C	III	Berenguer Medicine 1997 ⁵⁶²	N=12
					Maertens AnnHematol 2000 ⁴⁴⁶	N=1
					Salesa SJID 1993 ⁵⁶⁶	N=1
					Uno JIC 2014 ⁵³⁶	N=1
					Pickles JInfect 1996 ⁵⁶⁷	N=1
					Idigoras CID 2001 ⁵⁶⁸	N=6, disseminated
Any with pneumonia	To assess clinical manifestations and imaging characteristics	CT scan of the lungs	A	III	Berenguer Medicine 1997 ⁵⁶²	N=2
					Maertens AnnHematol 2000 ⁴⁴⁶	N=1
					Uno JIC 2014 ⁵³⁶	N=1
					Ochi IJH 2015 ⁵¹⁰	N=1
					Bouza CID 1996 ⁵⁶⁵	N=1
Any with abdominal / lymph node infection	To assess clinical manifestations and imaging characteristics	CT scan of the abdomen	A	III	Ochi IJH 2015 ⁵¹⁰	N=1
Any with bone infection	To assess clinical manifestations and imaging characteristics	Bone radiography	C	III	Gosbell Mycoses 2003 ⁴⁷⁹	N=1
					Taj-Aldeen Medicine 2015 ⁵⁶⁴	N=23
					Pickles JInfect 1996 ⁵⁶⁷	N=1
Any with bone infection	To assess clinical manifestations and imaging characteristics	CT scan of spine / bones	A	III	Gosbell Mycoses 2003 ⁴⁷⁹	N=1
					Koehler CRM 2016 ⁴¹¹	
Any with bone infection	To assess clinical manifestations and imaging characteristics	MRI of spine / bones	A	III	Gosbell Mycoses 2003 ⁴⁷⁹	N=1
					Taj-Aldeen Medicine 2015 ⁵⁶⁴	N=23
					Koehler CRM 2016 ⁴¹¹	
					Steinbach JCM 2003 ⁵²⁹	N=1
Any with dissemination	To assess clinical manifestations and imaging characteristics	PET/CT	B	III	Kelly BMCID 2016 ⁴⁹⁵	N=1
Any with endocarditis	To assess clinical manifestations and imaging characteristics	Echocardiogram (preferably transesophageal)	A	III	Uno JIC 2014 ⁵³⁶	N=1
					Kelly BMCID 2016 ⁴⁹⁵	N=1
					Wakabayashi IntMed 2016 ⁵³⁸	N=1
AmB, amphotericin B; CF, cystic fibrosis; CLSI, Clinical and Laboratory Standards Institute; CT, computed tomography; DNA, deoxyribonucleic acid; EUCAST, European Committee for Antimicrobial Susceptibility Testing; FCZ, fluconazole; FFPE, formalin-fixed paraffin-embedded; HSCT, hematopoietic stem cell transplantation; Hsp, heat shock proteins; ICZ, itraconazole; IgA, immunoglobulin A; ITS, internal transcribed spacer; KOH, potassium hydroxide; MALDI-TOF MS, matrix assisted laser desorption ionization-time of flight mass spectrometry; MIC, minimal inhibitory concentration; MRI, magnetic resonance imaging; PET, positron emission tomography; PCR, polymerase chain reaction; PCZ, posaconazole; QoE, quality of evidence; SceSel+, <i>Scedosporium</i> -selective medium; SDA, Sabouraud dextrose agar; SoR, strength of recommendation; VCZ, voriconazole.						

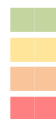
750 **Recommendations** – For the detection and localization of lomentosporiosis and imaging-guided sampling
751 of biopsies and body fluids, the guideline group strongly recommends magnetic resonance imaging (MRI)
752 and CT scan for bones, MRI scan for the brain, transesophageal echocardiogram for the heart, and CT scan
753 of the sinuses, lungs, and abdomen, based on suspected site of infection. The guideline group moderately
754 supports the usage of positron emission tomography (PET) scan for disseminated lomentosporiosis and
755 CT of the brain. Conventional radiography of the bones and the chest is marginally supported (**Figure 8**).

756 **Figure 8. Optimal diagnostic pathway for lomentosporiosis, when all imaging and assay techniques are**
 757 **available**



Legend:

- strongly recommended
- moderately recommended
- marginally recommended
- recommended against



BHI, brain heart infusion agar; CT, computed tomography; IMA, inhibitory mold agar; ITS, internal transcribed spacer; MALDI-TOF MS, matrix-assisted laser desorption/ionization time-of-flight mass spectrometry; MRI, magnetic resonance imaging

759 **Treatment approaches to lomentosporiosis**

760 Treatment in adults

761 **First-line antifungal monotherapy**

762 **Evidence** – *L. prolificans* appears to be intrinsically resistant to most antifungals^{572,573}, with VCZ showing
 763 the best *in vitro* activity against this fungus⁵⁷³. In several case series, the use of VCZ monotherapy led to
 764 the successful treatment of invasive lomentosporiosis in patients with various organ involvement pat-
 765 terns^{367,447,468,574}, with successful outcomes varying by case series between 25% to 66%. In two case series,
 766 outcome with AmB monotherapy was inferior to VCZ monotherapy, with survival in 2/13 patients receiv-
 767 ing AmB monotherapy in one case series⁴⁴⁷ and 0/4 patients successfully treated in another case series³⁶⁷.
 768 ISA monotherapy was effective in one case report in a patient with interstitial pulmonary disease⁴⁰⁷ and
 769 miltefosine was effective in a patient with disseminated lomentosporiosis and an azole drug-drug inter-
 770 action⁵³⁵ (**Table 9**).

771 **Table 9. First-line antifungal therapy for *Lomentospora spp.* infections**

Population	Intention	Intervention	SoR	QoE	Reference	Comment
Any	To cure	VCZ iv + TRB +/- other antifungals	A	Ilu	Jenks CMI 2020 ⁵⁷⁵	N=40, VCZ + TRB combination (+/- other antifungals) 10/16 (63%) success, other treatments 7/24 (29%) success
					Seidel CRM 2019 ¹¹	N=56, mortality with VCZ 52.6% vs. therapy w/o VCZ 68.8%, mortality with VCZ mono 50% or in combination 55.3%
					Jenks IJAA 2018 ³⁸⁴	N=6, VCZ + TRB 3/3 survived vs. VCZ or L-AmB 0/3 survived
					Wangchinda MMCR 2018 ⁵⁵⁶	N=1
Any	To cure	VCZ + either L-AmB OR MICA	B	III	Jenks IJAA 2018 ³⁸⁴	N=2, 1/2 survived
					Jenks CID 2020 ⁵⁷⁵	N=8, response 2/8 (25%)
					Seidel CRM 2019 ¹¹	N=17 7/17 (41%) survived
					Tamaki TID 2016 ⁵³¹	N=1, failure
Any	To cure	VCZ iv bid	B	Ilu	Cobo MedMycol 2017 ⁴⁶⁸	N=5, success 2/4
					Troke AAC 2008 ⁵⁷⁴	N=36, success 16/36 (44%)
					Hussain CID 2005 ⁴⁴⁷	N=18, VCZ 2/3 survived vs. AmB 2/13 survived
					Jenks CID 2020 ⁵⁷⁵	N=7, success 3/7; breakthrough lomentosporiosis in N=6 with VCZ prophylaxis
Any	To cure	L-AmB	D	III	Jenks CID 2020 ⁵⁷⁵	N=15, L-AmB mono 0/4 success vs. L-AmB combination 3/11 success
Interstitial pulmonary disease	To cure	ISA	C	III	Marty Mycoses 2018 ⁴⁰⁷	N=1, success
Hematological malignancy patients	To cure	VCZ + TRB	A	III	Cooley EID 2007 ⁴⁶⁹	N=7, VCZ plus TRB 2/4 survived vs. ICZ plus TRB or AmB 0/3 survived
CF with lung infection	To cure	VCZ + either MICA iv, TRB po OR AmB inhaled	C	III	Schwarz JCF 2018 ⁴⁵⁶	N=3, achieved improvement but no eradication

Standard dose unless stated otherwise; AmB, amphotericin B; bid, twice a day; d, day(s); FEV1, forced expiratory volume in one second; HSCT, hematopoietic stem cell transplantation; ICZ, itraconazole; ISA, isavuconazole; iv, intravenous; L-AmB, liposomal amphotericin B; MICA, micafungin; po, orally; qd, once a day; QoE, quality of evidence; TDM, therapeutic drug monitoring; tid, three times a day; SoR, strength of recommendation; SOT, solid organ transplants; TRB, Terbinafine; VCZ, voriconazole.

772
773 **Recommendations** – While combination antifungal therapy is the preferred option (see next paragraph),
774 the guideline group moderately supports first-line treatment with VCZ monotherapy specifically in those
775 who are more immunocompetent and have localized infection. Given superior outcomes seen with other
776 antifungal treatment strategies, monotherapy with L-AmB is not recommended. Although treatment suc-
777 cess was reported in one case report with miltefosine monotherapy, more data are needed before rec-
778 ommending this option. There is no evidence supporting other first-line monotherapy regimens.

779 ***First-line antifungal combination therapy***

780 **Evidence** – In the largest case series of lomentosporiosis infections published to date combination anti-
781 fungal therapy was associated with increased 28-day survival (15/24 survived vs. 4/16 receiving mono-
782 therapy)³⁶⁷. *In vitro* synergism has been demonstrated with combinations of AmB plus MICA⁵⁷⁶, AmB plus
783 pentamidine⁵⁷⁷, colistin plus VCZ⁵⁷⁸ and particularly VCZ plus TRB^{572,579,580}. In several case reports and case
784 series, combination antifungal therapy successfully treated lomentosporiosis with various organ involve-
785 ment patterns and mixed underlying disease, particularly with VCZ (intravenous 6 mg twice daily loading
786 dose followed by 4 mg twice daily) plus TRB (500 mg daily), plus or minus other antifungals⁴⁸⁶. In one case
787 report, VCZ plus TRB and surgical debridement resulted in suppression of *L. prolificans* osteomyelitis in an
788 immunocompetent woman⁵⁵⁶ and in a small case series, 3/3 patients treated with VCZ plus TRB combina-
789 tion therapy survived¹⁶². In two larger case series, 8/18 (45%) individuals treated with VCZ plus TRB com-
790 bination therapy were alive at Day 42¹¹ and 10/16 (63%) who were treated with VCZ plus TRB combination
791 therapy plus or minus other antifungals were alive at Day 28 in another case series³⁶⁷; in the latter case
792 series, survival at 84 and 360 days was significantly higher in those who received VCZ plus TRB combina-
793 tion therapy plus or minus other antifungals compared to those receiving other antifungal therapies³⁶⁷.
794 Combination therapy with VCZ plus either AmB or MICA has resulted in treatment response and survival
795 in patients with mixed underlying disease in several case series^{11,162,367}, although outcomes did not differ

796 compared to those treated with VCZ plus TRB combination therapy plus or minus other antifungals. In
797 patients with hematological malignancy in one case series, 2/4 (50%) who were treated with VCZ plus TRB
798 combination therapy survived, while 0/3 survived who received ICZ plus TRB or AmB⁴⁶⁹. In a case series of
799 three patients with CF, combination therapy with VCZ plus MICA, TRB, or inhaled AmB resulted in clinical
800 improvement but not in eradication of the fungus⁴⁵⁶. Surgery as adjunct treatment has been shown to be
801 significantly associated with survival³⁶⁷. Resection of surgically amenable lesions is an important adjunct
802 to management of infections caused by *L. prolificans*⁵⁸¹. Correction of underlying immune deficiencies is
803 also an important adjunct to antifungal therapy.

804 **Recommendations** – The guideline group strongly supports first-line VCZ-based combination antifungal
805 therapy for treatment of infections caused by *L. prolificans*, particularly VCZ plus TRB plus or minus other
806 antifungal agents. Combination therapy with VCZ plus either L-AmB or MICA is moderately supported. In
807 patients with hematological malignancy, combination therapy with VCZ plus TRB plus or minus other an-
808 tifungal agents is also strongly recommended. In patients with CF, combination therapy with VCZ plus
809 MICA, TRB, or inhaled AmB is marginally supported, as available data are too limited to give stronger
810 support to this strategy. There is little evidence supporting other first-line combination therapy regimens.

811 ***Other treatment options***

812 **Evidence** – Surgery in general and surgical debridement has been associated with improved treatment
813 response^{367,441}. **(Table 10)**.

814

815 **Table 10. Other treatment options for *Lomentospora spp.* infections**

Population	Intention	Intervention	SoR	QoE	Reference	Comment
Hematopoietic stem cell transplant patients	To cure	VCZ as secondary prophylaxis	C	III	Penteado TID 2018 ⁵¹⁶	N=1, failure
Immunocompetent with localized infection	To cure	Surgical debridement	A	III	Wangchinda MMCR 2018 ⁵⁵⁶	N=1
					Masukane IntMed 2017 ⁵⁸²	N=1, success
Hematological malignancy	To cure in context azole drug-drug interactions	Miltefosine	C	III	Trubiano Mycoses 2014 ⁵³⁵	N=1, success
All	To cure	Surgery (debridement, enucleation, vitrectomy)	A	II	Rodriguez-Tudela MedMycol 2009 ⁴⁴¹	N=169, survival associated with surgery
					Jenks CMI 2020 ⁵⁷⁵	N=7, survival associated with surgery

QoE, quality of evidence; SoR, strength of recommendation, VCZ, voriconazole.

816

817 **Recommendations** – The guideline group strongly recommends the use of surgical debridement where

818 applicable.

819

820 **Antifungal salvage treatment**

821 **Evidence** – VCZ monotherapy with TDM was effective in one large case series of 36 patients when VCZ

822 was used for compassionate use or salvage therapy⁵⁷⁴. In a small case series of two patients, both VCZ

823 plus AmB plus PCZ, and TRB plus AmB plus PCZ combinations led to treatment response in both patients³⁶⁷.

824 Miltefosine was effective in one case report in a patient with disseminated *L. prolificans* infection and an

825 azole drug-drug interaction⁵³⁵ (**Table 11**).

826 **Table 11. Antifungal salvage treatment for *Lomentospora spp.* infections**

Population	Intention	Intervention	SoR	QoE	Reference	Comment
Any	To cure	VCZ + TDM	B	IIu	Troke AAC 2008 ⁵⁷⁴	N=36, 44% success
Any	To cure	PCZ + L-AmB + either VCZ OR TRB	C	III	Jenks CID 2020 ⁵⁷⁵	N=2, response 2/2

Standard dose unless stated otherwise; L-AmB, liposomal amphotericin B; PCZ, posaconazole; QoE, quality of evidence; SoR, strength of recommendation; TDM, therapeutic drug monitoring; TRB, terbinafine; VCZ, voriconazole.

827

828 **Recommendations** – Although there is limited evidence to support a specific regimen to be used as sal-

829 vage therapy for invasive lomentosporiosis, the guideline group recommends the use of combination an-

830 tifungal therapy that should be tailored based on prior antifungal treatment and to the individual patient.

831 VCZ is moderately recommended.

832 **Treatment duration of lomentosporiosis**

833 **Evidence** – Extended duration of antifungal treatment has been associated with treatment success and/or
 834 survival in multiple case reports and case series. In two case series of patients with various underlying
 835 diseases and organ involvement patterns, patients who survived received VCZ plus TRB for at least 180
 836 days³⁶⁷ and antifungal treatment for three to six months in another case series¹⁶². In one case report of
 837 an immunocompetent patient with vertebral osteomyelitis, surgical debridement plus VCZ plus TRB for
 838 180 days resulted in clinical improvement and this patient was maintained on suppressive therapy⁵³⁵. In
 839 a literature review of immunocompromised adults and children with osteomyelitis, patients were treated
 840 for a mean duration of 115 days with a treatment response in 86% of patients⁵⁶⁴. In a multi-center study
 841 of CF patients and lomentosporiosis, mean duration of combination therapy was 3.9 months (**Table 12**)⁴⁵⁶.

842 **Table 12. Treatment duration for *Lomentospora spp.* infections**

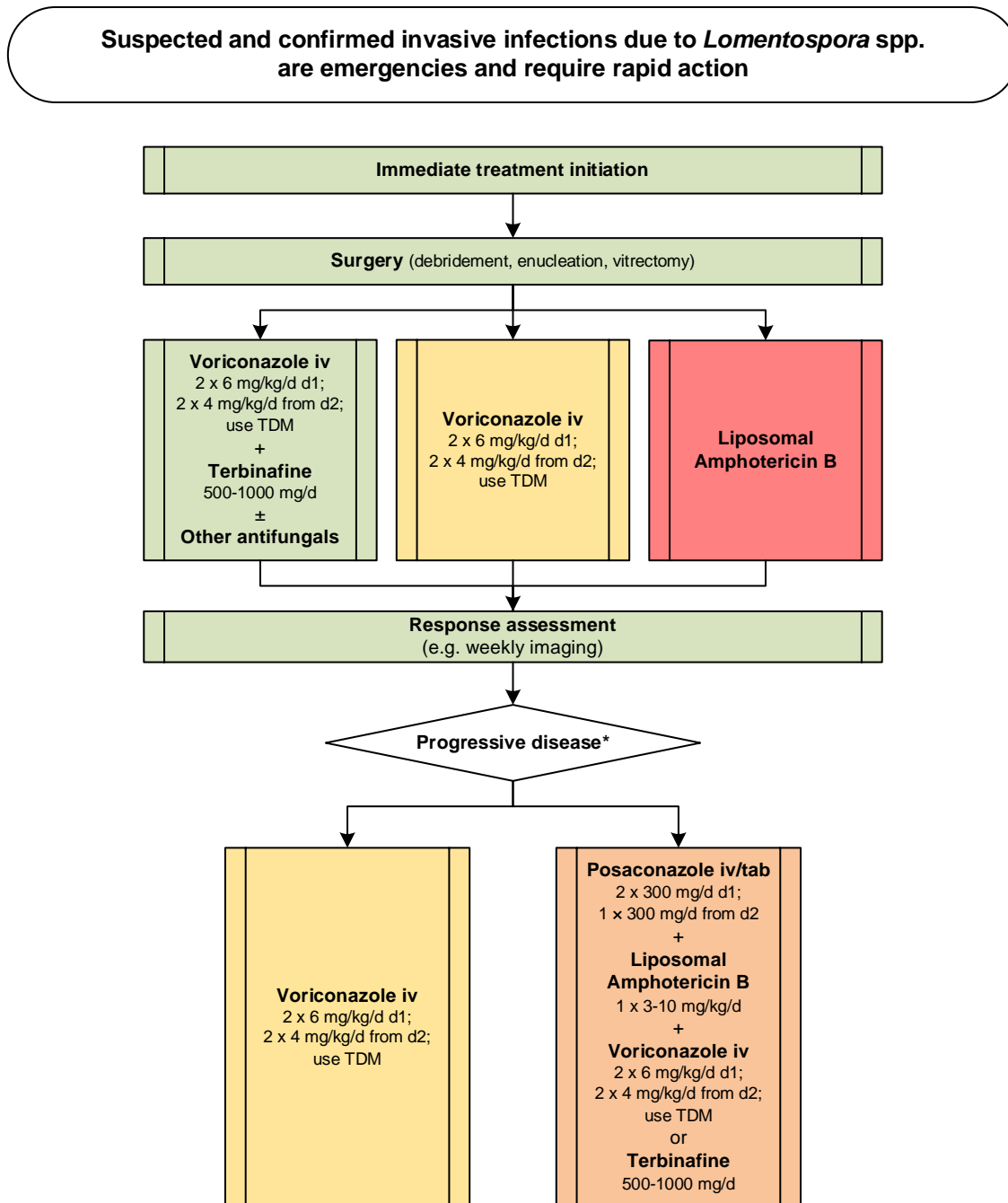
Population	Intention	Intervention	SoR	QoE	Reference	Comment
Any	To cure	181 d of therapy with VCZ + TRB	B	III	Jenks CID 2020 ⁵⁷⁵	IQR 69-332 d
Adults and pediatric immunocompromised patients with osteomyelitis	To cure	Mean duration of 115 d (5 d-730 d) of combined treatment	B	IIr	Taj-Aldeen Medicine 2015 ⁵⁶⁴	Systematic literature review
Immunocompetent with osteomyelitis	To cure	>180 d of therapy with VCZ and TRB	C	II	Wangchinda MMCR 2018 ⁵⁵⁶	Case report and literature review
CF patients	To cure	1-14 mo of therapy, mean duration 3.9 months	B	II	Schwarz JCF 2019 ⁴⁵⁶	N=31, AmB 25 mg qd by inhalation + iv + VCZ 40 mg qd by inhalation + iv
Any	To cure	3-6 mo of therapy	B	II	Jenks IJAA 2018 ³⁸⁴	N=7

Standard dose unless stated otherwise; bid, twice a day; CF, cystic fibrosis; d, days; IQR, interquartile range; iv, intravenous; mo, month(s); qd, once a day; QoE, quality of evidence; SoR, strength of recommendation; TRB, terbinafine; VCZ, voriconazole.

843

844 **Recommendations** – Extended durations of antifungal therapy have been associated with improved out-
 845 comes and survival, although no evidence exists to support a pre-specified duration of therapy. It is rea-
 846 sonable to tailor the duration of therapy to the individual patient and consider continuing antifungal ther-
 847 apy until immunological recovery and resolution of all clinical evidence of disease, if possible. A duration
 848 of at least 4 to 6 months of combination therapy has been most associated with positive outcomes and
 849 thus is moderately recommended (**Figure 9**).

850 **Figure 9. Optimal treatment pathway for lomentosporiosis in adults when all treatment modalities**
 851 **and antifungal drugs are available**



Legend:
 strongly recommended ■
 moderately recommended ■
 marginally recommended ■
 recommended against ■

TDM, therapeutic drug monitoring

* Choice of salvage treatment always depends by the treatment that the patient failed to respond to

852

853

854

855 **Specific considerations on treatment of lomentosporiosis in children**

856 **Evidence** – Published case reports and case series show poor outcomes from pneumonia and fungemia
 857 caused by *L. prolificans* in immunocompromised children^{503,516,583,584}. A larger case series of osteoarticular
 858 infections caused by non-*Aspergillus* molds showed a higher incidence of *L. prolificans* bone and joint
 859 infections in children compared to adults (35% vs 10%)⁵⁶⁴. In addition, direct inoculation was the main
 860 mechanism of infection in 73.5% in children compared to 43.5% in adults⁵⁶⁴. In a recent review of invasive
 861 *Lomentospora* (n=22) and *Scedosporium* (n=33) infections in children, surgery and VCZ treatment were
 862 associated with improved clinical outcome⁵⁸⁴ (**Table 13**).

863 **Table 13. First-line antifungal therapy for *Lomentospora spp.* infections in children**

Population	Intention	Intervention	SoR	QoE	Reference	Comment
Any	To cure	VCZ + other antifungals + surgery for localized infections	A	III	Seidel IJID 2019 ⁵⁸⁵	N=22
Neuroblastoma	To cure	AmB lipid-based formulations	C	III	Sparrow PHO 1992 ⁵⁸³	N=1, 2.6 yrs, died
Hematological malignancy	To cure	L-AmB 12 mg/kg qd	C	III	Penteado TID 2018 ⁵¹⁶ de Lucas EuRadiol 2006 ⁵⁰³	N=1, 14 yrs, failure N=1, 18 yrs, died
Any with osteoarticular infections	To cure	Surgery	B	II	Taj-Aldeen Medicine 2015 ⁵⁶⁴	N=12, mostly trauma/puncture wounds; 9/12 (75%) complete response

Standard pediatric dose unless stated otherwise; AmB, amphotericin B; ICZ, itraconazole; L-AmB, liposomal amphotericin B; qd, once a day; QoE, quality of evidence; SoR, strength of recommendation; VCZ, voriconazole; yrs, years.

864

865 **Recommendation** - Treatment recommendations follow those given for adults, with VCZ (+ TDM) being
 866 the backbone of therapy, with improved outcomes reported when combined with TRB, L-AmB or MICA
 867 (strong recommendation). Surgery plays a major role and is strongly recommended in the treatment of
 868 localized infections.

869

870 **3. Scedosporiosis**

871 **Epidemiology of scedosporiosis**

872 *Scedosporium spp.* are ubiquitous saprophytes mostly found in temperate areas, with regional differences
 873 in species distribution^{586,587}. In the clinical setting, the most commonly isolated species are *Scedosporium*
 874 *boydii* and *Scedosporium apiospermum*. *Scedosporium aurantiacum* is isolated to a lesser extent mainly

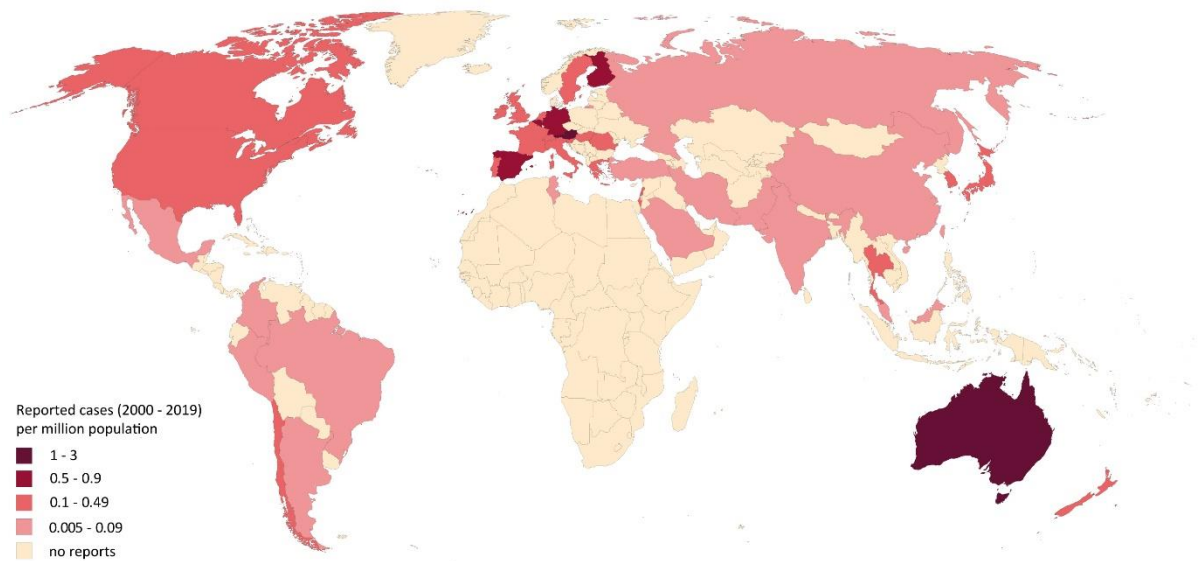
875 in Australia and Europe^{440,445,451,588-590}. Only few cases of infections caused by *Scedosporium dehoogii* have
876 been reported⁵⁹¹⁻⁵⁹⁴.

877 *Scedosporium* spp. initiates two distinct diseases: mycetoma and scedosporiosis. *Scedosporium* spp. are
878 an important cause of eumycotic mycetoma and the most common cause of this infection in the United
879 States⁵⁹⁵. *Scedosporium* mycetoma usually develops in immunocompetent patients. SOT and treatment
880 for hematological disease are major risk factors for scedosporiosis. Patients predominantly present with
881 pulmonary, cutaneous or cerebral infections^{11,445}. Secondary CNS infections may appear without an evi-
882 dent dissemination. Infection may also affect the paranasal sinuses or bones^{11,445}.

883 *Scedosporium* spp. have been recovered from respiratory secretions of patients with chronic pulmonary
884 conditions such as CF, ranking as the second most frequently isolated fungal pathogen after *Aspergillus*
885 spp.^{440,456,596}. The significance of *Scedosporium* in this setting is uncertain but may be the first step towards
886 invasive disease^{543,590}. Colonization has also been described in cancer patients⁴⁴⁴. Surgery, intravenous
887 drug injection, and repeated corticosteroid injections have also been associated with localized infections.
888 The main route of entry of the pathogen in immunocompetent patients is traumatic inoculation or aspi-
889 ration of contaminated water. Near drowning-, tsunami-, and earthquake-victims represent a high risk
890 group for developing scedosporiosis⁵⁹⁷⁻⁶⁰⁰. Near drowning has been associated with cerebral infection
891 caused by *S. apiospermum* that results from hematogenous spread from the lungs as the primary site of
892 infection⁴⁴⁸⁻⁴⁵⁵. CNS infection related to near drowning events caused by *Scedosporium* spp. may also arise
893 from penetration through the cribriform plate with direct invasion of the CNS. Eye infections after trau-
894 matic injuries are also common^{66,601-605}. Other affected body sides include the spine^{448,451,454}.

895 In a US study, *S. apiospermum* accounted for 6% of mold infections and 19% of non-*Aspergillus* infections
896 identified in liver and heart transplant recipients⁴⁴². The incidence of scedosporiosis was 0.93 per 100,000
897 patient-inpatient days, with a noted increase from 1993 to 2005 in a US cancer center⁴⁴⁴. In Australia,
898 among 137 patients who were monitored for a median of 4 years post-lung transplantation, 13 had fungal
899 infection and 3 of these were caused by *S. apiospermum*⁵⁹⁶. One percent of patients with lung transplan-
900 tation developed infections caused by *S. apiospermum*⁶⁰⁶ (**Figure 10**).

901 **Figure 10. Worldwide distribution of scedosporiosis (reported cases between 2000 and 2019 per mil-**
902 **lion population)**



903
904
905 Cases of severe *Scedosporium*-related infections reported in the medical literature were identified in a
906 PubMed search on November 15, 2019 using the search string “*Scedospori** OR *Pseudallescheri** OR *Lo-*
907 *mentospori**” that yielded 1,628 publications. In total, 541 cases were identified from 43 coun-
908 tries^{1,82,97,448-453,460,469,473,485,492,514,563,588,589,592-594,596,597,599-601,604,607-83811,300,454,456,524,585,594,598,602,603,605,831-898}.
909 Most cases were reported from the United States (n=146), Australia (n=73), Germany (n=60), India (n=58),
910 Spain (n=41), and Japan (n=28). Australia and Austria (n=10) reported most of the cases per million pop-
911 ulation. Number of cases reported between 2000 and 2019 are presented as cases per million population
912 per country. The resident population per country was obtained from www.worldometers.info³²¹.

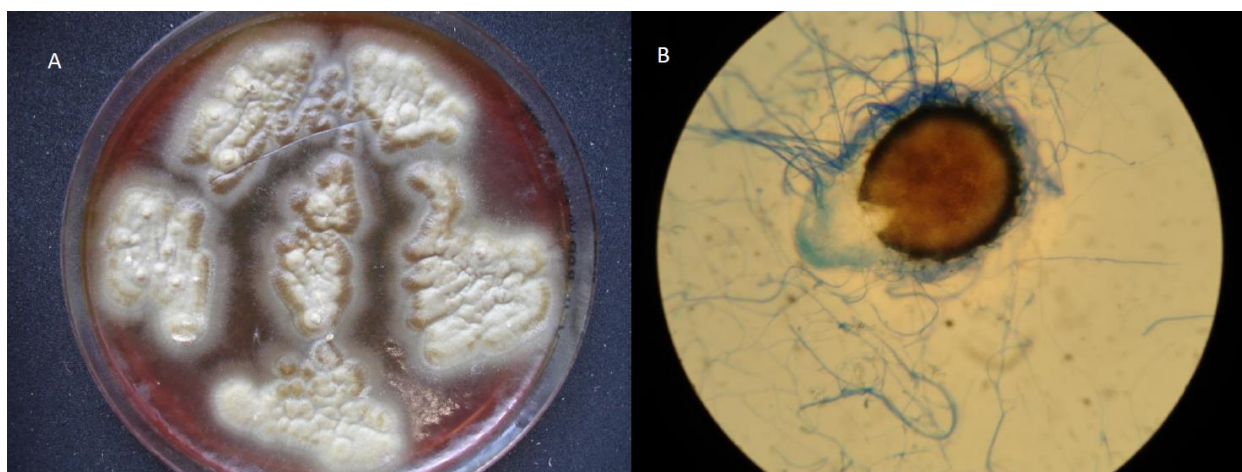913
914 **Diagnosis of Scedosporiosis**

915 ***Diagnosis – Microbiology – Conventional Methods***

916 **Evidence** – Definitive diagnosis of scedosporiosis is based on culture of the pathogen from infected tissue
917 samples and body fluids from sterile body regions or from blood^{13,495,541,542,599,671,760,846,879}. Direct micros-
918 copy and histopathology of clinical specimens is important for the diagnosis of a hyalohyphomycosis,
919 while further discrimination based on microscopy is rarely possible^{13,462,541,899}. Branching patterns of

920 *Scedosporium* spp. often resemble *Aspergillus* spp., with sometimes dichotomously branching septate hy-
921 phae seen in tissue, although branching off to the side at a 60° to 70° angle, which is different than the
922 45° angle seen with *Aspergillus* spp.. In addition, distinctive coremia or an ascocarp as well the presence
923 of pyriform adventitious conidia may indicate *Scedosporium* spp. as the mold. After a few days, the mold
924 colony takes on a tan color and has sporulating structures that differ from *Aspergillus* spp. See also **Figure**
925 **11** for microbiological characteristics.

926 **Figure 11. Microbiological characteristics of Pseudallescheria state of *S. boydii* (owned by co-author**
927 **V. Arsic-Arsenjevic)**



928
929 *Pseudallescheria* state of *S. boydii* growth on blood agar, B fully developed and ruptured cleistothecium,
930 the hallmark of the sexual stage (teleomorph) of this fungus.

931
932 Based on >11,600 respiratory tract samples from CF patients, the selective medium *Scedosporium* Selec-
933 tive agar (SceSel+) showed higher isolation rates than the standard medium⁵⁴³. Blyth *et al.* found a 90.6%
934 isolation rate for SceSel+ compared with 50% Mycosel and 46.9% for Sabouraud dextrose agar⁵⁴⁴. Other
935 selective fungal culture media that have been successfully used are the inhibitory mold agar (IMA), and
936 brain heart infusion (BHI) agar⁵⁴⁶. Species identification of cultures is achieved by subsequent ITS sequenc-
937 ing^{13,495,541,542,599,671,760,846,879} or by macroscopic and microscopic examination of the colonies (**Table 14**).

938 **Recommendations** – The guideline group strongly recommends obtaining infected tissue and body fluids
939 for histological evaluation, direct microscopy, and culture. For respiratory tract samples from CF patients,
940 the guideline group strongly supports the use of selective fungal culture media like SceScel+, IMA or BHI
941 agar. Based on pure cultures, members of the genus *Scedosporium* can rarely be identified by morphology
942 alone.

943 **Diagnosis – Microbiology – Serology**

944 **Evidence** – Standardized commercial serological tests for the detection of *Scedosporium* spp. infection
945 are lacking⁵⁴⁷. For CF patients, an ELISA test is under development that is based on the detection of my-
946 celial catalase A1 of the *S. apiospermum* complex⁹⁰⁰ (**Table 14**).

947 **Recommendations** – There is currently no commercial serological test available.

948 **Diagnosis – Microbiology – Molecular-based**

949 **Evidence** – Standardized commercial PCR assays are lacking for the diagnosis of scedosporiosis. Various
950 assay formats (oligoarray, multiplex PCR, PCR + reverse line blot hybridization, multiplex + microarray,
951 pan-fungal PCR + ITS sequencing) have been published from different groups in the field mainly based on
952 the ITS region^{551-553,901}. The assays from Harun *et al.*⁵⁵² and Lu *et al.*⁵⁵³ aim to discriminate all
953 *Scedosporium* spp. plus *L. prolificans*, while the assays from Bouchara *et al.*⁵⁵¹ and Nagano *et al.*⁹⁰¹ focus
954 on the identification of the *S. apiospermum* complex. All assays have been evaluated on respiratory tract
955 samples of CF patients. Highest sensitivity (100%) and specificity (99.2%) were found for the oligonucleo-
956 tide array published by Bouchara *et al.*⁵⁵¹ (**Table 14**).

957 **Recommendations** – The guideline group moderately supports the use of the oligonucleotide array pub-
958 lished by Bouchara *et al.*⁵⁵¹ for the detection of *S. apiospermum* complex in the sputum of CF patients,
959 and marginally recommends other methods. Future studies are needed to evaluate these tests outside
960 the CF setting.

961 **Diagnosis – Microbiology – Species identification**

962 **Evidence** – Based on positive cultures, species complex identification is mainly achieved by morphological
963 identification or ITS sequencing. For the identification to the species level, sequencing of both ITS and β -
964 tubulin is required^{555,902}. Alternative approaches are: loop-mediated isothermal amplification (LAMP),
965 quantitative real time PCR (qPCR), PCR-based reverse line blot hybridization (PCR-RLB), rolling circle am-
966 plification (RCA), repetitive sequence PCR and PCR-ESI-TOF MS, multiplexed PCR and liquid-phase array
967 that allow identification^{553,903,904}. Identification and genotyping can be done by repetitive sequence-based
968 PCR⁹⁰⁵. MALDI-TOF MS has been shown to be a reliable method for the identification to the genus level⁵⁷⁰
969 **(Table 14)**.

970 **Recommendations** – The guideline group strongly recommends species identification of pure cultures
971 using ITS1-ITS2 and β -tubulin sequencing, and marginally supports identification via alternative molecular
972 methods.

973 **Microbiology – Susceptibility testing**

974 **Evidence** – *Scedosporium* spp. exhibit high MIC values for AmB, ISAV, ICZ, and fluconazole⁹⁰⁶. Lowest MIC
975 values are found for VCZ, followed by PCZ and the echinocandins (ANID, CASPO, MICA)^{151,559,907-909}. Similar
976 results were found using CLSI⁵⁶¹, EUCAST testing⁵⁵⁹ and Sensititre® YeastOne® YO10 panels (Trek Diagnos-
977 tic Systems Ltd.)¹⁵¹. All studies found that VCZ was the most effective drug *in vitro* **(Table 14)**.

978 **Recommendations** – The guideline group strongly recommends susceptibility testing of *Scedosporium*
979 spp. using Sensititre® YeastOne® YO10 panels (Trek Diagnostic Systems Ltd.), EUCAST or CLSI methodology
980 to inform susceptibility patterns and moderately for clinical decision making, given the fact that clinical
981 breakpoints are not available.

982 **Diagnosis - Pathology**

983 **Evidence** – Fresh tissue microscopy with KOH treatment in the microbiology laboratory shows hyaline
984 hyphae similar to the hyphae of *Aspergillus* spp., *Fusarium* spp. and other hyalohyphomycetes. Discrimi-
985 nation from other hyalohyphomycetes is therefore difficult, even though *Scedosporium* spp. may show

986 some morphological features in histological findings with H&E or GMS stains such as irregular branching
 987 patterns, vascular invasion, and/or intra-tissue conidiation (**Table 14**).

988 **Recommendations** – The guideline group strongly recommends histopathology in the diagnosis of dis-
 989 ease, and moderately recommends direct microscopy of biopsies using KOH treatment.

990 **Diagnosis – Imaging**

991 **Evidence** – Best imaging modality depends on the site of infection^{411,910}. In case of suspected bone, spine,
 992 and joint infections MRI represents the method of choice for diagnosis of scedosporiosis, with fluorode-
 993 oxyglucose (PET)-CT being a suitable alternative imaging modality^{411,454,910}. For detection of brain involve-
 994 ment (*e.g.* CNS abscess formations), MRI and, if MRI was not available, CT have been used success-
 995 fully^{448,451,452,597-599}. In CF patients, near drowning victims, and victims of natural disasters, who are at risk
 996 for developing pulmonary manifestations of scedosporiosis, chest CT is the imaging modality of choice,
 997 while for differentiating colonization from infection in CF patient thorax CT or chest radiograph have been
 998 used to detect the abundance of pulmonary infiltrates^{445 452} (**Table 14**).

999 **Table 14. Microbiological, histopathological and imaging diagnostics for *Scedosporium* spp. infections**

Population	Intention	Approach	SoR	QoE	Reference	Comment
Microscopy, culture, MIC testing						
Any	To diagnose	Direct microscopy	A	III	Tortorano CMI 2014 ¹³ Cortez CMR 2008 ⁵⁴¹	
Any	To diagnose	Culture (species identification by ITS sequencing)	A	III	Tortorano CMI 2014 ¹³ Cortez CMR 2008 ⁵⁴¹ Lackner Mycoses 2011 ⁵⁴² Denton MMCR 2016 ⁶⁷¹ Sharma SJKDT 2015 ⁸⁴⁶ Leek CRT 2016 ⁵⁹⁹ Kelly BMCID 2016 ⁴⁹⁵ Torres-Sánchez TransPro-ceed 2018 ⁸⁷⁹ Loh Cureus 2018 ⁷⁶⁰	Blood culture CSF culture Tissue culture
Any with CF	To diagnose	Culture of respiratory tracts samples on selective media (SceSel+ , inhibitory mold agar or brain heart infusion agar)	A	III	Sedlacek JCF 2015 ⁵⁴³ Horré Mycoses 2011 ⁵⁴⁵ Hong JCM 2017 ⁵⁴⁶ Blyth JCM 2010 ⁵⁴⁴	>11,600 samples, from 2,346 cases, benefit of SceSel+ compared to standard media documented for N=5,000 samples. 150 samples from 42 cases, <i>Scedosporium</i> recovered on SceSel+, Mycosel, and SABD from 90.6%, 50.0%, and 46.9%
Any	To diagnose	Culture and histopathology	A	III	Balandin MMCR 2016 ⁴⁶² Tammer IJID 2011 ⁸⁹⁹	

Any	To determine susceptibility	Susceptibility testing with microdilution EUCAST method	A	III	Alastruey-Izquierdo AAC 2018 ⁵⁵⁹	Most active compound VCZ with MIC ₅₀ =1 mg/L, followed by echinocandins
Any	To determine susceptibility	Susceptibility testing with CLSI M38-A2 method	A	III	Espinel-Ingroff AJCM 2005 ⁹⁰⁹	No clinical breakpoints available
Any	To determine susceptibility of <i>S. apiospermum</i>	Susceptibility testing with Sensititre® YeastOne® YO10 test (TREK Diagnostic Systems Ltd)	A	IIu	Halliday IJAA 2016 ¹⁵¹	N=14 isolates, VCZ most active antifungal
Any	To inform antifungal treatment	Susceptibility testing with microdilution EUCAST or CLSI method	B	III	Alastruey-Izquierdo AAC 2018 ⁵⁵⁹	No clinical breakpoints available
Serology assays						
Any with CF	To diagnose	Detection by ELISA of antibodies to mycelial catalase	C	III	Mina CVI 2015 ⁹⁰⁰	Catalase A1 might be a good candidate for the development of an immunoassay for serodiagnosis of infections caused by the <i>S. apiospermum</i> complex in patients with CF. Test not commercially available
Nucleic-acid based assays						
Any with CF	To detect <i>S. boydii</i> / <i>S. apiospermum</i>	Oligoarray, with ITS region amplicons hybridized to the array for species identification	B	III	Bouchara JCM 2009 ⁵⁵¹	N=57, sputum samples from 39 cases; <i>S. apiospermum</i> detected in 16/57 samples vs. 12/57 by culture
Any with CF	To detect <i>Scedosporium</i> species and <i>L. prolificans</i>	Reverse line blot (RLB) hybridization after group-specific PCR	C	III	Lu Mycoses 2011 ⁵⁵⁴	N=59, sputum samples from 52 cases; 62.7% of samples were positive by RLB vs. 8.5% by culture
Any with CF	To detect fungal species including <i>S. apiospermum</i>	PCR targeting the 18S-ITS1-5.8S-ITS2-28S rRNA gene plus nested PCR	C	III	Nagano MedMycol 2010 ⁹⁰¹	N=77, sputum samples from 77 cases; <i>S. apiospermum</i> detected in 3/77 samples vs. 2/77 by selective culture
Any with CF	To detect and identify <i>Scedosporium</i> spp. and <i>L. prolificans</i>	Multiplex PCR, followed by RFLP analysis of ITS region	C	III	Harun JCM 2011 ⁵⁵²	208 sputum samples from 69 cases; Sens. 62%, spec. 97%
Any	To identify	ITS1-ITS2 + beta-tubulin sequencing	A	III	Hedayati MicPath 2019 ⁹⁰²	<i>S. boydii</i> in 2/90 and <i>Scedosporium ellipsoideum</i> in 1/90 CF patients
Any	To identify	Culture + ITS1-ITS2/beta-tubulin sequencing	A	III	Ziesing MedMycol 2016 ⁵⁵⁵	<i>S. apiospermum</i> / <i>Scedosporium boydii</i> in 2-3% CF patients, <i>S. aurantiacum</i> , <i>S. minutisporum</i> sporadically (N=3,186, over 5-yr period)
Any	To identify	MALDI-TOF MS	B	III	Sitterle CMI 2014 ⁵⁷⁰	
Any with CF	To identify	ITS sequencing/ microarray	C	III	Schwarz PIOSOne 2017 ⁵⁵⁸	<i>S. boydii</i> , <i>S. apiospermum</i> , <i>S. aurantiacum</i>
Any with CF	To identify and genotype	Repetitive sequence-based PCR	C	III	Matray MedMycol 2016 ⁹⁰⁵	<i>S. boydii</i> , <i>S. apiospermum</i> , <i>S. minutisporum</i> , <i>S. aurantiacum</i> , <i>S. ellipsoideum</i>
Tissue based diagnosis						
Any	Species identification	Direct microscopy of biopsies using KOH treatment	B	III	Ramirez-Garcia MedMycol 2018 ⁴⁴⁵ Kimura PatholInt 2010 ⁵⁷¹	Difficult to distinguish <i>Scedosporium</i> -infected tissues from those infected by <i>Aspergillus</i> or <i>Fusarium</i> , as all of them present hyaline hyphae, regular hyphal septation, and sometimes dichotomous branching. Unique features such as irregular branching patterns or intravascular invasion and intratissue conidiation may help pathologists to diagnose <i>Scedosporium</i> mycoses.
Any	To diagnose mold infection	Histopathology of biopsies	A	III	Walts DiagnCyto 2001 ⁹¹¹	
Imaging studies						
Any	To diagnose bone/joint infections	MRI	A	III	Koehler CRM 2014 ⁴¹¹ Zimmerli NEJM 2010 ⁹¹⁰	
Any		FDG-PET/CT	A	III	Koehler CRM 2014 ⁴¹¹	If MRI is not possible

	To diagnose bone/joint infections				Zimmerli NEJM 2010 ⁹¹⁰	
Any with brain lesions / abscesses	To assess clinical manifestations and imaging characteristics	CT scan of the brain	B	III	Berenguer Medicine 1997 ⁵⁶²	N=3
					Uno JIC 2014 ⁵³⁶	N=1
					McKelvie CEO 2001 ⁵⁶³	N=1
Any with brain lesions / abscesses	To assess clinical manifestations and imaging characteristics	MRI of the brain	A	III	Kelly BMCID 2016 ⁴⁹⁵	N=1
					Ochi IJH 2015 ⁵¹⁰	N=1
Any	To diagnose pulmonary infection	CT Thorax	A	III	Nakamura JMCR 2011 ⁴⁵²	
Any	To diagnose pulmonary infection	Chest X-ray	B	III	Nakamura JMCR 2011 ⁴⁵²	
					Ramirez-Garcia MedMycol 2018 ⁴⁴⁵	
Any with CF	To differentiate colonization from infection	CT Thorax	A	III	Ramirez-Garcia MedMycol 2018 ⁴⁴⁵	
CF, cystic fibrosis; CLSI, Clinical and Laboratory Standards Institute; CSF, cerebrospinal fluid; CT, computed tomography; ELISA, Enzyme-linked Immunosorbent Assay; EUCAST, European Committee for Antimicrobial Susceptibility Testing; FDG, fluorodeoxyglucose; IFD, invasive fungal disease; ITS, internal transcribed spacer; KOH, potassium hydroxide; MALDI-TOF MS, matrix assisted laser desorption ionization-time of flight mass spectrometry; MEC, minimum effective concentration; MIC, minimal inhibitory concentration; MRI, magnetic resonance imaging; PCR, polymerase chain reaction; PET, positron emission tomography; QoE, quality of evidence; RFLP, restriction fragment length polymorphism; RLB, reverse line blot; rRNA, ribosomal ribonucleic acid; SABD Sabouraud Dextrose Agar; SceSel+, <i>Scedosporium</i> -selective medium; SoR, strength of recommendation; VCZ, voriconazole; yr, year.						

1000

1001 **Recommendations** – For all patients, the guideline group strongly recommends the use of MRI for the

1002 detection of brain abscesses and moderately recommends the use of contrast enhanced CT of the brain,

1003 when MRI is not available. For the detection of pulmonary infection, chest CT is strongly supported. For

1004 the detection and localization of scedosporiosis and the guided sampling of biopsies and body fluids, the

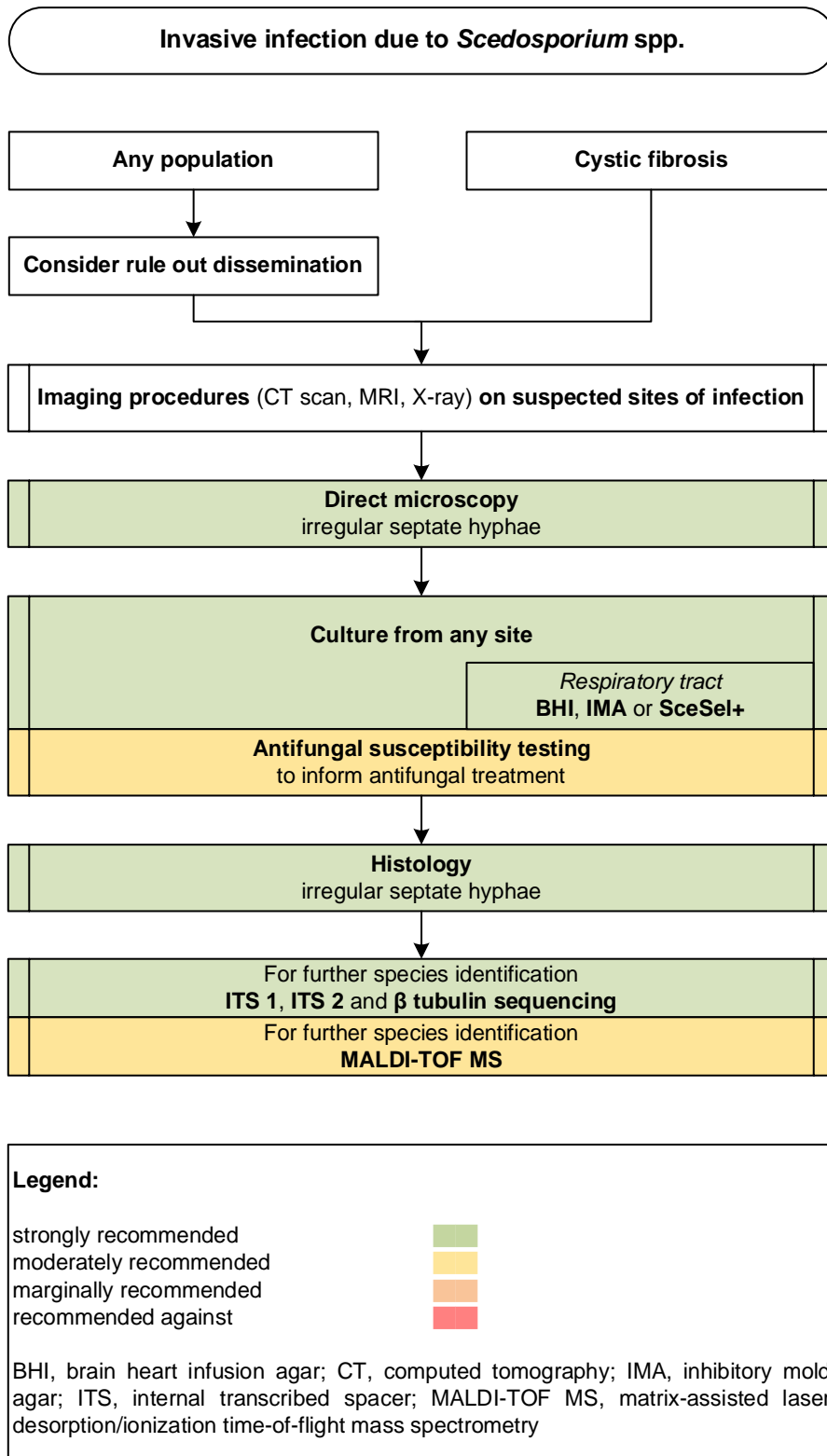
1005 guideline group strongly recommends MRI for the localization of scedosporiosis in bones and/or joints, or

1006 FDG-PET CT if MRI is not available. For suspected pulmonary infections the guideline group strongly rec-

1007 ommends chest CT, and moderately recommends chest X-ray if chest CT is not available. Diagnostic path-

1008 ways are displayed in **Figure 12**.

1009 **Figure 12. Optimal diagnostic pathway for scedosporiosis, when all imaging and assay techniques are**
 1010 **available**



1011

1012

1013 **Treatment approaches to scedosporiosis**

1014 Treatment in Adults

1015 **Diagnosis-driven treatment**

1016 **Evidence** – Studies have reported success of diagnosis-driven treatment in lung transplant recipients with
 1017 *Scedosporium* spp. colonization ^{493,912}, while results were more mixed for empiric treatment in patients
 1018 after near-drowning accidents ^{644,728}.

1019 **Recommendations** – In lung transplant recipients with colonization, pre-emptive treatment is moderately
 1020 recommended. Every attempt to obtain a diagnosis should be made at the time of initiation of therapy,
 1021 but should not delay therapy. Empiric treatment after near drowning accidents is marginally recom-
 1022 mended.

1023

1024 **First-line antifungal monotherapy**

1025 **Evidence** – In several studies, outcomes with VCZ based therapy were superior to any formulation of
 1026 AmB^{11,447}. Daily doses administered are started with 6 mg loading IV, followed by 4 mg IV twice daily. *In*
 1027 *vitro* clinical resistance to AmB formulations, as well as breakthrough infections, have been reported re-
 1028 peatedly. Use of AmB formulations should be restricted to settings in which there is no other antifungal
 1029 therapy available. For the use of ISA, ICZ or PCZ only limited evidence exists^{381,440,444,469}.

1030 **Recommendations** – First-line treatment with VCZ is strongly supported across all patterns of organ in-
 1031 volvement. Use of AmB formulations is discouraged whenever VCZ is available. The guideline group mar-
 1032 ginally supports the use of ISA, ICZ or PCZ for first line-treatment.

1033

1034 **First-line antifungal combination therapy**

1035 **Evidence** – In multiple studies antifungal combination therapy showed increased efficacy and improved
 1036 survival compared to monotherapy with AmB^{11,444,456,468}. There is a paucity of data evaluating combination
 1037 therapy vs. VCZ monotherapy (**Table 15**).

1038 **Table 15. First line treatment of *Scedosporium* spp. infections**

Population	Intention	Intervention	SoR	QoE	Reference	Comment
Fever-driven treatment						
Any with hematologi- cal malignancy	To cure <i>S. api- ospermum</i> in- fection	VCZ	C	III	Girmania JCM 1998 ⁹¹³	N=1, died
Diagnosis-driven treatment						

High-risk patients (lung transplant recipients with colonization)	To cure	Pre-emptive treatment	B	Ilu	Johnson TID 2014 ⁴⁹³	N=27; 17/20 VCZ and/or others, 9/17 cleared
					Parize TID 2017 ⁹¹²	N=14, 9/13 received azoles
					Sahi JHLT 2007 ⁸³³	N=5
					Tamm TID 2001 ⁹¹⁴	N=7
Near-drowning accidents	To cure	Empiric treatment	C	III	Katragkou Mycoses 2007 ⁷²⁸	N=12, mostly AmB
					Kowacs JCP 2004 ⁷⁴¹	N=1, AmB + ICZ
					Buzina MedMycol 2006 ⁶⁴⁴	N=1, CASPO
					Lee AJNS 2018 ⁵⁹⁷	N=1, AmB, later VCZ
					Chaney SMJ 2004 ⁶⁵⁸	N=1, AmB
					Mursch CNS 2006 ⁷⁸⁴	N=1, VCZ, later plus TRB
First-line treatment						
Any	To cure	VCZ iv, step down to oral possible	A	Ilu	Seidel CRM 2019 ¹¹	N=137, VCZ N=63, AMB
					Cobo MedMycol 2017 ⁴⁶⁸	N=10, 6/10 response
					Troke AAC 2008 ⁵⁷⁴	N=70, 64% response
					Husain CID 2005 ⁴⁴⁷	N=57, VCZ 6/8 survived vs. AmB 4/20 survived
Any	To cure	VCZ + one or more other antifungals (TRB, MICA, AmB)	B	Ilu	Seidel CRM 2019 ¹¹	N=29, VCZ + TRB N=17, VCZ + AmB N=12, benefit of combination unclear
					Cobo MedMycol 2017 ⁴⁶⁸	N=1, complete response
Any with <i>S. apiospermum</i>	To cure	ISA	C	III	Cornely Mycoses 2018 ³⁸¹	N=2, clinical response 1/2
Any with <i>S. aurantiacum</i> infection	To cure	VCZ OR PCZ	C	III	Heath CMI 2009 ⁴⁴⁰	N=29, low MICs against VCZ and PCZ
Immunocompromised	To cure	AmB lipid formulations	D	Ilu	Seidel CRM 2019 ¹¹	N=118, N=50 with AmB, N=30 AmB monotherapy. VCZ d42 mortality 11.3% vs. AmB 58.8% in immunocompromised, higher mortality with AmB mono vs. combination
					Perfect CID 2005 ³⁷⁸	N=8, 1/8 response
Immunocompetent	To cure	AmB lipid formulations alone OR in combination	C	Ilu	Seidel CRM 2019 ¹¹	N=90, VCZ d 42 mortality 14% vs. AmB 23.1%
Hematological malignancy	To cure	PCZ +/- AmB lipid formulation	C	III	Lamaris CID 2006 ⁴⁴⁴	N=4, 3/4 survived (including 2 with PCZ monotherapy)
Hematological malignancy	To cure	AmB lipid formulation + CASPO +/- VCZ	C	III	Lamaris CID 2006 ⁴⁴⁴	N=7, AmB + CASPO +/- VCZ 2/2 survived vs. AmB + ICZ 0/5 survived
Any with CF and lung infection	To cure	VCZ + either CASPO/MICA iv or inhaled AmB or both	B	III	Schwarz JCF 2018 ⁴⁵⁶	N=24, 2-drug combi 8/10 response, with 3-drug combi 14/14 response, VCZ mono 1/6 response
		VCZ	C	III		
Any with chronic lung disease	To cure	ICZ	D	III	Cooley EID 2007 ⁴⁶⁹	N=4, 3/4 died
Any with exogenous endophthalmitis	To cure	VCZ (po/iv, intravitreal), vitrectomy	C	III	Bui JOPT 2016 ⁸² Nochez JOPT 2008 ⁶⁰¹	N=2, success 2/2
Any with exogenous endophthalmitis	To cure	AmB iv + intravitreal	D	III	Roy OII 2016 ⁸²⁷ Taylor CEO 2002 ⁶⁰²	N=2, failure 2/2
Any with endogenous endophthalmitis	To cure	VCZ iv, oral, intravitreal +/- TRB +/- vitrectomy	B	III	Moloney Retina 2014 ⁹¹⁵ Jain ArchOphtal 2007 ⁷²¹	N=4, success 4/4
					Chen CEO 2007 ⁶⁶¹	N=2, lack of response due to delayed therapy 2/2
					Sarvat JOI 2007 ⁹¹⁶	N=1, success
					Musk JHLT 2006 ⁷⁸⁵	N=2, success 2/2
Hematological malignancy with endogenous endophthalmitis + other disseminated infections	To cure	AmB iv / intravitreal, VCZ po (delayed treatment)	D	III	McKelvie CEO 2001 ⁵⁶³	N=2, failure 2/2

Standard dose unless stated otherwise; AmB, amphotericin B; bid, twice a day; CASPO, caspofungin; CI, confidence interval; ICZ, itraconazole; ISA, isavuconazole; iv, intravenous; MIC, minimal inhibitory concentration; PCZ, posaconazole; po, orally; QoE, quality of evidence; SoR, strength of recommendation; TRB, terbinafine; VCZ, voriconazole.

1039

1040 **Recommendations** – There are limited data reporting successful outcomes with antifungal combination

1041 therapy with VCZ plus lipid formulation of AmB, VCZ plus TRB, and VCZ plus echinocandins^{11,444,456,785}. The

1042 guideline group does moderately support VCZ-based antifungal combination therapy for infections caused

1043 by *Scedosporium spp.*

1044

1045 **Antifungal salvage treatment**

1046 **Evidence** – In general, there are two drug-related reasons for treatment failures, refractory scedosporiosis

1047 or toxicity or intolerance to first-line regimens. For the triazole class, hepatic toxicity has the highest prev-

1048 alence and with AmB formulations renal toxicity may be a limiting factor. Toxicity may be caused by anti-

1049 fungals, or expected due to pre-existing organ damage. Only two drug classes show acceptable efficacy in

1050 scedosporiosis, thus salvage treatment mostly means switching to the other class. Successful outcomes

1051 have been reported with VCZ after primary treatment failure with lipid formulations of AmB³⁷⁶, PCZ⁹¹⁷,

1052 and after adding an echinocandin⁶⁹⁹ to pre-existing VCZ therapy (**Table 16**).

1053 **Table 16. Antifungal salvage treatment for *Scedosporium spp.* infections**

Population	Intention	Intervention	SoR	QoE	Reference	Comment
Any	To cure	VCZ	B	IIu	Perfect CID 2003 ³⁷⁶	N=10, response 3/10
Any	To cure	VCZ + echinocandin + GM-CSF	C	III	Goldman MMCR 2016 ⁶⁹⁹	N=1 cured after deteriorating on VCZ alone
Any	To cure	ISA	D	III	Cornely Mycoses 2018 ³⁸¹ Marty Mycoses 2018 ⁴⁰⁷	N=2, failure 2/2
Hematological malignancy with brain abscess	To cure	PCZ	C	III	Mellinghoff CID 2002 ⁹¹⁷	N=1, success

Standard dose unless stated otherwise; GM-CSF, granulocyte-macrophage colony-stimulating factor; ISA, isavuconazole; PCZ, posaconazole; QoE, quality of evidence; SoR, strength of recommendation; VCZ, voriconazole.

1054

1055 **Recommendations** – The guideline group moderately recommends VCZ, and marginally PCZ or adding an

1056 echinocandin to VCZ monotherapy for salvage treatment.

1057

1058 **Other treatment options**

1059 **Evidence** – Other treatment options include surgery and discontinuation/reduction of immunosuppres-
1060 sive drugs (**Table 17**).

1061

1062 **Table 17. Other treatment options for *Scedosporium* spp. infections**

Population	Intention	Intervention	SoR	QoE	Reference	Comment
Immunocompromised patients with subcutaneous scedosporiosis	To cure	Discontinuation of cyclosporine and prednisone followed by 2 wk levofloxacin iv without antifungal treatment	C	III	Li Mycopathol 2017 ⁵⁹³	N=1, success
Any with eye infection	Survival	Surgery	B	III	Seidel CRM 2019 ¹¹	N=47, surgery not associated with better survival

iv, intravenous; QoE, quality of evidence; SoR, strength of recommendation; wk, week(s)

1063

1064 **Treatment duration for scedosporiosis**

1065 **Evidence** – The duration of therapy necessary to treat scedosporiosis is unknown. In general, weeks to

1066 months of therapy are given. If the underlying immunodeficiency resolves (*e.g.*, diabetes is controlled,

1067 neutropenia definitively resolved, or immunosuppression can be tapered or stopped), therapy can be

1068 continued until resolution of signs and symptoms (**Table 18**).

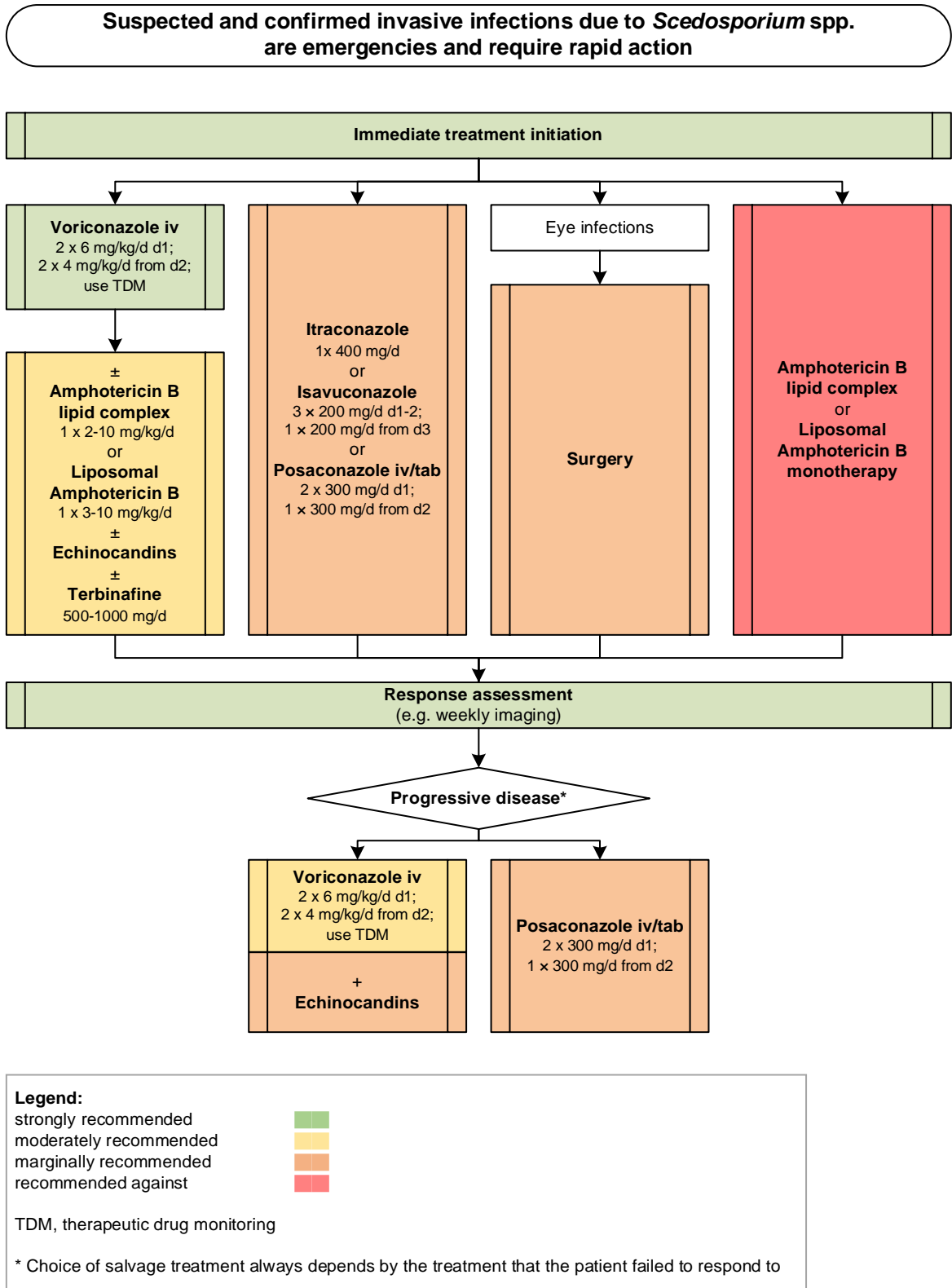
1069 **Table 18. Treatment duration for *Scedosporium* spp. infections**

Population	Intention	Intervention	SoR	QoE	Reference	Comment
CNS infections	To cure	VCZ for >3 mo	B	III	Schwartz Infection 2011 ⁹¹⁸	<i>Aspergillus</i> spp. 63%, <i>Scedosporium</i> spp. 18%, duration (mean) 93 d (1-1.128)
Any with fungal osteoarticular infections	To cure	VCZ for > 3 mo	B	III	Kumashi CMI 2006 ⁷⁴²	<i>Aspergillus fumigatus</i> N=2, non- <i>fumigatus</i> <i>Aspergillus</i> spp. N=8, non-specified <i>Aspergillus</i> spp. N=3, <i>Fusarium</i> spp. N=6, <i>Zygomycetes</i> N=5, <i>S. apiospermum</i> N=2, <i>Exserohilum</i> spp. N=1, Duration: 5 mo (median 3 mo; range 11 d to 18 mo)

Standard dose unless stated otherwise; CNS, central nervous system; d, day(s); mo, month(s); QoE, quality of evidence; SoR, strength of recommendation, VCZ, voriconazole.

1070 Treatment pathways for adults are displayed in **Figure 13**.

1071 **Figure 13. Optimal treatment pathway for scedosporiosis in adults** when all treatment modalities and
 1072 antifungal drugs are available



1073

1074

1075 **Specific considerations on treatment of scedosporiosis in children**

1076 **Evidence** – The clinical presentation of scedosporiosis in immunocompromised children is comparable to
 1077 that observed in adult patients, with a high rate of disseminated disease. Pulmonary and CNS scedospori-
 1078 osis in near-drowning patients is an important characteristic of *Scedosporium* spp., and the association of
 1079 invasive fungal disease and near drowning seems to be unique to scedosporiosis⁷²⁸. Reported outcomes
 1080 for disseminated diseases are dramatically poor, both in immunocompromised and immunocompetent
 1081 patients⁹¹⁹. In a recent review of invasive *Lomentospora* (n=22) and *Scedosporium* (n=33) infections in
 1082 children VCZ use and surgery were associated with improved clinical outcome⁵⁸⁴. Favourable outcome for
 1083 localized infections in immunocompetent children treated with VCZ have been reported also in other
 1084 studies^{664,860,920} (**Table 19**).

1085 **Table 19. Therapy in children for *Scedosporium* spp. infections**

Population	Intention	Intervention	SoR	QoE	Reference	Comment
First-line antifungal therapy						
Any	To cure	VCZ +/- other antifungals + surgery for localized infections	A	III	Seidel IJID 2019 ⁵⁸⁵	N=22
Immunocompetent	To cure	VCZ 8-9 mg/kg qd iv, use of TDM	A	III	Stripelis Med-Mycol 2009 ⁸⁶⁰	N=1, 10 yrs, success
					Cruysmans PID 2015 ⁶⁶⁴	N=1, 7 yrs, success
					Salamat IJPO 2015 ⁹²⁰	N=1, 6 yrs, success
Any	To cure	VCZ iv + TRB 25 mg qd po	C	III	Whyte PID 2005 ⁵⁴⁰	N=1, 8 yrs, survived
					Tintelnot Med-Mycol 2009 ⁵³³	N=1, 9 yrs
Hematological malignancy	To cure	L-AmB (N=11, 9 died)	C	III	Caira Haematol 2008 ⁹¹⁹	Literature review, N=52, median age 47 (3-79): <i>S. apiopsermum</i> N=15, 7/15 died (1 adult, died); <i>L. prolificans</i> N=37, 33/37 died
		D-AmB (N=24, 21 died)	C	III		
		D-AmB + 5FC (N=2, 2 died)	C	III		
		D-AmB + azoles (N=9, 6 died)	C	III		
		Azoles (N=6, 4 died)	C	III		
Hematological malignancy	To cure	Surgery + azole	C	III	Issakainen MedMycol 2010 ⁷²⁰	N=1, 14 yrs, success
Hematological malignancy with endogenous endophthalmitis + disseminated	To cure	VCZ 8 mg/kg qd iv, 100 µg intravitreal, TRB 125 mg qd, CASPO 50 mg qd, vitrectomy, surgical debridement	C	III	Chiam JAAPOS 2013 ⁴⁶⁷	N=1, success
Any with exogenous endophthalmitis	To cure	VCZ po, intravitreal 2x 200 µg, vitrectomy	C	III	Zarkovic IntOphthalmol 2007 ⁶⁰³	N=1, success
Any with chronic granulomatous disease	To cure	VCZ (OR ICZ)	C	III	Jabado CID 1998 ⁹²¹	N=2, + surgery, 2/2 survived
Salvage antifungal therapy						
Hematological malignancy	To cure	L-AmB (N=2, 2 died)	D	III	Caira Haematol 2008 ⁹¹⁹	Literature review, N=52, median age 47 (3-79): <i>S. apiopsermum</i> N=15, 7 died (1 adult, died); <i>L. prolificans</i> , N=37, 33 died
		L-AmB + VCZ (N=1, died)	C	III		
		L-AmB + ICZ (N=1, survived)	C	III		
		ICZ (N=4, 3 died)	C	III		
		VCZ (N=1, died)	D	III		
		PCZ (N=1, survived)	C	III		
		VCZ + TRB (N=1, survived)	C	III		

Standard pediatric dose unless stated otherwise; 5-FC, 5-fluorocytosine; bid, twice a day; CASPO, caspofungin; d, day(s); D-AmB, amphotericin B deoxycholate; CASPO, caspofungin; ICZ, itraconazole; iv, intravenous; L-AmB, liposomal amphotericin B; PCZ, posaconazole; po, orally; qd, once a day; QoE, quality of evidence; SoR, strength of recommendation; TDM, therapeutic drug monitoring; TRB, terbinafine; VCZ, voriconazole; yrs, years.

1086
1087 **Recommendations** – Treatment recommendations follow those given for adults. VCZ (+ TDM) is the first-
1088 line treatment of infections due to members of the genus *Scedosporium*. Surgery for localized disease is
1089 strongly recommended. Additional measures to reduce the immunosuppression should be considered.

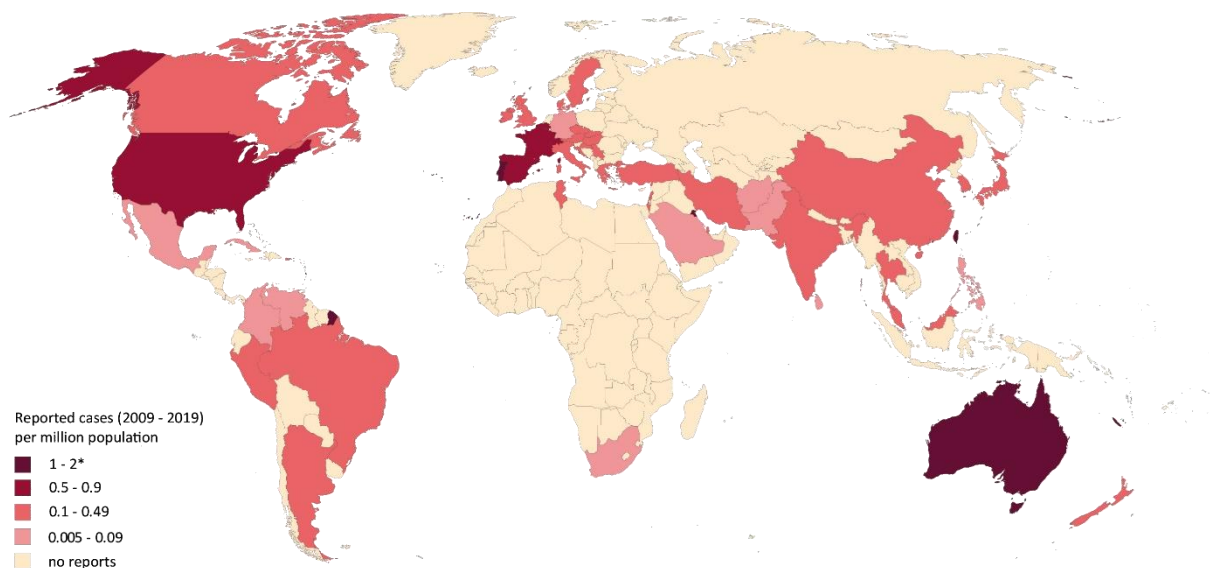
1090
1091 **4. Phaeohyphomycosis**
1092 **Epidemiology of phaeohyphomycosis**
1093 Phaeohyphomycosis (Greek: phaeo = dark) is caused by a heterogeneous group of melanized demati-
1094 ceous fungi that have a worldwide distribution and are found in soil, wood and decaying matter. Clinically
1095 important species causing systemic infections belong to the genera *Alternaria*, *Aureobasidium*, *Bipolaris*,
1096 *Chaetomium*, *Cladophialophora*, *Cladosporium*, *Curvularia*, *Exophiala*, *Exserohilum*, *Fonsecaea*, *Helmin-*
1097 *thosporium*, *Lomentospora* (see **lomentosporiosis**), and *Ochroconis*⁹²². The term phaeohyphomycosis has
1098 been introduced to separate these infections from the clinically and pathologically distinct chromoblasto-
1099 mycosis or mycetoma that are also caused by melanized fungi⁹²³. Phaeohyphomycosis occurs more fre-
1100 quently in male than female individuals and, unlike other mold infections, commonly occurs in immuno-
1101 competent patients, presenting as keratitis, subcutaneous, rhinosinusitis, allergic bronchopulmonary, but
1102 sometimes also as invasive pulmonary or severe cerebral infections with fungemia, with recent research
1103 indicating that previously unrecognized CARD9 immunodeficiency is present in many patients developing
1104 severe infections who were previously thought to be immunocompetent^{924,925}. Eye and subcutaneous
1105 phaeohyphomycosis usually follow a traumatic injury or surgery, without apparent underlying immune
1106 deficiency^{251,923}, in contrast, a history of previous trauma is rarely found in immunocompromised patients
1107 ⁹²⁶. If left untreated subcutaneous lesions slowly increase in size to form abscesses. Eye infections are
1108 frequently caused by *Alternaria*, *Curvularia*, *Exserohilum*, or *Helminthosporium* spp.. In skin infections,

1109 commonly associated genera are *Alternaria*, *Bipolaris*, *Exophiala*, and *Phialophora*^{248,922,927-929}. Brain infec-
1110 tions are comparably common, may present as brain abscess, meningitis, or encephalitis⁹²⁵, and are
1111 mainly caused by *Cladophialophora bantiana*, a neurotropic fungus that caused severe infections also in
1112 immunocompetent patients, with a considerable number of cases described in India^{924,928,930}. However,
1113 other fungi, such as *Rhinoctadiella mackenziei*, *Chaetomium strumarium*, *Verruconis gallopava* and *Ex-*
1114 *ophiala dermatitidis* in immunocompromised hosts and *Exserohilum rostratum* in a recent outbreak in the
1115 United States are also well described as causing CNS phaeohyphomycosis^{925,931-933}. *Bipolaris* and *Curvularia*
1116 are associated with fungal sinusitis with brain invasion, a clinical form that is becoming more common⁹²².
1117 Melanized molds can cause endocarditis after valve replacement, mediastinitis following surgery, and
1118 peritonitis in patients on continuous peritoneal dialysis⁹³⁴⁻⁹³⁸. Disseminated phaeohyphomycosis is mostly
1119 associated with immunocompromising or debilitating disease and is thought to originate in the lung after
1120 inhalation of the fungal agent^{923,929,939}.

1121 The prevalence of phaeohyphomycosis varies between regions, patient population and etiological agent.
1122 Cerebral phaeohyphomycosis occurs worldwide, but most cases have been reported from the United
1123 States, mostly in immunocompromised patients. Iatrogenic meningitis and other infections related to epi-
1124 dural injections of corticosteroids have been reported in two recent US outbreaks traced to environmental
1125 contamination at compounding pharmacies. During 2012, 754 cases of infection and 64 deaths were con-
1126 firmed among the 13,534 people potentially exposed to contaminated lots of methylprednisolone⁹³². Cer-
1127 ebral phaeohyphomycosis has also been frequently reported from India, particularly affecting immuno-
1128 competent individuals⁹⁴⁰. In India, *Alternaria* and *Curvularia* accounted for 7% of mold-related keratitis in
1129 a 10-year study²⁴⁸. In a multicentre study, 9.4% of fungal infections in liver and heart transplant recipients
1130 were related to phaeohyphomycosis, affecting sinuses, lung and CNS⁴⁴² (**Figure 14**).

1131

1132 **Figure 14. Worldwide distribution of phaeohyphomycosis (reported cases between 2009 and 2019 per**
 1133 **million population)**



1134

1135 Cases of phaeohyphomycosis reported in the medical literature were identified in a PubMed search on

1136 October 31, 2019 using the search string (Phaeohyphomycosis OR *Acrophialophora* OR *Alternaria* OR *An-*

1137 *thopsis* OR *Arnium* OR *Arthrinium* OR *Aureobasidium* OR *Bipolaris* OR *Botryodiplodia* OR *Botryomyces* OR

1138 *Chaetomium* OR *Chrysonilia* OR *Cladophialophora* OR *Cladosporium* OR *Cladorrhinum* OR *Coniothyrium*

1139 OR *Corynespora* OR *Curvularia* OR *Cyphellophora* OR *Dichotomophthora* OR *Dichotomophthoropsis* OR

1140 *Dissitimurus* OR *Drechslera* OR *Exophiala* OR *Wangiella* OR *Exserohilum* OR *Fonsecaea* OR *Hormonema* OR

1141 *Hortaea* OR *Lecytophora* OR *Leptosphaeria* OR *Medicopsis* OR *Microsphaeropsis* OR *Myceliophthora* OR

1142 *Mycocentrospora* OR *Mycocleptodiscus* OR *Nattrassia* OR *Neoscytalidium* OR *Neurospora* OR *Nigrograna*

1143 OR *Nodulisporium* OR *Ochroconis* OR *Oidiodendron* OR *Onychocola* OR *Papulaspora* OR *Periconia* OR *Phae-*

1144 *oacremonium* OR *Phaeosclera* OR *Phaeotheca* OR *Phaeotrichoconis* OR *Phialemonium* OR *Phialophora* OR

1145 *Phyllostica* OR *Phoma* OR *Didymella* OR *Phomopsis* OR *Phyllostictina* OR *Pleurophoma* OR *Pleurophomopsis*

1146 OR *Pleurostoma* OR *Polycytella* OR *Pseudomicrodochium* OR *Pyrenochaeta* OR *Ramichloridium* OR *Rhi-*

1147 *nocladiella* OR *Rhytidhysterion* OR *Sarcinomyces* OR *Scytalidium* OR *Taeniolella* OR *Tetraploa* OR *Thermo-*

1148 *myces* OR *Trematosphaeria* OR *Trichomarisis* OR *Ulocladium* OR *Veronaea* OR *Verruconis*) AND (case [Ti-

1149 tle/Abstract] OR patient [All Fields] OR report [Title/Abstract] OR infections OR invasive OR fungemia OR

1150 blood OR disseminat*) NOT Chromoblastomycosis[Title/Abstract] NOT mycetoma [Title/Abstract]) that

1151 yielded 3,325 publications. In total, 935 cases were identified from 55 countries^{97,138,666,926,934,936,939,941-}
1152 ^{111697,138,666,926,934,936,939,941-11158,163,173,178,489,518,749,935,937,1117-1343251,310,319,607,834,863,890,929,938,1344-1468}. Most cases
1153 were reported from India (n>200), China (n=188), United States (n=162), Spain (n=44), and Japan (n=41).
1154 Most infections were related to species of the genera *Alternaria* (>300), *Curvularia*, *Exophiala* (~100 each),
1155 *Exserohilum* (~70), *Cladophialophora*, *Bipolaris* (~50 each), *Phaeoacremonium*, *Cladosporium*, *Fonsecaea*,
1156 *Aureobasidium* (~20 each). Number of cases reported between 2009 and 2019 are presented as cases per
1157 million population per country. The resident population per country was obtained from www.worldome-
1158 ters.info³²¹. *One case each was reported from French Guiana, Martinique and New Caledonia (>2 cases
1159 per million population between 2009 and 2019)^{957,1092,1272}.

1160

1161 **Diagnosis of phaeohyphomycosis**

1162 ***Diagnosis – Microbiology – Conventional Methods***

1163 **Evidence** – Diagnosis relies on histopathology and careful gross and microscopic examination of cultured
1164 strains, which show dark colonies with usually darkly pigmented septate hyphae with widely variable co-
1165 nidia and conidiophores, respectively^{14,1131,1354}. Pleomorphism that is seen in dematiaceous organisms on
1166 histopathology is the most specific finding in microscopy. The Fontana-Masson stain helps to make mela-
1167 nin visible in dematiaceous molds that may appear pale in H&E and other stains, and helps to differentiate
1168 melanized elements of phaeohyphomycetes from other mold structures in tissue samples¹⁴ (**Table 20**).

1169

1170

1171 **Recommendations** – The guideline group strongly recommends histological evaluation and culture from
1172 clinical samples.

1173

1174 ***Diagnosis – Microbiology – Serology***

1175 **Evidence** – There are no simple serological or antigen diagnostic tests for infections caused by phaeohy-
1176 phomycetes, mainly due to the huge diversity of these pathogens. BDG and GM tests may cross-react with
1177 some melanized fungi, though neither has been proven useful for diagnosis of phaeohyphomycosis in
1178 general⁵¹⁸ (**Table 20**).

1179 **Recommendations** – While the guideline group marginally supports serology on a case by case basis, there
1180 is currently no serological test that can be recommended.

1181

1182 ***Diagnosis – Microbiology – Molecular-based***

1183 **Evidence** – ITS1/ITS2 targeting oligonucleotide probes or PCR followed by sequencing on DNA extracted
1184 directly from sputum, tissue samples or sinus aspirates were occasionally applied successfully, showing a
1185 higher sensitivity than culture^{551,901,926}. However, much more data is needed for routine use of this ap-
1186 proach. Possible contamination should be carefully considered due to the ubiquitous nature of dematia-
1187 ceous fungi (**Table 20**).

1188 **Recommendations** – Based on case reports, direct analysis of clinical samples using oligonucleotide arrays
1189 or universal PCR followed by sequencing can only marginally be supported.

1190

1191 ***Diagnosis – Microbiology – Species identification***

1192 **Evidence** – Morphological identification may be complicated by limited sporulation of causative patho-
1193 gens. Identification to species level is performed by ITS1/ITS2 or D1/D2 sequencing^{1144,1354,1399,1469,1470}
1194 and/or MALDI-TOF MS analysis^{1077,1471-1474} of strains cultured from tissue or blood samples. The usefulness
1195 of MALDI-TOF MS is highly dependent on the use of enriched databases (**Table 20**).

1196 **Recommendations** – The guideline group strongly recommends identification to species level by ITS1/ITS2
1197 or D1/D2 sequencing and moderately by MALDI-TOF MS analysis of cultured strains.

1198

1199 **Microbiology – Susceptibility testing**

1200 **Evidence** – The relevance of susceptibility testing is not yet fully defined, as breakpoints have not been
1201 established by CLSI or EUCAST, and there is a limited correlation between *in vitro* MICs and clinical out-
1202 comes. VCZ^{1181,1475} or PCZ¹²⁵⁴ are the most active drugs when tested by broth microdilution. A number of
1203 genera showed good *in vitro* susceptibility to ICZ, PCZ, VCZ, and AmB using Sensititre® YeastOne® YO10
1204 panel¹⁵¹(**Table 20**).

1205 **Recommendations** – Susceptibility testing is strongly recommended for identifying susceptibility pat-
1206 terns, and moderately for guiding treatment.

1207

1208 **Diagnosis - Pathology**

1209 **Evidence** – Histopathological examination of tissue samples may lead to diagnosis¹⁴⁷⁶ or provides im-
1210 portant diagnostic information¹⁴⁷⁷ (**Table 20**).

1211 **Recommendations** – The guideline group strongly recommends histopathological examination of tissue
1212 samples.

1213

1214 **Diagnosis – Imaging**

1215 **Evidence** – Chest CT scan was the most common abnormal radiographic study in transplant recipients
1216 suffering from phaeohyphomycosis¹⁴⁷⁷. Cranial CT/MRI is indicated for evaluation of possible CNS infec-
1217 tion (**Table 20**).

1219 **Table 20. Microbiological, histopathological and imaging diagnostics for phaeohyphomycetes/dematiaceous**
 1220 **fungi/black fungi infections**

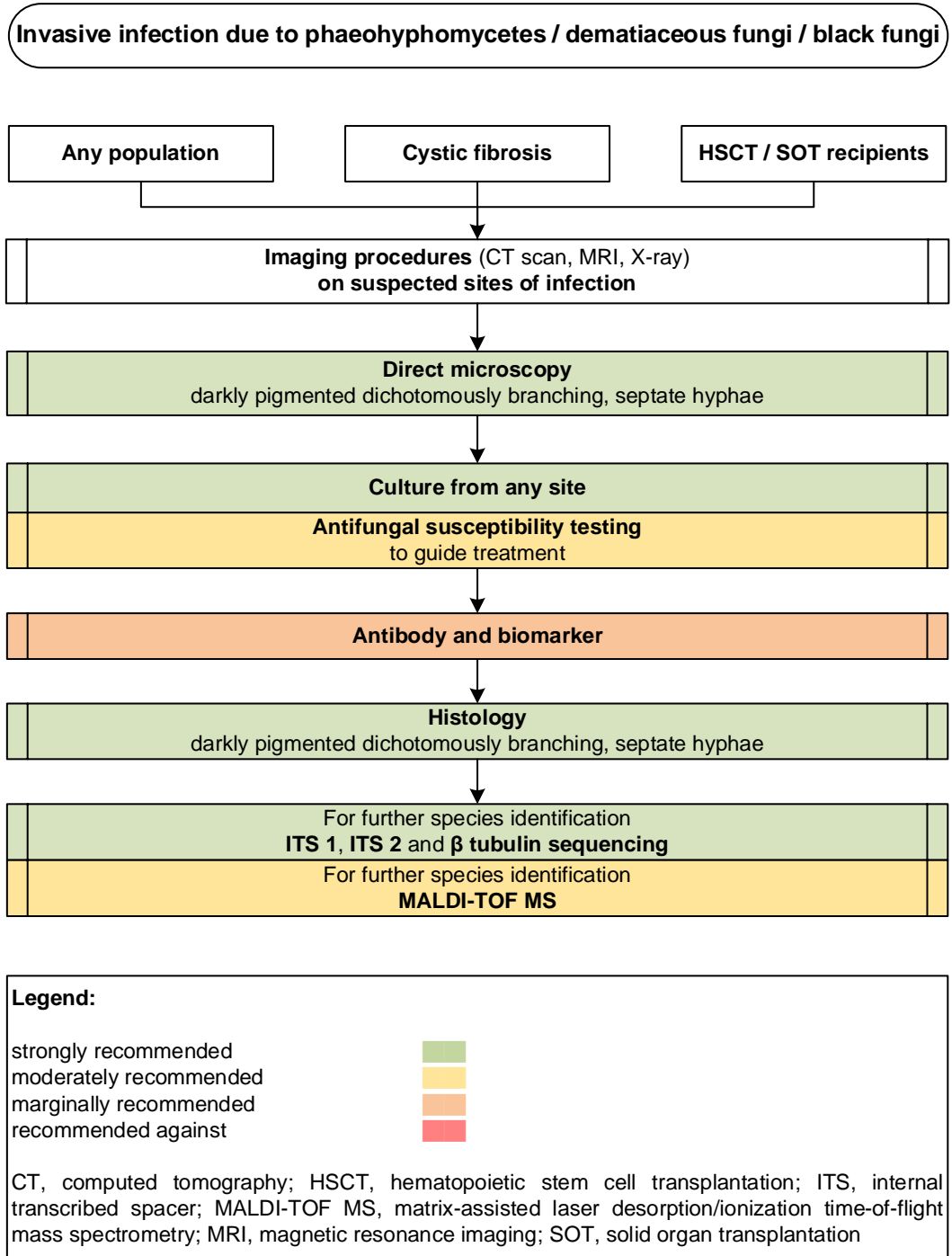
Population	Intention	Intervention	SoR	QoE	Reference	Comment
Microscopy, culture, MIC testing						
Any	To diagnose	Direct microscopy	A	III	Chowdhary CMI 2014 ¹⁴ Hoelett MMCR 2019 ¹⁴⁷⁸	Usually darkly pigmented
Any	To diagnose	Culture, species identification by morphological characteristics or ITS sequencing	A	III	Chowdhary CMI 2014 ¹⁴ Hoelett MMCR 2019 ¹⁴⁷⁸ Sato IntMed 2019 ¹³⁵⁴	Use Fontana-Masson stain avoid H&E stain
Any	To diagnose	Histopathology and culture	A	III	Ito ADV 2017 ¹¹⁴⁴ Shi Dermatopathol 2017 ¹⁴⁷⁹ Taj-Aldeen MedMycol 2010 ¹³⁹⁹ Koo MedMycol 2010 ¹¹⁸⁴ Cristini JCM 2010 ¹⁴⁶⁹ Garazoni MedMycol 2008 ¹⁴⁷⁰ Revankar OFID 2017 ⁵¹⁸ Kondori FEMSML 2015 ¹⁴⁷² Ozhak-Baysan MedMycol 2015 ¹⁴⁷³ Singh JCM 2017 ¹⁴⁷⁴ Fernandez BJID 2017 ¹⁰⁷⁷	Subcutaneous infections: Delayed growth (12-15 d). Culture confirmed by molecular methods CNS infections: Delayed growth (12-15 d) in most cases. Culture confirmed by molecular methods N=99, Diagnosis confirmed by culture in 97/99 (98%). Using ITS sequencing, the CDC further identified 5 isolates to the species level, 2 unknown isolates were identified, and 1 isolate initially identified as <i>Phialophora verrucosa</i> was determined to be <i>Pleurostomophora richardsiae</i> . Histopathology showed granulomatous inflammation and/or fungal elements in 49 of 99 (49%) cases.
GVHD	To diagnose	Blood culture	A	III	Sato IntMed 2018 ¹³⁵⁴	
Osteomyelitis and septic arthritis	To diagnose	Biopsy culture + histopathology	A	III	Lang BMCID 2018 ¹²⁰⁰	N=1
Any	To identify susceptibility pattern	Sensititre® YeastOne® YO10 panels	A	Ilu	Halliday IJAA 2016 ¹⁵¹	MIC90 AmB 1 µg/ml, ICZ 0.12 µg/ml, PCZ 0.25 µg/ml and VCZ 0.5 µg/ml had good <i>in vitro</i> activity against nine genera of dematiaceous fungi
Any	To identify susceptibility patterns	CLSI testing of isolates	A	III	Revankar OFID 2017 ⁵¹⁸	N=16 isolates, extended spectrum azoles and TRB most active antifungals
Any	To guide treatment of <i>Alternaria malorum</i> infection	Culture and molecular identification	B	III	Mirhendi MedMycol 2013 ¹²⁵⁴	MICs PCZ 0.063 µg/ml, AmB 0.125 µg/ml, ICZ 0.125 µg/ml, VCZ 1 µg/ml, FCZ 32 µg/ml. MECs ANID 0.016 µg/ml, CASPO 0.25 µg/ml
Any	To guide treatment of <i>E. dermatitidis</i> infection	Culture and molecular identification	B	III	Klasinc Mycopathol 2019 ¹¹⁸¹	MICs for 48h (µg/ml): ANID (8 µg/ml); FCZ (4 µg/ml); PCZ (0.25 µg/ml); VCZ (<0.016 µg/ml); ISA (0.125 µg/ml); ICZ (1 µg/ml); AmB (2 µg/ml)
Immunosuppressed patients	To guide treatment of <i>Exophiala oligosperma</i> infection	Culture and molecular identification	B	III	Rimawi MMCR 2013 ¹⁴⁷⁵	MICs AmB 0.5 µg/ml, MICA 0.25 µg/ml, PCZ 0.03 µg/ml, and VCZ 0.125 µg/ml
Serology assays						
Transplant patients	To diagnose	Serum GM or BDG	C	III	Revankar JFungi 2015 ¹⁴⁸⁰	GM and BDG occasionally may be cross-reactive with this group of fungi, but this is not consistent

Allergic bronchopulmonary aspergillosis	To detect fungi in sinus aspirates	Serum IgE level	C	III	Chowdhary MedMycol 2011 ¹⁴⁸¹	Peripheral eosinophilia and elevated total serum IgE level may indicate Allergic bronchopulmonary aspergillosis
Nucleic-acid based assays/MALDI-TOF MS						
Transplant patients	To diagnose	DNA sequencing from tissue	C	III	Ferrandiz-Pulido Mycoses 2019 ⁹²⁶	N=11; DNA sequencing confirmed the presence of <i>Alternaria</i> spp. (8 cases), <i>Cladosporium cladosporioides</i> , <i>Microsphaeropsis arundinis</i> and <i>E. oligosperma</i>
Any with CF	To detect in sputum	PCR + ITS1-ITS2 sequencing	C	III	Nagano MedMycol 2010 ⁹⁰¹	1 each of <i>E. dermatitidis</i> , and <i>Cladosporium</i> spp. were detected using the PCR assay compared to 3, and 0 respectively by selective culture
Any with CF	To detect in sputum <i>Acrophialophora fusispora</i> , <i>E. dermatitidis</i>	Oligoarray, developed with probes designed according to ITS1/ITS2 sequence data	C	III	Bouchara JCM 2009 ⁵⁵¹	Correct identification to species level of all <i>A. fusispora</i> and all but one strain of <i>E. dermatitidis</i> . It detected the presence of <i>E. dermatitidis</i> in two sputum samples whereas culture was negative in both samples.
Any with allergic fungal rhinosinusitis	To detect fungi in sinus aspirates	PCR assays using universal fungal primers (ITS3-ITS4), followed by <i>Bipolaris</i> primers (Bipol A73 + B572)	C	III	El-Morsy JLO 2010 ¹⁴⁸²	A comparison of culture with PCR assays; Cultures yielded 30 dematiaceous fungi in 68 samples. Universal fungal PCR assay yielded 68/68 positive results, no further fungal identification was performed. <i>Bipolaris</i> PCR assay gave 27 positive results. PCR assays gave positive results in 4 of 10 control samples without sinusitis. This study did not include an in-house validation of the assays used.
Any with fungal meningitis or other infections linked to contaminated methylprednisolone acetate	To detect <i>E. rostratum</i> and other in CSF	PCR using broad-range primers targeting ITS2 region vs. <i>E. rostratum</i> -specific primers	C	II	Gade JCM 2015 ¹⁴⁸³	<i>E. rostratum</i> DNA was detected in 28% of 413 cases (mostly from CSF samples). The <i>E. rostratum</i> -specific PCR assay was more sensitive than the broad-range PCR assay and when compared to culture. <i>Cladosporium</i> DNA was detected in CSF of one case.
Any	Species identification from culture	Species identification by ITS or D sequencing	A	III	Revankar OFID 2017 ⁵¹⁸	N=99, Diagnosis confirmed by culture in 97/99 (98%). Using ITS sequencing, the CDC further identified 5 isolates to the species level, 2 unknown isolates were identified, and 1 isolate initially identified as <i>P. verrucosa</i> was determined to be <i>P. richardsiae</i> . Histopathology showed granulomatous inflammation and/or fungal elements in 49 of 99 (49%) cases.
Any	Species identification from culture	Species identification by MALDI-TOF MS	B	III	Fraser JCM 2017 ¹⁴⁷¹	MALDI-TOF MS for species identification from strains cultured from tissue
Tissue-based diagnosis						
SOT recipients	To diagnose	Histology	A	IIu	Schieffelin TID 2014 ¹⁴⁷⁶	N=27, 4 diagnosed by histological appearance alone
SOT or HSCT transplant recipients	To diagnose	Histopathology	A	IIu	McCarthy MedMycol 2015 ¹⁴⁷⁷	N=56, histopathology added to the diagnostic information in 15 patients with 13 (86.7%) of those being skin specimens
Any with allergic rhinosinusitis	To diagnose	Histopathology	A	III	Montone HNP 2016 ¹⁴⁸⁴	Microscopic examination in allergic fungal rhinosinusitis reveals eosinophilic mucin
Imaging studies						
SOT or HSCT transplant recipients	To diagnose	Chest CT, chest X-ray, cranial CT, cranial MRI	A	IIu	McCarty MedMycol 2015 ¹⁴⁷⁷	N=56, Chest CT most common abnormal radiographic study, assisting in the diagnosis of 24 patients

ANID, anidulafungin; BAL, bronchoalveolar lavage; CASPO, caspofungin; CDC, Centers for Disease Control; CF, cystic fibrosis; CLSI, Clinical and Laboratory Standards Institute; CNS, central nervous system; CSF, cerebrospinal fluid; CT, computed tomography; d, day(s); DNA, deoxyribonucleic acid; FCZ, fluconazole; HSCT, hematopoietic stem cell transplantation; ICZ, itraconazole; ISA, isavuconazole; ITS, internal transcribed spacer; MALDI-TOF MS, matrix assisted laser desorption ionization-time of flight mass spectrometry; MEC, minimum effective concentration; MICA, micafungin; MIC, minimal inhibitory concentration; MRI, magnetic resonance imaging; PCR, polymerase chain reaction; PCZ, posaconazole; QoE, quality of evidence; SoR, strength of recommendation; SOT, Solid organ transplantation; TRB, terbinafine; VCZ, voriconazole.

- 1221
- 1222 **Recommendations** – The guideline group strongly recommends chest CT scan and cranial CT/MRI in the
- 1223 case of suspected lower respiratory tract and CNS infection, respectively (**Figure 15**).
- 1224

1225 **Figure 15. Optimal diagnostic pathway for phaeohyphomycosis, when all imaging and assay tech-**
 1226 **niques are available**



1227
 1228
 1229
 1230
 1231

1232 **Treatment approaches to phaeohyphomycosis**

1233 Treatment in adults

1234 **Targeted first-line antifungal therapy**

1235 **Evidence** – The use of either VCZ or lipid formulations of AmB (including combinations particularly for
 1236 disseminated infections) has successfully treated phaeohyphomycosis cases with various organ involve-
 1237 ment patterns^{378,518,932,1322,1477,1485-1487}. There are reports of successful treatment with CASPO or PCZ mono-
 1238 or combination therapy^{518,1477,1486,1487}.

1239 In several case series of CNS phaeohyphomycosis, D-AmB or lipid formulations of AmB as well as - more
 1240 recently - VCZ (alone or in combination with lipid formulations of AmB) were the most commonly success-
 1241 fully used agents^{518,923,924,940}. VCZ alone (n=301) or in combination with L-AmB (n=143) has been success-
 1242 fully used in the outbreak associated with *E. rostratum* contaminated methylprednisolone injections⁹³².

1243 Large case series report the successful use of either ICZ or VCZ (both sometimes in combination with
 1244 surgery) for cutaneous or subcutaneous phaeohyphomycosis, with smaller case-series reporting similar
 1245 success rates for PCZ, and case reporting of successful use of TRB^{518,926,1119,1476,1488-1491}. ICZ has also been
 1246 most frequently used to successfully treat chromoblastomycosis¹⁴⁹².

1247 ISA has been used successfully in first-line treatment for *Exserohilum* or *Curvularia* infections but not for
 1248 infections due to *Cladophialophora* spp. or *Cladosporium* spp.³⁸¹.

1249 Intravenous or intravitreal AmB (with or without VCZ, 5-fluorocytosine (5-FC) or vitrectomy) has been the
 1250 mainstay of the treatment for patients with endogenous or exogenous endophthalmitis with inconsisten-
 1251 cies in treatment outcomes reported^{518,952,1030,1082,1390,1453,1493-1499} **(Table 21)**.

1252 **Table 21. First-line antifungal therapy for phaeohyphomycetes/dematiaceous fungi/black fungi infections**

Population	Intention	Intervention	SoR	QoE	Reference	Comment
Any	To cure	AmB lipid formulations	B	Ilu	Perfect CID 2005 ³⁷⁸	N=4 with <i>Curvularia</i> , response/cure 3/4 (75%)
					Ben-Ami CID 2009 ¹⁴⁸⁶	N=9, response 6/9
					Bagga MMCR 2019 ¹⁵⁰⁰	N=1, success
					McCarty MedMycol 2015 ¹⁴⁷⁷	N=56, L-AmB N=20, combination therapy N=15, overall death N=14
Any with <i>Cladophialophora</i> or <i>Cladosporium</i> infection	To cure	ISA	D	Ilu	Cornely Mycoses 2018 ³⁸¹	N=2, <i>C. bantiana</i> + <i>Cladosporium</i> spp., response 0/2
Any with <i>Exserohilum</i> or <i>Curvularia</i> infection	To cure	ISA	C	Ilu	Cornely Mycoses 2018 ³⁸¹	N=2, <i>E. rostratum</i> and <i>Curvularia lunata</i> , response 2/2

Any with disseminated infection	To cure	AmB lipid formulation + VCZ / PCZ / ICZ OR echinocandin OR all three +/- TRB +/- 5-FC	B	III	Ben-Ami CID 2009 ¹⁴⁸⁶	N=27, AmB lipid formulation + VCZ/PCZ N=10 OR + echinocandin N=14 OR all three N=3; combination therapy 22/27 response, monotherapy 13/19 response
					Hagiya JIC 2019 ¹⁵⁰¹	N=1, <i>E. dermatitidis</i> , L-AmB + VCZ, failure
					Chalkias TID 2014 ¹⁰¹⁰	N=1, <i>E. dermatitidis</i> , L-AmB + VCZ, success
					Edathodu JCM 2013 ¹⁵⁰²	N=1, <i>Triadelphia pulvinata</i> , VCZ + L-AmB, failed
					McCarty MedMycol 2015 ¹⁴⁷⁷	N=56, VCZ N=24, L-AmB N=20, CASPO N=7; combination therapy N=15, 14/56 died
					Qiu JIC 2019 ¹⁵⁰³	N=1, <i>Phialophora</i> spp., success
					Santos CMI 2017 ¹⁴⁸⁸	N=2
					Qureshi ClinTransplant 2012 ¹³²²	N=10, <i>V. gallopava</i> , AmB lipid formulations or D-AmB + VCZ or ICZ, 8/10 survived
					Revanker OFID 2017 ⁵¹⁸	N=26, response d30 31%, mortality d30 38%. Combination 5/16 response vs. monotherapy 3/10 response. 18/26 died, 11/16 combination vs. 7/10 monotherapy.
Any	To cure	VCZ	B	III	Ben-Ami CID 2009 ¹⁴⁸⁶	N=3, response 2/3
					Pundhir IJSTDAIDS 2016 ¹⁵⁰⁴	N=1, <i>Scolecobasidium</i> spp., response
					Vasquez CID 2017 ¹⁴⁸⁷	N=14, 13/14 survived
					McCarty MedMycol 2015 ¹⁴⁷⁷	N=56, VCZ N=24, combination therapy N=15, 14/56 died
					Revanker OFID 2017 ⁵¹⁸	N=26, 9/26 VCZ monotherapy, including 2 with endocarditis (both died)
Any	To cure	CASPO	C	III	Ben-Ami CID 2009 ¹⁴⁸⁶	N=4, response 3/4
					McCarty MedMycol 2015 ¹⁴⁷⁷	N=56, CASPO N=7, combination N=15, 14/56 died
Any with disseminated infection	To cure	VCZ / PCZ + echinocandin OR TRB	B	III	Vasquez CID 2017 ¹⁴⁸⁷	N=2, 2/2 failed
					Thomas MMI 2018 ¹⁴⁹⁰	N=1, + surgery, failed
					Revanker OFID 2017 ⁵¹⁸	N=26, 16/26 combination, 2/4 endocarditis patients survived
Any	To cure	PCZ	C	III	Ben-Ami CID 2009 ¹⁴⁸⁶	N=1, response
					Moran TID 2019 ¹²⁶⁹	N=1, <i>V. gallopava</i> , success
Any	To cure	D-AmB	D	III	Sribenjalux TID 2019 ¹³⁸⁵	N=1, <i>P. richardsiae</i> , success
					Chhabra IJDR 2013 ¹⁰²³	N=1, <i>Alternaria alternata</i> , + surgery, success
SOT patients with cavitary native lung nodules	To cure	VCZ + CASPO	C	III	Shah TID 2019 ¹³⁶³	N=1, <i>Phaeoacremonium parasiticum</i> , success
Phaeohyphomycosis of the CNS	To cure	Lipid based AmB formulations	B	III	Revanker CID 2004 ⁹²⁴	N=109, AmB N=59, L-AmB N=8, 5-FC + AmB N=24, ICZ +/- AmB N=18, +/- surgery, overall death N=66
					Chakrabarti MedMycol 2015 ⁹⁴⁰	N=113, <i>C. bantiana</i> , D-AmB 48.7%, AmB + 5-FC 15.3%, lipid preparations of AmB 14.2%, none associated with better outcome
					Doymaz Mycoses 2015 ¹⁵⁰⁵	N=1, <i>Fonsecaea monophora</i> , success
					Thomas MMI 2018 ¹⁴⁹⁰	N=1, fatal outcome
					Howlett MMCR 2019 ¹¹³¹	N=1, <i>C. bantiana</i> , failure
					Dobias FMicrobiol 2018 ¹⁰⁶²	N=1, <i>F. monophora</i> , success
Phaeohyphomycosis of the CNS	To cure	VCZ +/- L-AmB	B	III	Gopalakrishnan IJMM 2017 ¹¹⁰⁴	N=2, <i>C. bantiana</i> , success 2/2
					Rosow TID 2011 ¹³⁴¹	N=1, <i>Bipolaris spicifera</i> , success
					Santos CMI 2017 ¹⁴⁸⁸	N=1, success
					Jung JKNS 2014 ¹¹⁶⁰	N=1, + surgery, success
					Gadgil JCN 2013 ¹⁰⁸⁸	N=1, <i>Curvularia</i> spp., + surgery, success

					Mukhopadhyay JMM 2017 ¹¹⁹⁸	N=1, <i>C. bantiana</i> , failure
					Mohammadi Mycoses 2018 ¹²⁶⁰	N=1, <i>R. mackenziei</i> , failure
					Revanker OFID 2017 ⁵¹⁸	N=6, + surgery in 4/6, 2/6 survived
					Taj-Aldeen MedMycol 2010 ¹³⁹⁹	N=1, <i>R. mackenziei</i> , failure
	To cure	D-AmB +/- surgery	D	III	Revanker CID 2002 ⁹²³	Review, N=72, D-AmB N=62, L-AmB N=3, 5-FC + AmB N=5, Azole + AmB N=10, +/- surgery, 57/72 died. D-AmB 14/62 (23%) survived
					Badali JCM 2011 ⁹⁷³	N=1, <i>Thielavia subthermophila</i> , failure
					Sládeková JMMCR 2014 ¹⁵⁰⁶	N=1, <i>C. bantiana</i> , failure
Any with <i>E. rostratum</i>	To cure	L-AmB + PCZ / ICZ +/- surgery	C	III	Katragkou MedMycol 2014 ¹⁴⁸⁵	Review, N=48, 13/32 combination therapy
Any with <i>E. rostratum</i>	To cure	VCZ +/- L-AmB	B	III	Smith NEJM 2013 ⁹³²	N=444, VCZ monotherapy N=301, combination VCZ + L-AmB N=143
Any with cutaneous / subcutaneous phaeohyphomycosis	To cure	ISA PCZ +/- surgical debridement	C	III	Dalla GTID 2019 ¹⁵⁰⁷	N=1, <i>A. alternata</i> , success
					Los-Arcos TID 2019 ¹⁵⁰⁸	N=1, <i>Medicopsis romeroi</i> , success
					Crawford TID 2015 ¹⁵⁰⁹	N=1, <i>M. arundinis</i> , success
					Thomas MMI 2018 ¹⁴⁹⁰	N=1, +surgery, success
					Revanker OFID 2017 ⁵¹⁸	N=32, PCZ N=10, response d30 79%, mortality d30 3%, follow-up response 84%, 11/32 partial response, 16/32 complete response
Any with cutaneous / subcutaneous phaeohyphomycosis	To cure	ICZ +/- surgery	A	IIu	Crabol PLOSNTD 2014 ¹⁴⁹¹	N=5, response 5/5
					Schieffelin TID 2014 ¹⁴⁷⁶	N=24, excision N=22, ICZ N=19, VCZ N=2, no antifungal therapy N=3
					Santos CMI 2017 ¹⁴⁸⁸	N=51, surgical excision w/o antifungals N=21, ICZ N=30, success 51/51
					Ogawa Mycopathol 2016 ¹⁴⁸⁹	N=6, 2 <i>Exophiala</i> and 3 <i>Fonsecaea</i> ; ICZ N=4; ICZ + surgery N=2, success
					Revanker OFID 2017 ⁵¹⁸	N=32, ICZ N=13, surgery N=6, response d30 79%, mortality d30 3%, follow-up response 84%
					Ferrández-Pulido Mycoses 2018 ⁹²⁶	N=6, response 3/6; failure 3/6
					Chan SMJ 2014 ¹⁵¹⁰	N=1, <i>M. romeroi</i> , success
					Bohelay Mycoses 2016 ¹⁵¹¹	N=1, <i>Exophiala spinifera</i> , success
					Sharma Mycopathol 2016 ¹⁵¹²	N=1, <i>M. romeroi</i> , success
					Khader IJDVL 2015 ¹⁵¹³	N=1, <i>C. bantiana</i> , success
					Furudate CRD 2012 ¹⁵¹⁴	N=1, <i>Phaeoacremonium rubrigenum</i> , success
					Chander Mycopathol 2016 ¹⁵¹⁵	N=2, <i>Rhytidhysterion rufulum</i> , success 1/2
					Chhonkar IJPS 2016 ¹⁵¹⁶	N=3, success 2/3
					Mittal IJD 2014 ¹⁵¹⁷	N=1, <i>Cladophialophora carrionii</i> , success
					Parente Mycoses 2011 ¹⁵¹⁸	N=2, <i>E. jeanselmei</i> and <i>C. carrionii</i> , success 2/2
					Sang MedMycol 2011 ¹⁵¹⁹	N=1, <i>Veronaea botryosa</i> , success
					Pereira IJDVL 2010 ¹⁵²⁰	N=1, <i>Cladophialophora boppii</i> , success
					Crawford TID 2015 ¹⁵⁰⁹	N=1, <i>M. arundinis</i> , success
					Gunathilake JMM 2013 ¹⁵²¹	N=1, <i>C. lunata</i> , success
					Machmachi MedMycol 2011 ¹⁵²²	N=1, <i>Falciformispora tompkinsii</i> , success
Nolêto CMI 2019 ¹⁵²³	N=1, <i>Phoma (Peyronellaea) spp.</i> , success					
Haridasan TID 2017 ¹⁵²⁴	N=7, no response to ICZ alone, 6/7 lesions surgically excised					

					Michelon DOJ 2014 ¹⁵²⁵	N=1, <i>Alternaria</i> spp., success			
Any with cutaneous / subcutaneous phaeohyphomycosis	To cure	VCZ +/- surgery	A	IIu	Galipothu IJMM 2015 ¹⁵²⁶	N=1, order <i>Pleosporales</i> , success			
					Revanker OFID 2017 ⁵¹⁸	N=41, surgery N=20; systemic antifungals N=40. VCZ 26 (65%), VCZ combi 12 (30%), response d30 53%, mortality d30 12%, follow-up response 68%			
					Revanker OFID 2017 ⁵¹⁸	N=32, VCZ N=9			
					Ferrández-Pulido Mycoses 2018 ⁹²⁶	N=11, <i>Exophiala</i> ; partial response			
					Balla JCP 2015 ¹⁵²⁷	N=1, <i>Curvularia</i> spp., success			
					Los-Arcos TID 2019 ¹⁵⁰⁸	N=1, SOT, <i>M. romeroi</i> , success			
					Brokalaki TransProceed 2012 ¹⁵²⁸	N=1, <i>V. gallopava</i> , success			
					Lief TID 2011 ¹⁵²⁹	N=2, <i>E. jeanselmei</i> , mixed response			
					Desoubeaux JMM 2013 ¹⁵³⁰	N=1, <i>E. jeanselmei</i> , success			
					Crabolo PLOSNTD 2014 ¹⁴⁹¹	N=8, response in 5/8; 2/3 switched to PCZ salvage treatment			
					Crawford TID 2015 ¹⁵⁰⁹	N=1, <i>M. arundinis</i> , success			
					Vermeire DMID 2010 ¹⁵³¹	N=2, <i>A. alternata</i> and <i>Curvularia</i> spp., success 2/2			
Any with cutaneous / subcutaneous phaeohyphomycosis	To cure	TRB +/- VCZ / ICZ	C	III	Mohammed AJM 2019 ¹⁵³²	N=1, <i>E. jeanselmei</i> , success			
					Thomas MMI 2018 ¹⁴⁹⁰	N=2, success 1/2			
					Ogawa Mycopathol 2016 ¹⁴⁸⁹	N=1, success			
Any with subcutaneous chromoblasto-mycosis	To cure	Ketoconazole + surgery	D	III	Radhakrishnan IJMM 2010 ¹⁵³³	N=1, <i>E. spinifera</i> , failure			
					Bao AJTMH 2018 ¹⁵³⁴	N=1, <i>F. monophora</i> , success			
					Mouchalouat IID 2011 ¹⁴⁹²	N=15, ICZ N=6, ICZ + FCZ N=5, surgery N=4, success 12/15 (80%)			
		TRB + local thermotherapy	C	III	Shi MMCR 2016 ¹⁵³⁸	N=1, <i>F. monophora</i> , success			
					PCZ + surgery	C	III	Dupont TID 2010 ¹⁵³⁹	N=1, <i>C. carrionii</i> , success
Intravenous drug user with endophthalmitis	To cure	AmB intravitreal, iv, VCZ iv + vitrectomy	D	III	Fox JOII 2016 ¹⁰⁸²	N=1, <i>Pleurostoma richardsiae</i> , failure			
Post-op patients with exogenous endophthalmitis	To cure	AmB intraocular, VCZ intraocular, po + vitrectomy	D	III	Alex MMCR 2013 ⁹⁵²	N=1, <i>C. lunata</i> , failure			
Post-op patients with exogenous endophthalmitis	To cure	5-FC, AmB intravitreal, topical	C	III	Kaushik AJO 2001 ¹⁴⁹⁸	N=1, <i>C. lunata</i> cultured, success			
Post-op patients with exogenous endophthalmitis	To cure	VCZ topical, intravitreal, FCZ po + vitrectomy	C	III	Homa Mycopathol 2018 ¹⁵⁴⁰	N=1, <i>E. dermatitidis</i> , success			
Any with exogenous endophthalmitis	To cure	AmB intravitreal +/- iv +/- subconjunctival + vitrectomy	D	III	Clamp RCBR 2014 ¹⁰³⁰	N=1, <i>E. dermatitidis</i> , failure			
					Hofling-Lima AJO 1999 ¹⁴⁹³	N=2, <i>E. jeanselmei</i> , failure			
					Margo AJO 1990 ¹⁴⁹⁶	N=1, <i>E. dermatitidis</i> , failure			
					Sun MedMycol 2010 ¹³⁹⁰	N=1, <i>P. verrucosa</i> , failure			
Any with endogenous endophthalmitis	To cure	AmB intravitreal, iv, FCZ po +/- intravitreal +/- topical +/- vitrectomy	C	III	Rao Retina 2004 ¹⁵⁴¹	N=1, <i>Alternaria</i> spp, outcome was VA hand movements			
					Pavan AJO 1993 ¹⁴⁹⁷	N=1, <i>Bipolaris hawaiiensis</i> , success			
Any with endogenous endophthalmitis	To cure	AmB intravitreal, iv + vitrectomy	C	III	Zayit-Soudry AJO 2005 ¹⁴⁹⁴	N=1, <i>Phialemonium curvatum</i> , success			
					Weinberger MedMycol 2006 ¹⁵⁴²	N=1, <i>P. curvatum</i> , failure			
Any with endogenous endophthalmitis	To cure	AmB intravitreal, topical, iv, FCZ intravitreal, topical, systemic, VCZ intravitreal, systemic + vitrectomy	C	III	Wu RCBR 2011 ¹⁴⁵³	N=1, <i>Cladosporium</i> spp., success			
Any with endogenous endophthalmitis	To cure	VCZ	C	III	Dogra IJO 2018 ¹⁵⁴³	N=1, <i>Lecytophora</i> spp., success			

Standard dose unless stated otherwise; 5-FC, 5-fluorocytosine; AmB, amphotericin B; CASPO, caspofungin; CNS, central nervous system; CSF, cerebrospinal fluid; d, day(s); D-AmB, amphotericin B deoxycholate; FCZ, Fluconazole; ICZ, itraconazole; ISA, isavuconazole; KCZ, ketoconazole; L-AmB, liposomal amphotericin B; PCZ, posaconazole; qd, once a day; QoE, quality of evidence; SoR, strength of recommendation; SOT, solid organ transplantation; TRB, terbinafine; VA, visual acuity; VCZ, voriconazole.

1254 **Recommendation** – Lipid formulations of AmB alone or in combination with a triazole and/or echi-
1255 nocandin and VCZ monotherapy are all moderately supported as first-line treatment across all patterns
1256 of organ involvement, including the CNS. For CNS infection due to *C. bantiana*, the addition of 5-FC is
1257 marginally supported. Specifically for disseminated infections combination therapy with VCZ or PCZ plus
1258 an echinocandin or TRB is a moderately supported alternative. The use of D-AmB is discouraged whenever
1259 better tolerated lipid formulations of AmB are available.

1260
1261 For *E. rostratum* infections, first-line treatment with VCZ (with or without L-AmB) is moderately sup-
1262 ported, while the guideline group marginally supports the use of combination therapy with L-AmB and
1263 another azole (with or without surgery). ISA is marginally supported as first-line treatment for *Exserohilum*
1264 or *Curvularia* infections, but the group recommends against the use of ISA for infections due to *Clado-*
1265 *phialophora* spp. or *Cladosporium* spp. In patients with cutaneous or subcutaneous phaeohyphomycoses
1266 the guideline group strongly supports the use of VCZ or ICZ as first line treatment, with a moderate rec-
1267 ommendation for PCZ and marginal recommendations for ISA or TRB.

1268

1269 **Salvage antifungal therapy**

1270 **Evidence** – ISA has been successfully used as salvage therapy in patients infected with *Alternaria* spp.
 1271 (n=1) and *Curvularia* spp. (n=1)³⁸¹. PCZ and VCZ have also been successfully used for salvage treat-
 1272 ment^{926,1491} (**Table 22**).

1273 **Table 22. Antifungal salvage treatment for phaeohyphomycetes/dematiaceous fungi/black fungi infections**

Population	Intention	Intervention	SoR	QoE	Reference	Comment
Any	To cure	ISA	B	Ilu	Cornely Mycoses 2018 ³⁸¹	N=1, <i>Alternaria</i> spp., response
					Cornely Mycoses 2018 ³⁸¹	N=1, <i>Curvularia</i> spp., response
Any	To cure	PCZ	B	III	Meriden MedMycol 2012 ¹⁵⁴⁴	N=1, <i>V. gallopava</i> , success
					Secniková DermaTeraphy 2014 ¹⁵⁴⁵	N=1, <i>A. alternata</i> , success
					Crabol PLOSNTD 2014 ¹⁴⁹¹	N=2, success 2/2
Any with cutaneous / subcutaneous phaeohyphomycosis	To cure	VCZ +/- TRB + surgical debridement	B	III	Kulkarni ECT 2017 ¹⁵⁴⁶	N=1, <i>M. romeroi</i> , success
					Garcia-Reyne TID 2011 ¹⁵⁴⁷	N=1, <i>Diaporthe longicolla</i> , success
					Ferrándiz-Pulido Mycoses 2018 ⁹²⁶	N=3, success 3/3
Immunocompromised patients with subcutaneous phaeohyphomycosis	To cure	Intralesional L-AmB	C	III	Mahajan IJD 2014 ¹⁵⁴⁸	N=1, <i>Rhynchostyria</i> spp., success
Immunocompromised patient with chromoblastomycosis	To cure	L-AmB, ICZ, intralesional L-AmB	C	III	Tawade Cutis 2018 ¹⁵⁴⁹	N=1, <i>Cladosporium carrionii</i> , success
		ICZ + TRB + local heat therapy	C	III	Tan Mycopathol 2015 ¹⁵⁵⁰	N=1, <i>F. monophora</i> , partial response
Immunocompetent patient with recurrent infection	To cure	ICZ	C	III	Geltner Infection 2015 ¹⁵⁵¹	N=1, <i>V. gallopava</i> , relaps after discontinuation
					Maquiné RSBMT 2019 ¹⁵⁵²	N=1, <i>C. bantiana</i> , failure
Any with chromoblastomycosis	To cure	VCZ	C	III	Criado JDT 2011 ¹⁵⁵³	N=3, <i>F. pedrosoi</i> , partial response

Standard dose unless stated otherwise; ICZ, itraconazole; ISA, isavuconazole; L-AmB, liposomal amphotericin B; QoE, quality of evidence; SoR, strength of recommendation; TRB, terbinafine; VCZ, voriconazole.

1274

1275 **Recommendation** – ISA, PCZ or VCZ are recommended with moderate strength (BIII) for salvage treat-
 1276 ment of phaeohyphomycosis.

1277

1278 **Other treatment**

1279 **i) Surgical/medical interventions**

1280 **Evidence** – In several case reports or series, surgical interventions (*i.e.* surgery, cryosurgery, cryotherapy,
 1281 laser therapy, heat therapy or potassium iodide) were performed to contain localized cutaneous infection
 1282 or reduce infectious burden in advanced phaeohyphomycosis cases^{926,1119,1476,1486,1488,1554-1559}. The surgery
 1283 involved either debridement of the skin and soft tissue, resection of subcutaneous or pulmonary nodules,
 1284 or drainage of brain abscess. For phaeohyphomycosis cases with cerebral abscess, complete excision with

1285 administration of antifungal therapy was documented^{930,940,1145,1260,1560-1563}. Complete excision of lesions
 1286 was shown to be critical for successful management of *C. bantiana*-related CNS infection¹⁵⁶⁴. The use of
 1287 surgical intervention in addition to systemic corticosteroids for patients with allergic fungal sinusitis to
 1288 reduce symptoms has been noted as well¹⁵⁶⁵. For patients with allergic bronchopulmonary mycosis, sur-
 1289 gical intervention alone for reducing symptoms was reported¹⁵⁶⁵ (Table 23).

1290 **Table 23. Other treatment options for phaeohyphomycetes/dematiaceous fungi/black fungi infections**

Population	Intention	Intervention	SoR	QoE	Reference	Comment
Any with localized cutaneous infection or subcutaneous nodule	To cure	Surgery	A	IIu	Ferrandiz-Pulido Mycoses 2018 ⁹²⁶	N=11, surgery N=6
					Haridasan TID 2017 ¹¹¹⁹	N=7
					Schiffelin TID 2017 ¹⁵⁶⁶	N=17
					Guarro JCM 2003 ¹⁵⁵⁴	N=2
					Ben-Ami CID 2009 ¹⁴⁸⁶	N=14, 11/14 survived
Santos CMI 2017 ¹⁴⁸⁸	N=51, complete excision w/o antifungals N=21, partial debridement 16/30 with antifungals (53.3%), 51/51 cured					
Any with subcutaneous nodule	To cure	Cryotherapy, laser therapy, heat therapy or potassium iodide	C	III	Yang MedMycol 2012 ¹⁵⁵⁵	N=1
					Gugnani MedMycol 2006 ¹⁵⁵⁶	N=1
					Torres-Rodriguez ArchDermatol 2005 ¹⁵⁵⁷	N=1
Any with chromoblastomycosis	To cure or reduce infectious burden in advanced cases	Cryosurgery	B	IIu	Bonifaz Mycoses 2001 ¹⁵⁵⁸	N=51
					Castro IJD 2003 ¹⁵⁵⁹	N=22
Any with cerebral abscess	To cure	Surgery + antifungal therapy	A	IIu	Mohammadi Mycoses 2018 ¹²⁶⁰	N=1
					Kantarcioglu MedMycol 2017 ¹⁵⁶⁰	N=85
					Doymaz Mycoses 2015 ¹⁵⁰⁵	N=1
					Nandedkar AJN 2015 ¹⁵⁶⁷	N=1
					Jung JKNS 2014 ¹¹⁶⁰	N=1
					Gadgil JCN 2013 ¹⁰⁸⁸	N=1
					Delfino MedMycol 2006 ¹⁵⁶¹	N=1
					Jabeen CID 2011 ¹¹⁴⁵	N=6
					Garg NeurolIndia 2007 ⁹³⁰	N=10
Chakrabarti MedMycol 2015 ⁹⁴⁰	N=114, <i>C. bantiana</i> , complete excision 52/114 (46.4%), partial excision 41/114 (36.7%)					
Any with cerebral abscess	To cure	Adding 5-FC to antifungal treatment	C	III	Chakrabarti MedMycol 2015 ⁹⁴⁰	N=113, <i>C. bantiana</i>
Any with allergic sinusitis	To reduce symptoms	Surgery + systemic corticosteroids	A	IIu	Rinaldi DMID 1987 ¹⁵⁶⁵	N=5
Any	To cure	G-CSF or GM-CSF	C	III	Ben-Ami CID 2009 ¹⁴⁸⁶	N=39, response 16/19 for G-CSF or GM-CSF
Any with allergic sinusitis	To reduce symptoms and corticosteroids	Omalizumab	C	III	Gan AJO 2015 ¹⁵⁶⁸	N=7, unclear how many of those phaeohyphomycosis
Allergic bronchopulmonary mycosis	To reduce symptoms	Surgery	C	III	Halwig ARRD 1985 ¹⁵⁶²	N=1
					Rinaldi DMID 1987 ¹⁵⁶⁵	N=5
					Chowdhary MedMycol 2012 ¹⁵⁶³	N=1
					Chowdhary MedMycol 2011 ¹⁵⁶⁹	N=1, pediatric patient
Solid organ transplant recipients with cutaneous phaeohyphomycosis	To cure	Surgical excision / debridement	A	IIu	Santos CMI 2017 ¹⁴⁸⁸	N=51, complete excision w/o antifungals N=21, partial debridement 16/30 (53.3%), 51/51 cured

5-FC, 5-fluorocytosine; G-CSF, granulocyte colony-stimulating factor; GM-CSF, granulocyte-macrophage colony-stimulating factor; ICZ, itraconazole; QoE, quality of evidence; SoR, strength of recommendation.

1291

1292 **Recommendation** – For localized cutaneous infections or subcutaneous nodules, the guideline group
 1293 strongly supports a complete surgical removal whenever possible. The group strongly supports the use of
 1294 surgery in addition to systemic antifungal therapy or corticosteroids for patients with cerebral abscess or
 1295 allergic fungal sinusitis, respectively.

1296

1297 **ii) Augmentation of host response**

1298 **Evidence** – G-CSF or GM-CSF has been added to antifungal treatment in a case series that involved 39
 1299 cases of proven or probable phaeohyphomycosis¹⁴⁸⁶.

1300

1301 **Recommendation** – The guideline group marginally supports G-CSF or GM-CSF to augment host re-
 1302 sponse against phaeohyphomycosis.

1303

1304 **Treatment duration**

1305 **Evidence** – There is no standard treatment duration for phaeohyphomycosis, with durations ranging from
 1306 weeks to months. A median duration of treatment with a variety of antifungal agents (*i.e.* VCZ, PCZ, ICZ,
 1307 AmB or TRB) was reported as 50 to 73 days in all patients⁵¹⁸ while in patients with underlying malignancy
 1308 and infection with *E. dermatitidis*, the duration of successful treatment with triazoles ranged between 7
 1309 and 64 days¹⁴⁸⁷. Among SOT recipients, an average treatment duration of 10 months¹⁴⁷⁶ was noted, rang-
 1310 ing from 3 to 18 months¹⁴⁸⁸ (**Table 24**).

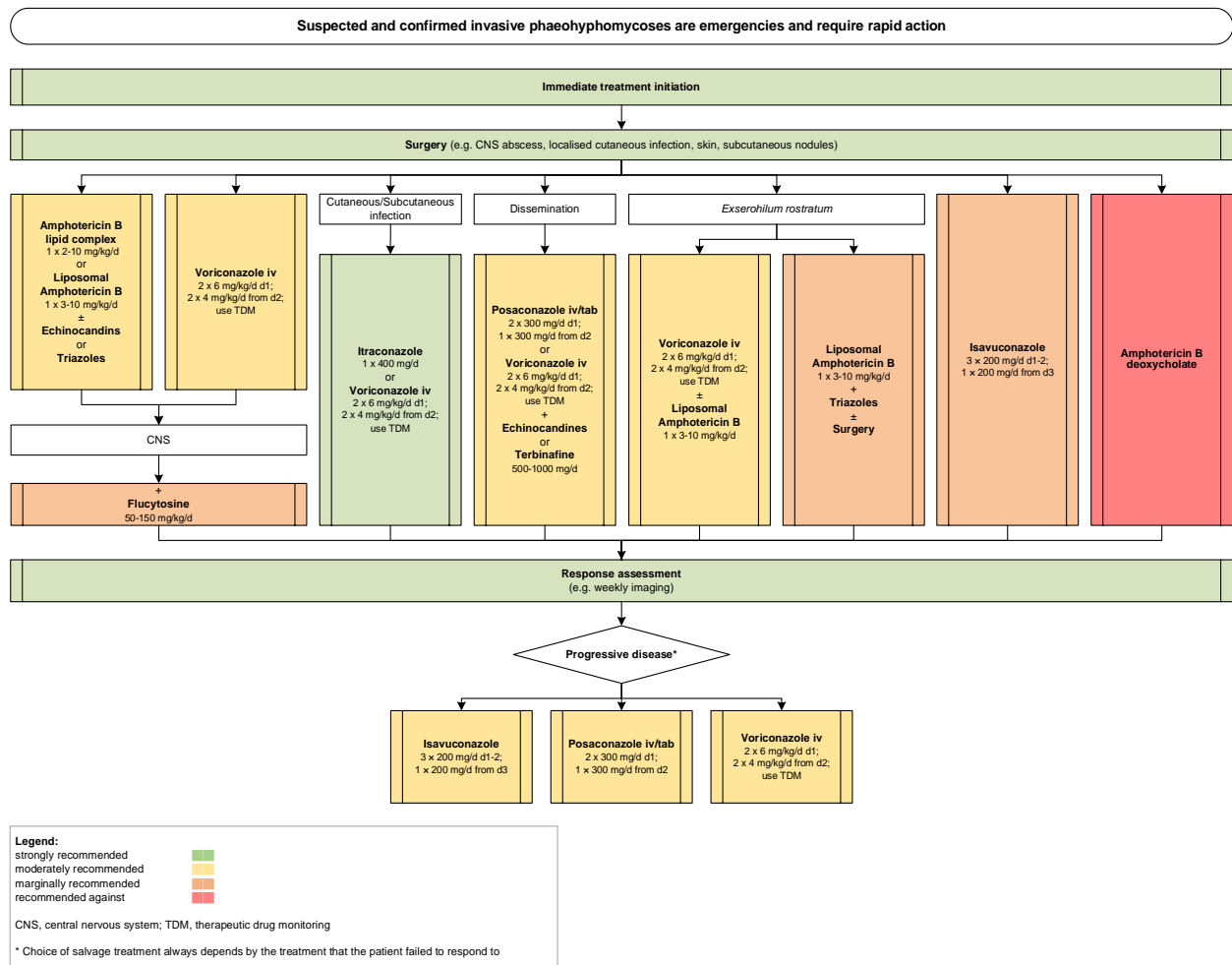
1311 **Table 24. Treatment duration for phaeohyphomycetes/dematiaceous fungi/black fungi infections**

Population	Intention	Intervention	SoR	QoE	Reference	Comment
SOT recipients with cutaneous infection	To cure	ICZ for 3–18 mo	B	III	Schieffelin TID 2014 ¹⁴⁷⁶	N=24; Average treatment among 17 survivors 10 mo (range 6–27 mo)
					Santos CMI 2017 ¹⁴⁸⁸	N=30, ICZ for 3-18 mo
Any	To cure	Long term treatment with VCZ, PCZ, ICZ, AmB, 5-FC	B	III	Revankar OFID 2017 ⁵¹⁸	N=99, median duration 50–73 d (range 2–915 d)
Any	To cure	ICZ for a median of 50–73 d for local infections, VCZ for more severe infections +/- TRB or AmB	C	III	Revanker OFID 2017 ⁵¹⁸	Local superficial infection: median duration 73 d (range 1–915 d). Local deep infection: median duration 50 d (range 3–710 d). Disseminated infection: median duration treatment 61 d (range 2–720 d).
Hemato-oncological patients with <i>E. dermatitidis</i> blood-stream infections	To cure	<i>E. dermatitidis</i> : VCZ for 7–64 d	C	III	Vasquez CID 2017 ¹⁴⁸⁷	<i>E. dermatitidis</i> , duration of successful treatment range 7-64 d

5-FC, 5-fluorocytosine; AmB, amphotericin B; d, day(s); ICZ, itraconazole; PCZ, posaconazole; mo, month(s); QoE, quality of evidence; SoR, strength of recommendation; SOT, Solid organ transplant; TRB, terbinafine; VCZ, voriconazole.

1312
 1313 **Recommendation** – The guideline group moderately supports treatment until all signs and symptoms of
 1314 infection have resolved. The treatment duration is determined by clinical response regardless of the type
 1315 of antifungal agents administered (**Figure 16**).

1316 **Figure 16. Optimal treatment pathway for phaeohyphomycosis in adults when all treatment modalities and antifungal drugs are available**
 1317



1318
 1319
 1320
 1321 **Specific considerations on treatment of phaeohyphomycosis in children**
 1322 **Evidence** - There are minimal data in children on the treatment of phaeohyphomycosis⁹²⁴. All reported
 1323 pediatric cases had CNS involvement (**Table 25**).

1324 **Table 25. First-line antifungal therapy in children for phaeohyphomycetes/dematiaceous fungi/black fungi infec-**
 1325 **tions**

Population	Intention	Intervention	SoR	QoE	Reference	Comment
Immunocompetent	To cure	ABLC 3-6 mg/kg qd + 5-FC, then ABLC 6 mg/kg qd + ICZ 6 mg/kg qd	C	III	Chang JCN 2009 ¹⁵⁷⁰	N=1, 3 yrs, cerebral abscesses, <i>E. dermatitidis</i> , failure
Immunocompetent	To cure	L-AmB, VCZ 200 mg bid	C	III	Alabaz MedMycol 2009 ¹⁵⁷¹	N=1, 8 yrs, systemic infection, <i>E. dermatitidis</i> , failure
Hematological patients	To cure	L-AmB + surgery	C	III	Bay RCI 2017 ¹⁵⁷²	N=1, 8 yrs, nasal vestibule infection, <i>Curvularia spicifera</i> , success
					Saint-Jean CJIDMM 2007 ¹⁵⁷³	N=1, 3 yrs, cutaneous infection, <i>E. rostratum</i> , success
HSCT	To cure	PCZ 150 mg qd	C	III	Tanuskova JMMCR 2017 ¹⁵⁷⁴	N=1, 8 yrs, lung infection, <i>E. dermatitidis</i> , lung, failure
HSCT	To cure	ANID 1.5 mg/kg qd+ VCZ 7 mg/kg qd for 5 d, then ANID 1.5 mg/kg qd + L-AmB	C	III	El Feghaly MMCR 2012 ¹⁵⁷⁵	N=1, 2 yrs, fungemia, <i>Graphium basitruncatum</i> , failure
Any	To cure	Various including AmB, surgery, combination L-AmB plus 5-FC	C	IIu	Revankar CID 2004 ⁹²⁴	N=15 children, CNS; most frequent <i>C. bantiana</i> and <i>Ramichloridium mackenziei</i> , 5/15 survived: AmB + 5-FC + (partial) excision N=2, AMB N=1, lipid AMB + ICZ + aspiration/excision N=2

Standard pediatric dose unless stated otherwise; 5-FC, 5-flucytosine; ANID, anidulafungin; AmB, amphotericin B; ABLC, Amphotericin B Lipid Complex; ALL, acute lymphocytic leukemia; AML, acute myeloid leukemia; bid, twice a day; CNS, central nervous system; d, day(s); HSCT, hematopoietic stem cell transplantation; ICZ, itraconazole; L-AmB, liposomal amphotericin B; PCZ, posaconazole; qd, once a day; QoE, quality of evidence; SoR, strength of recommendation; VCZ, voriconazole; yrs, years.

1326

1327 **Recommendation** - Consideration should be given to prescribe an antifungal with sufficient CNS pene-
 1328 tration. Combination therapy containing lipid formulations of AmB is moderately recommended, as is
 1329 surgery.

1330

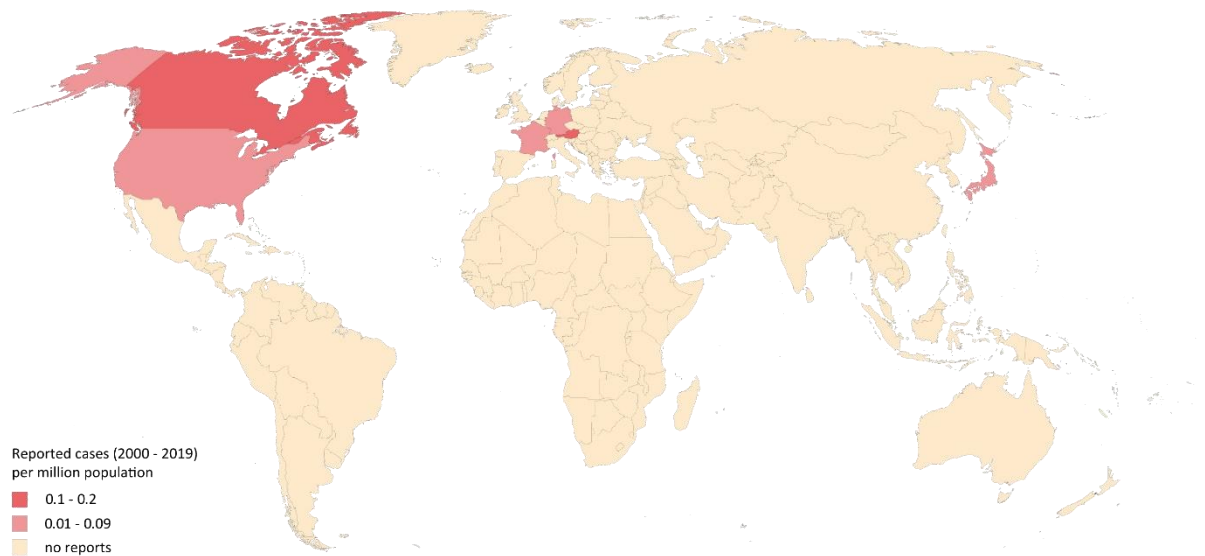
1331 5. Rasamsonia

1332 Epidemiology of infections caused by *Rasamsonia* spp.

1333 *Rasamsonia* is a new genus introduced in 2011 comprising 11 thermotolerant species that were formerly
 1334 classified in the genera *Geosmithia*, *Penicillium*, or *Talaromyces*¹⁵⁷⁶. *Rasamsonia* has rarely been reported
 1335 as the causative pathogen of fungal infections in humans, and most of these reports originate from north-
 1336 ern countries and high-resource settings¹⁰. *Rasamsonia* can colonize the respiratory tract of patients with
 1337 CF with variable clinical significance^{1577,1578}. Infections caused by *Rasamsonia argillacea* (formerly known
 1338 as *Geosmithia argillacea*), *Rasamsonia piperina* and *Rasamsonia aegroticola* have been reported mainly
 1339 in severely ill patients with chronic granulomatous disease or underlying malignancy, and those undergo-

1340 ing hematopoietic stem cell transplantation or lung transplantation^{1034,1579-1585}. Diagnosis can be mislead-
1341 ing as *R. argillacea* is morphologically similar to *Penicillium* spp. and *Paecilomyces* spp. and misidentifica-
1342 tion has been frequently reported^{1579-1581,1586}. *Rasamsonia*-related infections predominantly affect the
1343 lungs and may disseminate to adjacent organs or to the CNS^{1580,1585} (Figure 17).

1344 **Figure 17. Worldwide distribution of infections caused by *Rasamsonia* spp. (reported cases between**
1345 **2000 and 2019 per million population)**



1346
1347 Cases of severe *Rasamsonia*-related infections reported in the medical literature were identified in a Pub-
1348 Med search on November 15, 2019 using the search string “*Rasamsonia* OR *Geosmithia* OR *Penicillium*
1349 *argillaceum*” that yielded 126 publications. Twenty eight cases have been reported from six countries
1350 since 2000^{10,1034,1577,1579-1585,1587-1590}. Most cases were reported from Germany (n=8), Canada (n=7) and the
1351 United States (n=6). The number of cases reported between 2000 and 2019 is presented as cases per
1352 million population per country. The resident population per country was obtained from [www.worldome-](http://www.worldometers.info)
1353 [ters.info](http://www.worldometers.info)³²¹.

1354

1355 **Diagnosis of *Rasamsonia* infections**

1356 ***Diagnosis – Microbiology – Conventional Methods***

1357 **Evidence** - Cultures using yeast extract-peptone-dextrose agar, Sabouraud dextrose agar or potato flakes
1358 agar can achieve the highest diagnostic value for clinical samples obtained from sterile body sites. Incu-
1359 bation at 28–30°C for up to four weeks has been reported¹⁰. For superficial and respiratory tract samples,
1360 clinical signs and symptoms are important to differentiate between colonization/contamination and in-
1361 fection^{1579-1583,1586,1587,1591-1593}. Mucous sputum samples should be pretreated with a mucolytic agent be-
1362 fore culture, but these pretreatments may cause false negative GM antigen levels^{1594,1595} (**Table 26**).

1363 **Recommendation** - The guideline group strongly recommends culture from clinical samples.

1364 **Diagnosis – Microbiology – Serology**

1365 **Evidence** – GM cross-reacts with *Rasamsonia* spp. and positive results have been described from BALF
1366 and serum¹⁵⁸⁵ (**Table 26**).

1367 **Recommendations** – The guideline group moderately supports GM testing from BALF and serum.

1368 **Diagnosis – Microbiology – Molecular-based**

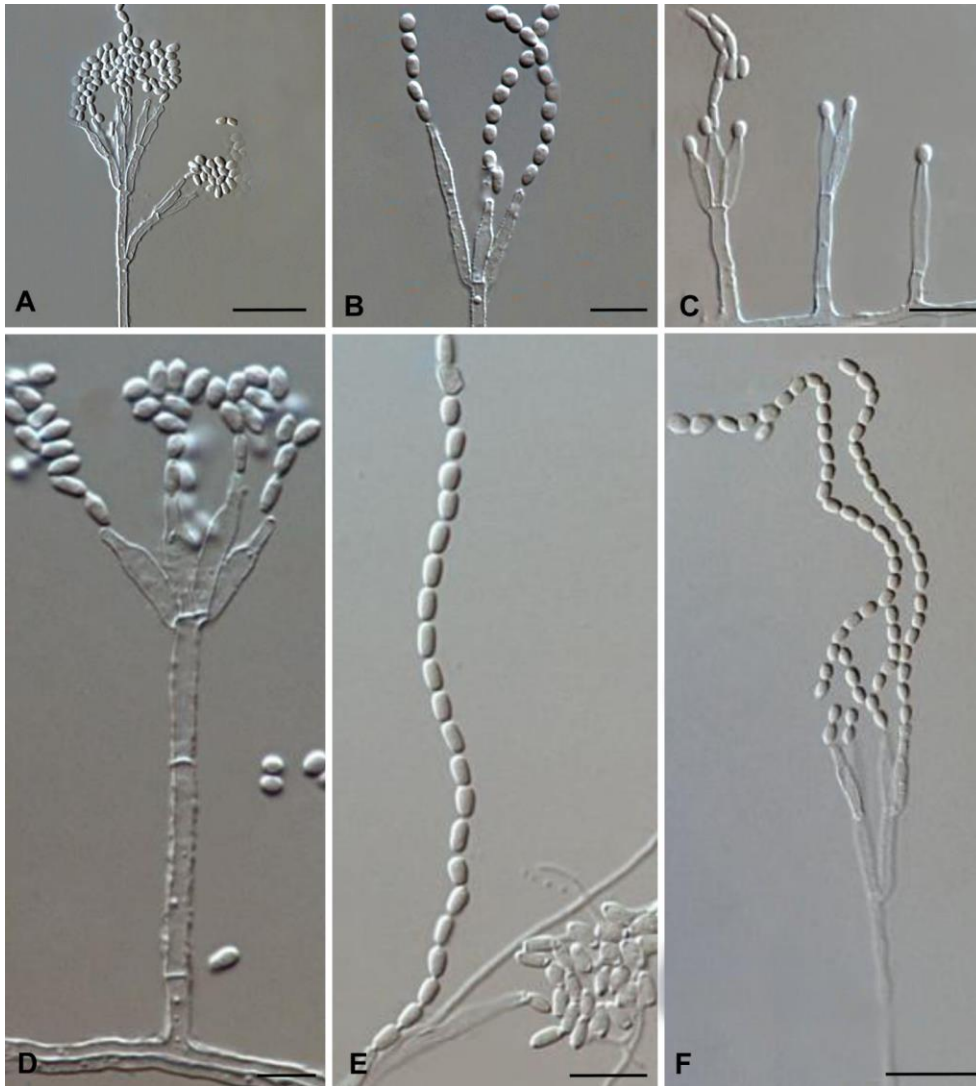
1369 **Evidence** - Direct fungal detection by real-time PCR of respiratory samples has been reported in CF pa-
1370 tients¹⁵⁹⁶ (**Table 26**).

1371 **Recommendation** - The guideline group moderately recommends specific real-time PCR for detection of
1372 *Rasamsonia* spp. in respiratory samples from CF patients.

1373 **Diagnosis – Microbiology – Species identification**

1374 **Evidence** - Identification to the genus level can be done by microscopic examination. *Rasamsonia* spp.
1375 overall resembles *Paecilomyces* spp. and *Penicillium* spp., but *Rasamsonia* spp. differs from *Paecilomyces*
1376 spp. in having more regular branched conidiophores with distinct rough-walled structures, and from *Pae-*
1377 *cilomyces* spp. and *Penicillium* spp. by the shape of the conidia which are cylindrical. See also **Figure 18**
1378 with microscopic morphology from the Atlas of Clinical Fungi project¹⁹ (**Table 26**).

1379 **Figure 18. Microscopic morphology of *Rasamsonia* spp.**¹⁹



1380
 1381 **Panel A-B**, *R. argillacea*, phialides with conidia in chains; **Panel C-D**, *Rasamsonia eburnea*, with erect co-
 1382 nidiophores and monoverticillate, later becoming biverticillate penicilli producing ellipsoidal or ovoidal,
 1383 conidia; **Panel E-F**, *R. piperina*, phialides with conidia in chains. Scale bars = 10 μ m.

1384
 1385 Accurate identification to the species level requires ITS/ β -tubulin sequencing^{555,1577,1580,1581,1591,1593,1597-1599}.
 1386 Genotyping can be achieved by repetitive sequence-based PCR and random amplification of polymorphic
 1387 DNA^{1581,1599} (**Table 26**).

1388 **Recommendation** - The guideline group strongly recommends to perform microscopy of cultures, fol-
 1389 lowed by ITS/ β -tubulin gene sequencing for species identification.

1390 **Diagnosis – Microbiology – Susceptibility testing**

1391 **Evidence** - Antifungal susceptibility testing according to EUCAST or CLSI guidelines may be useful to de-
 1392 termine susceptibilities^{1580,1583,1587,1590,1591}; however, the absence of interpretive breakpoints warrants cau-
 1393 tion when utilizing MICs to guide treatment (**Table 26**).

1394 **Recommendation** - The guideline group strongly recommends that antifungal susceptibility testing should
 1395 be performed for epidemiological purposes, while susceptibility testing to guide the choice of antifungal
 1396 therapy is moderately recommended.

1397 **Diagnosis – Microbiology – Pathology**

1398 **Evidence** - Histological examination of PAS, H&E, GMS stained tissue biopsy sections is important for as-
 1399 certaining fungal structures^{1583,1587,1593} (**Table 26**).

1400 **Recommendation** - The guideline group strongly recommends that histology should be performed when-
 1401 ever possible.

1402 **Diagnosis – Microbiology – Imaging studies**

1403 **Evidence** – Diagnostic imaging studies of the affected organ/systems (CT for thorax, CT or MRI for brain)
 1404 can delineate the extent of involvement of the infection^{1580,1582-1584,1587}. Invasion of adjacent structures as
 1405 shown by CT examination has been reported^{1580,1582-1584,1587} (**Table 26**).

1406 **Table 26. Microbiological, histopathological and imaging diagnostics for *Rasamsonia* infections**

Population	Intention	Intervention	SoR	QoE	Reference	Comment
Microscopy, culture, MIC testing						
Any	To diagnose	Histology (GMS & HE)	A	IIIu	Machouart JCM 2011 ¹⁵⁸³ Doyon JCM 2013 ¹⁵⁸⁷ Sohn ALM 2013 ¹⁵⁹³	
Any	To diagnose	Culture, SDA 28-30°C, ≤4 wk	A	IIIu	Abdolrasouli Mycoses 2018 ¹⁵⁷⁸ De Ravin CID 2011 ¹⁵⁸⁰ Doyon JCM 2013 ¹⁵⁸⁷ Hong JCF 2017 ¹⁵⁸¹ Ishiwada Mycopathol 2016 ¹⁵⁸² Machouart JCM 2011 ¹⁵⁸³ Matos Mycoses 2015 ¹⁵⁹² Sohn ALM 2013 ¹⁵⁹³	
Any with CF / chronic granulomatous disease	To diagnose	Culture – selection of YPDA, SDA, PFA	A	III	Giraud JCM 2010 ¹⁵⁹¹ Giraud FM 2013 ¹⁵⁸⁶ Babiker MMCR 2019 ¹⁵⁷⁹	
Any with CF	To diagnose	Culture, sputum with mucolytic, homogenize, serial dilution, SDA	A	IIIu	Masoud-Landgraf MedMycol 2014 ¹⁵⁹⁴	

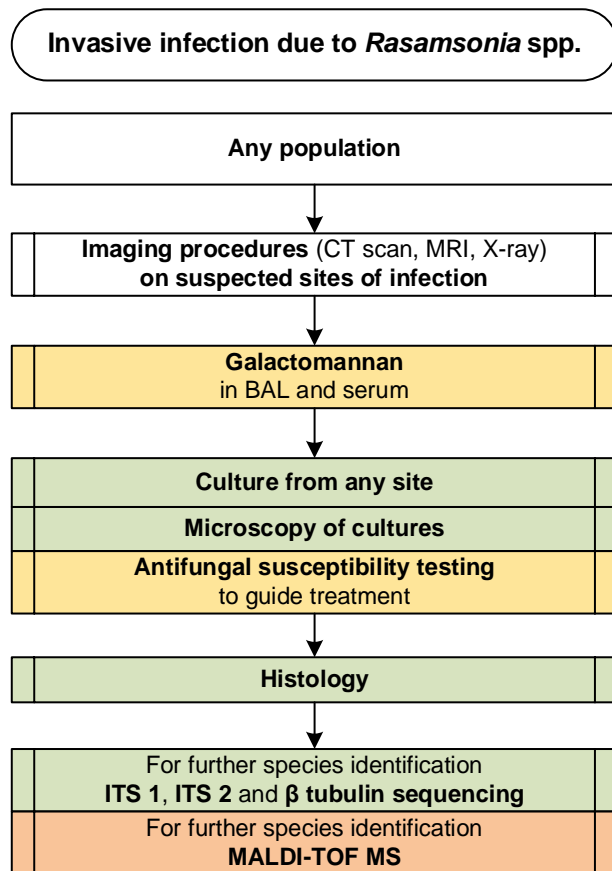
		+ 100mg/L chloramphenicol, 28-30°C, ≤4 wk			Abdolrasouli Mycoses 2018 ¹⁵⁷⁸	
Any	To diagnose	Microscopy of cultures	A	III	Hong JCF 2017 ¹⁵⁸¹ Giraud JCM 2010 ¹⁵⁹¹	
Children/neonates	To diagnose	Culture, gastric aspiration of sputum	B	III	Fujita TJEM 2019 ¹⁵⁸⁸	Acid resistant
Chronic pulmonary disease with colonization	To diagnose underlying disease	Test for CF	C	III	Grenouillet Mycopathol 2018 ¹⁶⁰⁰	Colonization indicative of CF
Any with CF	To identify susceptibility patterns	Antifungal susceptibility testing according to EUCAST or CLSI	B	III	Giraud JCM 2010 ¹⁵⁹¹ Hong JCF 2017 ¹⁵⁸¹ Doyon JCM 2013 ¹⁵⁸⁷ Machouart JCM 2011 ¹⁵⁸³ Houbraken JCM 2013 ¹⁵⁹⁸	
Any	To guide treatment	Antifungal susceptibility testing of <i>R. argillacea</i>	B	III	De Ravin CID 2011 ¹⁵⁸⁰	
Serology assays						
Any	To diagnose	GM testing (Platelia, Bio-Rad) in BAL and serum	B	III	Valentin BMT 2012 ¹⁵⁸⁵ Cumming DMID 2007 ¹⁶⁰¹ Machouart JCM 2011 ¹⁵⁸³ Sohn ALM 2013 ¹⁵⁹³	
Nucleic-acid based assays/MALDI-TOF MS						
Any	To diagnose from any sample	Molecular sequencing (ITS1, ITS2, β-tubulin),	B	III	Hong JCF 2017 ¹⁵⁸¹	
Any	To diagnose from autopsy tissue	PCR/ESI-TOF-MS	B	III	Giraud FMB 2013 ¹⁶⁰²	
CF	To detect in respiratory secretions	Real-time PCR	B	II	Steinman NMNI 2014 ¹⁵⁹⁶	Not <i>R. eburnea</i>
CF	To diagnose from sputum	Oligoarray, ITS2	C	III	Bouchara JCM 2009 ⁵⁵¹	N=20 fungal species, sens. 100% and spec. 99.2%, <i>Rasamsonia emersonii</i> included
Any	To identify	MALDI-TOF MS	C	IIIu	Barker MedMycol 2014 ¹⁵⁹⁷	Only <i>R. argillacea</i>
Any	To identify	ITS1-ITS2/beta-tubulin sequencing	A	IIu	Houbraken JCM 2013 ¹⁵⁹⁸ De Ravin CID 2011 ¹⁵⁸⁰ Hong JCF 2017 ¹⁵⁸¹ Barker MedMycol 2014 ¹⁵⁹⁷ Marguet MMCR 2012 ¹⁵⁷⁷ Sohn ALM 2013 ¹⁵⁹³ Giraud JCM 2010 ¹⁵⁹¹	
CF	To identify	Culture + ITS1-ITS2/beta-tubulin sequencing	A	III	Ziesing MedMycol 2016 ⁵⁵⁵	
Any	To identify	Morphology, molecular genetics (beta-tubulin and calmodulin genes, ITS analysis)	A	IIu	Houbraken JCM 2013 ¹⁵⁹⁸	Differs from <i>Paezilomyces</i> by more regular branching
Any with CF	To identify and genotype	Repetitive sequence-based PCR	C	III	Mouhajib JCM 2016 ¹⁶⁰³	
Any	To genotype	RAPD	C	III	Guevara-Suarez JCM 2016 ¹⁶⁰⁴	
Tissue-based diagnosis						
Any	To diagnose	Histology; PAS, HE, GMS stainings	A	III	Hong JCF 2017 ¹⁵⁸¹ Machouart JCM 2011 ¹⁵⁸³	
Any with CF	To establish definitive diagnosis	Autopsy	A	III	Hong JCF 2017 ¹⁵⁸¹ Valentin BMT 2012 ¹⁵⁸⁵	
Imaging studies						
Any with CGD	To detect	Chest CT	A	III	De Ravin CID 2011 ¹⁵⁸⁰	N=5
Any	To detect contiguous spread & dissemination	Chest CT, cranial CT	A	III	De Ravin CID 2011 ¹⁵⁸⁰ Ocak RCR 2019 ¹⁵⁸⁴ Doyon JCM 2013 ¹⁵⁸⁷ Ishiwada Mycopathol 2016 ¹⁵⁸² Machouart JCM 2011 ¹⁵⁸³	

Amb, amphotericin B; BAL, bronchoalveolar lavage; CF, cystic fibrosis; CGD, chronic granulomatous disease; CLSI, Clinical and Laboratory Standards Institute; CT, computed tomography; ESI-TOF MS, Electrospray Ionization time of flight mass spectrometry; EUCAST, European Committee for Antimicrobial Susceptibility Testing; GM, Galactomannan; GMS, Grocott-Gomori's methenamine silver; HE, hematoxylin-eosin; ICZ, itraconazole; ITS, internal transcribed spacer; MALDI-TOF MS, matrix assisted laser desorption ionization-time of flight mass spectrometry; MIC, mini-

mal inhibitory concentration; PAS, periodic acid-Schiff; PCR, polymerase chain reaction; PCZ, posaconazole; PFA, potato flakes agar; QoE, quality of evidence; SDA, Sabouraud Dextrose agar; SoR, strength of recommendation; TRB, terbinafine; VCZ, voriconazole; wk, week(s); YPDA, yeast extract-peptone-dextrose agar.

1407
 1408 **Recommendation** - The guideline group strongly recommends performing radiological examinations to
 1409 delineate the extent of involvement of the infection (**Figure 19**).

1410
 1411 **Figure 19. Optimal diagnostic pathway for *Rasamsonia* infections, when all imaging and assay tech-**
 1412 **niques are available**



Legend:

strongly recommended	
moderately recommended	
marginally recommended	
recommended against	

BAL, bronchioalveolar lavage; CT, computed tomography; ITS, internal transcribed spacer; MALDI-TOF MS, matrix-assisted laser desorption/ionization time-of-flight mass spectrometry; MRI, magnetic resonance imaging

1414

1415 **Treatment approaches to *Rasamsonia* infections**

1416 Treatment in Adults

1417 **Evidence** - Evidence for the treatment of invasive infections due to *Rasamsonia* spp. is sparse, with cur-
 1418 rently only 23 cases available in the literature¹⁰. Colonization, specifically in CF patients, was reported
 1419 much more frequently. However, mortality reaches upwards of 40% in invasive infections, so treatment
 1420 should not be delayed for this significant pathogen¹⁰. Overall, high MICs have been reported for triazoles,
 1421 while echinocandins show best *in vitro* susceptibility^{1577,1579-1583,1585,1587,1590}. CASPO and MICA have been
 1422 used successfully^{1579,1584,1587,1605}; successful use of combination therapy with an echinocandin plus PCZ or
 1423 L-AmB has also been reported^{1579,1584,1605}. Surgery is another important cornerstone of treatment of local-
 1424 ized infections^{1579,1580,1587}. Secondary prophylaxis with PCZ has been reported^{1577,1580,1583,1587} (**Table 27**).

1425 **Table 27. Therapy for *Rasamsonia* infections**

Population	Intention	Intervention	SoR	QoE	Reference	Comment
First-line antifungal therapy						
Any, any with CGD	To cure and avoid treatment failure/death	Avoid azole mono-therapy	A	Ilu	De Ravin CID 2011 ¹⁵⁸⁰	Azoles lead mostly to failure, MICs VCZ and occasional ICZ >8-16, PCZ usually >4
					Marguet MMCR 2012 ¹⁵⁷⁷	
					Machouart JCM 2011 ¹⁵⁸³	
					Valentin BMT 2012 ¹⁵⁸⁵	
					Doyon JCM 2013 ¹⁵⁸⁷	
					Ishiwada Mycopathol 2016 ¹⁵⁸²	
					Hong JCF 2017 ¹⁵⁸¹	
Babiker MMCR 2019 ¹⁵⁷⁹	<i>in vitro</i> study in CF; Echinocandins with highest activity; resistance to azoles					
Steinmann AAC 2016 ¹⁵⁹⁰						
Any	To cure	CASPO OR MICA +/- PCZ	B	III	Abdolrasouli Mycoses 2018 ¹⁵⁷⁸	N=1, CF, response to CASPO
					Doyon JCM 2013 ¹⁵⁸⁷	N=1, MICA + PCZ, response
HSCT with GVHD	To cure	CASPO + L-AmB +/- PCZ	B	III	Valentin BMT 2012 ¹⁵⁸⁵	N=1, initial response, then deterioration; died
					Ocak RCR 2019 ¹⁵⁸⁴	N=1, partial clinical response
HSCT	To cure	L-AmB	C	III	Corzo-Leon Mycoses 2015 ¹⁰³⁴	N=1, died
Antifungal salvage treatment						
Any with CF	To cure	Echinocandin	C	III	Abdolrasouli Mycoses 2018 ¹⁵⁷⁸	N=1, clinical stable
Any with CGD	To cure	Empirical treatment with PCZ, L-AmB and CASPO	C	III	Ocak RCR 2019 ¹⁵⁸⁴	
					Babiker MMCR 2019 ¹⁵⁷⁹	
Other treatment options						
Any with CGD	To cure	Surgery	B	III	De Ravin CID 2011 ¹⁵⁸⁰	N=4, 1/4 died
					Babiker MMCR 2019 ¹⁵⁷⁹	N=1, success
Immunocompetent	To cure	Surgery / resection of infected (graft) material	B	III	Doyon JCM 2013 ¹⁵⁸⁷	N=1, success
Treatment duration						
Any with CGD	To cure	Prolonged treatment / Secondary prophylaxis	B	Ilu	Machouart JCM 2011 ¹⁵⁸³	N=9, 5/9 survived, 4/9 prolonged treatment/secondary prophylaxis up to 6 yrs
					De Ravin CID 2011 ¹⁵⁸⁰	

Immunocompetent	To cure	Prolonged treatment / Secondary prophylaxis	B	III	Doyon JCM 2013 ¹⁵⁸⁷	N=1, 13 mo of PCZ, success
Standard dose unless stated otherwise; CASPO, caspofungin; CF, cystic fibrosis; CGD, chronic granulomatous disease; GVHD, graft-versus-host disease; HSCT, hematopoietic stem cell transplantation; ICZ, itraconazole; L-AmB, liposomal amphotericin B; MICA, micafungin; mo, months; PCZ, posaconazole; QoE, quality of evidence; SoR, strength of recommendation; TRB, terbinafine; VCZ, voriconazole.						

1426

1427 **Recommendations** - The guideline group strongly recommends to avoid azole monotherapy due to re-

1428 ports of clinical failure and high MICs. The guideline group moderately recommends primary treatment

1429 with an echinocandin, or a combination of an echinocandin with either L-AmB or PCZ. Surgery, when-

1430 ever possible is moderately recommended for treatment of *Rasamsonia* infections. Treatment duration

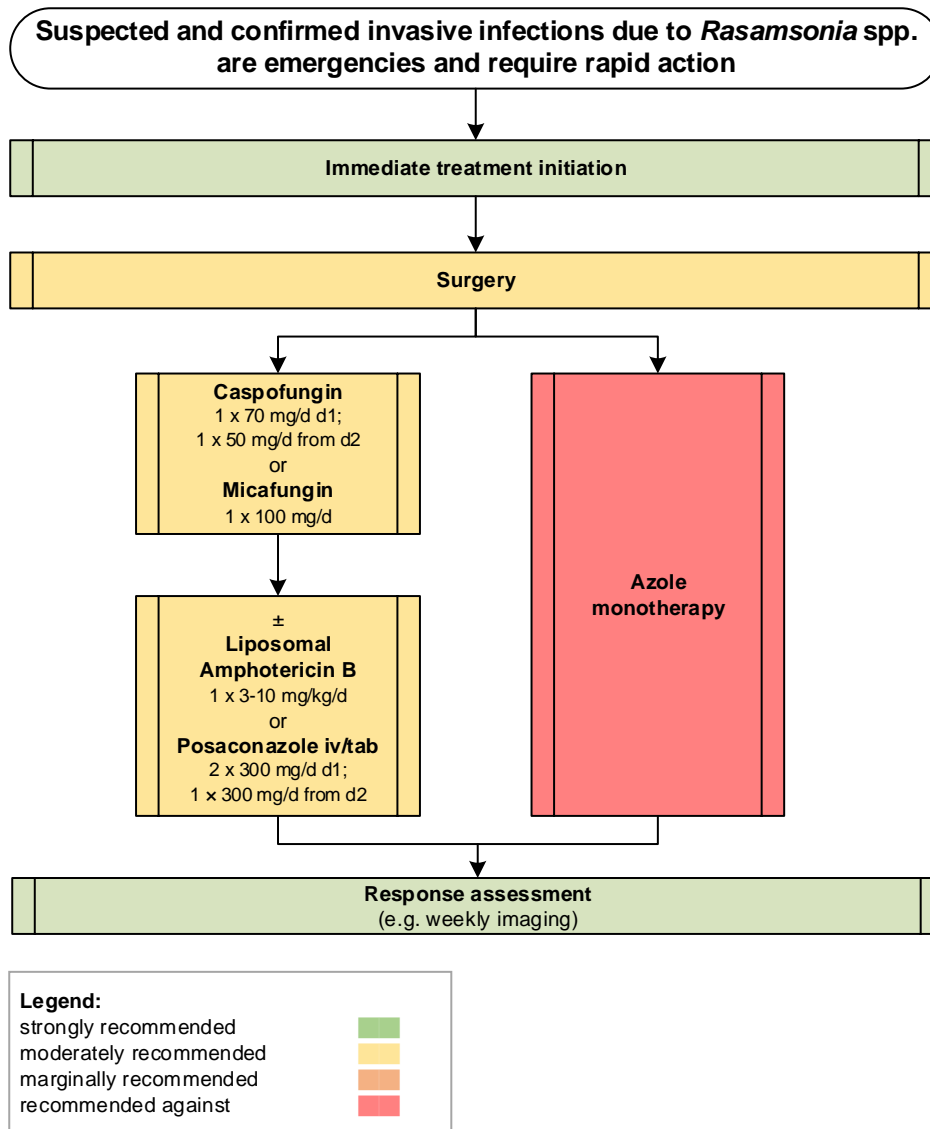
1431 depends on the affected site, clinical response and underlying condition but can be up to several

1432 months. Secondary prophylaxis is moderately recommended (**Figure 20**).

1433

1434 **Figure 20. Optimal treatment pathway for *Rasamsonia* infections in adults when all treatment modali-**

1435 **ties and antifungal drugs are available**



1436

1437 **Specific considerations on treatment of *Rasamsonia* infections in children**

1438 **Evidence** – Invasive infections caused by *Rasamsonia* spp. have been described as a complication occur-
 1439 ring in children with CGD¹⁵⁸⁰. Breakthrough infections while on mold-active azole prophylaxis have been
 1440 reported, but treatment with MICA has been associated with favorable outcome^{1402,1580,1588} (**Table 28**).

1441

1442 **Table 28. First-line antifungal therapy in children for *Rasamsonia* infections**

Population	Intention	Intervention	SoR	QoE	Reference	Comment
Any with CGD	To cure	MICA+VCZ	B	III	Ishiwada Mycopathol 2015 ¹⁵⁸²	N=1, 16 yrs, mixed infection with <i>Aspergillus nidulans</i>
Any	To cure	MICA	B	III	Fujita TJEM 2019 ¹⁵⁸⁸	N=3 CGD, 3/3 survived;
					De Ravin CID 2011 ¹⁵⁸⁰	
					Tanuskova JMM 2017 ¹⁴⁰²	N=1 Allo SCT; survived
Any with CF	To cure and improve lung function	Secondary prophylaxis	B	III	Marguet MMCR 2012 ¹⁵⁷⁷	N=1, long-term prophylaxis with PCZ + intermittent echinocandin improved FEV1

Standard pediatric dose unless stated otherwise; CF, cystic fibrosis; CGD, chronic granulomatous disease; d, day(s); FEV1, forced expiratory volume in one second; iv, intravenous; MICA, micafungin; po, orally; QoE, quality of evidence; SoR, strength of recommendation; VCZ, voriconazole; wk, week(s); yrs, years.

1443

1444 **Recommendations** – Echinocandins with or without another antifungal are moderately recommended as

1445 first-line treatment in children, in line with recommendations in adults. Triazole monotherapy should be

1446 avoided. Surgery is moderately recommended if feasible and infection is not disseminated.

1447

1448 **6. *Schizophyllum* and other basidiomycetes**

1449 **Epidemiology of infections caused by *Schizophyllum* spp. and other basidiomycetes**

1450 Basidiomycetes, such as *Schizophyllum commune*, *Coprinopsis cinerea* (formerly *Hormographiella asper-*

1451 *gillata*) and *Phanerochaete chrysosporium* (formerly *Sporotrichum pruinosum*) are often found in decay-

1452 ing matter. Despite their worldwide distribution invasive infections due to these fungal agents are rare.

1453 In humans, *S. commune* accounts for the majority of infections caused by these organisms, the vast ma-

1454 jority of which presents as pulmonary disease or sinusitis¹⁶⁰⁶⁻¹⁶¹⁰. *C. cinerea* is the second most prevalent

1455 basidiomycete causing mainly infections of the lung^{1611,1612}. Eye infections have also been identified¹⁶¹³⁻

1456 ¹⁶¹⁵. There are only few reports of infections affecting other organs such as brain, spine or peritoneum¹⁶¹⁶⁻

1457 ¹⁶¹⁸. Fungemia is uncommon^{1619,1620}.

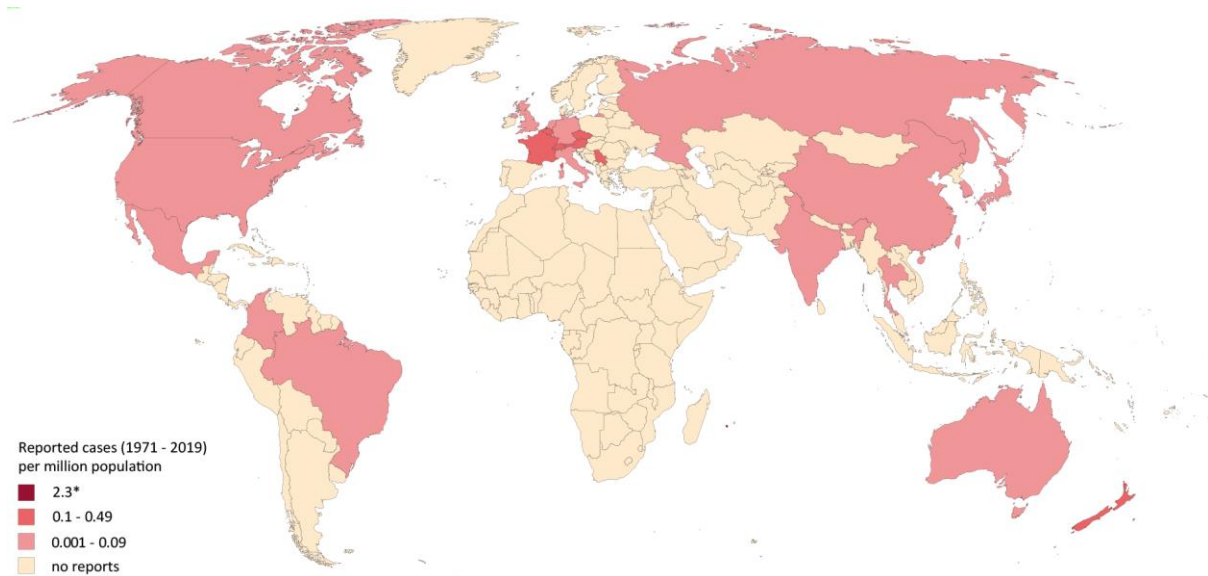
1458 Co-infection with other molds has often been reported, possibly because affected patients are critically ill

1459 or severely immunocompromised and thus are susceptible to concomitant infections¹⁶¹¹.

1460 True prevalence of these infections is likely underestimated, as microbiological methods of species iden-

1461 tification are rather difficult due to lack of asexual reproduction¹⁶²¹ (**Figure 21**).

1463 **Figure 21. Worldwide distribution of infections caused by *Schizophyllum* spp. and other basidiomycetes (reported cases between 1971 and 2019 per million population)**
 1464



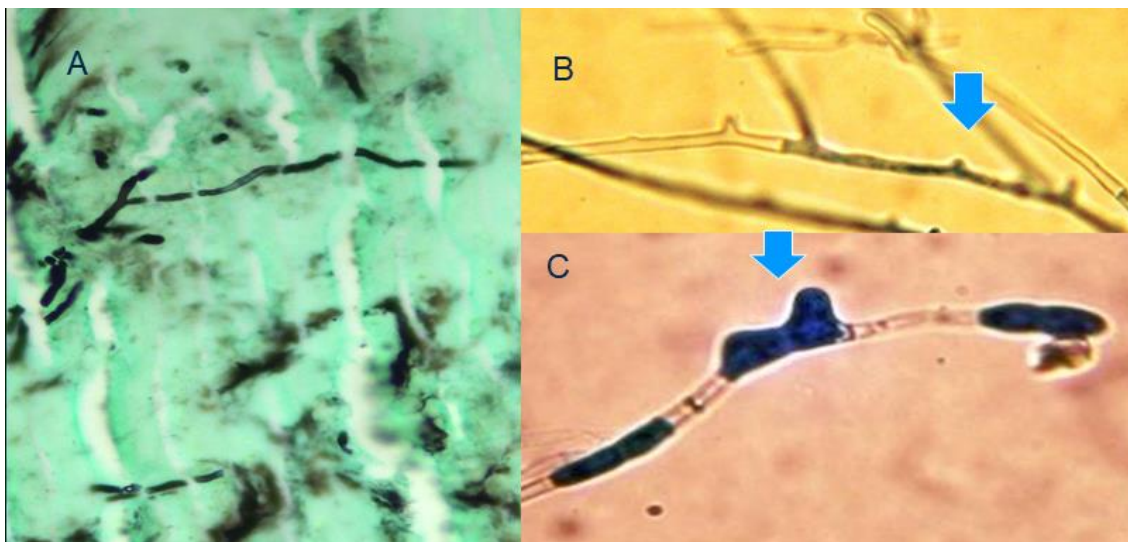
1465
 1466
 1467 Cases of infections caused by *Schizophyllum*, *Coprinopsis* and other basidiomycetes reported in the med-
 1468 ical literature were identified in a PubMed search on October 15, 2019 using the search string “(*Trametes*
 1469 *OR Lenzites OR Lophotrichus OR Schizophyllum OR Ustilago OR Coprinus OR Coprinopsis OR Hormographi-*
 1470 *ella aspergillata OR C. cinereus)* AND (infection OR case report OR report [title/abstract] OR case [title/ab-
 1471 stract] OR abscess OR fungemia OR blood OR invasive)” excluding reports on plants and animals that
 1472 yielded 748 publications. Reports of 103 cases of rare basidiomycetes-related infections have been iden-
 1473 tified from 27 countries, 88 since the year 2000^{239,1034,1116,1209,1606,1607,1609,1611-1674}. *S. commune* and *C. cinerea*
 1474 accounted for 73% of the cases. Infections due to *P. chrysosporium*, *Schizophyllum radiatum*, *Ustilago* spp.
 1475 and other basidiomycetes were found sporadically in the literature. Most cases were reported from the
 1476 United States (n=11) and India (n=6). In Singapore and Hong Kong one case each has been reported since
 1477 1971. The number of cases reported between 1971 and 2019 is presented as cases per million population
 1478 per country. The resident population per country was obtained from www.worldometers.info³²¹. *Two
 1479 cases of infections caused by *Trametes polyzona* were reported from La Réunion (2.3 cases per million
 1480 population between 1971 and 2019)¹⁶³⁹.

1482 **Diagnosis of infections caused by *Schizophyllum* and other basidiomycetes**

1483 **Diagnosis – Microbiology – Conventional Methods**

1484 **Evidence** – Culture is mandatory for species identification and antifungal susceptibility testing, but many
1485 basidiomycetes are sterile and do not sporulate in the laboratory¹⁶²¹. In microscopy the hyphal clamp
1486 connections with spicules suggest *S. commune*¹⁶⁰⁹. See also **Figure 22** and **Figure 23** for microscopic mor-
1487 phology from the Atlas of Clinical Fungi project¹⁹.

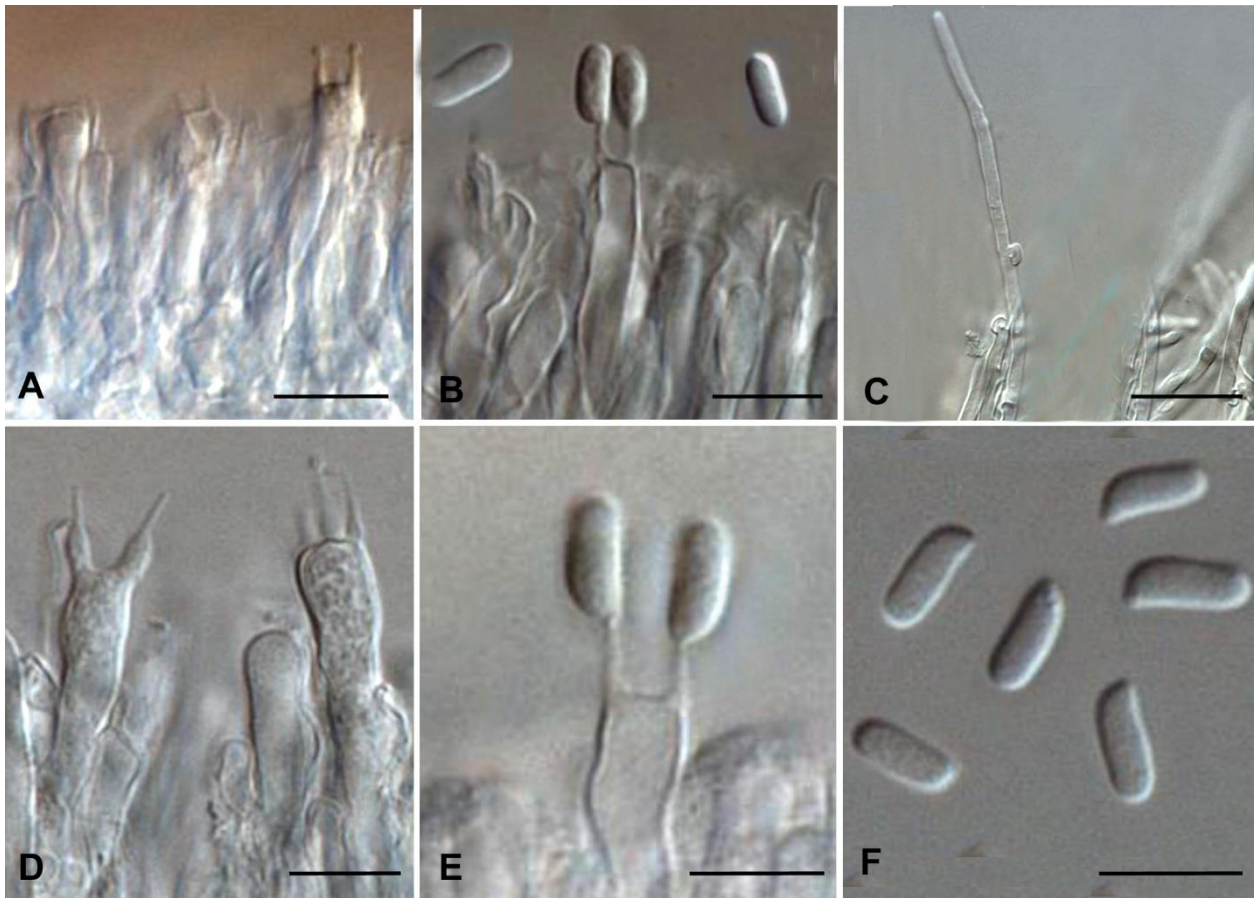
1488 **Figure 22. Microbiological characteristics of *S. commune* (owned by co-author V. Arsic-Arsenjevic)**



1489
1490 **Panel A**, GMS stain; **Panel B-C**, Spicula (blue arrows) in lactophenol cotton blue stain, microscopy x 400
1491 and x 1000.

1492

1493 **Figure 23. Microscopic morphology of *Schizophyllum* spp.**¹⁹



1495
 1496 **Panels A-C, *S. commune***, palisade of basidia located on the gills, basidiospores, hyphae with clamp con-
 1497 nections. **Panels D-F, *S. radiatum***, basidia producing basidiospores and basidiospores. Scale bars = 10 μ m.

1498

1499 For non-sterile samples, such as respiratory tract specimens, distinguishing among genuine infection, col-
 1500 onization, and contamination is important (**Table 29**).

1501 **Recommendation** - The guideline group strongly recommends that tissue microscopy and culture should
 1502 be performed when possible.

1503

1504 **Diagnosis – Microbiology – Serology**

1505 **Evidence** – In general, basidiomycetes lack GM and BDG in their cell walls, but cases with elevated BDG
1506 have been reported^{1646,1675-1677}. A positive GM test may suggest co-infection with *Aspergillus* spe-
1507 cies^{1612,1644,1646,1665,1675,1676}. *S. commune* infection may lead to false-positive cryptococcal antigen testing
1508 and may result in misdiagnosis¹⁶³¹ (**Table 29**).

1509 **Recommendation** – Serological testing is not recommended as part of the diagnostic evaluation for infec-
1510 tions caused by *Schizophyllum* and other basidiomycetes.

1511

1512 **Diagnosis – Microbiology – Molecular-based**

1513 **Evidence** – PCR sequencing of cultured strains and of formalin-fixed paraffin-embedded tissue samples
1514 can be useful for detection of basidiomycetes such as *H. aspergillata* and *Phellinus undulatus*¹⁶⁴¹ (**Table**
1515 **29**).

1516 **Recommendation** - The guideline group moderately recommends PCR from formalin-fixed paraffin-em-
1517 bedded tissue samples.

1518

1519 **Diagnosis – Microbiology – Species identification**

1520 **Evidence** – Definite identification requires PCR of fungal isolates followed by ITS and/or D1/D2 sequencing
1521 for this heterogeneous group of fungi^{1606,1609,1613,1641,1644,1646,1665,1666,1672,1673,1675-1679}. MALDI-TOF MS has
1522 been reported to be useful for identification of *S. commune*¹⁶⁰⁶ (**Table 29**).

1523 **Recommendation** – While species identification of basidiomycetes may be difficult due to incomplete
1524 public databases and rareness of reference strains the guideline group strongly recommends that ITS
1525 and/or D1/D2 sequencing should be performed on the culture isolate for species identification, and mar-
1526 ginally recommends MALDI-TOF MS for the same purpose.

1527

1528 **Diagnosis – Microbiology – Susceptibility testing**

1529 **Evidence** – Antifungal susceptibility testing is useful to determine susceptibilities^{1646,1680-1682}; however, the
1530 absence of interpretive breakpoints warrants caution when utilizing MICs to guide treatment (**Table 29**).

1531 **Recommendation** - The guideline group strongly recommends that antifungal susceptibility testing should
1532 be performed for identifying susceptibility patterns, while susceptibility testing to guide the choice of an-
1533 tifungal therapy is moderately suggested.

1534

1535 **Diagnosis –Pathology**

1536 **Evidence** – Histological examination of PAS and/or GMS stained tissue biopsy sections are important for
1537 ascertaining fungal invasion, but are often inconclusive and may confound basidiomycetes with *Aspergil-*
1538 *lus* spp.^{1613,1627,1634,1641,1646,1666,1672,1675,1676,1679} (**Table 29**).

1539 **Recommendation** – The guideline group moderately recommends that histopathology should be per-
1540 formed when possible.

1541

1542 **Diagnosis – Microbiology – Imaging studies**

1543 **Evidence** – Most diagnostic imaging studies involve infections caused by *Hormographiella* spp.. CT scan is
1544 useful to detect pulmonary and sino-orbito-cerebral infections¹⁶⁴¹ and MRI has been used to detect CNS
1545 involvement^{1641,1677} (**Table 29**).

1546

1547
1548

Table 29. Microbiological, histopathological and imaging diagnostics of infections caused by *Schizophyllum* spp. and other basidiomycetes

Population	Intention	Intervention	SoR	QoE	Reference	Comment
Microscopy, culture, MIC testing						
Any	To diagnose	Microscopy of tissue biopsy	A	III	Chowdhary JCM 2013 ¹⁶³² Hoeningl Mycoses 2013 ¹⁶⁰⁹ Saha Mycopathol 2013 ¹⁶¹⁴ Toya IJH 2013 ¹⁶⁸³ De Ravin JCM 2014 ¹⁶⁷⁹ Verma Mycopathol 2014 ¹⁶⁸⁴ Shigemura Infection 2015 ¹⁶⁷⁶ Lim AJD 2017 ¹⁶⁸⁵ Jain JMM 2019 ¹⁶¹³ Nanno TID 2016 ¹⁶⁴⁶	Observation of tissue invasion by fungi. No definite identification of species provided. Occasionally spicules on the hyphae may be seen in biopsy samples from lung and sinuses. Culture and identification are mandatory for species identification.
Any	To diagnose	Culture	A	III	Friman SJID 2006 ¹⁶⁸⁶ Chowdhary JCM 2013 ¹⁶³² Hoeningl Mycoses 2013 ¹⁶⁰⁹ Saha Mycopathol 2013 ¹⁶¹⁴ Toya IJH 2013 ¹⁶⁸³ Chan JCM 2014 ¹⁶³¹ De Ravin JCM 2014 ¹⁶⁷⁹ Verma Mycopathol 2014 ¹⁶⁸⁴ Shigemura Infection 2015 ¹⁶⁷⁶ Hardin Mycopathol 2017 ¹⁶⁴⁰ Lim AJD 2017 ¹⁶⁸⁵ Heiblig Mycoses 2015 ¹⁶⁴¹ Surmont MedMycol 2002 ¹⁶⁶⁶	Always need to distinguish between genuine infection, colonization and contamination specifically in respiratory specimens. Other molds co-exist in respiratory specimens culture. Multiple cultures may be necessary. Complementary with tissue biopsy. Basidiomycete colonies in culture are white cottony to fluffy, fast-growing, with yellow-brown reverse. Basidiomycetes are sensitive to cycloheximide, allowing them to be distinguished from <i>Coccidioides</i> spp. Many basidiomycetes are sterile and will not sporulate in the laboratory, although some develop clamp connections or spicules on the hyphae, and some isolates may produce basidiocarps (after exposure of the culture plate to alternating cycles of light and darkness). Definitive species identification requires ITS and or LSU sequencing
Any	To diagnose <i>S. commune</i>	Morphology	C	IIIu	Michel MedMycol 2016 ¹⁶⁰⁶	Fungus usually does not sporulate under classical culture conditions
Any	To guide treatment and correlate MICs with outcome for basidiomycetes	Antifungal susceptibility testing with CLSI method	Bu	IIIu	Singh JCM 2013 ¹⁶⁶⁰	MIC AmB < 1 µg/ml, VCZ < 0.25 µg/ml
Any	To determine MICs of <i>S. commune</i> , <i>Bjerkandera adusta</i> and <i>Coprinus</i> spp.	Antifungal susceptibility testing	A	IIu	Gonzalez AAC 2001 ¹⁶⁸⁰	MIC90 AmB 0.5 µg/ml, ICZ 0.125 µg/ml, PCZ 0.5 µg/ml, VCZ 0.5 µg/ml for <i>S. commune</i> , <i>Bjerkandera adusta</i> and <i>Coprinus</i> spp., FCZ and 5-FC higher MIC90 but within achievable concentrations in serum
Any	To determine MICs of <i>C. cinerea</i> (formerly <i>H. aspergillata</i>) and <i>Coprinellus domesticus</i> (formerly <i>Hormographiella verticillata</i>).	Antifungal susceptibility testing	A	IIu	Gené AVL 1996 ¹⁶⁸⁷ Verweij JCM 1997 ¹⁶⁷² Nanno TID 2016 ¹⁶⁴⁶ Abuali JCM 2009 ¹⁶²³	MICs miconazole 0.6 to 5.0 µg/ml, ICZ 0.07 to 0.6 µg/ml, and KCZ 0.2 to 1.6 µg/ml. Resistant to FCZ 20 to 80 µg/ml and 5-FC 322 to 0.322 µg/ml, susceptibility to AmB variable 0.07 to 4.6 µg/ml. All strains of <i>C. domesticus</i> susceptible to AmB; 4/7 of <i>C. cinerea</i> resistant 2.3 to 4.6 µg/ml N=1, <i>C. cinerea</i> , resistant to echinocandins and AmB, but susceptible to azoles
Any	To determine MICs of <i>S. commune</i>	Antifungal susceptibility testing	A	IIu	Chowdhary AAC 2013 ¹⁶⁸¹	Low geometric mean MICs of AmB 0.29 µg/ml, ISA 0.19 µg/ml, ICZ 0.2 µg/ml, VCZ 0.24 µg/ml, High geometric mean MICs of FCZ 19.39 µg/ml and 5-FC

						17.28 g/ml. 5/8 cases of ABPM treated with ICZ had no recrudescence
Any	To determine MICs of <i>S. commune</i> + <i>S. radiatum</i>	Antifungal susceptibility testing	A	IIu	Siqueira JCM 2016 ¹⁶⁶²	Geometric mean MICs AmB 0.29 µg/ml, CFG 0.58 µg/ml and TBF 0.79 µg/ml, ICZ 1.67 µg/ml and PCZ 2.93 µg/ml. <i>S. radiatum</i> showed higher GM MICs for all the antifungals than <i>S. commune</i> , especially for ICZ and PCZ
Any	To determine MICs of <i>Inonotus/Phellinus</i> spp.	Antifungal susceptibility testing, E-test	A	III	Davis PIDJ 2007 ¹⁶³⁴ Sutton JCM 2005 ¹⁶⁶⁷ Ramesh JCI 2014 ¹⁶⁸²	Case reports
Serology assays						
Any	To diagnose	GM	D	III	Suarez JCM 2011 ¹⁶⁶⁵ Lagrou JMM 2005 ¹⁶⁴⁴ Nanno TID 2016 ¹⁶⁴⁶ Godet Mycopathol 2017 Haidar Mycoses 2017 ¹⁶⁷⁵ Shigemura Infection 2015 ¹⁶⁷⁶	Not used for detecting invasive infection with basidiomycetes. Positive GM can suggest co-infection with <i>Aspergillus</i> spp.; ELISA cross-reactivity with <i>C. cinerea</i> or <i>Inonotus/Phellinus</i> spp. cannot be excluded
Any	To diagnose	BDG	D	III	Chauhan LabMed 2017 ¹⁶¹⁶ Nanno TID 2016 ¹⁶⁴⁶ Haidar Mycoses 2017 ¹⁶⁷⁵ Shigemura Infection 2015 ¹⁶⁷⁶ Koncan JMBT 2016 ¹⁶⁸⁸	N=3 with elevated BDG, but in general basidiomycetes lack GM and BDG in their cell walls
<i>S. commune</i> empyema thoracis	To diagnose	Cryptococcal Ag latex agglutination	D	III	Chan JCM 2014 ¹⁶³¹	Cross-reactivity with <i>Cryptococcal</i> antigen test leading to misdiagnosis
Nucleic-acid based assays/MALDI-TOF MS						
Any	To diagnose <i>C. cinerea</i>	PCR	B	III	Heiblig Mycoses 2015 ¹⁶⁴¹	PCR from formalin-fixed paraffin-embedded tissue samples. Described for <i>C. cinerea</i> .
Any	To identify <i>S. commune</i>	MALDI-TOF MS	C	III	Michel MedMycol 2016 ¹⁶⁰⁶	Homemade reference spectra library must be used
Any	To identify <i>S. commune</i>	ITS sequencing	A	IIu	Won ALM 2012 ¹⁶⁸⁹ Michel MedMycol 2016 ¹⁶⁰⁶ Buzina JCM 2001 ¹⁶⁷⁸	
Any	To identify <i>Hormographiella</i> spp.	ITS sequencing	A	III	Verweij JCM 1997 ¹⁶⁷² Lagrou JMM 2005 ¹⁶⁴⁴ Suarez JCM 2011 ¹⁶⁶⁵ Jain JMM 2019 ¹⁶¹³ Nanno TID 2016 ¹⁶⁴⁶ Correa Martinez NMI 2017 ¹⁶⁹⁰ Heiblig Mycoses 2015 ¹⁶⁴¹ Surmont MedMycol 2002 ¹⁶⁶⁶ Chauhan LabMed 2019 ¹⁶¹⁶	N=10, all case reports
Any	To identify <i>Hormographiella</i> spp.	D1/D2 sequencing	A	III	Nanno TID 2016 ¹⁶⁴⁶	
Any	To identify <i>Inonotus/Phellinus</i> spp.	ITS, D1/D2 sequencing	B	III	De Ravin JCM 2014 ¹⁶⁷⁹ Haidar Mycoses 2017 ¹⁶⁷⁵ Shigemura Infection 2015 ¹⁶⁷⁶ Williamson JMM 2011 ¹⁶⁷³	Case reports, species identification difficult besides sequencing due to incomplete public database/small amount of reference strains
Tissue-based diagnosis						
All	To diagnose	Histopathology of biopsy tissue; PAS and GMS stainings	C	III	Bojic Mycoses 2013 ¹⁶²⁷ Jain JMM 2019 ¹⁶¹³ Nanno TID 2016 ¹⁶⁴⁶ Verweij JCM 1997 ¹⁶⁷² Correa Martinez NMI 2017 ¹⁶⁹⁰ Heiblig Mycoses 2015 ¹⁶⁴¹ Surmont MedMycol 2002 ¹⁶⁶⁶	<i>Hormographiella</i> spp.: microscopic examination often inconclusive, only suggestive, may confound with <i>Aspergillus</i> spp.

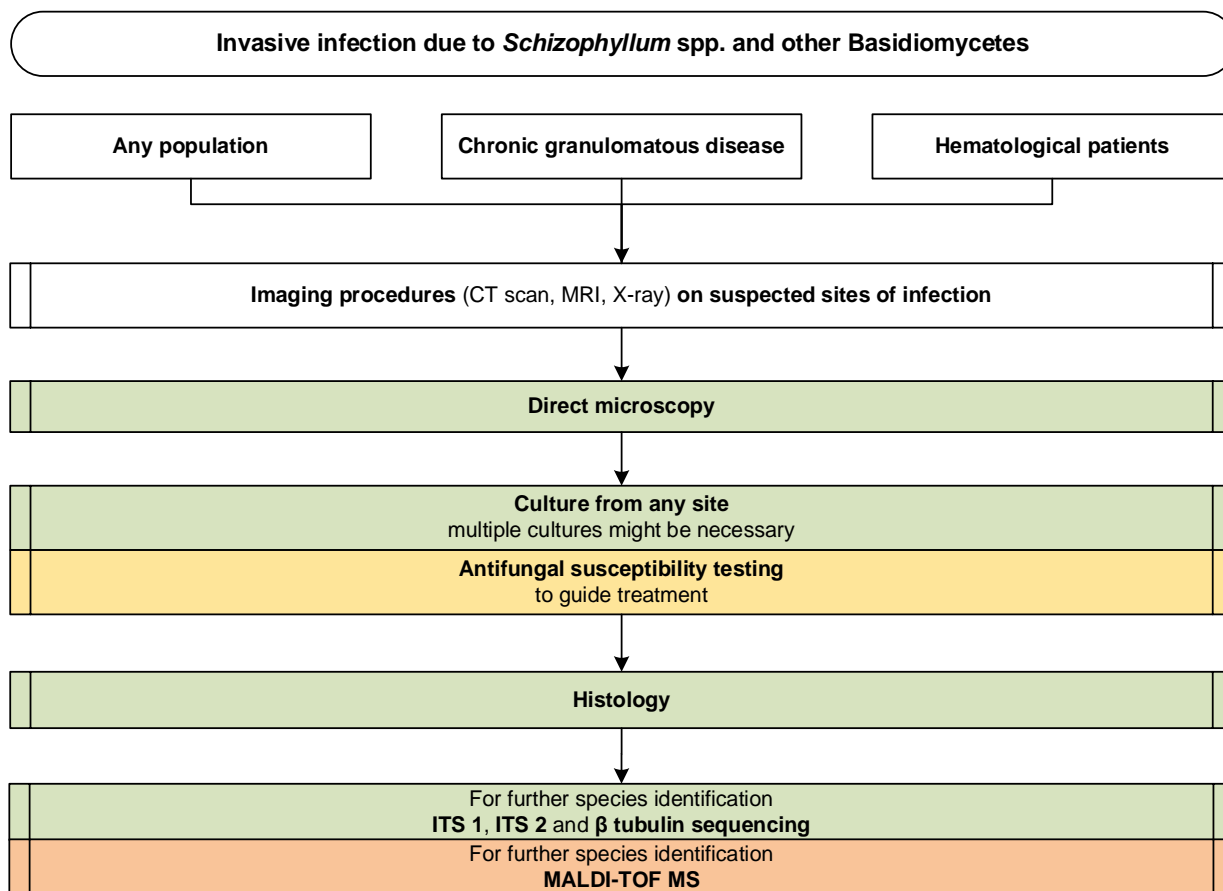
Any	To diagnose	Microscopy of tissue biopsy	A	III	Chowdhary JCM 2013 ¹⁶³²	Observation of tissue invasion by fungi. No definite identification of species provided. Occasionally spicules on the hyphae may be seen in biopsy samples from lung and sinuses. Culture and identification are mandatory for species identification.
Hematological/allogeneic SCT patients with respiratory symptoms or persistent neutropenic fever	To diagnose	Lung biopsy with histopathology (bronchoscopic or transthoracic)	A	III	Nanno TID 2016 ¹⁶⁴⁶ Surmont MedMycol 2002 ¹⁶⁶⁶	
Any with CGD	To diagnose	Biopsy of inflamed tissue with histopathology and stainings	C	III	Davis PIDJ 2007 ¹⁶³⁴ De Ravin JCM 2014 ¹⁶⁷⁹ Haidar Mycoses 2017 ¹⁶⁷⁵ Shigemura Infection 2015 ¹⁶⁷⁶	Case reports
Imaging studies						
Hematological/allogeneic SCT patients with respiratory symptoms or persistent neutropenic fever	To detect pulmonary infection and assess imaging characteristics of <i>Hormoglyphiella</i> spp. infection	Chest (HR-) CT	A	III	Suarez JCM 2011 ¹⁶⁶⁵ Bojic Mycoses 2013 ¹⁶²⁷ Lagrou JMM 2005 ¹⁶⁴⁴ Nanno TID 2016 ¹⁶⁴⁶ Godet Mycopathol 2017 ¹⁶¹²	N=5
Hematological/allogeneic SCT patients	To detect sino-orbito-cerebral infection and assess imaging characteristics of sinusitis caused by <i>Hormoglyphiella</i> spp.	CT Sinuses	A	III	Heiblig Mycoses 2015 ¹⁶⁴¹	Case report
Hematological patients with neurologic symptoms/seizures	To detect CNS involvement of <i>Hormoglyphiella</i> spp. infection	MRI	A	III	Chauhan LabMed 2019 ¹⁶¹⁶ Nanno TID 2016 ¹⁶⁴⁶ Heiblig Mycoses 2015 ¹⁶⁴¹	Case reports
Any with CGD	To detect granulomatous inflammation and assess imaging characteristics	MRI	B	III	Davis PIDJ 2007 ¹⁶³⁴ De Ravin JCM 2014 ¹⁶⁷⁹ Ramesh JCI 2014 ¹⁶⁸² Haidar Mycoses 2017 ¹⁶⁷⁵	Case reports: soft tissue / osteomyelitis due to <i>Tropicoporus tropicalis</i>
5-FC, 5-fluorocytosine; ABPM, allergic bronchopulmonary mycosis; AFST, antifungal susceptibility testing; AmB, amphotericin B; BDG, Beta-D-Glucan; CGD, chronic granulomatous disease; CLSI, Clinical and Laboratory Standards Institute; CT, computed tomography; ELISA, Enzyme-linked Immunosorbent Assay; FC, fluorocytosine; FCZ, fluconazole; GM, Galactomannan testing; GMS, Grocott-Gomori's methenamine silver; HR, high-resolution; ICZ, itraconazole; ITS, internal transcribed spacer; ISA, isavuconazole; KCZ, ketoconazole; LSU, large subunit; MALDI-TOF MS, matrix assisted laser desorption ionization-time of flight mass spectrometry; MIC, minimal inhibitory concentration; MRI, magnetic resonance imaging; PAS, periodic acid-Schiff; pat., patient; PCR, polymerase chain reaction; PCZ, posaconazole; QoE, quality of evidence; SCT, stem cell transplant; SoR, strength of recommendation; TRB, terbinafine; VCZ, voriconazole.						

1549

1550 **Recommendation** – The guideline group strongly recommends HR chest CT and CT of the sinuses and MRI

1551 of the brain to delineate the extent of involvement of the infection (**Figure 24**).

1552 **Figure 24. Optimal diagnostic pathway for infections caused by *Schizophyllum* spp. and other basidio-**
 1553 **mycetes, when all imaging and assay techniques are available**



Legend:

strongly recommended	
moderately recommended	
marginally recommended	
recommended against	

CGD, chronic granulomatous disease; CT, computed tomography; ITS, internal transcribed spacer; MALDI-TOF MS, matrix-assisted laser desorption/ionization time-of-flight mass spectrometry; MRI, magnetic resonance imaging

1554

1555

1556

1557 **Treatment approaches to infections caused by *Schizophyllum* spp. and other basidiomycetes**

1558 Treatment in Adults

1559 ***First line treatment for infections caused by S. commune***

1560 **Evidence** – For treatment of infections caused by *S. commune*, data are primarily obtained from case

1561 reports and small case series. Infections with systemic spread and proven or probable CNS involvement

1562 have primarily been treated with L-AmB, with step down therapy to oral azoles (e.g., PCZ) after clinical

1563 improvement and stabilization of the patient^{1609,1620,1652}. In patients with pulmonary infections including
 1564 bronchopneumonia and pulmonary fungal balls VCZ, ICZ and FCZ have led to clinical improvement or
 1565 cure^{1621,1670,1681} (Table 30).

1566 **Table 30. First-line antifungal therapy for infections caused by *Schizophyllum* spp. and other basidiomycetes**

Population	Intention	Intervention	SoR	QoE	Reference	Comment	
Any	To cure <i>S. commune</i> infection	L-AmB; optional: step down to PCZ	B	III	Oliveira PLOSNTD 2017 ¹⁶²⁰	N=1, success	
					Hoeningl Mycoses 2013 ¹⁶⁰⁹	N=1, brain abscess, step down to PCZ solution, success	
					Rihs JCM 1996 ¹⁶⁵²	N=1, brain abscess, success	
Patients with pulmonary fungal ball	To cure	ICZ + tapering doses of systemic glucocorticoids	C	III	Chowdhary Mycoses 2013 ¹⁶²¹	N=1, success	
Any	To cure invasive pulmonary diseases/ bronchopneumonia due to <i>S. commune</i>	VCZ	C	III	Chowdhary AAC 2013 ¹⁶⁸¹	N=2, success 2/2	
					Tullio MedMycol 2008 ¹⁶⁷⁰		
Any	To cure invasive pulmonary diseases/ bronchopneumonia due to <i>C. cinerea</i>	Echinocandins	D	III	Lagrou JMM 2005 ¹⁶⁴⁴	N=4, progression while on CASPO/MICA	
					Suarez JCM 2011 ¹⁶⁶⁵		
					Chauhan LabMed 2019 ¹⁶¹⁶		
					Nanno TID 2016 ¹⁶⁴⁶		
					Conen CMI 2010 ¹⁶¹¹		
		Avoid echinocandins	A	III	Lagrou JMM 2005 ¹⁶⁴⁴		N= 7, high MICs to echinocandins, progression under treatment
					Suarez JCM 2011 ¹⁶⁶⁵		
					Chauhan LabMed 2019 ¹⁶¹⁶		
					Nanno TID 2016 ¹⁶⁴⁶		
					Godet Mycopathol 2017 ¹⁶¹²		
Ramesh JCI 2014 ¹⁶⁸²							
Conen CMI 2010 ¹⁶¹¹							
Hematological malignancies patients	To cure <i>C. cinerea</i> infection	L-AmB iv +/- inhalative L-AmB OR VCZ 4 mg/kg bid after loading dose	B	III	Godet Mycopathol 2017 ¹⁶¹²	N=1, poor response to L-AmB but rapid improvement after addition of nebulized L-AmB	
					Corzo-Leon Mycoses 2015 ¹⁰³⁴	N=1, bIFI under VCZ prophylaxis, treatment with L-AmB, died	
					Heiblig Mycoses 2015 ¹⁶⁴¹	N=1, stable disease	
					Surmont MedMycol 2002 ¹⁶⁶⁶	N=1, improvement	
Hematological malignancies patients	To cure pulmonary infection	D-AmB, ICZ	D	III	Verweij JCM 1997 ¹⁶⁷² ,	N=1, failure	
Hematological malignancies patients	To cure disseminated infection	VCZ iv	C	III	Conen CMI 2010 ¹⁶¹¹	N=3, stable disease 1/3, success 2/3	
					Koncan JMBT 2016 ¹⁶⁸⁸	N=1, success	
					Heiblig Mycoses 2015 ¹⁶⁴¹	N=1, stable disease	
Any	To cure respiratory diseases, ranging from saprobic colonization to fungal pneumonia	ICZ	C	III	Chowdhary JCM 2013 ¹⁶³²	N=4, <i>Emmia lacerata</i> , outcome unknown	
Patients with CGD	To cure	VCZ	C	III	Ramesh JCI 2014 ¹⁶⁸²	N=1, <i>T. tropicalis</i> , success	
Immunodeficiency patients	To cure disseminated infection	L-AmB, VCZ	D	III	Friman Scand JID 2006 ¹⁶⁸⁶	N=1, <i>Phlebia tremellosa</i> , failure	
Patients with CGD	To cure	L-AmB 7.5 mg/kg qd, followed by L-AmB + ISA	C	III	Haidar Mycoses 2017 ¹⁶⁷⁵	N=1, <i>T. tropicalis</i> , success	

Standard dose unless stated otherwise; bid, twice a day; bIFI, breakthrough invasive fungal infection; CASPO, caspofungin; CGD, chronic granulomatous disease; d, day(s); D-AmB, amphotericin B deoxycholate; ISA, isavuconazole; iv, intravenous; L-AmB, liposomal amphotericin B; MICA, micafungin; MIC, minimal inhibitory concentration; PCZ, posaconazole; po, orally; qd, once a day; QoE, quality of evidence; SoR, strength of recommendation; VCZ, voriconazole.

1567

1568 **Recommendations** – The guideline group moderately recommends first-line treatment with L-AmB (with
1569 the option to step down to PCZ later) based on descriptive case reports for infections with *S. commune*.
1570 Primary treatment with VCZ is marginally supported and may be used in patients intolerant to L-AmB.

1571

1572 **First line treatment for infections caused by *C. cinerea***

1573 **Evidence** - First line treatment for *infections caused by C. cinerea* is difficult to establish due to limited
1574 clinical data but *in vitro* data highlight that AmB and VCZ MICs are lower compared to those of CASPO and
1575 FCZ^{1612,1691}. Echinocandins should be avoided for the treatment of these infections due to higher MICs as
1576 well as reports of progression of disease in patients receiving echinocandins^{1611,1612,1644,1646,1665,1677}. L-AmB
1577 with dosages of 3 – 10 mg/kg has been used to treat *C. cinerea*-related infections and has led to cure in
1578 some patients. In cases of pulmonary infection caused by *C. cinerea* and nephrotoxicity associated with
1579 high-dose systemic L-AmB treatment, addition of inhaled L-AmB may allow dose reduction of systemic L-
1580 AmB and cure¹⁶¹². VCZ may also be used as an alternative to L-AmB¹⁰³⁴ in cases where there are contrain-
1581 dications to L-AmB as well as for step down treatment after clinical improvement under L-AmB treat-
1582 ment¹⁶¹¹.

1583 **Recommendations** – Despite limited literature on the treatment of these infections, first-line treatment
1584 with systemic L-AmB +/- inhaled L-AmB or VCZ is moderately recommended for *C. cinerea*-related infec-
1585 tions in patients with hematological malignancy. No data are available for other patient cohorts. Use of
1586 parenteral VCZ as first-line treatment is marginally recommended, whereas the guideline group recom-
1587 mends against the use of echinocandins.

1588

1589 **First line treatment for infections caused by other filamentous basidiomycetes**

1590 **Evidence** - The relevance of *Emmia lacerata* (formerly *Ceriporia lacerata*) as a human pathogen remains
1591 unclear. In case series, *E. lacerata* was found to be a colonizer of the airways but also a cause for fungal
1592 pneumonia^{1632,1660}. *In vitro* data showed the lowest MICs for PCZ and ISA compared to FCZ, 5-FC and echi-
1593 nocandins^{1632,1660}. Data on treatment is limited to three patients who received ICZ (n=2) or VCZ (n=1).
1594 Outcome is known for only one patient who received ICZ 200 mg tid and improved clinically¹⁶³².
1595 Infections caused by *Tropicoporus tropicalis* (formerly *Phellinus tropicalis*) have been reported exclusively
1596 in patients with CGD causing pneumonia, abscesses, brain lesions or osteomyelitis^{1634,1667,1675,1682}. Re-
1597 ported MICs were low for AmB and all triazoles, whereas higher MICs were found for FCZ^{1634,1675,1682}.
1598 Several different antifungal strategies have been published. Most included L-AmB either in combination
1599 with VCZ or ISA^{1634,1675,1692}. VCZ monotherapy was used in one patient successfully¹⁶⁸². Surgical treatment
1600 with resection of infected areas or drainage of abscess formations were performed in the majority of
1601 cases. Interestingly, the majority of *T. tropicalis*-related infections occurred while patients were on ICZ
1602 prophylaxis^{1634,1667,1682}.
1603 A single case of *Phlebia tremellosa* (formerly *Merulius tremellosus*) related infection in an immunocom-
1604 promised host was published¹⁶⁸⁶. Despite sequential therapy with L-AmB and VCZ the patient ultimately
1605 died.

1606
1607 **Recommendations** – Based on *in vitro* susceptibility data and a single case report, ICZ treatment is recom-
1608 mended marginally for the treatment of *E. lacerata* (formerly *Ceriporia lacerata*) infections. For patients
1609 with CGD and infection due to *T. tropicalis* the guideline group marginally recommends first line treatment
1610 with L-AmB +/- VCZ or ISA. VCZ monotherapy is an alternative option (marginally recommended).

1611
1612 **Salvage treatment for basidiomycetes**

1613 **Evidence** – Few breakthrough infections with *C. cinerea* in patients with hematological malignancy have
1614 been reported. Different antifungal strategies including surgery have been used for management of these

1615 infections. However, the majority of patients had a fatal outcome despite salvage treatment because of
 1616 progression of the infection or the underlying disease. Salvage treatment with L-AmB (5-10 mg/kg) alone
 1617 or in combination with VCZ and surgical debridement was associated with clinical and radiological im-
 1618 provement or cure in some of these patients^{1641,1665}. The addition of inhaled L-AmB (25 mg tiw) to systemic
 1619 L-AmB led to cure and reduced nephrotoxicity in a patient¹⁶⁷⁵ (Table 31).

1620 **Table 31. Antifungal salvage treatment for infections caused by *Schizophyllum* spp. and other basidiomycetes**

Population	Intention	Intervention	SoR	QoE	Reference	Comment
Hematological malignancies patients	To cure pulmonary infection with <i>C. cinerea</i>	L-AmB	B	III	Suarez JCM 2011	N=2, success 1/2
					Conen CMI 2010 ¹⁶¹¹	N=2, success 2/2
Hematological malignancies patients	To cure <i>C. cinerea</i> infection	L-AmB 5-10 mg/kg + VCZ iv/PCZ +/- surgical debridement	C	III	Conen CMI 2010 ¹⁶¹¹	N=2, improved when PCZ was added to L-AmB + VCZ
					Heiblig Mycoses 2015 ¹⁶⁴¹	N=1, improved
Hematological malignancies patients	To cure <i>C. cinerea</i> infection	VCZ 4 mg/kg iv bid after loading	B	III	Conen CMI 2010 ¹⁶¹¹	N=2, stable 1/2, improved 1/2
Hematological patients/allogeneic SCT patients	To cure pulmonary infection and reduce toxicity	Add nebulized AmB 25 mg tiw	C	III	Godet Mycopathol 2017 ¹⁶¹²	N=1, stable disease
Hematological malignancies patients	To cure <i>C. cinerea</i> infection	Echinocandin	D	III	Conen CMI 2010 ¹⁶¹¹	N=1, failure
Patients with CGD	To cure	ISA + dose-reduced L-AmB	C	III	Haidar Mycoses 2017 ¹⁶⁷⁵	N=1, response

Standard dose unless stated otherwise; bid, twice a day; CGD, chronic granulomatous disease; ISA, isavuconazole; iv, intravenous; L-AmB, liposomal amphotericin B; PCZ, 110osaconazole; QoE, quality of evidence; SCT, stem cell transplantation; SoR, strength of recommendation; tiw, three times a week; VCZ, voriconazole.

1621

1622 **Recommendations** – Use of L-AmB (5-10 mg/kg) or parenteral VCZ are moderately recommended for
 1623 salvage treatment of *C. cinerea*-related infections in hematological patients. Combination of both +/- sur-
 1624 gical debridement is marginally recommended as is the combination of ISA with a reduced dose of L-AmB.
 1625 The guideline group recommends against the use of echinocandins for basidiomycetes.

1626

1627 **Other treatment options for basidiomycetes**

1628 **Evidence** – There is a single case report of a patient with biphenotypic acute leukemia developing *C. ci-*
 1629 *nerea*-related infection during induction chemotherapy while on primary prophylaxis¹⁶⁶⁵. In this patient L-
 1630 AmB 5 mg/kg was successfully used as secondary prophylaxis during allogeneic HSCT for a total of 45 days.
 1631 This patient did not suffer from relapsing disease and was considered cured from her IFI. In CGD patients
 1632 with basidiomycetes infection, cultures from infected sites may be positive for years¹⁶⁹². However, they

1633 should not be classified as contaminants but should be considered as the causative agent in this set-
 1634 ting¹⁶⁷⁵. Secondary prophylaxis with VCZ or PCZ was used in two patients for several years without recur-
 1635 rence of infection¹⁶⁹².

1636 For deep-seated basidiomycete infections surgical intervention may be of benefit for the patient. Case
 1637 reports of successful treatment of such infections including surgery (debridement, excision of lung nod-
 1638 ules, wedge resection, excision of infected tissue), plus antifungal treatment, highlight the potential ben-
 1639 efits of surgery in this setting^{1611,1641,1673,1676}. However, surgery was not able to control fungal infection in
 1640 a patient with post-surgical eye infection or in an allogeneic HSCT patient with pulmonary infection who
 1641 showed progress of disease after resection of the lung nodules^{1612,1613}. Thus, surgery and antifungal treat-
 1642 ment should always be combined if feasible (**Table 32**).

1643 **Table 32. Other treatment options for infections caused by *Schizophyllum* spp. and other basidiomycetes**

Population	Intention	Intervention	SoR	QoE	Reference	Comment
Hematological patients planned for allo-SCT	Secondary prophylaxis	L-AmB or inhaled AmB	C	III	Suarez JCM 2011 ¹⁶⁶⁵	
Patients with CGD	Secondary prophylaxis	VCZ	C	III	Ramesh JCI 2014 ¹⁶⁸²	Case reports, CGD patients kept on VCZ for several months without recurrence or deterioration
					Nguyen JACI 2009 ¹⁶⁹²	
					Shigemura Infection 2015 ¹⁶⁷⁶	
Patients with CGD	To cure <i>Inonotus/Phellinus</i> spp. infection	Do not consider as contamination	C	III	Haidar Mycoses 2017 ¹⁶⁷⁵	Literature review, fungus was misinterpreted as contaminant, but should be considered as causative in this specific setting
Post-surgical eye infection	To cure	Surgery/vitreectomy	C	III	Jain JMM 2019 ¹⁶¹³	N=1, TPK + vitrectomy + systemic and topical antifungals
Sinusitis	To cure	Surgical debridement	B	III	Heiblig Mycoses 2015 ¹⁶⁴¹	N=1, improved
Pulmonary infection	To cure	Surgical excision of lung nodules/wedge resection	B	III	Godet Mycopathol 2017 ¹⁶¹²	N=1, Progress of infection after surgery
					Conen CMI 2011 ¹⁶¹¹	N=2, success 1/2, stable disease 1/2
Skin/subcutaneous infection	To cure	Surgical excision of infected tissue	B	III	Shigemura Infection 2015 ¹⁶⁷⁶	N=1, <i>Fuscoporia undulatus</i> , cure
					Williamson JMM 2011 ¹⁶⁷³	

AmB, amphotericin B; CGD, chronic granulomatous disease; L-AmB, liposomal amphotericin B; QoE, quality of evidence; SCT, stem cell transplantation; SoR, strength of recommendation; TPK, total penetrating keratoplasty; VCZ, voriconazole.

1644

1645 **Recommendations** – Secondary prophylaxis for hematological patients during allogeneic HSCT with L-
 1646 AmB is marginally recommended. In CGD patients with basidiomycete infections secondary prophylaxis
 1647 with VCZ or PCZ is marginally recommended. Surgical resection of infected tissue and debridement are
 1648 moderately recommended whenever feasible.

1649

1650 **Treatment duration**

1651 **Evidence** - Treatment duration has been determined on a case-by-case basis and depends on the extent

1652 of surgery, the organs involved, the pathogen involved, status of underlying disease and ongoing immu-

1653 nosuppression. For CNS infections a treatment duration of 6 weeks or more has been reported^{1609,1652},

1654 while for fungal rhinosinusitis with mucosal and/or bone invasion a treatment duration of >2 months has

1655 been reported¹⁶⁰⁶. For bone infections a treatment duration of up to several years has been published¹⁶⁹²

1656 **(Table 33).**

1657 **Table 33. Treatment duration for infections caused by *Schizophyllum* spp. and other basidiomycetes**

Population	Intention	Intervention	SoR	QoE	Reference	Comment
Any with CNS involvement	To cure	6 wk or more of therapy	B	III	Hoeningl Mycoses 2013 ¹⁶⁰⁹ Rihs JCM 1996 ¹⁶⁵²	N=2, duration determined case-by-case
Fungal rhinosinusitis with mucosal and/or bone invasion	To cure	2 mo or more	C	III	Michel MedMycol 2016 ¹⁶⁰⁶	Treatment duration determined case-by-case

CNS, central nervous system; mo, month(s); QoE, quality of evidence; SoR, strength of recommendation; wk, week(s)

1658

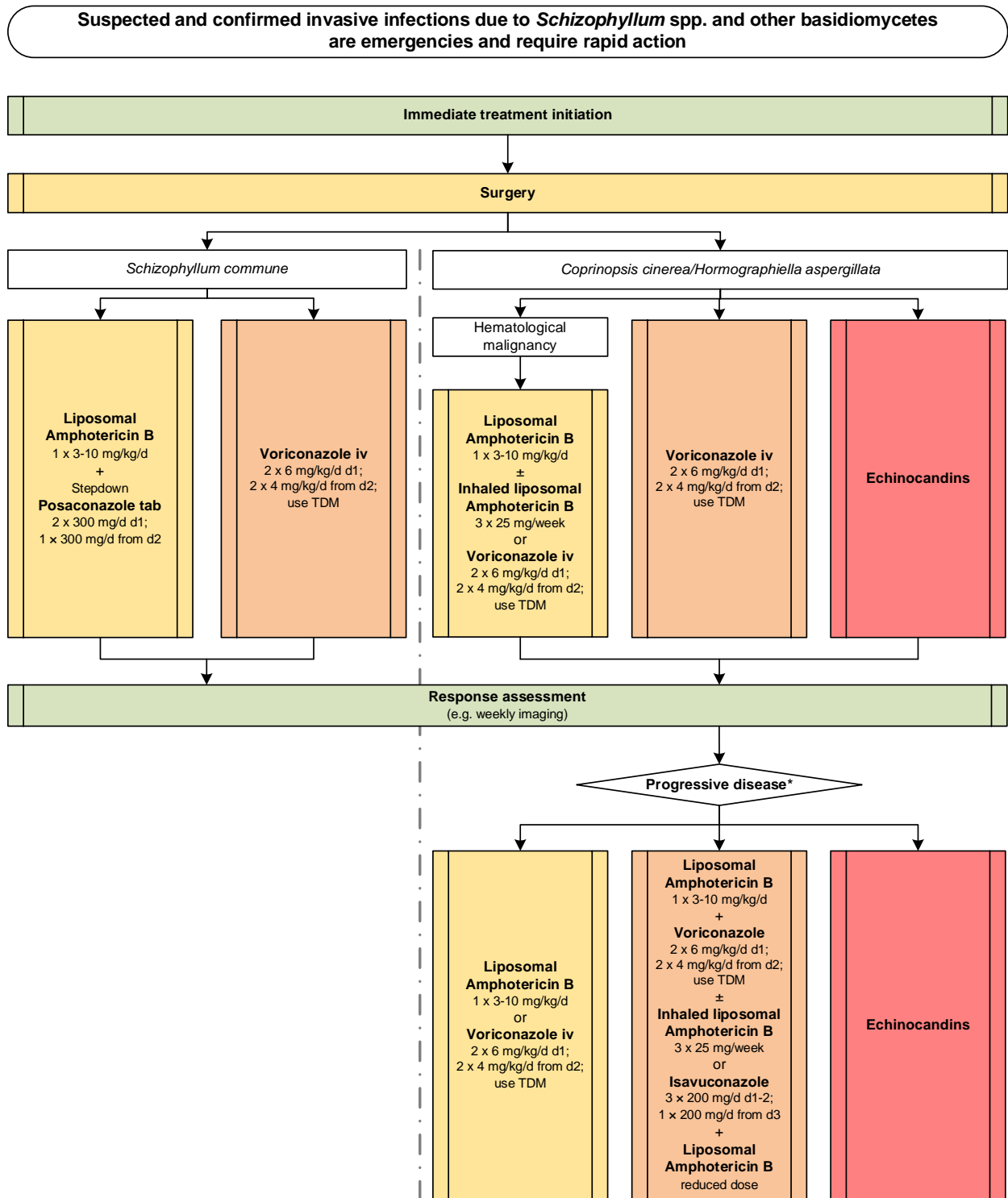
1659 **Recommendation** – Treatment duration should be determined on a case by case basis. For all types of

1660 CNS infections a treatment duration of 6 weeks or more is moderately recommended^{1609,1652}. For fungal

1661 rhinosinusitis with mucosal and/or bone invasion a treatment duration of 2 months or more is margin-

1662 ally recommended¹⁶⁰⁶ **(Figure 25).**

1664 **Figure 25. Optimal treatment pathway for infections caused by *Schizophyllum* spp. and other basidio-**
 1665 **mycetes in adults when all treatment modalities and antifungal drugs are available**



Legend:
 strongly recommended
 moderately recommended
 marginally recommended
 recommended against

TDM, therapeutic drug monitoring

* Choice of salvage treatment always depends by the treatment that the patient failed to respond to

1667 **Specific considerations on treatment of infections caused by *Schizophyllum* spp. and other basidiomy-**
 1668 **cetes in children**

1669 **Evidence** – Pediatric data is limited only to case reports (**Table 34**).

1670 **Table 34. Therapy in children for *Schizophyllum* spp. and other basidiomycetes infections**

Population	Intention	Intervention	SoR	QoE	Reference	Comment
First-line antifungal therapy						
BMT (Immunocompromised) with invasive basidiomycosis	To cure	VCZ iv	B	III	Lim AJD 2017 ¹⁶⁸⁵	N=1, 22 mo, <i>Earliella scabrosa</i> , failure
Any	To cure	L-AmB 7.5-10 mg/kg qd, VCZ iv, surgical debridement	B	III	Heiblig Mycoses 2015 ¹⁶⁴¹	N=1, 19 yrs, stable disease
AML	To cure	No treatment	D	III	Abuali JCM 2009 ¹⁶²³	N=1, 14 yrs, fatal outcome
Antifungal salvage treatment						
Children/Young adults with CGD	To cure	VCZ 200 mg po bid +/- other antifungals	B	III	Ramesh JCI 2014 ¹⁶⁸²	N=1, 24 yrs, <i>T. tropicalis</i> retropharyngeal abscess, survived
					Sigemura Infection 2015 ¹⁶⁷⁶	N=1, 23 yrs, <i>Phellinus mori</i> , VCZ + MICA, survived
					Davis PIDJ 2007 ¹⁶³⁴ (molecular work presented by Sutton JCM 2005 ¹⁶⁶⁷)	N=1, 21 yrs, paraspinal abscess and sacral osteomyelitis, <i>T. tropicalis</i> , survived
					De Ravin JCM 2014 ¹⁶⁷⁹	N=1, 10 yrs, <i>Phellinus</i> spp., paravertebral abscess, + surgery, survived
Children with soft tissue infection	To cure	PCZ 100 mg qd + alternate regimen of PCZ 100 mg/200 mg for consolidation 2 wk after clinical improvement	C	III	Correa Martinez NMI 2017 ¹⁶⁹⁰	N=1, <i>C. cinerea</i>
Standard pediatric dose unless stated otherwise; AML, acute myeloid leukemia; bid, twice a day; BMT, bone marrow transplant; CGD, chronic granulomatous disease; iv, intravenous; L-AmB, liposomal amphotericin B; MICA, micafungin; PCZ, posaconazole; po, orally; qd, once a day; QoE, quality of evidence; SoR, strength of recommendation; VCZ, voriconazole; yrs, years.						

1671

1672 **Recommendations** - According to data in adults, the recommendation for therapy includes VCZ alone or
 1673 in combination with L-AmB (moderate recommendation).

1674

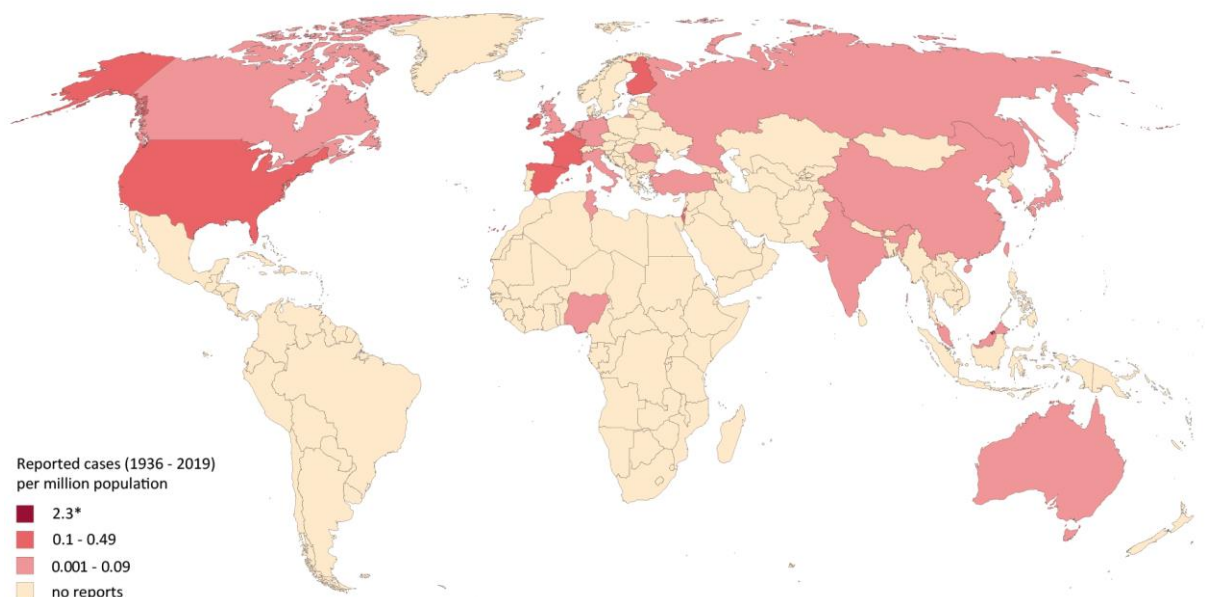
1675 **7. Scopulariopsis**

1676 **Epidemiology of infections caused by *Scopulariopsis* spp.**

1677 *Scopulariopsis* is found in soil and plant material with a worldwide distribution¹⁶⁹³. Some species have
 1678 teleomorphs, which are classified in the genus *Microascus*¹⁶⁹⁴. *Scopulariopsis brevicaulis* is the most rele-
 1679 vant species in humans¹⁶⁹⁵. Single cases of infections caused by *Scopulariopsis acremonium*, *Scopulariop-*
 1680 *sis brumptii* and *Scopulariopsis candida* have been reported, mostly from Western Europe and North-

1681 America¹⁶⁹⁶⁻¹⁶⁹⁸. *Scopulariopsis* is typically associated with onychomycosis or other superficial infec-
1682 tions^{1699,1700}. Severe *Scopulariopsis*-related systemic infections have been reported, mainly in immunosup-
1683 pressed patients with underlying malignancy, HSCT and SOT recipients, affecting lungs, paranasal-sinuses
1684 and soft tissues^{1589,1697,1698,1701,1702}. Infections have rarely occurred in immunocompetent patients follow-
1685 ing traumatic injuries or surgery affecting the eye or deep soft tissue¹⁷⁰³⁻¹⁷⁰⁵. Dissemination to the CNS or
1686 other organs and fungemia have been noted in severely ill patients^{1706,1707}. Heart infections due to *Scopu-*
1687 *lariopsis* have been described mainly in patients who underwent prosthetic valve implantation^{1708,1709}. In
1688 a retrospective study in a US Cancer Center, ~2% of fungal infections of the brain in bone marrow trans-
1689 plant patients were caused by *Scopulariopsis*¹⁷¹⁰. The National Institutes of Health reported that in pa-
1690 tients with positive bronchoalveolar lavage BDG tests ~3% of confirmed fungal infections were due to
1691 *Scopulariopsis*¹⁷¹¹. In patients post-lung transplantation an incidence of 0.2% was reported in a center in
1692 Spain⁶⁰⁶ (**Figure 26**).

1693
1694 **Figure 26. Worldwide distribution of infections caused by *Scopulariopsis* spp. (reported cases between**
1695 **1936 and 2019 per million population)**



1696

1697 Cases of *Scopulariopsis*-related infections reported in the medical literature were identified in a PubMed
1698 search on October 30, 2019 using the search string “*Scopulariopsis* OR *Microascus*” that yielded 554 pub-
1699 lications. In total, 86 cases were identified from 24 countries, 61 since the year
1700 2000^{606,643,720,1107,1116,1589,1696-1698,1701-1764}. Most cases were reported from the United States (n=41), France
1701 (n=10) and Spain (n=5). The number of cases reported between 1936 and 2019 is presented as cases per
1702 million population per country. The resident population per country was obtained from www.worldome-
1703 ters.info³²¹. *One case was reported from Brunei Darussalam (2.3 cases per million population between
1704 1936 and 2019)¹⁷⁵².

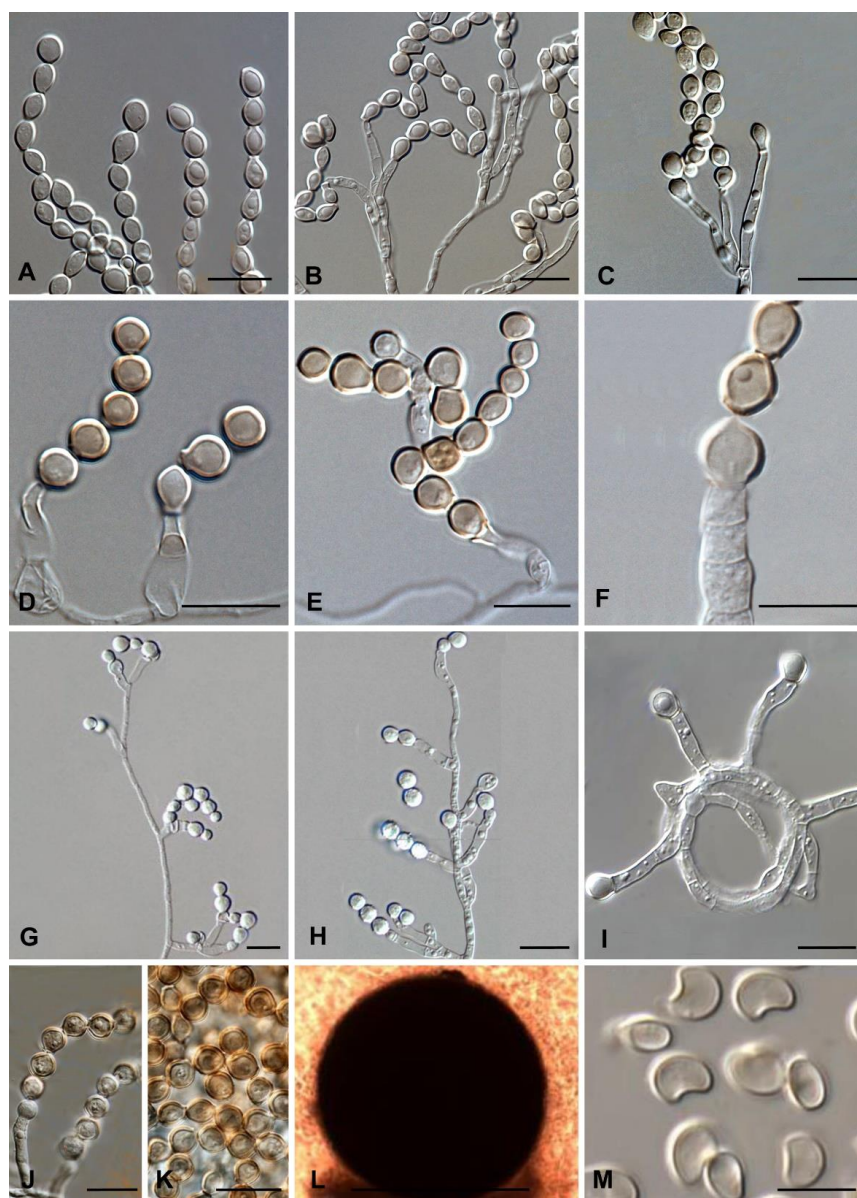
1705

1706 **Diagnosis of Scopulariopsis**

1707 ***Diagnosis – Microbiology – Conventional Methods***

1708 **Evidence** – The definitive diagnosis of *Scopulariopsis*-related infections has traditionally relied on the iso-
1709 lation of *Scopulariopsis* spp. from infected tissue or body fluids, with histological findings showing dichot-
1710 omously branched septate hyphae, and culture confirmation of *Scopulariopsis* spp.^{1706,1732,1751,1765}. See also
1711 **Figure 27** with microscopic morphology from the Atlas of Clinical Fungi project¹⁹.

1712 **Figure 27. Microscopic morphology of *Scopulariopsis* spp.**¹⁹



1713

1714

1715 **Panel A-C, *Scopulariopsis koningii***, conidiogenous cells single or in groups, cylindrical or with slightly swollen basal parts, conidia spherical to ovoidal; **Panel D-F, *Scopulariopsis asperula***, conidiophores with anellated conidiogenous cells and conidia; **Panel G-H, *S. brevicaulis***, conidiogenous cells and conidia; **Panel I, *Scopulariopsis flava***, conidiogenous cells and conidia; **Panel J-K, *Scopulariopsis fusca***, conidiogenous

1719 cells arising from aerial hyphae, single or in groups; **Panel L-M**, *S. candida*, ascomata spherical, black, with
1720 pore in the apical papilla, ascospores heart-shaped in lateral view. Scale bars = 10 µm.

1721 Culture is essential, and histological findings alone are insufficient for the diagnosis of these infections as
1722 *Scopulariopsis* spp. can be difficult to distinguish from *Aspergillus* spp., *Fusarium* spp., and *Scedosporium*
1723 spp. by histology and morphological appearance alone¹⁷⁴⁶ (**Table 35**).

1724 **Recommendations** – The guideline group strongly recommends that infected tissue or body fluids be ob-
1725 tained for culture and also microscopic/histological evaluation, when possible.

1726 **Diagnosis – Microbiology – Serology**

1727 **Evidence** – In multiple case reports, *Aspergillus* GM and BDG have been negative^{1711,1732,1766} (**Table 35**).

1728 **Recommendations** – *Aspergillus* GM and BDG are not recommended as part of the diagnostic evaluation
1729 for *Scopulariopsis*-related infections.

1730 **Diagnosis – Microbiology – Molecular-based**

1731 **Evidence** – PCR assays have been developed that can identify *Scopulariopsis* isolates to the genus level¹⁷⁶⁷
1732 and species level^{1706,1726,1732,1764,1766}, in two reports PCR has been performed directly on sputum sam-
1733 ples^{1706,1768} (**Table 35**).

1734 **Recommendations** – The guideline group marginally supports the use of molecular-based diagnostic tests
1735 to diagnose *Scopulariopsis*-related infections, if available.

1736 **Diagnosis – Microbiology – Species identification**

1737 **Evidence** – Using PCR assays¹⁷⁶⁹⁻¹⁷⁷¹ and phylogenetic analysis using multi-gene sequences¹⁷⁷², identifica-
1738 tion to the species level has been reported in some studies, although the specificity of PCR varies from
1739 study to study and has been as low as 70% in some studies^{561,1768}. MALDI-TOF MS has been used to identify
1740 *Scopulariopsis* isolates in one case report¹⁷⁷³ and the combination of PCR and MALDI-TOF MS in another
1741 case report¹⁷⁰¹ (**Table 35**).

1742 **Recommendations** – The guideline group strongly recommends species identification using ITS2 or D1/D2
1743 or 18S PCR or phylogenetic analysis for species identification from isolates and marginally the use of
1744 MALDI-TOF MS for the same purpose.

1745 **Microbiology – Susceptibility testing**

1746 **Evidence** – *Scopulariopsis* species typically demonstrate high MICs to many antifungal agents including
1747 FCZ, ICZ, 5-FC, and AmB¹⁷⁷⁴. Antifungal susceptibility testing using CLSI⁵⁶¹ and EUCAST testing⁵⁵⁹ can de-
1748 termine MICs, while having been shown to poorly correlate with E-test³³⁰. However, there are not enough
1749 data documenting a correlation between MICs and clinical outcome nor has a clinically meaningful cutoff
1750 value been established^{1719,1775} (**Table 35**).

1751 **Recommendations** – Given that *Scopulariopsis* spp. typically demonstrate high MICs to many antifungal
1752 agents, CLSI or EUCAST testing is strongly recommended to determine antifungal susceptibility, and mod-
1753 erately for guiding antifungal treatment.

1754 **Diagnosis - Pathology**

1755 **Evidence** – Histological findings showing dichotomously branched septate hyphae have been reported in
1756 multiple studies to be suggestive of *Scopulariopsis* infection, including in those with underlying hemato-
1757 logical malignancies^{1701,1732,1764}, solid organ transplant patients¹⁷⁷⁶, and a patient with endocarditis¹⁷¹².
1758 *Scopulariopsis* spp. can be difficult to distinguish from *Aspergillus* spp., *Fusarium* spp., and *Scesosporium*
1759 spp. by morphology alone¹⁷⁴⁶ (**Table 35**).

1760 **Recommendations** – The guideline group strongly recommends histopathological examination of biopsy
1761 tissue in cases of suspected *Scopulariopsis* infection.

1762 **Diagnosis – Imaging**

1763 **Evidence** – *Scopulariopsis* spp. rarely cause invasive infections in humans and the diagnosis is typically
1764 made in immunocompromised individuals. As with other invasive fungal infections, imaging studies have

1765 played a crucial role in determining the likely site of *Scopulariopsis* infection^{1702,1726,1751} and assisting in the
 1766 procurement of infected tissue or body fluids¹⁷⁵⁵ (Table 35).

1767 **Table 35. Microbiological, histopathological and imaging diagnostics of *Scopulariopsis* infections**

Population	Intention	Intervention	SoR	QoE	Reference	Comment
Microscopy, culture, MIC testing						
Any	To diagnose	Culture and microscopy	A	II	Arroyo JCM 2017 ¹⁷⁶⁵	H&E, GMS, and PAS stainings revealed numerous septate hyphae with dichotomous branching. Cultures confirmed <i>Scopulariopsis</i> spp.
					Sattler MMCR 2014 ¹⁷⁵¹	Allergic sinusitis; Hyaline septate hyphae and globose to pyriform truncate spores at direct examination. Cultures confirmed <i>Scopulariopsis</i> spp.
					Salmon CMI 2010 ¹⁷⁰⁶	Biopsy showed numerous septate hyphae by direct observation after Chlorazol-Black staining. Microscopic examination of histological sections stained with lactophenol blue, PAS, H&E and GMS stainings revealed branched septate hyphae and many vesicular swellings of different sizes. Cultures confirmed <i>Scopulariopsis</i> spp.
Any	To determine antifungal susceptibility	EUCAST method	A	III	Alastruey-Izquierdo AAC 2018 ⁵⁵⁹	<i>S. brevicaulis</i> had high MICs for all antifungals
Any	To determine antifungal susceptibility	CLSI MIC testing	A	IIu	Sandoval-Denis JCM 2013 ⁵⁶¹	N=97, Echinocandins had better <i>in vitro</i> activities than azoles
Any	To guide antifungal treatment	CLSI MIC testing	B	IIu	Cawcutt CRM 2015 ¹⁷⁰⁹	N=1, Endocarditis; susceptible to CASPO, MICA and TRB, treatment with CASPO + VCZ, success
					Gavril Infection 2016 ¹⁷⁰¹	N=1, cutaneous infection; susceptible to MICA, but no correlation between MIC and clinical outcome
					Shaver AJT 2014 ¹⁷⁵⁵	N=1, Lung transplant patient; susceptible to echinocandins, failure
Serology assays						
Any	To diagnose	Aspergillus GM EIA	D	III	Salmon CMI 2010	N=1, disseminated <i>S. brevicaulis</i> . Serum <i>Aspergillus</i> GM +, thought to be false + due to cross-reactivity with <i>S. brevicaulis</i> cell wall components
					Miossec JCM 2011 ¹⁷⁶⁶	N=1, <i>Scopulariopsis</i> fungemia. <i>Aspergillus</i> GM assays x5 were negative, starting 11 d after transplant
					Iwen MedMycol 2012 ¹⁷³²	N=1, Invasive <i>Scopulariopsis</i> infection. <i>Aspergillus</i> GM negative
Aplastic anemia	To diagnose	Aspergillus GM from serum and BAL, BDG from serum and BAL	D	III	Rose JInfect 2014 ¹⁷¹¹	N=1. Invasive <i>Scopulariopsis</i> infection. BDG and GM (both serum and BAL) negative
Nucleic-acid based assays/MALDI-TOF MS						
Any	To diagnose	PCR directly from sputum/tissue	C	II	Salmon CMI 2010 ¹⁷⁰⁶	N=1. Disseminated <i>S. brevicaulis</i> detected by PCR from sputum and tissue and culture
Any	To diagnose	Universal 28S PCR + RFLP directly from sputum	C	II	Bontems BJD 2009 ¹⁷⁶⁸	N=17, <i>S. brevicaulis</i> isolated in culture from infected nails, 12/17 were correctly identified by PCR-RFLP (spec. 71%)

Any with non-dermatophyte onychomycosis	To detect	Development of PCR for detection in nail (keratin)	C	III	Stavrakieva PIPD 2003 ¹⁷⁷⁷	Development of PCR assay for identification of <i>S. brevicaulis</i> in clinical samples using species-specific primers. Amplification of 336 bp DNA fragment of ribosomal LSU. Method not applied to nail fragments.
Any	To identify species	PCR-RFLP	A	IIu	Kordalewska PJM 2015 ¹⁷⁶⁹	N=48, sens 100%, spec 100% on genus level
					Kordalewska MedMycol 2018 ¹⁷⁷⁰	
					Kordalewska Mycopathol 2016 ¹⁷⁶⁷	
Any	To identify species	ITS 1/2 and intervening 5.8S nrDNA, <i>tub2</i> and <i>tef1</i> gene regions	A	IIu	Woudenberg StudMycol 2017 ¹⁷⁷²	N=248 isolates: 152 <i>Microascus</i> , 88 <i>Scopulariopsis</i> , 4 <i>Yunnania</i> , 4 out-groups. Multi-gene phylogenies recognized 12 <i>Scopulariopsis</i> spp.
Any	To identify <i>Scopulariopsis</i>	PCR to 28S rDNA	B	II	Jagielski PJM 2013 ¹⁷⁷⁸	N=40 <i>Scopulariopsis</i> spp. and 4 reference strains of <i>S. brevicaulis</i> from clinical isolates from hair and nails sequenced. Poor ability to identify the species
					Sandoval-Denis JCM 2013 ⁵⁶¹	N= 99 clinical isolates, PCR able to identify 67% to the species level
Onychomycosis	To identify <i>Scopulariopsis</i>	PCR to 28S rDNA	B	II	Monod JMM 2006 ¹⁷⁷¹	N=5 culture-proven isolates of <i>S. brevicaulis</i> , PCR was able to correctly identify 4/5 as <i>S. brevicaulis</i> and the non-identified isolate was a probably contaminate
					Bontems BJD 2009 ¹⁷⁶⁸	N=17 cases of <i>S. brevicaulis</i> isolated in culture from infected nails, 12/17 were correctly identified by PCR-RFLP (spec. 71%)
Any	To identify isolates	ITS2 or D1/D2 or 18S PCR+ sequencing from isolates	A	III	Yang DMID 2012 ¹⁷⁶⁴	N=1, invasive pulmonary <i>S. brevicaulis</i> detected by PCR only
					Iwen MedMycol 2012 ¹⁷³²	N=3, <i>S. brevicaulis</i> detected by PCR and histopathology
					Miossec JCM 2011 ¹⁷⁶⁶	N=1, disseminated <i>S. brevicaulis</i> detected by PCR only
					Gluck IJPO 2011 ¹⁷²⁶	N=1, <i>S. brevicaulis</i> detected by PCR and culture
AML	To identify <i>Scopulariopsis</i>	MALDI-TOF MS and PCR	C	III	Gavril Infection 2017 ¹⁷⁰¹	N=1, invasive <i>S. brevicaulis</i> detected by culture, MALDI-TOF MS, and PCR
Any	To identify <i>Scopulariopsis</i>	MALDI-TOF MS	C	III	Rath WJOHNS 2019 ¹⁷⁷³	N=1, otomycosis, confirmed with MALDI-TOF MS
Tissue-based diagnosis						
Any	To diagnose	Histopathological examination of biopsy tissue	A	II	Iwen MedMycol 2012 ¹⁷³²	N=33, invasive or disseminated disease. Main features seen in deep cutaneous, pulmonary or sinus areas: hyaline branched septate hyphae, irregularly-shaped hyphae and swollen thick-walled structures, angioinvasion, necrosis. In 12/33, conidia, conidia-like bodies, round or swollen structures or ascospores identified. Comment: swollen structures are unlikely to be conidia that are seen in cases of <i>Scopulariopsis</i> onychomycosis
					Yang DMID 2012 ¹⁷⁶⁴	N=1, Bronchial invasion of <i>S. brevicaulis</i>
					Taton TID 2017 ¹⁷⁷⁶	N=1, Necrotizing <i>Microascus</i> tracheobronchitis. Endobronchial swabs, biopsies, and BAL positive for <i>Microascus</i> spp. (teleomorph of <i>Scopulariopsis</i> spp.).

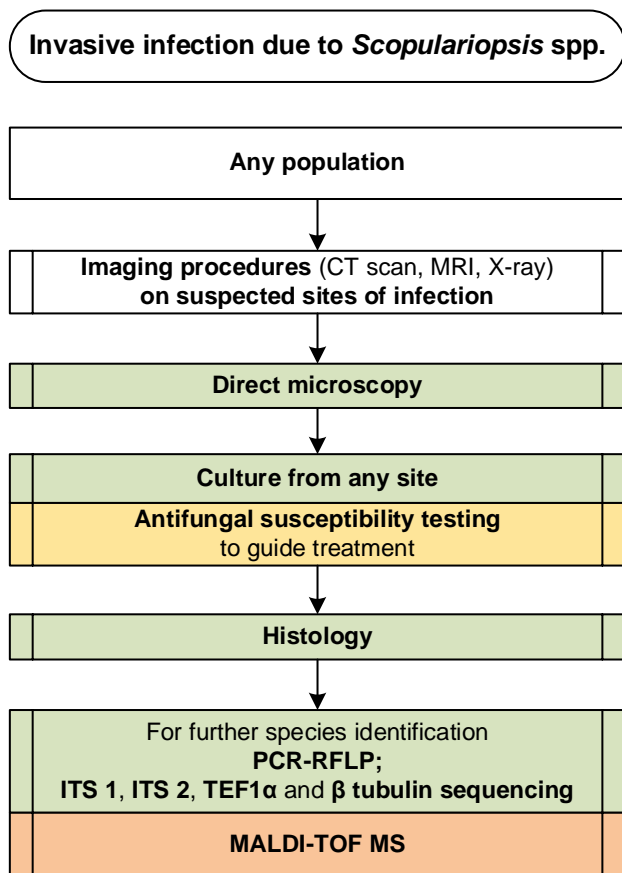
					Arroyo MJCM 2017 ¹⁷⁶⁵	N=1, thrombectomy and resection of ascending aortic graft histologically revealed dichotomously branched septate hypha, which grew <i>S. brevicaulis</i>
					Gavril Infection 2017 ¹⁷⁰¹	N=1, invasive cutaneous infection; branched septate hyphae demonstrated at dermal-epidermal junction grew <i>S. brevicaulis</i>
Imaging studies						
SOT patients	To assess the cause of pulmonary symptoms	Chest radiograph and CT	B	II	Pate TID 2016 ¹⁷⁴³	N=1, pneumonia, <i>S. brumptii</i>
		Chest CT	A	II	Shaver AJT 2014 ¹⁷⁵⁵	N=1, pneumonia, pleural effusion, <i>S. brumptii</i>
Sinusitis	To assess the clinical manifestations and imaging characteristics of sinusitis caused by <i>Scopulariopsis</i>	CT scan of the sinuses	A	II	Gluck IJPO 2011 ¹⁷²⁶	Sinus opacification in pediatric patients presenting with sinusitis that was later proven to be caused by <i>Scopulariopsis</i>
					Sattler MMCR 2014 ¹⁷⁵¹	N=1, Mucosal thickening at the floor of the left maxillary sinus that penetrated into the premolar dentition in an apparently immunocompetent patient
					Kammoun JMM 2018 ¹⁷⁰²	N=1, Orbital cellulitis resulted from erosion and calcification of the frontal sinus by <i>Scopulariopsis</i> spp.
BAL, bronchoalveolar lavage; BDG, Beta-D-Glucan; CASPO, caspofungin; CLSI, Clinical and Laboratory Standards Institute; CT, computed tomography; d, day(s); DNA, deoxyribonucleic acid; EUCAST, European Committee for Antimicrobial Susceptibility Testing; GM, Galactomannan testing; GMS, Grocott-Gomori's methenamine silver; HE, hematoxylin and eosin; ITS, internal transcribed spacer; LSU, large subunit; MALDI-TOF MS, matrix assisted laser desorption ionization-time of flight mass spectrometry; MIC, minimal inhibitory concentration; nrDNA, nuclear ribosomal deoxyribonucleic acid; PAS, periodic acid-Schiff; PCR, polymerase chain reaction; rDNA, ribosomal deoxyribonucleic acid; RFLP restriction fragment length polymorphism; QoE, quality of evidence; SoR, strength of recommendation; SOT, solid organ transplant; TRB, terbinafine; VCZ, voriconazole.						

1768

1769 **Recommendations** – As with other invasive fungal infections, imaging studies such as chest CT for pul-
1770 monary symptoms or CT of the sinuses for sinusitis are strongly recommended to assist in diagnosis,
1771 when applicable (**Figure 28**).

1772

1773 **Figure 28. Optimal diagnostic pathway for *Scopulariopsis* infections when all imaging and assay tech-**
 1774 **niques are available**



Legend:

strongly recommended	
moderately recommended	
marginally recommended	
recommended against	

CT, computed tomography; ITS, internal transcribed spacer; MALDI-TOF MS, matrix-assisted laser desorption/ionization time-of-flight mass spectrometry; PCR, polymerase chain reaction; RFLP, restriction fragment length polymorphism; ; TEF1 α , translational elongation factor 1 α

1775

1776

1777 **Treatment approaches to *Scopulariopsis* infections**

1778 Treatment in adults

1779 **Evidence** - *Scopulariopsis* spp. usually exhibit high MICs to all currently available antifungal

1780 agents^{1719,1775,1779-1781}. ICZ, FCZ and 5-FC have almost no activity against *Scopulariopsis* spp.^{561,1719,1775,1781}.

1781 Therefore, drugs that should be considered for the treatment of invasive disease include AmB, VCZ, PCZ,
 1782 echinocandins, and TRB^{1719,1775,1779-1781}. Some reports also suggest a high percentage of *in vitro* synergism
 1783 with antifungal combinations of AmB and ANID (>80%)¹⁷⁸² or PCZ, CASPO and TRB (~100%)¹⁷⁷⁹. However,
 1784 the relevance of these *in vitro* data is not clear, because there are not enough data documenting a corre-
 1785 lation between MICs and the clinical outcome^{1719,1775}.

1786 Adequate debridement or excision of necrotic tissue and the early start of systemic antifungal treatment
 1787 appear to be the major means of halting progression of the disease^{1702,1712,1747,1776,1783}. In patients with
 1788 invasive *Scopulariopsis* infection, various combinations of D-AmB, lipid-based AmB formula-
 1789 tions^{1696,1698,1706,1709,1722,1724,1731,1732,1752,1755,1757,1758,1760,1776,1783,1784}, azoles^{1706,1743,1750,1752,1755,1758,1776,1785},
 1790 TRB^{1758,1760,1776,1785} and echinocandins^{1696,1763,1764,1766} have been reported (Table 36).

1791 **Table 36. Therapy for *Scopulariopsis* infections**

Population	Intention	Intervention	SoR	QoE	Reference	Comment
First line treatment						
Any	To cure	L-AmB 3-10 mg/kg qd + VCZ	B	III	Kurata IJH 2018 ¹⁶⁹⁸ Isidro JTCS 2006 ¹⁷³¹	N=1, failure N=1, failure
Any	To cure	VCZ iv, step down to therapy po later	B	III	Kammoun JMM 2018 ¹⁷⁰² Jain CardiovasPathol 2011 ¹⁷⁰⁸	N=1, success N=1, success
Any	To cure	VCZ + Echinocandin + TRB 250 mg qd	C	III	Taton TID 2017 ¹⁷⁷⁶ Shaver AJT 2014 ¹⁷⁵⁵ Miossec JCM 2011 ¹⁷⁶⁶ Wuyts JHLT 2005 ¹⁷⁶³	N=1, success N=1, failure N=1, failure N=1, failure
AML with skin infection	To cure	Echinocandin	D	III	Gavril Infection 2016 ¹⁷⁰¹	N=1, failure
Any	To cure	AmB lipid formulations +/- other antifungals	B	III	Satyavani SMJ 2010 ¹⁷⁵² Ellison AOHNS 1998 ¹⁷²² Gentry THIJ 1995 ¹⁷²⁴ Beltrame IJID 2009 ¹⁶⁹⁶ Perfect CID 2005 ³⁷⁸ Phillips DMID 1989 ¹⁷⁴⁶ Neglia AJM 1987 ¹⁷⁸⁴ Mohammedi EJCMI 2004 ¹⁷⁸⁶ Celard CID 1999 ¹⁷⁸⁷ Migrino CID 1995 ¹⁷³⁸	N=1, success N=1, success N=1, success N=1, failure N=3, failure N=1, failure N=2, failure N=1, failure N=1, failure N=1, failure
Any	To cure	L-AmB + echinocandin	C	III	Salmon CMI 2010 ¹⁷⁰⁶ Iwen MedMycol 2012 ¹⁷³²	N=1, failure N=1, failure
Any	Cure	ISA	B	III	Cornely Mycoses 2018 ³⁸¹	N=2, success
Antifungal salvage treatment						
Any	To cure	PCZ	B	III	Cawcutt CMR 2015 ¹⁷⁰⁹ Pate TID 2016 ¹⁷⁴³ Rakita AJT 2015 ¹⁷⁵⁰ Arroyo JCM 2017 ¹⁷⁶⁵	N=1, PCZ salvage after CASPO and VCZ, stable disease N=1, PCZ + TRB salvage after AmB and MICA, success N=1, PCZ + TRB salvage after VCZ, success N=1, PCZ + MICA salvage, followed by PCZ mono after AmB and VCZ; success
AML	To cure bronchial infection	VCZ iv + CASPO	D	III	Yang DMID 2012 ¹⁷⁶⁴	N=1, <i>S. brevicaulis</i> , salvage after L-AmB and VCZ

	To cure	ICZ	C	III	Ng MJM 2003 ¹⁷⁰⁷	N=1, <i>S. brevicaulis</i> , salvage after AmB
Any	To cure	L-AmB 10 mg/kg qd + VCZ	D	III	Salmon CMI 2010 ¹⁷⁰⁶	N=1, disseminated infection <i>S. brevicaulis</i> ; L-AmB + CASPO, switch to AmB + VCZ, failed
Other treatment options						
Endogenous fungal endophthalmitis	To cure	Vitreotomy with intravitreal VCZ and 3 wk of oral VCZ	C	III	Raevis CRO 2018 ¹⁷⁴⁷	
Diabetes	To cure	Topical efinaconazole	C	III	Kimura JOD 2018 ¹⁷⁸⁸	N=1, onychomycosis, <i>S. brevicaulis</i> . Failure of 13 mo TRB + ICZ, switch to topical treatment
Fungal keratitis	To Cure	AmB topical 0.15%, VCZ 1% + VCZ po, later ICZ po + 2x 5 µg/0.1 ml AmB intracameral	C	III	Wilde IntOphthalmol 2018 ¹⁷⁸⁹	N=1, <i>Scopulariopsis gracilis</i>
Treatment duration						
Aortic graft	To cure	PCZ + MICA for 2 mo, then PCZ for 6 mo	C	III	Arroyo JCM 2017 ¹⁷⁶⁵	N=1, success
Lung transplant recipient	To cure	PCZ + TRB for 22 mo	C	III	Rakita AJT 2015 ¹⁷⁵⁰	N=1, success
Prosthetic mitral valve endocarditis with septic emboli	To cure	Combination therapy (L-AmB/VCZ + CASPO) for 8 wk, then chronic suppression with VCZ (shifted to PCZ due to AEs)	C	III	Cawcutt CRM 2015 ¹⁷⁰⁹	N=1, heart surgery and thrombectomy of septic emboli
Liver transplant recipient	To cure	MICA + PCZ + TRB for 47 d, then PCZ and TRB for 2 mo	C	III	Pate TID 2016 ¹⁷⁴³	N=1
Endogenous endophthalmitis	To cure	VCZ 4 mg/kg bid for 3 wk	C	III	Raevis CRO 2018 ¹⁷⁴⁷	N=1, + 0.1 mL intravitreal VCZ, vision improvement
Uncontrolled diabetes	To cure	VCZ for 2 mo	C	III	Kammoun JMM 2018 ¹⁷⁰²	N=1, sinusitis, surgical debridement, success
Standard dose unless stated otherwise; AE, adverse event; AmB, amphotericin B; AML, acute myeloid leukemia; bid, twice a day; CASPO, caspofungin; d: day(s); DSAEK, Descemet's stripping automated endothelial keratoplasty; ISA, isavuconazole; ICZ, itraconazole; iv, intravenous; L-AmB, liposomal amphotericin B; MICA, micafungin; mo, month(s); PCZ, posaconazole; po, orally; qd, once a day; QoE, quality of evidence; SoR, strength of recommendation; TRB, terbinafine; VCZ, voriconazole; wk, week(s).						

1792

1793

Recommendation - According to available data and drug safety profiles¹⁷⁹⁰, the group moderately recom-

1794

mends L-AmB (monotherapy or combination therapy with VCZ or another antifungal), VCZ monotherapy,

1795

or ISA monotherapy as the preferred treatment regimens. Other combination therapy regimens should

1796

be considered according to results of *in vitro* studies^{1779,1782}. Antifungal regimens that include PCZ delayed

1797

release tablet alone or in combination with TRB or MICA are moderately recommended for salvage ther-

1798

apy^{1758,1760,1776,1785}.

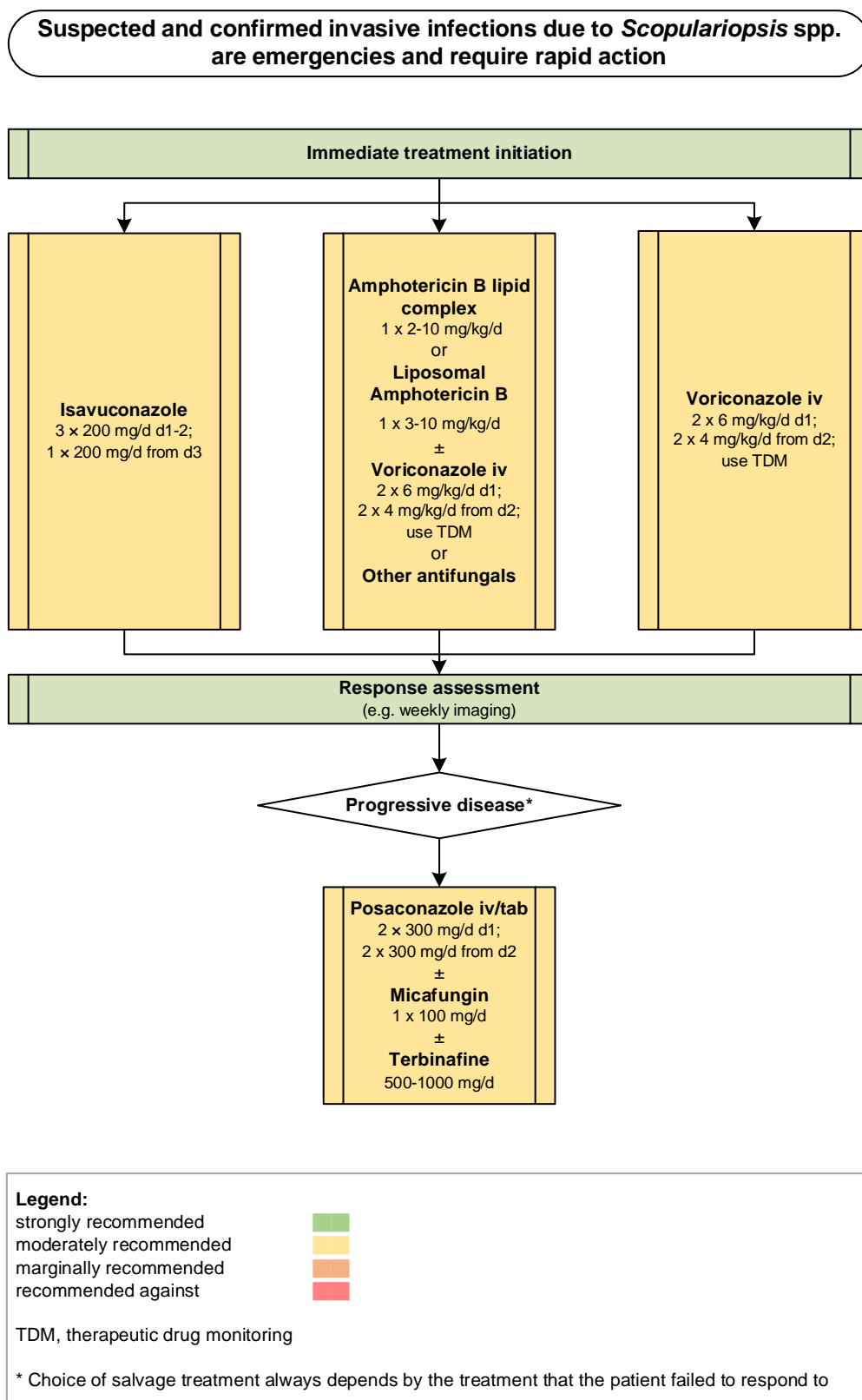
1799

The duration of therapy should be individualized, and based on the site and extent of infection, and on

1800

the immune status of the patient (**Figure 29**).

1801 Figure 29. Optimal treatment pathway for *Scopulariopsis* infections in adults when all treatment mo-
 1802 dalities and antifungal drugs are available



1803
 1804

1805 **Specific considerations on treatment of *Scopulariopsis* infection in children**

1806 **Evidence** – Only scarce data exist on invasive infections by *Scopulariopsis* spp. in chil-
 1807 dren^{1726,1735,1745,1756,1784,1791}. In these studies, all children had an underlying Hematological malignancy
 1808 and/or received a HSCT (**Table 37**).

1809 **Table 37. First-line antifungal therapy in children for *Scopulariopsis* infections**

Population	Intention	Intervention	SoR	QoE	Reference	Comment
Any	To cure	D-AmB iv	D	III	Krisner JCM 1995 ¹⁷⁹¹	N=1, 12 yrs, cutaneous infection + lung involvement, <i>Microascus</i> ; D-AmB, followed by ABCD, failure Review of N=5, 17-40 yrs, AmB +/- ICZ or miconazole; failure 5/5
					Neglia AJM 1987 ¹⁷⁸⁴	N=1, 17 yrs, lung infection, cAmB, + surgery, died
					Krisel CID 1994 ¹⁷³⁵	N=1, 12 yrs, sino-nasal infection, cAmB + G-CSF + ICZ for 6 mo, surgery, survived
AML + BMT	To cure	VCZ + CASPO	C	III	Steinbach JInfect 2004 ¹⁷⁵⁶	N=1, 10 yrs, skin and blood infection, survived
AML	To cure	L-AmB iv for 7 d, then switched to CASPO 1.5 mg/kg qd iv (first dose 2 mg/kg) + VCZ 7 mg/kg qd iv for 3 mo; then VCZ 150 mg po bid + CASPO 1.5 mg/kg iv tiw for 3 mo; followed by 6 mo VCZ 150 mg bid	B	III	Petit TLID 2011 ¹⁷⁴⁵	N=1, 11 mo, lung infection, survived
AML	To cure	VCZ 150 mg iv bid initially, after positive culture and susceptibility testing followed by L-AmB, surgery	B	III	Gluck IJPO 2011 ¹⁷²⁶	N=1, 17 yrs, sino-nasal infection, survived

Standard pediatric dose unless stated otherwise; ABCD, amphotericin B colloidal dispersion; AmB, amphotericin B; AML, acute myeloid leukemia; bid, twice a day; BMT, bone marrow transplant; CASPO, caspofungin; cAmB, oral encochleated amphotericin B; D-AmB, amphotericin B deoxycholate; G-CSF, granulocyte colony-stimulating factor; ICZ, itraconazole; iv, intravenous; L-AmB, liposomal amphotericin B; mo, month(s); po, orally; qd, once a day; QoE, quality of evidence; SoR, strength of recommendation; tiw, three times a week; VCZ, voriconazole; wk, week(s); yrs, years.

1810

1811 **Recommendations** – Treatment recommendations are extrapolated from those for adult patients, and
 1812 L-AmB or VCZ or both in combination are moderately recommended.

1813

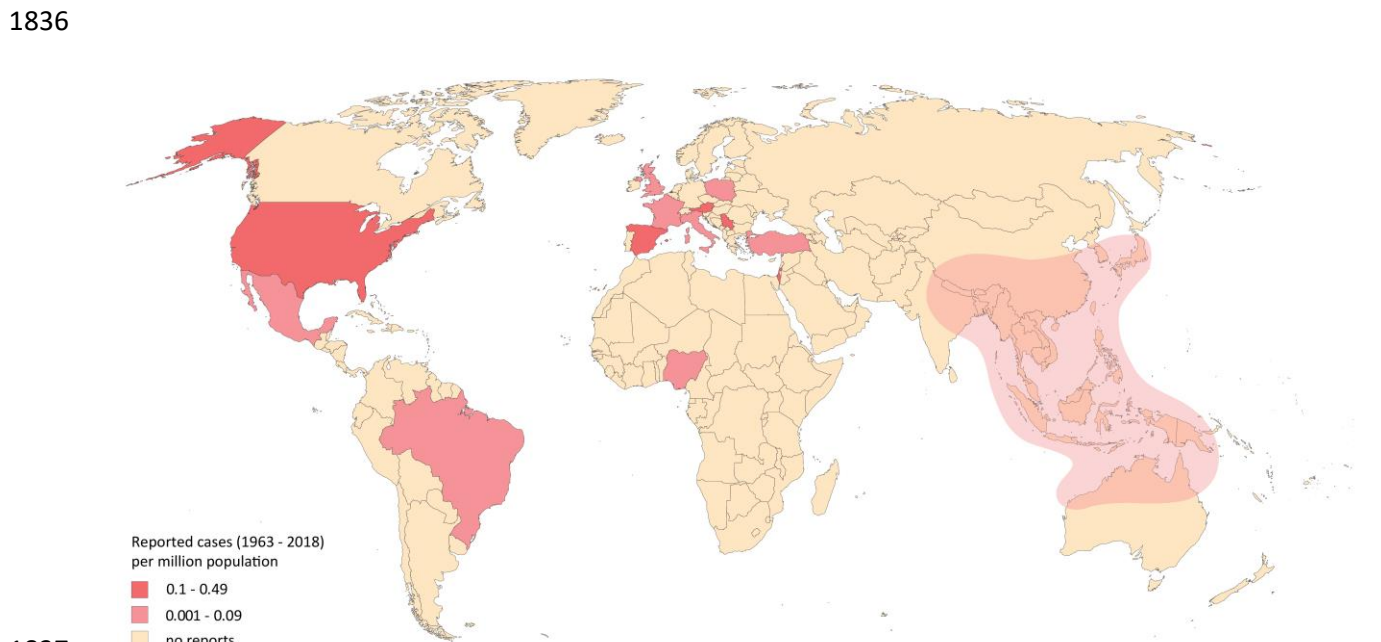
1814 **8. *Penicillium***

1815 **Epidemiology of infections caused by *Penicillium* spp.**

1816 Several *Penicillium* spp. have been redefined as *Talaromyces*; for example, *P. marneffeii* and *P. pur-*
 1817 *purogenum* are now named *Talaromyces marneffeii* and *Talaromyces purpurogenus*, respectively, and are
 1818 therefore not included in this section¹⁷⁹². *Penicillium* spp. are ubiquitous in nature and are used in drug

1819 and food production industries; e.g., *P. chrysogenum* (formerly *P. notatum*) is used to produce the antibi-
1820 otic penicillin and *P. camemberti* and *P. roqueforti* are used in cheese making^{1793,1794}. *Penicillium* spp. have
1821 been recognized as environmental allergens, which are frequently associated with hypersensitivity pneu-
1822 monitis in exposed workers^{1795,1796}, with unknown clinical significance. *Penicillium* spp. are rarely patho-
1823 genic in humans and are usually considered as laboratory contaminants or non-pathogenic colonizers in
1824 clinical material. However it is important to recognize that pathogenic species such as *P. chryso-*
1825 *genum*^{1797,1798}, *Penicillium citrinum*^{1799,1800}, *P. decumbens*^{1798,1801}, *P. commune*¹⁸⁰², *P. oxalicum*¹⁸⁰³ and *P.*
1826 *purpurogenum* (*T. purpurogenus*)¹⁷⁹⁸ grow well at 37°C, whereas the majority of common laboratory
1827 contaminants do not grow at body temperature. *Penicillium* spp. have been reported as a cause of oppor-
1828 tunistic infections leading to mycotic keratitis, endophthalmitis and lung infection^{1800,1804-1806}. Dissemi-
1829 nated infections such as endocarditis (following valve prosthesis insertion), CNS infection and fungemia
1830 also have been reported less frequently^{1798,1807,1808}. In addition to immunocompromised humans, fatal
1831 *Penicillium* infections in dogs have been described¹⁸⁰⁹ (Figure 30).

1832
1833 **Figure 30. Worldwide distribution of infections caused by *Penicillium* spp. (reported cases between**
1834 **1963 and 2018 per million population). The red cloud marks regions where penicilliosis (caused by var-**
1835 **ious *Penicillium* spp.) is endemic.**




1838 Cases of severe *Penicillium*-related infections reported in the medical literature were identified in a Pub-
1839 Med search on September 12, 2019. The search string included all *Penicillium* spp. listed in the Index Fun-
1840 gorum database (accessed September 12, 2019) and “(infection OR invasive OR disseminated OR patient
1841 [Title/Abstract] OR case [Title/Abstract] OR cases [Title/Abstract] OR report [Title/Abstract] OR isolate
1842 [Title/Abstract]) NOT marneffeii [Title]” that yielded 834 publications. In total, 75 cases from 13 countries
1843 were identified, 34 since the year 2000^{49,173,606,1116,1740,1798,1800,1804-1808,1810-1848}. Most cases were reported
1844 from the United States (n=40), Nigeria (n=8), Spain (n=6), and United Kingdom (n=5). Few cases of invasive
1845 *Penicillium*-related infections were reported from endemic countries^{1799,1803,1849,1850}. The number of cases
1846 reported between 1963 and 2018 is presented as cases per million population per country. The resident
1847 population per country was obtained from www.worldometers.info³²¹. The grey cloud marks regions
1848 where penicilliosis is endemic and from where travel-related cases are possible (South East Asia, North
1849 India, Bhutan and Nepal, North Korea, Papua-New Guinea, and North Australia¹⁸⁵¹⁻¹⁸⁵³).

1850

1851 **Diagnosis of *Penicillium* infections**

1852 **Evidence** - Conventional diagnosis using microscopy and culture is essential for identification of *Penicil-*
1853 *lium* spp. A positive culture from deep sterile tissues confirms the diagnosis^{1798,1799,1824}. Definitive diagnosis
1854 of *Penicillium*-related infections needs to recognize invasive fungal elements by histological examination
1855 of tissue sections^{1798,1799}. Infections caused by *Penicillium* spp. may be overlooked or misdiagnosed as
1856 aspergillosis due to nonspecific clinical and radiological findings¹⁸⁰³. In addition, direct microscopic exam-
1857 ination of both genera shows similar hyaline septate hyphae (hyalohyphomycosis) (**Figure 31**).

1858



1860
 1861 **Panel A**, *P. canis*, simple conidiophores, arising from creeping and aerial hyphae; **Panel B-C**, *P. capsulatum*,
 1862 short conidiophores and smooth-walled, monoverticillate. Phialides densely aggregated in small whorls;
 1863 **Panel D**, *P. chrysogenum*, conidiophores smooth-walled, penicilli usually terverticillate, flask-shaped phi-
 1864 alides; **Panel E**, *P. citrinum* conidiophores smooth-walled, penicilli biverticillate; **Panel F**, *P. decumbens*,
 1865 conidiophores rough-walled, penicilli monoverticillate, flask-shaped phialides; **Panel G-H**, *P. roqueforti*,

1866 conidiophores arising from submerged hyphae, relatively wide, with tuberculate walls, stage-branched
 1867 penicillin; **Panel I**, *P. spinulosum*, conidiophores, smooth- to rough-walled; penicilli monoverticillate, flask-
 1868 shaped phialides. Scale bars = 10 µm.

1869

1870 In routine laboratory evaluation, identification does not usually go beyond the genus level due to a huge
 1871 number of species and the lack of expertise in identification at species level. Morphological identification
 1872 to the species level is very difficult therefore molecular identification using ITS and β-tubulin sequencing
 1873 is the gold standard, with MALDI-TOF MS being an alternative^{559,1604,1854-1856}. Serological cross-reaction in
 1874 the GM assay or *Aspergillus*-specific lateral flow device test has been observed^{335,1857-1859}. Clinical diagnosis
 1875 using imaging techniques¹⁸⁵⁴ or non-culture-based tests such as BDG have been used to diagnose *Penicil-*
 1876 *lium* infections¹⁸⁶⁰. Antifungal susceptibility testing results are variable and species-specific^{559,1803,1861}.
 1877 Terbinafine and echinocandins showed the best *in vitro* activity against *Penicillium* spp., AmB showed
 1878 intermediate antifungal activity, while the azole MICs differed between isolates¹⁶⁰⁴, with higher MICs es-
 1879 pecially in *P. citrinum*, *P. oxalicum* and *Penicillium rubens*^{559,1604,1803} (**Table 38**).

1880 **Table 38. Microbiological, histopathological and imaging diagnostics of *Penicillium* infections**

Population	Intention	Intervention	SoR	QoE	Reference	Comment
Microscopy, culture, MIC testing						
Any	To diagnose	Tissue biopsy	A	III	Mok JCM 1997 ¹⁷⁹⁹	
					Lyratzopoulous JInfect 2002 ¹⁷⁹⁸	
					Hesse MMCR 2017 ¹⁸²⁴	
					Chowdhary OFID 2014 ¹⁸⁰³	
Any	To diagnose	Culture	A	III	Mok JCM 1997 ¹⁷⁹⁹	
					Lyratzopoulous JInfect 2002 ¹⁷⁹⁸	
					Keceli IUN 2005 ¹⁸³⁰	
					Iwasaki JJO 2008 ¹⁸⁶²	
					Oshikata BMCMPM 2013 ¹⁸⁵⁰	
					Hesse MMCR 2017 ¹⁸²⁴	
Any	To diagnose	Microscopy	A	III	Geltner Transpl 2013 ¹⁸⁶¹	
					Chowdhary OFID 2014 ¹⁸⁰³	
Any	To identify species	Microscopy	B	IIr	Visagie StudMycol 2014 ¹⁸⁶³	<i>Hamigera</i> , <i>Paecilomyces</i> , <i>Rasamsonia</i> , <i>Sagenomella</i> , <i>Talaromyces</i> , and <i>Trichocoma</i> also show <i>Penicillium</i> -like “brush” structures
Any	To guide treatment and correlate MIC with outcome	Antifungal susceptibility testing, EUCAST method	B	III	Alastruey-Izquierdo AAC 2018 ⁵⁵⁹	
Any	To guide treatment and correlate MIC with outcome	Antifungal susceptibility testing, CLSI method	B	III	Chowdhary OFID 2014 ¹⁸⁰³	
					Geltner Transplantation 2013 ¹⁸⁶¹	
					Barcus ACMA 2005 ¹⁸⁶⁴	
					Lyratzopoulos JInfect 2002 ¹⁷⁹⁸	
					Kantarcioglu Mycoses 2004 ¹⁸²⁹	

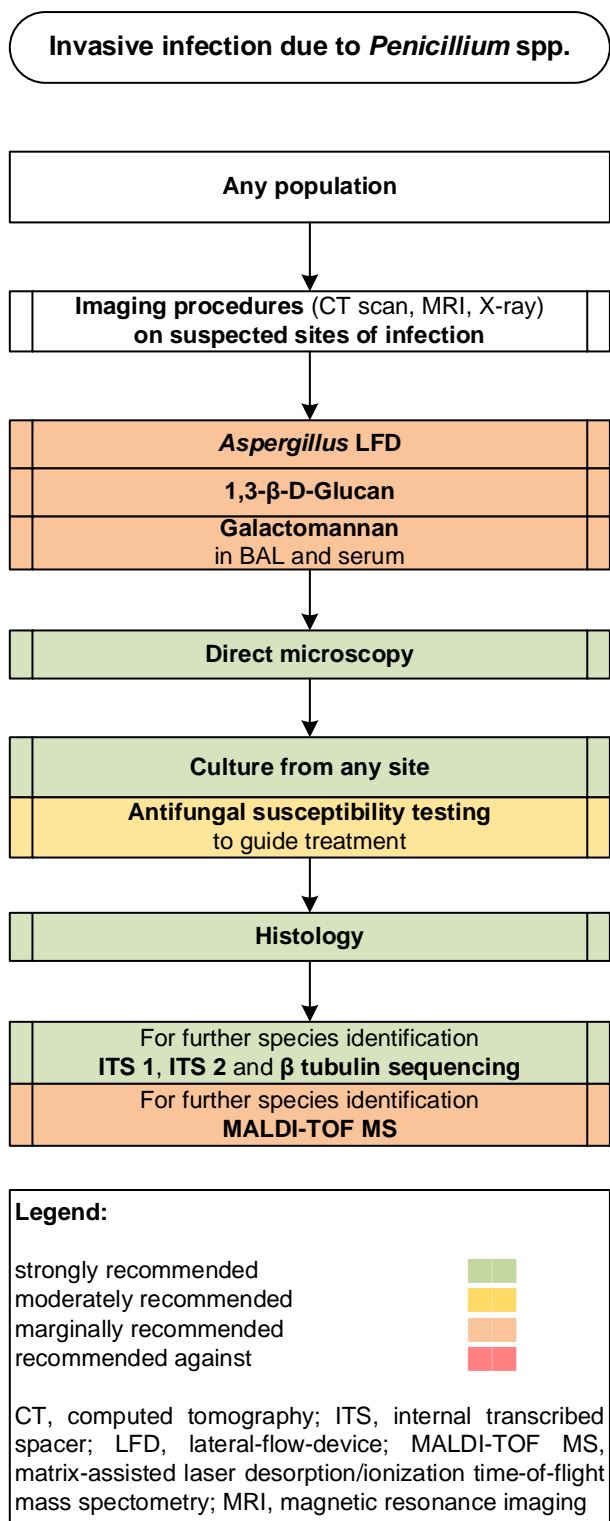
Any	To determine <i>in vitro</i> activity by generating MIC	Antifungal susceptibility testing, CLSI method	C	Ilu	Lyratzopoulos JInfect 2002 ¹⁷⁹⁸ Guevara-Suarez JCM 2016 ¹⁶⁰⁴	
Serology assays						
Any	To detect <i>Penicillium</i> spp. other than <i>T. marneffeii</i>	Galactomannan EIA	C	III	Mennink-Kersten LID 2004 ¹⁸⁶⁵	May cross-react with <i>Penicillium</i> spp.
Any	To detect <i>Penicillium</i> spp. other than <i>T. marneffeii</i>	<i>Aspergillus</i> -specific Lateral Flow Device	C	III	Thornton CVI 2008 ³³⁵ Prattes Mycoses 2015 ¹⁸⁵⁷ Willinger Transpl 2014 ¹⁸⁵⁸	Cross-reacts with <i>Penicillium</i> spp. (but not with <i>T. marneffeii</i>)
Any	To detect <i>Penicillium</i> spp. other than <i>T. marneffeii</i> in blood	BDG in serum	C	III	Odabasi MedMycol 2006 ¹⁸⁶⁰	Cell wall of <i>Penicillium</i> spp. contains BDG
Nucleic-acid based assays						
Any with sinusitis	To diagnose	Beta-tubulin sequencing (from sinus content)	B	III	Radulesco Mycopathol 2018 ¹⁸⁵⁴	N=1, fungus ball, <i>P. roqueforti</i>
Any	To diagnose	28S rRNA broad-range real-time PCR + sequencing in various clinical specimen	C	II	Vollmer JCM 2008 ¹⁸⁵⁵	Panfungal, <i>Penicillium</i> just to the genus level
Any	To identify species	MALDI-TOFF MS	C	III	Lau BMCM 2016 ¹⁸⁶⁶	
Any	To identify species	Culture + ITS/beta-tubulin sequencing	A	Ilu	Guevara-Suarez JCM 2016 ¹⁶⁰⁴ Mohammadi JRMS 2017 ¹⁸⁶⁷ Oshikata BMCMP 2013 ¹⁸⁶⁸ Chen BMCID 2013 ¹⁸⁶⁹ Reboux JMM 2019 ¹⁸⁵⁶	N=77 clinical isolates N=1 N=1
Tissue-based diagnosis						
Any	To diagnose	Histopathology of biopsy tissue	A	III	Barcus ACMA 2005 ¹⁸⁶⁴ Lyratzopoulos JInfect 2002 ¹⁷⁹⁸ Lyratzopoulos JInfect 2002 ¹⁷⁹⁸ Hall AHJ 1974 ¹⁸²³ Yoshida Chest 1992 ¹⁸⁷⁰ Gelfand SMJ 1990 ¹⁸²⁰ D'Antonio JCM 1997 ¹⁸⁷¹	
Imaging studies						
Any	To detect sinusitis	Cranial CT	A	III	Radulesco Mycopathol 2018 ¹⁸⁵⁴	N=1
Any	To detect dissemination	PET/CT	B	III	Qiu BMCID 2015 ¹⁸⁷²	N=2
Any	To detect and assess brain lesions / abscesses	Cranial CT	B	III	Beh MJM 2009 ¹⁸⁷³ Noritomi RIMT 2005 ¹⁸⁷⁴ Zhang MCO 2016 ¹⁸⁷⁵	N=1 N=1 N=1
Any	To detect and assess brain lesions / abscesses	MRI	A	III	Ye IJMM 2015 ¹⁸⁷⁶ Beh MJM 2009 ¹⁸⁷³ Noritomi RIMT 2005 ¹⁸⁷⁴ Zhang MCO 2016 ¹⁸⁷⁵	N=1 N=1 N=1 N=1
Any	To detect and assess pneumonia	Chest radiography	C	III	Cheng MedMycol 1998 ¹⁸⁷⁷ Hung AJRCCM 2013 ¹⁸⁷⁸ Lu CMJ 2005 ¹⁸⁷⁹ Yadav IJPM 2019 ¹⁸⁸⁰ Ye IJMM 2015 ¹⁸⁷⁶ Sun CMI 2006 ¹⁸⁸¹ McShane Thorax 1998 ¹⁸⁸² Chen BMCID 2013 ¹⁸⁶⁹ Zhang MCO 2016 ¹⁸⁷⁵	N=3 N=1 N=6 N=1 N=1 N=24 N=1 N=1 N=1
Any	To detect and assess pneumonia	Chest CT	A	III	Cheng MedMycol 1998 ¹⁸⁷⁷ Geltner Transpl 2013 ¹⁸⁶¹ Hung AJRCCM 2013 ¹⁸⁷⁸ Lu CMJ 2005 ¹⁸⁷⁹ Yadav IJPM 2019 ¹⁸⁸⁰ Ye IJMM 2015 ¹⁸⁷⁶ Jung JKMS 2012 ¹⁸⁸³ Santos MedMycol 2006 ¹⁸⁸⁴ Lin HIVM 2009 ¹⁸⁸⁵	N=3 N=1 N=1 N=3 N=1 N=2 N=1 N=1, 8 yo, CGD N=19

					McShane Thorax 1998 ¹⁸⁸²	N=1
					Qiu BMCID 2015 ¹⁸⁷²	N=14
					Chen BMCID 2013 ¹⁸⁶⁹	N=1
					Aviles-Robles IJID 2016 ¹⁸⁰⁴	N=1
					Beh MJM 2009 ¹⁸⁷³	N=1
					Wang Mycopathol 2018 ¹⁸⁸⁶	N=4
					Zhang MCO 2016 ¹⁸⁷⁵	N=1
					Chowdhary OFID 2014 ¹⁸⁰³	
Any	To detect and assess abdominal/lymph node infections	Abdominal CT	A	III	George IJMM 2008 ¹⁸⁸⁷	N=1
					Lu CMJ 2005 ¹⁸⁷⁹	N=1
					Yadav IJPM 2019 ¹⁸⁸⁰	N=1
					Mancao PedRadiol 2003 ¹⁸³⁵	N=1
					Othman ATP 2006 ¹⁸⁸⁸	N=1
					Aviles-Robles IJID 2016 ¹⁸⁰⁴	N=1
					Beh MJM 2009 ¹⁸⁷³	N=1
Any	To detect and assess bone infections	Bone radiography	B	III	Chan JBJSB 1990 ¹⁸⁸⁹	N=1
					Louthrenoo BJR 1994 ¹⁸⁹⁰	N=8
					Sudjaritruk BMCID 2012 ¹⁸⁹¹	N=1
Any	To detect and assess bone infections	CT spine / bones	A	III	Louthrenoo BJR 1994 ¹⁸⁹⁰	N=1
					Qiu BMCID 2015 ¹⁸⁷²	N=14
BDG, Beta-D-Glucan; CGD, chronic granulomatous disease; CLSI, Clinical and Laboratory Standards Institute; CT, computed tomography; EIA, enzyme-linked immunoassay; EUCAST, European Committee for Antimicrobial Susceptibility Testing; ITS, internal transcribed spacer; MRI, magnetic resonance imaging; PCR, polymerase chain reaction; PET, positron emission tomography; pt, patient; QoE, quality of evidence; rRNA, ribosomal ribonucleic acid; SoR, strength of recommendation; yo, years old						

1881

1882 **Recommendations** – The guideline group strongly recommends conventional diagnostic techniques such
1883 as microscopy and culture as well as histopathological analysis of tissue sections. Molecular diagnosis in
1884 clinical specimens is moderately supported, while ITS and β -tubulin sequencing of isolates is strongly rec-
1885 ommended for species identification. The group marginally supports GM, BDG and the *Aspergillus* LFD for
1886 diagnosis of *Penicillium*-related infections. MIC determination is moderately recommended to guide treat-
1887 ment. Imaging is variably recommended depending on the case and patient condition, but strongly rec-
1888 ommended to clinically diagnose invasive infections (**Figure 32**).

1889 **Figure 32. Optimal diagnostic pathway for *Penicillium* infections, when all imaging and assay tech-**
 1890 **niques are available**



1891

1892

1893 **Treatment approaches for infections caused by *Penicillium* spp.**

1894 Treatment in adults

1895 **Evidence** – Data guiding the treatment of *Penicillium* infections is scarce and mainly obtained from case
1896 reports. For first-line antifungal therapy, L-AmB has been used in many instances with variable results for
1897 invasive infections¹⁷⁹⁸. Failure has been reported with both AmB alone or in combination with other an-
1898 tifungal agents^{1798,1800}, while successful treatment with AmB has been reported in other case series^{1845,1892}.
1899 Clinical failure of VCZ treatment may be related to high VCZ MICs in infections caused by *P. oxalicum*¹⁸⁰³,
1900 a finding not uncommon in other *Penicillium* spp. such as *P. citrinum* and *P. rubens*^{559,1604}. PCZ has been
1901 successfully used to treat infections caused by *P. oxalicum* with high MICs against VCZ¹⁸⁰³. Treatment du-
1902 rations of 6 weeks have been reported in patients with successful outcome¹⁸⁰³. Salvage treatment with
1903 parenteral VCZ resulted in satisfactory global response in 9 of 10 patients in one study³⁷⁶. In invasive in-
1904 fections, surgical resection of pulmonary nodules resulted in a successful outcome in most reported
1905 cases^{1854,1869} (Table 39).

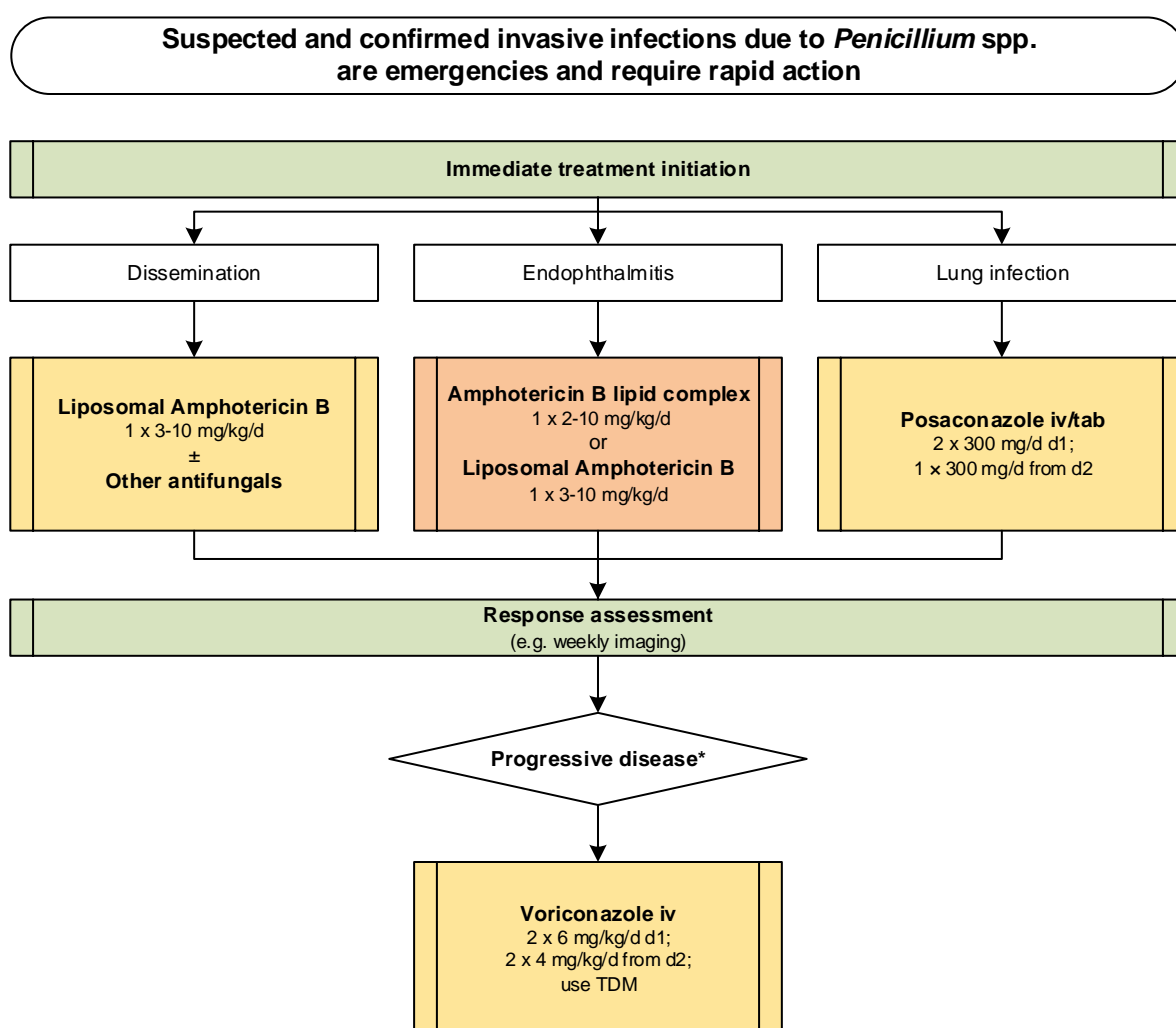
1906 **Table 39. Therapy for *Penicillium* infections**

Population	Intention	Intervention	SoR	QoE	Reference	Comment
First-line antifungal therapy						
Exogenous endophthalmitis	To cure	FCZ po; AmB intravitreal	D	III	Garg JCRS 2016 ¹⁸⁰⁰	N=1, <i>P. citrinum</i> , failure
Exogenous endophthalmitis	To cure	AmB iv, topical, intracameral	C	III	Iwasaki JJO 2008 ¹⁸⁶²	N=1, <i>Penicillium</i> spp., success
Exogenous endophthalmitis	To cure	MICA 100 mg qd for 9 d, VCZ 200 mg qd po for 9 d + 5-FC 6000 mg qd for 9 d, + VCZ eye drop qds	C	III	Kanda IMCRJ 2018 ¹⁸⁹²	N=1, <i>Penicillium</i> spp., success
Endogenous endophthalmitis	To cure	AmB iv, 5-FC	C	III	Swan AJO 1985 ¹⁸⁴⁵	N=1, <i>Penicillium</i> spp., success
Any with pulmonary infection due to <i>P. oxalicum</i>	To cure	PCZ	B	III	Chowdhary OFID ¹⁸⁰³	N=2, Posaconazole oral solution for 6 weeks, both cured
Any with disseminated infection	To cure	L-AmB +/- other drugs e.g. ICZ, 5-FC	B	III	Lyratzopoulos JInfect 2002 ¹⁷⁹⁸	N=1, <i>P. chrysogenum</i> , L-AmB + 5-FC, failure
					Lyratzopoulos JInfect 2002 ¹⁷⁹⁸	N=1, <i>P. decumbens</i> , L-AmB + ICZ, outcome unclear
Antifungal salvage treatment						
Any	To cure	VCZ iv	B	IIu	Perfect CID 2003 ³⁷⁶	N=10, response 9/10
Other Treatment Options						
Any	To cure	Surgery	B	IIIu	Chen BMCID 2013 ¹⁸⁶⁹	N=1, <i>P. capsulatum</i> , success
					Aviles-Robles IJID 2016 ¹⁸⁰⁴	N=1, <i>P. chrysogenum</i> , success
					Radulesco Mycopathol 2018 ¹⁸⁵⁴	N=1, <i>P. roqueforti</i> , success
Treatment duration						
Any	To cure	≥6 wk antifungal treatment	C	III	Chowdhary OFID 2014 ¹⁸⁰³	N=3, <i>P. oxalicum</i> , response to PCZ 2/3, failure 1/3
Standard dose unless stated otherwise ; 5-FC, 5-Fluorocytosine; AmB, amphotericin B; d, day(s); FCZ, fluconazole; iv, intravenous; ICZ, itraconazole; L-AmB, liposomal amphotericin B; MICA, micafungin; PCZ, posaconazole; po, orally; qd, once a day; qds, four times a day; QoE, quality of evidence; SoR, strength of recommendation; VCZ, voriconazole; wk, week(s).						

1907

1908 **Recommendations** – The guideline group moderately supports L-AmB alone or in combination with
 1909 other antifungals for invasive infections caused by *Penicillium* spp. The guideline group marginally sup-
 1910 ports systemic treatment with lipid-based formulations of AmB for *Penicillium*-related endophthalmitis.
 1911 The group moderately recommends salvage therapy with parenteral VCZ. Surgery is moderately recom-
 1912 mended when feasible (**Figure 33**).

1913
 1914 **Figure 33. Optimal treatment pathway for *Penicillium* infections in adults when all treatment modalities and antifungal drugs are available**
 1915



Legend:

strongly recommended ■
 moderately recommended ■
 marginally recommended ■
 recommended against ■

TDM, therapeutic drug monitoring

* Choice of salvage treatment always depends by the treatment that the patient failed to respond to

1916

1917 **Specific considerations on treatment of infections caused by *Penicillium* spp. in children**

1918 **Evidence** – Pulmonary infections caused by *Penicillium* spp. have been described in children following lung
1919 transplantation and in those with CGD¹⁸¹¹ (**Table 40**).

1920 **Table 40. First-line antifungal therapy in children for *Penicillium* infections**

Population	Intention	Intervention	SoR	QoE	Reference	Comment
Lung trans-plant	To cure	VCZ + ANID	C	III	Ammermann ClinTransplant 2017 ¹⁸¹¹	N=3, <i>Penicillium</i> spp., 3/3 survived

Standard pediatric dose unless stated otherwise; ANID, anidulafungin; QoE, quality of evidence; SoR, strength of recommendation; VCZ, voriconazole.

1921
1922 **Recommendations** – VCZ is moderately recommended as a first-line treatment option, although quality
1923 of evidence is weak¹⁸¹¹.

1924

1925 **9. Non-marneffeii *Talaromyces***

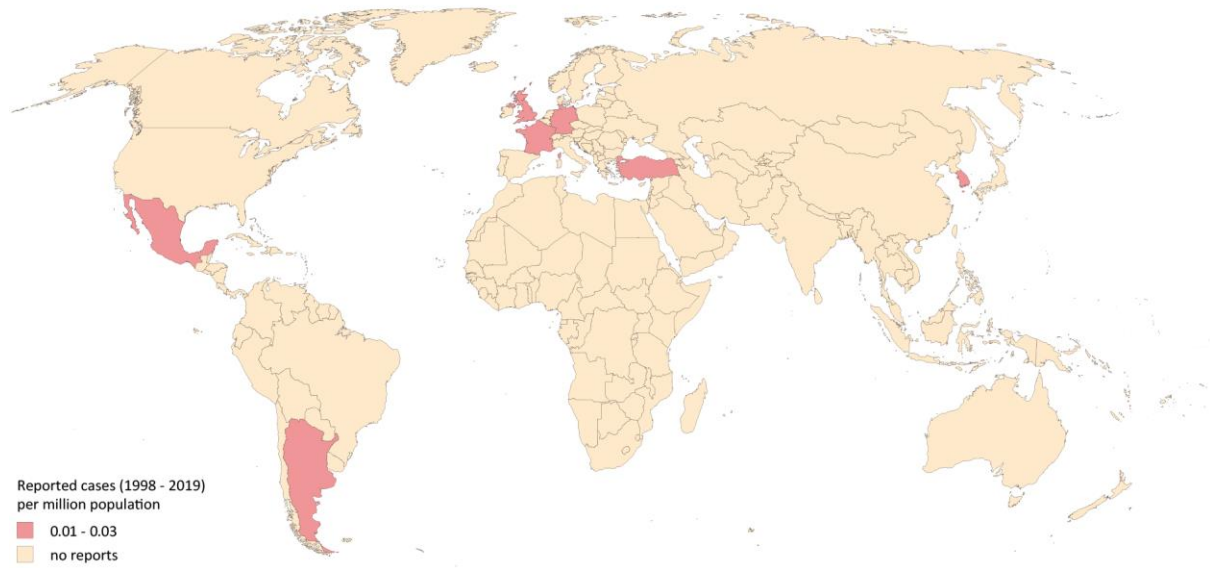
1926 **Epidemiology of infections caused by non-marneffeii *Talaromyces* spp.**

1927 *Talaromyces* spp. belong to the order Eurotiales and are ubiquitously found in air, soil, and indoor envi-
1928 ronments. The vast majority of reported infections due to *Talaromyces* spp. are related to *T. marneffeii*
1929 (formerly *P. marneffeii*), which is endemic in China and in tropical regions of South East Asia, and are
1930 mostly associated with advanced HIV infection¹⁸⁵¹. Very few cases of talaromycosis caused by species
1931 other than *marneffeii* have been reported from non-endemic regions e.g., Europe and America over the
1932 past 20 years^{1798,1884,1893-1898}. Infections have occurred in immunocompromised patients with CGD, malign-
1933 nancy, or long-term corticosteroid treatment for other chronic diseases. Infections are caused by *T. pur-*
1934 *pureogenus*, *T. stollii*, *T. piceae*^{1884,1897}, and *T. amestolkiae*, and mainly affect the lung and rarely other
1935 organs^{1798,1898}. Hematogenous spread is common in *T. marneffeii*-related infections; conversely, dissemi-
1936 nation has rarely been reported for other *Talaromyces* spp.¹⁸⁹⁷ (**Figure 34**).

1937

1938
1939

Figure 34. Worldwide distribution of infections caused by non-marneffeii *Talaromyces* spp. (reported cases between 1998 and 2019 per million population)



1940
1941

1942 Cases of severe *Talaromyces*-related infections reported in the medical literature were identified in a Pub-
1943 Med search on July 29, 2019. The search string included all *Talaromyces* spp. that were identified in the
1944 Index Fungorum database (accessed 27. July 2019): (*Talaromyces* and *T.* each plus the following: *albob-*
1945 *iverticillius, amelstokiae, apiculatus, assiutensis, atroroseus, aurantiacus, austrocalifornicus, bacillisporus,*
1946 *barcinensis, boninensis, brunneus, calidicanus, cecidicola, coalescens, convolutus, dendriticus, dextrii, du-*
1947 *clauxii, echinosporus, emodensis, erythromellis, euchlorocarpus, flavus, funiculosus, galapagensis, hachi-*
1948 *joensis, helicus, indigoticus, intermedius, islandicus, lagunensis, leycettanus, loliensis, luteus, macrospo-*
1949 *rus, malagensis, mimosinus, minioluteus, muroii, palmae, panamensis, paucisporus, phialosporus, piceus,*
1950 *pinophilus, pittii, primulinus, proteolyticus, pseudostromaticus, purpureus, purpureogenus, rademirici,*
1951 *radicus, ramulosus, retardatus, rotundus, ruber, rubicundus, rugulosus, ryukyuensis, sabulosus, siamensis,*
1952 *stipitatus, stollii, subinflatus, sublevisporus, tardifaciens, thermocitrinus, trachyspermus, ucrainicus, uda-*
1953 *gawae, unicus, variabilis, varians, vermiculatus, flavus, vermiculatus, verruculosus, viridis, viridulus, wort-*
1954 *mannii*) NOT *marneffeii* [title]) that yielded 608 publications. In total, 10 cases were identified from 7 coun-

1955 tries^{1116,1798,1884,1893-1898}. Number of cases reported between 1998 and 2019 is presented as cases per mil-
 1956 lion population per country. The resident population per country was obtained from www.worldome-
 1957 ters.info³²¹.

1958
 1959 **Diagnosis of non-marneffeii Talaromyces infections**
 1960 **Evidence** - Non-marneffeii Talaromyces spp. are rarely encountered in clinical specimens submitted to the
 1961 diagnostic laboratory. Conventional diagnosis by microscopy and culture is essential to see the *Penicil-*
 1962 *lium*-like structures^{1893,1895}. Histopathological examination is crucial to demonstrate invasiveness with sep-
 1963 tate hyphae¹⁸⁸⁴. Morphological identification is very challenging, therefore sequencing of the ITS and β -
 1964 tubulin-encoding genes has been applied for species identification¹⁸⁵⁶. Imaging with CT scan helps with
 1965 the localisation of fungal infections¹⁸⁹⁴. To guide treatment, antifungal susceptibility testing is important
 1966 to correlate MIC with treatment outcome. In one study echinocandins seem to have the best *in vitro* ac-
 1967 tivity¹⁶⁰⁴ (Table 41).

1968 **Table 41. Microbiological, histopathological and imaging diagnostics for non-marneffeii Talaromyces infections**

Population	Intention	Intervention	SoR	QoE	Reference	Comment
Microscopy, culture, MIC testing						
Any	To diagnose	Tissue biopsy stained by GMS	A	III	Sili MMCR 2015 ¹⁸⁹⁵	By GMS staining, hyphal structures were shown and by PCR investigation <i>Talaromyces</i> sp. was identified
Any	To diagnose	Culture	A	IIIu	Villanueva-Lozano JIC 2017 ¹⁸⁹³	N=1, BAL culture on PDA
Any	To diagnose	Microscopy	A	IIIu	Zainudin PSHC 2018 ¹⁸⁹⁹	Microscopy revealed <i>Penicillium</i> -like structure, identified as <i>P. chrysogenum</i> by PCR
					Villanueva-Lozano JIC 2017 ¹⁸⁹³	N=1, Microscopy showed <i>Penicillium</i> -like structure proved by PCR amplification as <i>T. amestolkiae</i>
Any	To guide treatment and correlate MIC with outcome	Broth microdilution (M-38A2 CLSI)	B	IIIu	Guevara-Suarez JCM 2016 ¹⁶⁰⁴	Susceptibility testing of <i>T. amestolkiae</i> , <i>Talaromyces purpurpurogenus</i> . Best <i>in vitro</i> effect had echinocandins, however, only a few <i>Talaromyces</i> isolates were tested in this study
Nucleic-acid based assays/MALDI-TOF MS						
Any	To identify clinically important <i>T. marneffeii</i> and non-marneffeii spp.	Bruker MALDI-TOF MS system	C	III	Lau BMCM 2016 ¹⁸⁶⁶	N=59 isolates with documented penicilliosis. Database is suboptimal. Among four species phylogenetically closely related to <i>T. marneffeii</i> , only <i>Penicillium brevicompactum</i> and <i>P. chrysogenum</i> were identified, while <i>Talaromyces aurantiacus</i> and <i>Talaromyces stipitatus</i> strains were not identified
Any	To identify species	ITS1/ITS2/ITC sequencing for molecular species identification of <i>Talaromyces</i> -/ <i>Penicillium</i> -like fungi (25-30°C) yeast-like (35-37°C) forming red pigment	A	III	Ryu LMO 2017 ¹⁹⁰⁰	Sanger sequencing of the ITS regions covering ITS1, 5.8S, and ITS2, and the β -tubulin gene from the genomic DNA revealed <i>Talaromyces albobiverticillius</i>

Tissue-based diagnosis						
Any	To diagnose	Histopathology of biopsy tissue	A	III	Santos MedMycol 2006 ¹⁸⁸⁴	Multinucleated giant phagocytic cell with budding fungal elements in patient with pulmonary nodule
Imaging studies						
Any	To assess the clinical manifestations and imaging characteristics of pneumonia caused by <i>Talaromyces</i> spp.	Chest CT	A	III	Atalay LIM 2016 ¹⁸⁹⁴	N=1, bilobular infiltrates and <i>T. purpurogenus</i> in sputum
BAL, bronchoalveolar lavage; DNA, deoxyribonucleic acid; CLSI, Clinical and Laboratory Standards Institute; CT, computed tomography; GMS, Grocott-Gomori's methenamine silver; ITS, internal transcribed spacer; MALDI-TOF MS, matrix assisted laser desorption ionization-time of flight mass spectrometry; MIC, minimal inhibitory concentration; PCR, polymerase chain reaction; PDA, ; PDA, potato dextrose agar; QoE, quality of evidence; SoR, strength of recommendation; <i>T.</i> , <i>Talaromyces</i>						

1969

1970 **Recommendations** – The guideline group strongly recommends microscopy and culture to diagnose *Tal-*

1971 *aromyces*-related infections, as well as histopathological evaluation (GMS staining) of tissue biopsies to

1972 distinguish between true infection and colonization. Molecular identification of isolates by sequencing

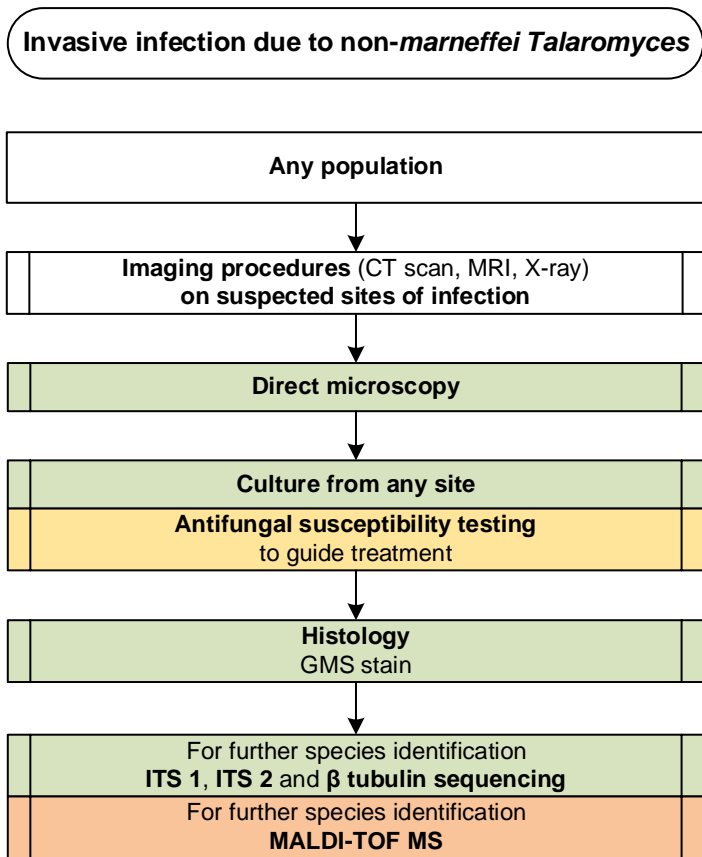
1973 the ITS regions is strongly recommended, while MALDI-TOF MS is marginally recommended by the group

1974 for species identification. Antifungal susceptibility testing is moderately recommended to guide treatment

1975 and correlation between MIC and outcome. CT scan is strongly recommended to clinically diagnose the

1976 infections (**Figure 35**).

1977 **Figure 35. Optimal diagnostic pathway for non-marneffeii Talaromyces infections , when all imaging**
 1978 **and assay techniques are available**



Legend:

strongly recommended	■
moderately recommended	■
marginally recommended	■
recommended against	■

CT, computed tomography; GMS stain, Grocott's methenamine silver stain; ITS, internal transcribed spacer; MALDI-TOF MS, matrix-assisted laser desorption/ionization time-of-flight mass spectrometry; MRI, magnetic resonance imaging

1979

1980

1981

1982 **Treatment approaches to non-marneffeii Talaromyces infection**

1983 Treatment in adults

1984 **Evidence** – In view of the infrequency/rarity of infections caused by non-marneffeii Talaromyces spp., in-

1985 formation on antifungal treatment is available from a few published case reports. L-AmB has been suc-

1986 cessfully used as a first-line treatment¹⁷⁹⁸. Salvage treatment of non-*marneffe* *Talaromyces*-related infec-
 1987 tions with a combination of AmB plus ICZ/TRB has been unsuccessful¹⁷⁹⁸. In invasive infections, surgical
 1988 resection of pulmonary nodules resulted in a successful outcome¹⁸⁸⁴ (Table 42).

1989 **Table 42. Therapy for non-*marneffe* *Talaromyces* infections**

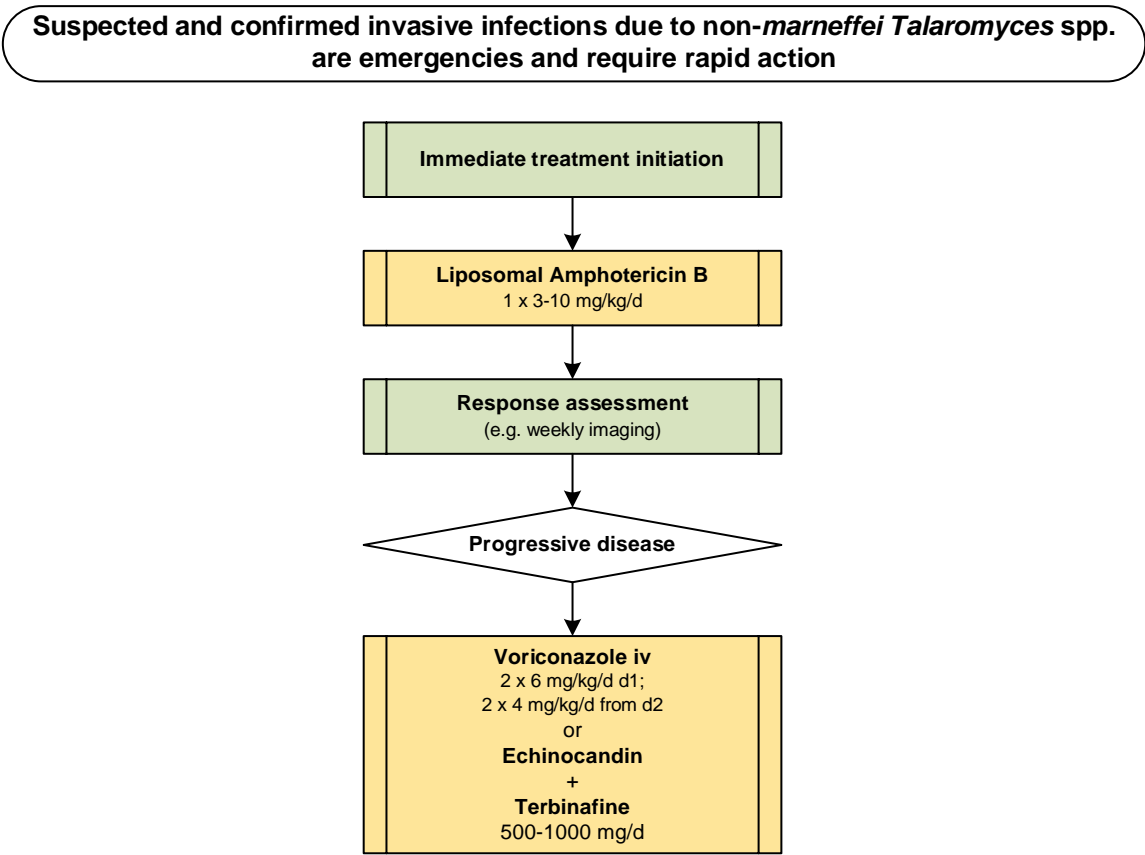
Population	Intention	Intervention	SoR	QoE	Reference	
First-line antifungal therapy						
Any	To cure	L-AmB	B	III	Lyratzopoulos JInfect 2002 ¹⁷⁹⁸ Guevera-Suarez JCM 2016 ¹⁶⁰⁴ Lyratzopoulos JInfect 2002 ¹⁷⁹⁸	Higher MICs for azoles compared to AmB and echinocandins N=1, CGD, <i>Talaromyces purpureogenus</i> , success
Antifungal salvage treatment						
Any	To cure	Lipid formulations AmB + ICZ + /- TRB	C	III	Lyratzopoulos JInfect 2002 ¹⁷⁹⁸	N=2, 2/2 died
Any	To cure	VCZ iv	C	III	Santos MedMycol 2006 ¹⁸⁸⁴	N=1, pulmonary nodule and adjacent rib osteomyelitis, <i>Talaromyces picea</i> , + surgery, cured
Any	To cure	TRB and echinocandins	C	III	Guevera-Suarez JCM 2016 ¹⁶⁰⁴	TRB and echinocandins had higher <i>in vitro</i> activity than AmB
Other treatment options						
Any	To cure	Surgery	B	III	Santos MedMycol 2006 ¹⁸⁸⁴	N=1, <i>Talaromyces picea</i> , success
Treatment duration						
Any	To cure	12 wk of therapy	C	III	Lyratzopoulos JInfect 2002 ¹⁷⁹⁸	N=1, survived
Standard dose unless otherwise stated AmB, amphotericin B; CGD, chronic granulomatous disease; ICZ, itraconazole; L-AmB, liposomal amphotericin B; MIC, minimal inhibitory concentration; PCZ, posaconazole; QoE, quality of evidence; SoR, strength of recommendation; wk, week(s)						

1990

1991 **Recommendations** – Treatment with L-AmB is moderately recommended by the group. The guideline
 1992 group moderately recommends surgical resection, and marginally salvage therapy with VCZ or an echi-
 1993 nocandin plus TRB (Figure 36).

1994

1995 **Figure 36. Optimal treatment pathway for non-marneffeii Talaromyces infections in adults when all**
 1996 **treatment modalities and antifungal drugs are available**



Legend:

- strongly recommended
- moderately recommended
- marginally recommended
- recommended against

1997

1998

1999

2000 **Specific considerations on treatment of non-marneffeii Talaromyces infections in children**

2001 **Evidence** – Specific pediatric data and case reports are lacking.

2002 **Recommendations** – Treatment recommendations follow those in adults.

2003

2004 **10. Paecilomyces**

2005 **Epidemiology of Paecilomyces infections**

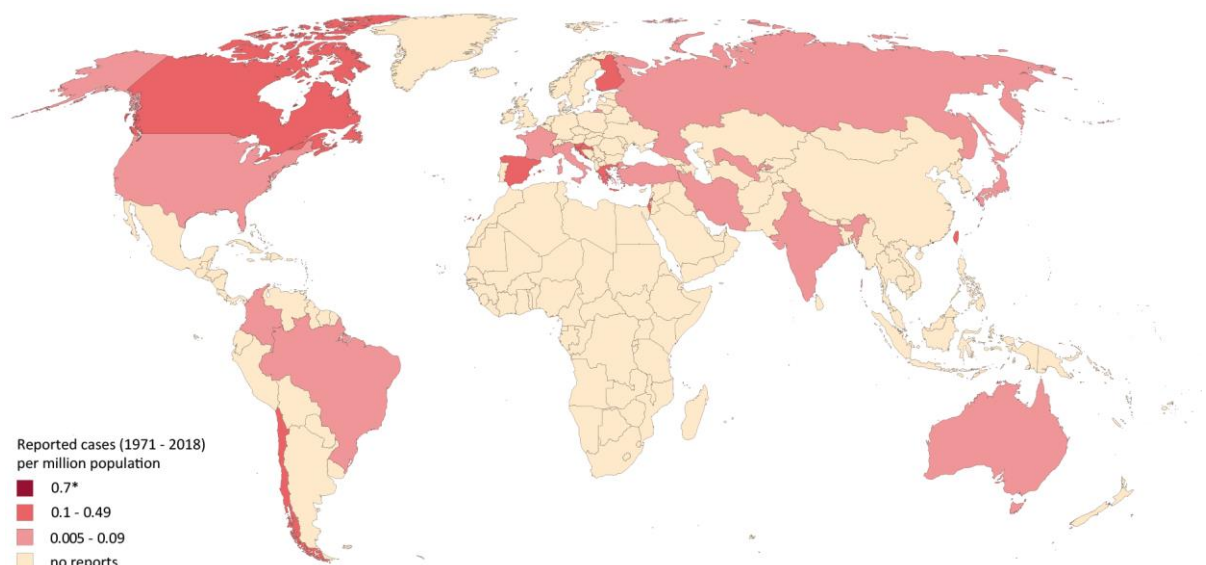
2006 *Paecilomyces* spp. are members of the order Eurotiales. They are filamentous, saprophytic, and thermo-

2007 tolerant fungi that are ubiquitously found in soil, food products, decaying organic material, and house

2008 dust¹⁹⁰¹. In the past, *Paecilomyces* spp. were often considered as contaminants when isolated clinically,
2009 but recently they are becoming recognized worldwide as important cause of infections primarily in im-
2010 munocompromised patients or patients with indwelling catheters¹⁹⁰². However, immunocompetent indi-
2011 viduals can also be affected, *e.g.*, by direct inoculation of fungus following trauma^{1903,1904}. The majority
2012 of these infections is caused by *P. variotii* spp. complex that is composed of *P. variotii sensu stricto*, *P.*
2013 *formosus*, *P. divaricatus*, *P. brunneolus*, and *P. dactylethromorphus*¹⁹⁰⁵. *P. variotii* is the asexual state of
2014 *Byssochlamys spectabilis*. Microbiological identification of *Paecilomyces* spp. is challenging due to its
2015 morphological similarity to some *Rasamsonia* and *Hamigera* spp.¹⁹⁰⁶. Phylogenetic analyses showed that
2016 *Purpureocillium lilacinum* (formerly *Paecilomyces lilacinus*) belongs to the order Hypocreales and thus
2017 shall not be considered together with *Paecilomyces* spp.¹⁹⁰⁵. Species identification is crucial for patient
2018 management since both species appear to have different susceptibility profiles and clinical response to
2019 antifungal agents^{1903,1907}. *P. variotii* infection can affect many different organ systems and presents with
2020 various manifestations including pneumonia, skin and soft tissue infections, endophthalmitis, peritonitis,
2021 osteomyelitis, and bloodstream infections, especially in immunocompromised patients¹⁹⁰⁸⁻¹⁹¹⁴ (**Figure**
2022 **37**).

2023

2024 **Figure 37. Worldwide distribution of infections caused by *Paecilomyces* spp. (reported cases between**
2025 **1971 and 2018 per million population)**



2026

2027

2028 Cases of severe *Paecilomyces*-related infections reported in the medical literature were identified in a
2029 PubMed search on October 31, 2019 including all *Paecilomyces* spp. identified in the Index Fungorum da-
2030 tabase (accessed 27. July 2019) in the PubMed search string (*Paecilomyces* plus the following: *antarcticus*,
2031 *aspergilloides*, *atrovirens*, *baarnensis*, *borysthenicus*, *breviramosus*, *brunneolus*, *brunneolus*, *burcii*, *byssos-*
2032 *chlamydoides*, *canadensis*, *cinnamomeus*, *clavisporus*, *cossus*, *cremeoroseus*, *cylindricosporus*, *divarica-*
2033 *tus*, *echinosporus*, *erectus*, *fimetarius*, *fulvus*, *fuscatus*, *gunnii*, *hawkesii*, *heliothis*, *hepiali*, *huaxiensis*, *in-*
2034 *dicus*, *isarioides*, *laeensis*, *longipes*, *loushanensis*, *mandshuricus*, *maximus*, *maximus*, *maximus*, *militaris*,
2035 *musicola*, *niphetodes*, *odonatae*, *parvisporus*, *pascuus*, *penicillatus*, *persimplex*, *puntonii*, *purpureus*, *ra-*
2036 *mosus*, *rariramus*, *saturatus*, *simplex*, *smilanensis*, *stipitatus*, *subglobosus*, *suffultus*, *tabacinus*, *taitungi-*
2037 *acus*, *tenuis*, *variotii*, *verrucosus*, *verticillatus*, *victoriae*, *vinaceus*, *wawuensis*, *xylariiformis*, *zollerniae*)
2038 AND (infection OR invasive OR fungal infection OR fungemia OR blood OR disseminated OR subcutaneous
2039 OR case [Title/Abstract] OR report [Title/Abstract] OR case series [Title/Abstract] OR patient OR isolate)
2040 that yielded 662 publications. In total, 93 cases were identified from 23 countries, 67 since the year
2041 2000^{572,1116,1903,1907,1914-1969}. Most cases were reported from the United States (n=16), Spain (n=13) and Tai-
2042 wan (n=14). The number of cases reported between 1971 and 2018 is presented as cases per million pop-
2043 ulation per country. The resident population per country was obtained from www.worldometers.info³²¹.
2044 *Five cases were reported from Hong Kong SAR (0.7 cases per million population between 1971 and
2045 2018)^{1925,1943,1944,1957}.

2046

2047 **Diagnosis of *Paecilomyces* infections**

2048 A species distinction is achieved in the course of diagnosis on the basis of various microbiological and
2049 molecular criteria.

2050 **Evidence** – The initial step in laboratory diagnosis is histopathological examination and microscopy, which
2051 reveal non-specific branched septate hyphae¹⁹⁶⁵. Culture is essential for species identification. Based on
2052 the culture morphology on different growth media, species determination can be achieved^{1597,1915,1965,1970-}

2053 ¹⁹⁷³. Histology is also required for identification of fungi, classification and evaluation of irregular hy-

2054 phae¹⁹¹³.

2055 Molecular-based methods can be used for species identification from DNA extracted from clinical isolates

2056 with subsequent Sanger sequencing, but not for the detection of fungal DNA directly from clinical mate-

2057 rial. Differentiation occurs via PCR-based DNA amplification of the rRNA gene regions ITS1 and ITS2 and

2058 of the 28S D1 and D2 regions. Additionally the amplification of the β -tubulin-encoding gene for species

2059 identification has been mentioned. Genbank analysis and sequence alignment are used for exact species

2060 assignment^{1597,1938,1965,1970,1971,1974-1976}. Occasionally MALDI-TOF MS technology is used for species identifi-

2061 cation¹⁹²⁶.

2062 For susceptibility testing, the EUCAST¹⁹⁷⁴ and CLSI M38-A2 microdilution methodologies¹⁹⁶⁵ have shown

2063 AmB and echinocandins to be active against clinical *P. variotii* isolates. Among the triazoles, ICZ and PCZ

2064 showed clinically relevant activity against *P. variotii*. PCZ and TRB showed good *in vitro* activity with ICZ

2065 the second most active and VCZ the less active triazole¹⁹⁷⁰.

2066 Imaging technologies (chest CT) are mainly used for detection of suspected pulmonary infections^{1915,1977}

2067 **(Table 43).**

2068 **Table 43. Microbiological, histopathological and imaging diagnostics of *Paecilomyces* infections**

Population	Intention	Intervention	SoR	QoE	Reference	Comment	
Microscopy, culture, MIC testing							
Any	To diagnose	Culture	A	III	Samson StudMycol 1974 ¹⁹⁷⁸	Differentiate between <i>P. lilacinum</i> and <i>P. variotii</i>	
					Houbraken JCM 2010 ¹⁹⁷⁰		
					Barker MedMycol 2014 ¹⁵⁹⁷		Sabouraud glucose brain heart infusion agar at 30°C
					Abolghasemi Tanaffos 2015 ¹⁹¹⁵		Sabouraud dextrose agar
					Eren TID 2018 ¹⁹¹³		Potato dextrose agar
Any	To diagnose	Microscopy	A	III	Eren TID 2018 ¹⁹¹³	Gram and Giemsa staining	
					Uzunoglu JMM 2017 ¹⁹⁶⁵	Lactophenol cotton blue	
Any	To guide treatment	EUCAST microdilution protocol	B	III	Castelli AAC 2008 ¹⁹⁷⁴		
					Feldman Mycoses 2016 ¹⁹⁰³		
Any	To guide treatment	Broth microdilution method according to CLSI guidelines (M38-A)	B	III	Aguilar AAC 1999 ¹⁷⁷⁴		
					Houbraken JCM 2010 ¹⁹⁷⁰		
Nucleic acid-based assays/MALDI-TOF MS							
Any	To identify species	PCR: ITS1, ITS2, and β -tubulin gene +/- 5.8S rDNA	A	IIu	Houbraken JCM 2010 ¹⁹⁷⁰		
					Uzunoglu JMM 2017 ¹⁹⁶⁵		
					Kantarcioglu Mycoses 2003 ¹⁹³⁸		
					Barker MedMycol 2014 ¹⁵⁹⁷		

					Castelli AAC 2008 ¹⁹⁷⁴	
Any	To identify species	MALDI-TOF MS	B	III	Chen FMicrobiol 2015 ¹⁹²⁶	
					Barker MedMycol 2014 ¹⁵⁹⁷	
Tissue-based diagnosis						
Any	To diagnose	Histopathological examination of biopsy tissue	A	III	Eren TID 2018 ¹⁹⁷⁹	
Imaging studies						
Any	To identify CNS infection	Cranial MRI	B	III	Kantarcioglu Mycoses 2003 ¹⁹³⁸	
Any	To identify pulmonary infection	Chest (HR) CT	A	III	Marques EFIM 2019 ¹⁹⁰⁴	
					Abolghasemi Tanaffos 2015 ¹⁹¹⁵	
CLSI, Clinical and Laboratory Standards Institute; CT, computed tomography; EUCAST, European Committee for Antimicrobial Susceptibility Testing; HR, high-resolution; ITS, internal transcribed spacer; MALDI-TOF MS, matrix assisted laser desorption ionization-time of flight mass spectrometry; PCR polymerase chain reaction; QoE, quality of evidence; rRNA, ribosomal ribonucleic acid; SoR, strength of recommendation;						

2069

2070 **Recommendations** - Direct microscopy and culture followed by PCR sequencing of the ITS and D1/D2

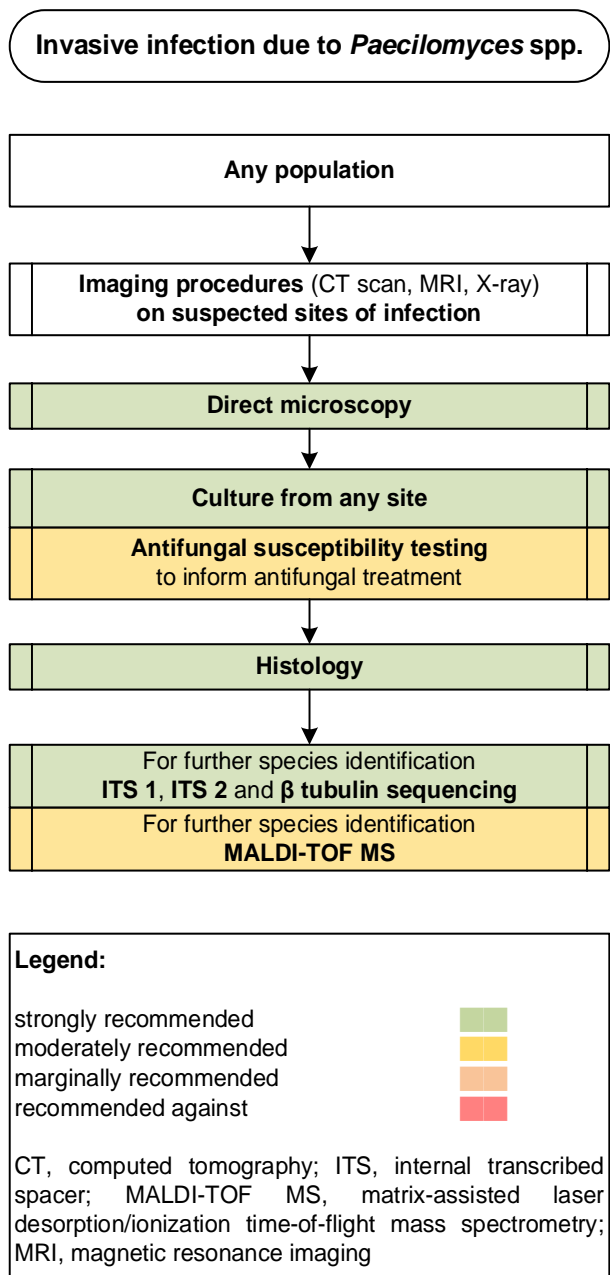
2071 regions for species identification are strongly recommended, as is histopathological examination of tissue.

2072 Antifungal susceptibility testing is moderately recommended to guide treatment. Imaging modalities such

2073 as chest CT are strongly recommended if applicable (**Figure 38**).

2074

2075 **Figure 38. Optimal diagnostic pathway for *Paecilomyces* infections, when all imaging and assay tech-**
 2076 **niques are available**



2077

2078

2079 **Treatment approaches to *Paecilomyces* infections**

2080 Treatment in adults

2081 **Evidence** – L-AmB generally demonstrates good *in vitro* activity¹⁹⁸⁰ and different AmB formulations have
 2082 been reported with varying but usually good responses^{1907,1914,1924,1929,1943,1944,1947,1953,1964}. Antifungal com-
 2083 bination therapies have only been described in individual cases (*e.g.*, L-AmB in combination with
 2084 ICZ^{1907,1965} or AmB in combination with ANID¹⁹⁰⁷), and were associated with favourable outcomes. ICZ and

2085 PCZ show good activity against *P. variotii*¹⁹⁸⁰ and have been successfully used for salvage ther-
 2086 apy^{1915,1966,1964}. The appropriate length of treatment for *P. variotii* infections is unclear. Successful case
 2087 reports cite treatment duration ranges from 4 to 12 weeks^{1907,1915,1964,1965,1979}. For dialysis-associated peri-
 2088 tonitis, shorter treatment duration of 10 days is reported in two cases in combination with peritoneal
 2089 catheter removal¹⁹⁴⁷.

2090 Various authors have reported good treatment responses after surgical interventions^{1921,1943,1944,1962,1967}
 2091 and removal of venous or intraperitoneal catheter systems^{1924,1947,1964,1965} (Table 44).

2092 **Table 44. Therapy for *Paecilomyces* infections**

Population	Intention	Intervention	SoR	QoE	Reference	Comment
First-line antifungal therapy						
Any	To cure	L-AmB	B	III	Salle JInfect 2005 ¹⁹¹¹	N=1, fungemia, response
					Chamilos JInfect 2005 ¹⁹²⁴	N=1, <i>P. variotii</i> , + CVC removal, re-sponse, MICs VCZ 8 µg/ml, AmB 0.25 µg/ml, PCZ 0.06 µg/ml
					Steiner CRID 2013 ¹⁹¹⁰	N=1, pneumonia, <i>P. variotii</i> , failure
					Bellanger Mycopathol 2017 ¹⁹⁰⁷	N=1, fungemia, + ANID, success
					Dharmasena BMJ 1985 ¹⁹²⁹	N=1, pneumonia, success
					Kantarcioğlu Mycoses 2003 ¹⁹³⁸	N=1, CNS infection, failure
					Cohen-Abbo Infection 1995 ¹⁹¹⁴	N=1, response
					Lam Eye 1999 ¹⁹⁴³	N=1, endophthalmitis + fungemia, + surgery, success
Any	To cure	VCZ	D	III	Eren TID 2018 ¹⁹⁷⁹	N=1, skin infection, + surgery, success
Any	To cure	PCZ tablet	C	III	Marques EJCRIM 2019 ¹⁹⁰⁴	N=1, pulmonary mycetoma, died
Any	To cure	ICZ po	C	III	Abolghasemi Tanaffos 2015 ¹⁹¹⁵	N=1, pneumonia, success
					Vasudevan IJD 2013 ¹⁹⁶⁶	N=1, subcutaneous hyalohypomycosis, success
Peritoneal dialysis patients	To cure peritonitis	L-AmB iv +/- ICZ po	B	III	Torres PDI 2014 ¹⁹⁰⁸	N=3, + catheter removal N=3, + laparotomy N=1, success 2/3
					Uzunoglu JMM 2017 ¹⁹⁶⁵	N=1, success
					Marzec JCM 1993 ¹⁹⁴⁷	N=4, + catheter removal N=4, success 4/4
Antifungal salvage treatment						
Any	To cure	PCZ	B	III	Feldmann Mycoses 2016 ¹⁹⁰³	N=1, pneumonia, response
					Bellanger Mycopathol 2017 ¹⁹⁰⁷	N=1, fungemia, success
Any	To cure	ICZ po	B	III	Lee JHJT 2002 ¹⁹⁴⁴	N=1, sternotomy wound infection, + surgery, success
Other treatment options						
Peritoneal dialysis patients	To cure	Catheter removal	A	III	Torres PDI 2014 ¹⁹⁰⁸	N=3, initial response 3/3, success 2/3
					Uzunoglu JMM 2017 ¹⁹⁶⁵	N=1, success
					Marzec JCM 1993 ¹⁹⁴⁷	N=4, success 4/4
Endophthalmitis	To cure	Vitrectomy and AmB 5 µg intravitreal	C	III	Tarkkanen AOS 2004 ¹⁹⁶²	N=1, initial response but several relapses
					Lam Eye 1999 ¹⁹⁴³	N=1, endophthalmitis + fungemia, success
Any	To cure	Surgical debridement	B	III	Eren TID 2018 ¹⁹⁷⁹	N=1, skin infection, + surgery, success
					Lee JHJT 2002 ¹⁹⁴⁴	N=1, sternotomy wound infection, success
Treatment duration						

Diabetic	To cure pneumonia	4 wk ICZ	C	III	Abolghasemi Tanaffos 2015 ¹⁹¹⁵	N=1, success
Solid organ transplant recipients	To cure skin infection	6 wk VCZ po	C	III	Eren TID 2018 ¹⁹⁴⁴	N=1, success
Any	To cure pulmonary mycetoma	6 wk PCZ	C	III	Marques EJCRIM 2019 ¹⁹⁰⁴	N=1, died
Peritoneal dialysis patients	To cure peritonitis	4-8 wk L-AmB iv + ICZ po	C	III	Torres PDI 2014 ¹⁹⁰⁸	N=3, initial response 3/3, success 2/3
					Uzunoglu JMM 2017 ¹⁹⁶⁵	N=1, success
					Marzec JCM 1993 ¹⁹⁴⁷	N=4, >10 d AmB deoxycholate, success 4/4
Hematological malignancy	To cure fungemia	6-12 wk L-AmB, step down to PCZ po possible	C	III	Bellanger Mycopathol 2017 ¹⁹⁰⁷	N=1, success
					Salle JInfect 2005 ¹⁹¹¹	N=1, response
Standard dose unless stated otherwise; ANID, anidulafungin; AmB, amphotericin B; CNS, central nervous system; CVC, central venous catheter; d, day(s); ICZ, itraconazole; iv, intravenous; L-AmB, liposomal amphotericin B; MIC, minimal inhibitory concentration; PCZ, posaconazole; po, orally; qd, once a day; QoE, quality of evidence; SoR, strength of recommendation; VCZ, voriconazole; wk, week(s).						

2093

2094 **Recommendation** – We moderately support the use of L-AmB (3-10 mg/kg qd) as a first-line antifungal

2095 monotherapy. We moderately recommend PCZ tablet (300 mg/d maintenance) or ICZ oral (400 mg/d) for

2096 salvage treatment. Treatment duration is a personalized decision and should be tailored to clinical signs.

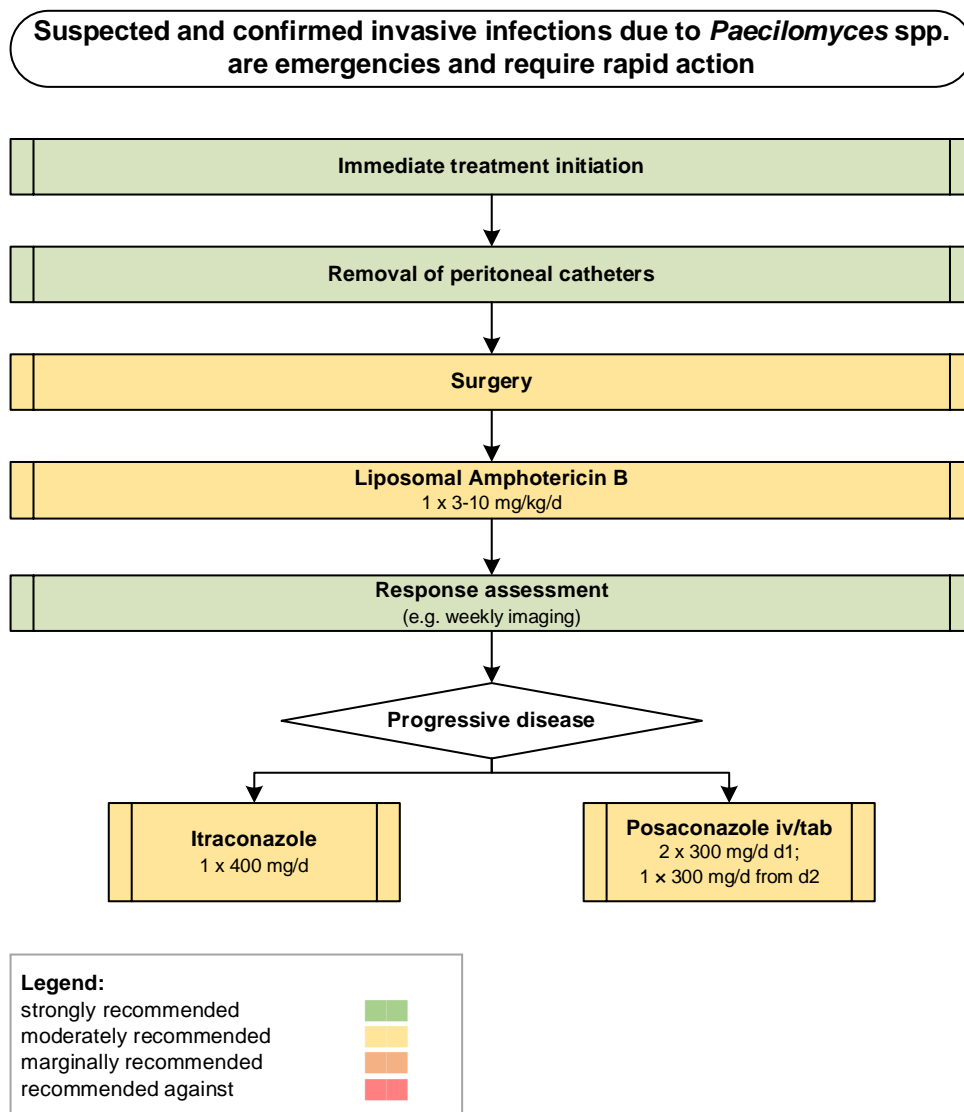
2097 In general, weeks to months of therapy are given and we marginally support 4 to 12 weeks of treatment.

2098 We moderately support a recommendation of surgical debridement of infected tissues and strongly sup-

2099 port removal of peritoneal catheters in peritoneal dialysis patients with peritonitis (**Figure 39**).

2100

2101 **Figure 39. Optimal treatment pathway for *Paecilomyces* infections in adults when all treatment mo-**
 2102 **dalities and antifungal drugs are available**



2103

2104 **Specific considerations on treatment of *Paecilomyces* infections in children**

2105 **Evidence** – Only a few cases of *P. variotii*-related infection in children are described. In individual cases,

2106 successful treatment was achieved with AmB or VCZ^{1924,1928,1951,1952,1967} (Table 45).

2107

2108 **Table 45. Therapy in children for *Paecilomyces* infections**

Population	Intention	Intervention	SoR	QoE	Reference	Comment
First-line antifungal therapy						
Solid organ transplant recipient	Infectious source control/pneumonia	L-AmB qd or 10 mg/kg tiw +/- ICZ po OR VCZ 7 mg/kg bid	B	III	Das PedTransplant 2000 ¹⁹²⁸	N=1, 9 yrs, Lung TX, pneumonia, several fungi in BAL, including <i>Aspergillus versicolor</i> , <i>Aspergillus fumigatus</i> , <i>Aspergillus niger</i> , <i>Penicillium</i> spp., <i>P. variotii</i> , questionable response, died from complications of bronchopneumonia
					Polat Mycopathol 2015 ¹⁹⁵¹	N=1, 16 yrs, Live TX, peritonitis, success
Antifungal salvage treatment						
Hematological malignancy	To cure fungemia	L-AmB	C	III	Chamilos JInfect 2005 ¹⁹²⁴	N=1, 14 yrs, CVC infection, + catheter removal, success
Treatment duration						
Any	To cure peritonitis	4-6 wk of therapy	C	III	Rinaldi PedNephrol 2000 ¹⁹⁵²	N=1, success
					Polat Mycopathol 2015 ¹⁹⁵¹	N=1, success
Any	To cure	6-8 wk of therapy with L-AmB, followed by ICZ	C	III	Chamilos JInfect 2005 ¹⁹²⁴	N=1, fungemia, success
					Das PedTransplant 2000 ¹⁹²⁸	N=1, pneumonia, questionable response
Any	To cure splenic abscess	14 mo of therapy with FCZ + 5-FC	C	III	Wang DMID 2005 ¹⁹⁶⁷	N=1, success
Standard pediatric dose unless otherwise stated; 5-FC, 5-fluorocytosine; A <i>Aspergillus</i> ; BAL, bronchoalveolar lavage; bid, twice a day; CVC, central venous catheter; FCZ, fluconazole; ICZ, itraconazole; L-AmB, liposomal amphotericin B; mo, month(s); po, orally; qd, once a day; QoE, quality of evidence; SoR, strength of recommendation; tiw, three times a week; VCZ, voriconazole; wk, week(s); yrs, years.						

2109

2110 **Recommendation** – Although there is limited evidence to support a specific regimen, we moderately
 2111 support the use of L-AmB (3 mg/kg qd or 10 mg/kg tiw), or VCZ as first-line treatment for *Paecilomy-*
 2112 *ces*-related infections in children.

2113

2114 **11. *Purpureocillium***

2115 **Epidemiology of *Purpureocillium* infections**

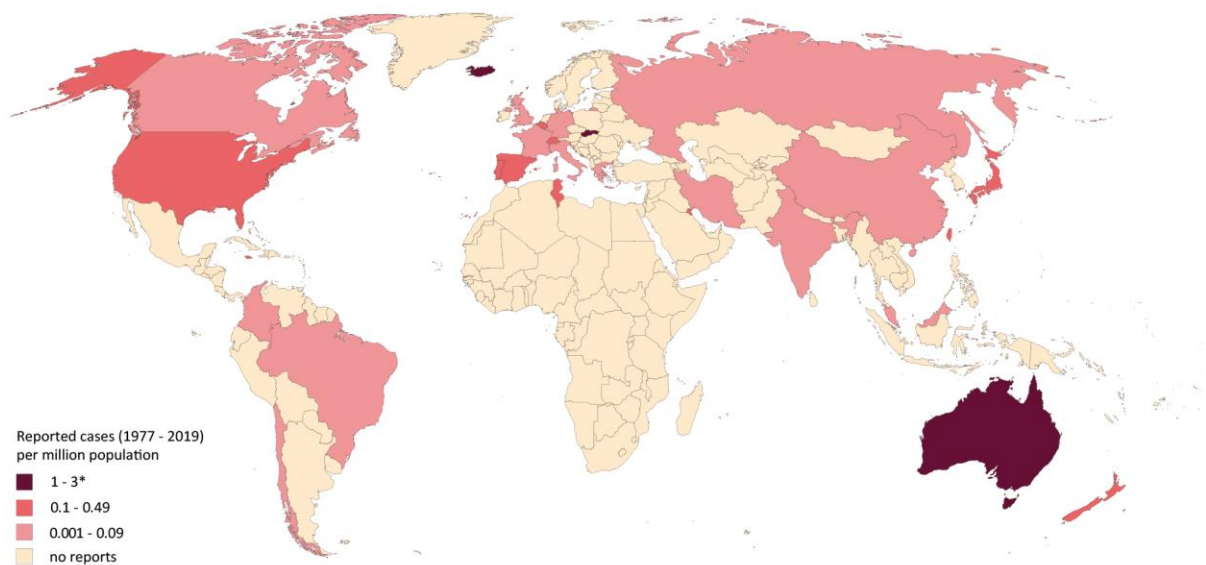
2116 *P. lilacinum* (formerly *Paecilomyces lilacinus*) is a saprobic, non-dermatophyte mold with a worldwide dis-
 2117 tribution and can be commonly found in soil. Due to its nematophagous potential it is widely used as a
 2118 bio-control agent in agriculture and has been isolated from water streams in the Middle East, possibly as
 2119 a run-off from agricultural use^{1981,1982}.

2120 *P. lilacinum* has a tropism for ocular structures, thus, the most frequent clinical manifestations in humans
 2121 are keratitis and endophthalmitis, followed by cutaneous and subcutaneous infections¹⁹⁸³. The most com-
 2122 mon route of infection is via external invasion but endogenous infections also have been reported, mainly
 2123 in immunocompromised patients. In a US study in 2 referral centers, ~4% of cases of fungal keratitis were

2124 caused by *P. lilacinum*¹⁹⁸⁴. Frequently, eye infections are associated with intra-ocular lens implantation,
2125 trauma and the use of soft contact lenses^{1918,1983-1985}. Up to one third of reported *Purpureocillium*-associ-
2126 ated keratitis cases required enucleation¹⁹⁸³. Poor outcome is possibly related to the limited efficacy of
2127 topical natamycin, which is the treatment of choice for *Fusarium*-associated fungal keratitis, the main
2128 causative pathogen¹⁹⁸³. The use of topical VCZ has demonstrated good effects in advanced cases of *Pur-*
2129 *pureocillium* keratitis^{1935,1986}. Cutaneous and sub-cutaneous infections mainly occur in transplant or other
2130 immunosuppressed patients, especially those with underlying malignancy¹⁹⁸³. Cases of non-ocular, non-
2131 cutaneous infections caused by *P. lilacinum* have been described but these are in general rare¹⁹⁸⁷⁻¹⁹⁹². *P.*
2132 *lilacinum* presents moderate virulence¹⁹⁹³. Infections are rarely disseminated, mainly in severely immun-
2133 ocompromised patients^{1991,1994,1995}. In Spain, an incidence of 1% has been reported in patients following
2134 lung transplantation⁶⁰⁶ (Figure 40).

2135

2136 **Figure 40. Worldwide distribution of infections caused by *Purpureocillium* spp. (reported cases be-**
2137 **tween 1977 and 2019 per million population)**



2138

2139 Cases of severe *Purpureocillium*-related infections reported in the medical literature were identified in a
2140 PubMed search on October 30, 2019 using the search string "*Purpureocillium atypicola* OR *Purpureocil-*
2141 *lium lavendulum* OR *Purpureocillium lilacinum* OR *Paecilomyces lilacinus* OR *Purpureocillium sodanum* OR
2142 *Purpureocillium takamizusanense*" that yielded 395 publications. Cases were identified in four additional

2143 publications in the *Paecilomyces* search. Overall, 250 cases from 28 countries have been selected, 171
 2144 cases reported since the year 2000^{572,606,655,881,1116,1344,1346,1918,1926,1930,1945,1973,1975,1976,1984,1986-1992,1994-2097}.
 2145 Most cases were reported from the USA (n=113), Australia (n=26), Spain (n=17), India and Japan (each
 2146 n=13). Nine patients with *Purpureocillium*-related infections that were reported during an outbreak due
 2147 to contaminated skin lotion in Switzerland were excluded²⁰⁶². Number of cases reported between 1977
 2148 and 2019 is presented as cases per million population per country. The resident population per country
 2149 was obtained from www.worldometers.info³²¹. *One case of infection caused by *P. lilacinum* was reported
 2150 from Iceland (3 cases per million population between 1977 and 2019)²⁰²⁵.

2151

2152 **Diagnosis of *Purpureocillium* infections**

2153 **Evidence** – Distinction between species is achieved in the course of diagnosis on the basis of various mi-
 2154 crobiological and molecular criteria. Direct microscopy of infected tissues is used for the characterization
 2155 and identification of numerous hyaline and septate hyphae of molds²⁰⁷³. Rarely conidiophores and phi-
 2156 alides can be observed^{1972,1975}. Culture is crucial for species identification. Based on culture morphology
 2157 on different growth media the species determination can be performed^{2009,2073,2085}. Histology is also re-
 2158 quired for identification of fungi and visualization of numerous separate hyphae and arthroconidia within
 2159 granulomas^{2009,2085}. For susceptibility testing the use of E-test strips has been described for *Purpureocil-*
 2160 *lium* spp.²⁰⁷³. MICs were high for AmB, ICZ, PCZ, CASPO and MICA, while VCZ had a relatively low MIC.

2161 Molecular methods are used for species identification, but not for detection of fungal DNA from clinical
 2162 material. Differentiation occurs via PCR-based DNA amplification of rRNA gene regions, mainly 28S D1 and
 2163 D2 regions, but also ITS1 and ITS2^{2009,2085}. PCR is performed from cultured clinical isolates. Genbank anal-
 2164 ysis and sequence alignment are used for the exact species assignment^{2009,2019,2073,2085} **(Table 46)**.

2165

2166 **Table 46. Microbiological and histopathological diagnostics of *Purpureocillium* infections**

Population	Intention	Intervention	SoR	QoE	Reference	Comment
Microscopy, culture, MIC testing						
Any	To diagnose	Culture	A	III	Demitsu J Dermatol 2017 ²⁰⁰⁹	Biopsy on SDA
					Saghrouni Med Mycol 2013 ²⁰⁷³	Biopsy on SDA

					Trinh TID 2017 ²⁰⁸⁵	Biopsy on brain heart infusion agar
					Narita AMO 2015 ¹⁹⁷³	
					Antas MicrobesInfect 2012 ¹⁹⁷²	Malt extract agar
					Nagamoto MMJ 2014 ¹⁹⁷⁵	SDA
Any	To diagnose	Microscopy	A	III	Saghrouni MedMycol 2013 ²⁰⁷³	KOH direct examination
					Antas MicrobesInfect 2012 ¹⁹⁷²	
					Todokoro IntOphthalmol 2014 ¹⁹⁷⁶	Gram and Fungiflora Y stainings
					Nagamoto MedMycol 2014 ¹⁹⁷⁵	Koh-Parker ink-direct microscopy
Any	To test susceptibility	E-test strips (bioMérieux, France)	B	III	Saghrouni MedMycol 2013 ²⁰⁷³	
Nucleic-acid based assays/MALDI-TOF MS						
Any	To diagnose in biopsy	In-house 18S rRNA PCR	C	III	Trinh TID 2017 ²⁰⁸⁵	
Any	To identify species	PCR rRNA D1/D2 or ITS region	A	III	Demitsu J Dermatol 2016 ²⁰⁰⁹	
					Saghrouni MedMycol 2013 ²⁰⁷³	
					Todokoro IntOphthalmol 2014 ¹⁹⁷⁶	
					Nagamoto MedMycol 2014 ¹⁹⁷⁵	
					Innocenti Mycoses 2011 ¹⁹⁷¹	
					Guo JMII 2019 ²⁰¹⁹	
Immunocompetent	To identify cause of facial skin lesion	MALDI-TOF MS using a microflex LT instrument (Bruker Daltonics Germany)	B	III	Saghrouni MedMycol 2013 ²⁰⁷³	
Tissue-based diagnosis						
Any	To diagnose	Histopathology of biopsy tissue	A	III	Trinh TID 2017 ²⁰⁸⁵	
					Demitsu J Dermatol 2017 ²⁰⁰⁹	
					Saghrouni MedMycol 2013 ²⁰⁷³	
					Antas MicrobesInfect 2012 ¹⁹⁷²	
AmB, amphotericin B; ITS, internal transcribed spacer; KOH, potassium hydroxide; MALDI-TOF MS, matrix assisted laser desorption ionization-time of flight mass spectrometry; PCR, polymerase chain reaction; QoE, quality of evidence; rRNA, ribosomal ribonucleic acid; SDA, Sabouraud Dextrose Agar; SoR, strength of recommendation						

2167

2168 **Recommendations** - Direct microscopy, and culture followed by sequencing of the 28S D1 and D2 re-

2169 gions and of ITS1 and ITS2 for species identification are strongly recommended, as is histopathological

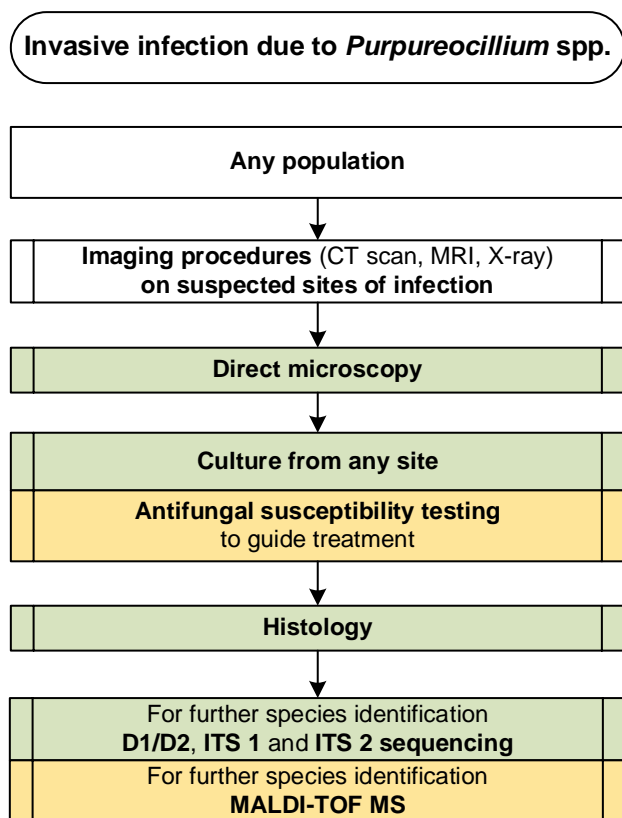
2170 examination of tissue. Identification of isolates with MALDI-TOF MS are moderately recommended. An-

2171 tifungal susceptibility testing is moderately recommended to guide antifungal treatment.

2172 If all diagnostic options are available, one should follow the management pathway (**Figure 41**).

2173

2174 **Figure 41. Optimal diagnostic pathway for *Purpureocillium* infections, when all imaging and assay**
 2175 **techniques are available**



Legend:

strongly recommended	
moderately recommended	
marginally recommended	
recommended against	

CT, computed tomography; ITS, internal transcribed spacer; MALDI-TOF MS, matrix-assisted laser desorption/ionization time-of-flight mass spectrometry; MRI, magnetic resonance imaging

2176

2177

2178

2179 **Treatment approaches to *Purpureocillium* infections**

2180 Treatment in adults

2181 **Evidence** - VCZ demonstrates generally good *in vitro* activity against *P. lilacinum*^{1970,1974} and several suc-
 2182 cessful therapy approaches with VCZ have been reported^{1988,2007,2069,2085,2086}. Furthermore, some reports
 2183 of successful treatment with VCZ in combination with TRB have been published^{1344,2009,2086,2092}. For sal-
 2184 vage therapy, the results for AmB have been mixed (not effective^{1999,2008,2024}, effective^{1975,1989,2083}). AmB

2185 generally shows poor activity against *P. lilacinum in vitro*^{1970,1974}. PCZ and ICZ have been reported to be
 2186 effective in individual cases^{1346,1973,1999,2012} but usually do not show *in vitro* activity against *Purpureocil-*
 2187 *lium lilacinum*¹⁹⁷⁴.

2188 Appropriate length of treatment for *P. lilacinum* infections is unclear. Successful cases cover ranges from
 2189 a few weeks to 7 months^{1344,1918,1973,1975,1988,2007,2009,2012,2046,2069,2085,2086}.

2190 Surgical debridement of infected tissue appears to be a major means of resolution of the infection if the
 2191 lesions are localized^{1346,1987,2001,2007,2019,2022,2069,2074,2086} (Table 47).

2192 **Table 47. Therapy for *Purpureocillium* infections**

Population	Intention	Intervention	SoR	QoE	Reference	Comment
First-line antifungal therapy						
Hematological malignancy	To cure	PCZ	C	III	Hobson ChestInfect 2013 ²⁰⁹⁸	N=1, pneumonia, success
Any	To cure	VCZ +/- surgical intervention	B	III	Ciecko ENTJ 2010 ²⁰⁰⁷	N=1, invasive fungal rhinitis, + surgery, success
					Huang Mycopathol 2011 ²⁰⁹⁹	N=1, cutaneous hyalohyphomycosis, response
					Keshkar-Jahromi Mycopathol 2012 ¹⁹⁸⁸	N=1, cutaneous + synovial infection, success
					Rimawi Mycopathol 2013 ¹⁴⁷⁵	N=1, subcutaneous infection, + surgery, success
					Trinh TID 2017 ²⁰⁸⁵	N=1, kidney infection, success
					Pastor CMI 2006 ¹⁹⁸³	N=119, <i>P. lilacinum</i> , oculomycosis and (sub)cutaneous infection, VCZ mono +/- TRB, success
					Martin CID 2002 ¹⁹⁹⁴	N=1, disseminated infection, response
	Schweitzer AJO 2012 ²⁰⁷⁴	N=1, bursitis, + surgical debridement, success				
Any with cutaneous / subcutaneous infection	To cure	VCZ +/- TRB 250 mg qd +/- surgical intervention	B	III	Hilmarsdottier SJID 2000 ²¹⁰⁰	N=1, cutaneous infection, success
					Lavergne TID 2012 ¹³⁴⁴	N=1, cutaneous hyphomycosis, <i>P. lilacinum</i> and <i>A. alternata</i> , success
					Demitsu J Dermatol 2016 ²⁰⁰⁹	N=1, subcutaneous hyalohyphomycosis, success
					Ounissi TransProceed 2009 ²¹⁰¹	N=1, cutaneous hyalohyphomycosis, response
					Van Schoonevelt TID 2008 ²⁰⁸⁷	N=1, cutaneous infection, success
Any	To cure	ICZ 400 mg +/- surgical intervention	C	III	Hall IJD 2004 ²⁰²²	N=1, cutaneous hyalohyphomycosis, success
					Hecker JAAD 1997 ²⁰²⁴	N=2, response 2/2
					Clark CID 1999 ²⁰⁰⁸	N=1, soft tissue infection, ICZ no response, switch to TRB, success
Any	To cure	L-AmB 5 mg/kg qd	C	IIIit	Walsh TID 1999 ²¹⁰²	
					Clark CID 1999 ²⁰⁰⁸	N=1, soft tissue infection, L-AmB no response, switch to TRB, success
Any with keratitis	To cure	VCZ topical and VCZ iv/po +/- VCZ 1 mg/0.1 ml intravitreal +/- surgical interventions	B	IIu	Chew CJO 2016 ²¹⁰³	N=3, 1/3 no visual improvement, 2/3 enucleation
					Ali SeminOphthalmol 2015 ¹⁹¹⁸	N=28, 7/28 therapeutic keratoplasties, 1/28 enucleation

					Turner BMCRN 2015 ²⁰⁸⁶	N=21, VCZ 17/21 (81%) for a minimum of 3 mo, topical 11/21 (52%), intracameral 6/21 (29%), intravitreal 3/21 (14%), surgical intervention 18/21 (86%), penetrating keratoplasty 8/21 (38%), 5/21 second penetrating keratoplasty (24%), pars plana vitrectomy 9/21 (43%), second pars plana vitrectomy 4/21 (19%), enucleation 4/21 (19%), multiple protracted and poor outcomes
					McLintock CEO 2013 ²⁰⁴⁶	N=1, scleritis, keratitis, + several surgeries, success but poor outcome
					Oliveira BMJCR 2019 ²¹⁰⁴	N=1, + surgery, success
					Todokoro IntOphthalmol 2014 ¹⁹⁷⁶	N=2, success 2/2
					Wu Cornea 2010 ²¹⁰⁵	N=1, success but poor outcome
					Juyal IJPM 2018 ²¹⁰⁶	N=1, trauma, treatment response, + keratoplasty, success
Any with endophthalmitis	To cure	VCZ topical + VCZ iv/po +/- VCZ intravitreal 1 mg/0.1 ml +/- surgical interventions	C	III	Trachsler KMA 2012 ²¹⁰⁷	N=1, treatment response
					Yoshida IntOphthalmol 2018 ²¹⁰⁸	N=1, endophthalmitis, + surgery, response but poor outcome
					Garbino SJID 2002 ²¹⁰⁹	N=1, + surgery, response
Antifungal salvage treatment						
Any with keratitis	To cure	PCZ	C	III	Arnoldner Cornea 2014 ¹⁹⁹⁹	N=1, keratitis, + surgery, success
Any with endophthalmitis	To cure	ICZ 100 mg + miconazole topical + natamycin topical	C	III	Narita AMO 2015 ¹⁹⁷³	N=1, endophthalmitis, + surgery, success
Any with cutaneous / subcutaneous infection	To cure	TRB po 250 mg qd or bid +/- surgical intervention	C	III	Clark CID 1999 ²⁰⁰⁸	N=1, success
					Blackwell BJD 2000 ²⁰⁰¹	N=1, + surgery, outcome not reported
Any with cutaneous / subcutaneous infection	To cure	PCZ	C	III	Ezzedine ADV 2012 ²⁰¹²	N=1, good response, lost to follow-up
					Saegeman ACB 2012 ¹³⁴⁶	N=1, <i>P. lilacinum</i> and <i>Alternaria infectoria</i> , response
Any with cutaneous infection	To cure	L-AmB 150 mg qd	C	III	Nagamoto MedMycol 2014 ¹⁹⁷⁵	N=1, success
Immunocompetent patients with onychomycosis	To cure	Amorolfine 5% nail lacquer + TRB systemic 250 mg qd + ICZ 200 mg qd	D	III	Innocenti Mycoses 2011 ¹⁹⁷¹	N=1, failure
					Pontini GIDV 2016 ²¹¹⁰	N=1, failure
Peritoneal dialysis patients with Peritonitis	To cure	TRB po 250 mg + VCZ	C	III	Wolley PDI 2012 ²⁰⁹²	N=1, + catheter removal, success
Other treatment options						
Any with cutaneous or subcutaneous infection	To cure	Surgical debridement	A	III	Blackwell BJD 2000 ²⁰⁰¹	N=1, outcome not reported
					Saegeman ACB 2012 ¹³⁴⁶	N=1, <i>P. lilacinum</i> and <i>Alternaria infectoria</i> , response
					Ciecko ENTJ 2010 ²⁰⁰⁷	N=1, invasive fungal rhinitis, success
					Rimawi Mycopathol 2013 ¹⁴⁷⁵	N=1, success
					Hall IJD 2004 ²⁰²²	N=2, + surgery, 1/2 lost to follow up, 1/2 died of other causes
Endophthalmitis	To cure	Vitrectomy	B	III	Guo JMII 2019 ²⁰¹⁹	N=1, no antifungal drugs, success
Immunocompetent patients with lung abscess	To cure	Surgical lobectomy	C	III	Ono Respiration 1999 ¹⁹⁸⁷	N=1, no further antifungal treatment, success
Immunocompetent patients with septic bursitis	To cure	Surgical debridement	B	III	Schweitzer AJO 2012 ²⁰⁷⁴	N=1, success
Peritoneal dialysis patients with peritonitis	To cure	Catheter removal	B	III	Wolley PDI 2012 ²⁰⁹²	N=1, success
Treatment duration						
Any	To cure keratitis	Average therapy length 24.7 wk	B	Ilu	Ali SeminOphthalmol 2015 ¹⁹¹⁸	N=28, longer duration for cases in later disease course, outcome variable
					McLintock CEO 2013 ²⁰⁴⁶	N=1, immunocompromised patient, 6 mo of therapy with topical, oral and

						intravitreal VCZ, topical VCZ continued for 10 mo, success but poor outcome
Any	To cure ocular mycoses	Minimum of 3 mo VCZ po +/- VCZ topical, intracameral or intravitreal	B	IIu	Turner BMCRN 2015 ²⁰⁸⁶	N=21, multiple protracted and poor outcomes
Any	To cure endophthalmitis	7 mo of therapy with topical miconazole + pimacine ointment + 3 mo of therapy with ICZ	C	III	Narita AMO 2015 ¹⁹⁷³	N=1, success
Solid organ transplant recipients	To cure invasive fungal rhinitis	5 wk of therapy with VCZ	C	III	Ciecko ENTJ 2010 ²⁰⁰⁷	N=1, success
Immunocompetent patients	To cure septic bursitis	6 wk of overall therapy with VCZ po	C	III	Schweitzer AJO 2012 ²⁰⁷⁴	N=1, success
Peritoneal dialysis patients	To cure peritonitis	13 mo of overall therapy with VCZ, 12 mo with TRB	C	III	Wolley PDI 2012 ²⁰⁹²	N=1, success
Any	To cure cutaneous / subcutaneous infections	3-7 mo of antifungal therapy	B	III	Lavergne TID 2012 ¹³⁴⁴	N=1, cutaneous infection, 7 mo TRB, success
					Nagamoto MedMycol 2014 ¹⁹⁷⁵	N=1, skin infection, 2.5 mo L-AmB, success
					Rimawi Mycopathol 2013 ¹⁴⁷⁵	N=1, subcutaneous infection, 12 wk VCZ, success
					Trinh TID 2017 ²⁰⁸⁵	N=1, cutaneous infection, 12 wk VCZ, success
					Keshkar-Jahromi Mycopathol 2012 ¹⁹⁸⁸	N=1, cutaneous and synovial infection, 12 wk VCZ, success
					Demitsu J Dermatol 2016 ²⁰⁰⁹	N=1, subcutaneous hyalohyphomycosis, 3 mo VCZ + TRB, success
					Ezzedine ADV 2012 ²⁰¹²	N=1, cutaneous infection, 4 wk PCZ, good response
					Huang Mycopathol 2011 ²⁰⁹⁹	N=1, cutaneous infection, 3 wk VCZ oral + nystatin topical, good response
Standard dose unless stated otherwise; bid, twice a day; d, day(s); ICZ, itraconazole; iv, intravenous; L-AmB, liposomal amphotericin B; mo, month(s); PCZ, posaconazole; po, orally; qd, once a day; QoE, quality of evidence; SoR, strength of recommendation; TRB, terbinafine; VCZ, voriconazole; wk, week(s).						

2193

2194 **Recommendations** – The guideline group moderately supports first-line monotherapy with VCZ in all

2195 patients. ICZ (SUBA formulation preferred), PCZ and L-AmB are marginally recommended alternatives.

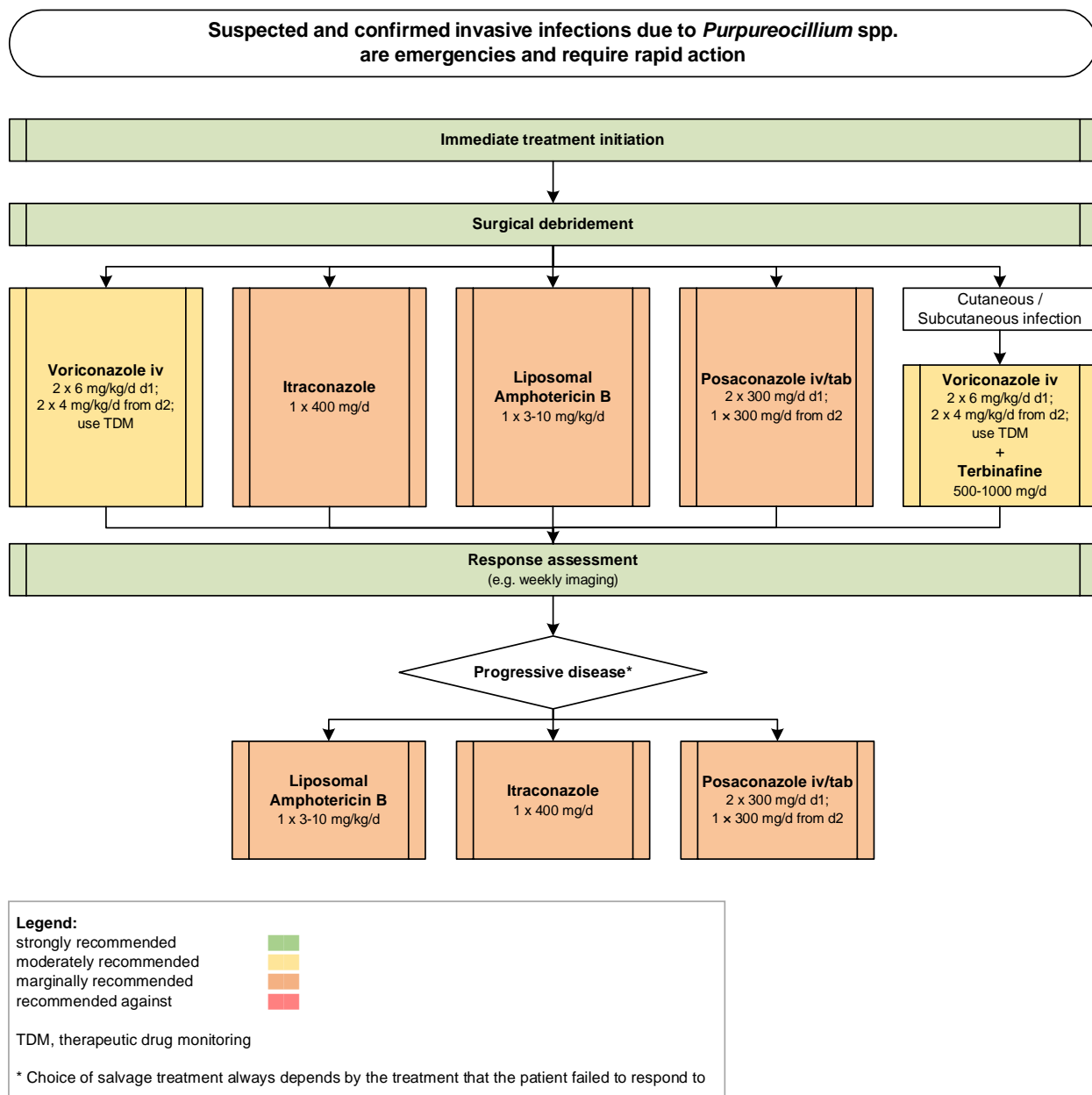
2196 For cutaneous and subcutaneous infections, combination therapy with VCZ plus TRB is moderately supported.

2197 For salvage therapy we marginally recommend L-AmB, PCZ or ICZ monotherapy. We moderately

2198 recommend a treatment duration of at least 3 months for ocular and cutaneous/subcutaneous infections.

2199 The guideline group strongly supports a recommendation for surgical debridement (**Figure 42**).

2200 **Figure 42. Optimal treatment pathway for *Purpureocillium* infections in adults when all treatment mo-**
 2201 **dalities and antifungal drugs are available**



2202

2203

2204

2205 **Specific considerations on treatment of *Purpureocillium* infections in children**

2206 **Evidence** - Only a few cases are reported with good treatment response to AmB formulations^{1989,2083,2111}.

2207 In an individual case, successful treatment is described with VCZ²⁰⁷³ (**Table 48**).

2208 **Table 48. Therapy in children for *Purpureocillium* infections**

Population	Intention	Intervention	SoR	QoE	Reference	Comment
First-line antifungal therapy						
Immunocompromised patients	To cure	AmB lipid formulations	C	III	Sillevis Smitt ADC 1997 ²¹¹¹	N=1, 12 yrs, lung infection, response
					Tan JCM 1992 ²⁰⁸³	N=1, 18 mo, fungemia, D-AmB, success
					Silliman JInfect 1992 ¹⁹⁸⁹	N=1, 4 yrs, two abdominal wall abscesses, D-AmB, response
Immunocompetent patients with cutaneous infection	To cure	VCZ 400 mg	B	III	Saghrouni MedMycol 2013 ²⁰⁷³	N=1, success
Treatment duration						
Immunocompetent patients	To cure cutaneous hyalohyphomycosis	3 mo VCZ	C	III	Saghrouni MedMycol 2013 ²⁰⁷³	N=1, success
Immunocompromised patients	To cure lung infection	4 wk AmB	C	III	Sillevis Smitt ADC 1997 ²¹¹¹	N=1, 12 yrs, response
Standard pediatric dose unless otherwise stated; L-AmB, liposomal amphotericin B; mo, month(s); QoE, quality of evidence; SoR, strength of recommendation; VCZ, voriconazole; wk, week(s); yrs, years.						

2209

2210 **Recommendations** – In line with recommendations in adults, the guideline group moderately supports

2211 the use of VCZ and marginally supports the use of L-AmB for treatment in children.

2212

2213 **Future directions**

2214 **Unmet needs**

2215 Despite recent advances in diagnostic testing and antifungal therapies, significant challenges remain in

2216 the management of rare mold infections. Diagnosis is based on conventional identification methods and

2217 culture, with molecular-based identification and testing often requiring referral to specialist laboratories

2218 with an expertise in phenotypic identification, including ECMM Excellence Centers¹⁷. Even when available,

2219 molecular identification using standardized sequencing techniques is mostly restricted to identification of

2220 isolates, while more rapid tests that can be applied directly to clinical samples are needed²¹¹². A promising

2221 method for faster identification of fungal isolates is MALDI-TOF MS, though current CE certified databases

2222 need to be substantially enhanced to become clinically useful and additional research is needed to reliably

2223 identify molds. MALDI-TOF MS requires a large number of strains to generate reliable reference data for

2224 identification. In order to improve molecular identification methods and MALDI-TOF MS libraries or de-

2225 velop new diagnostic tools, comprehensive well-curated and publicly accesible collections of clinical iso-

2226 lates need to be maintained at central repositories for research purposes. Since randomized trials are

2227 impractical due to the rare occurrence of these infections, prospective and detailed clinical registries such
2228 as the FungiScope registry^{10,367}, are important to refine treatment strategies, which may be specifically
2229 tailored for a particular pathogen and clinical syndrome. Furthermore, development of unique animal
2230 models for some of these fungi is important for validation of some of the current therapeutic recommen-
2231 dations and for development of novel therapies, including immunomodulatory treatment. Finally, estab-
2232 lishment of an online, searchable database of infections caused by rare molds, their clinical presentations
2233 and antifungal susceptibilities would assist in the management of difficult cases. In the digital era, we are
2234 now able to connect data sources globally to help optimize therapy of these often refractory infections.

2235

2236

2237 ***Priority research questions***

2238 The immediate research questions are similar for the individual rare molds. Common research themes for
2239 the rare molds are the need to develop better diagnostic tools and antifungal agents, as well as to identify
2240 unique biomarkers, understand pathogenesis and elucidate host defense mechanisms.

2241 **1.** Improved diagnostics: Culture-based diagnostics are slow or may be falsely negative due to vari-
2242 ous factors including ongoing antifungal treatment or prophylaxis^{2120,2121}. Biopsies are not always
2243 possible due to associated risks for the patients. Although non-culture-based diagnostics including
2244 point-of-care tests^{2122,2123} and molecular diagnostics²¹²⁴ have been developed for aspergillosis and
2245 to some extent also mucormycosis, the rare molds remain difficult to diagnose in a timely manner
2246 due to lack of rapid diagnostic tests. Research should focus on rapid diagnostic tests that may
2247 involve PCR testing. Although pan-fungal PCR targeting the ITS1 region of the ribosomal RNA gene
2248 can identify rare molds, this test is most accurate on fresh tissue in which hyphae are visible and
2249 less useful for samples containing low amounts of mold³⁴¹. Furthermore, multiplex PCR testing
2250 using the ITS1 and ITS2 regions as well as beta-tubulin on blood cultures, which have flagged pos-
2251 itive has identified molds such as *Fusarium* spp. and *L. prolificans*³³⁸. However, more sensitive

2252 targeted tests which could predict or identify development of invasive infection earlier than tra-
2253 ditional methods and could impact on management of these infections, which are often only di-
2254 agnosed with advanced infection, are needed.

2255
2256 Other advances include metabolite mass spectrometry²¹²⁵ of breath samples to identify volatile
2257 organic compound signatures specific for fungi, which has been successfully applied for diagnosis
2258 of invasive pulmonary aspergillosis²¹²⁶ and could be extended to invasive pulmonary infections
2259 with other molds. Metagenomic sequencing of blood or body fluids is now possible²¹²⁷ but while
2260 there is some experience in using this to detect bacteria and viruses, fungi have not been evalu-
2261 ated. The same applies for high resolution melting techniques²¹²⁸. Inexpensive and portable se-
2262 quencing machines will make these technologies widely available and may be a solution in coun-
2263 tries without laboratory infrastructure²¹²⁹. Innovative technologies, such as clustered regularly in-
2264 terspaced short palindromic repeats (CRISPR)-based diagnostic tools, may lead to point-of-care
2265 assays²¹²⁹. PET CT or MRI scans with *Aspergillus* antibodies or siderophores labelled to nuclear
2266 medicine isotopes have been used to diagnose aspergillosis^{2130,2131}, but rely on sensitive and spe-
2267 cific fungal biomarkers that will need to be developed for these rare conditions²¹³². Finally, future
2268 studies are needed to search for laboratory markers for treatment response assessment, includ-
2269 ing immunologic markers^{2121,2133}.

2270
2271 **2.** Improved treatments: With a limited number of antifungals currently available, there is an urgent
2272 need for studies designed to establish a correlation between *in vitro* susceptibility results and *in*
2273 *vivo* response, to better target treatment. Due to a number of new antifungal agents in the de-
2274 velopment pipeline, options for treating these difficult infections may improve in the near fu-
2275 ture²¹³⁴. Olorofim is currently being evaluated in human studies and has activity against *L. prolifi-*
2276 *cans*, *Scedosporium* spp.^{560,2135}, and some *Fusarium* spp.²¹³⁶. Evaluation of activity against the
2277 other rare molds is urgently required. Drugs in an earlier phase of development that have shown

2278 activity against rare molds include auranofin with *in vitro* activity against *Lomentospora* spp. and
2279 *Scedosporium* spp., although the mechanism of action is yet unclear²¹³⁷. The glycosylphosphati-
2280 dylinositol (GPI) synthesis inhibitor fosmanogepix, which weakens the cell wall and impairs fungal
2281 growth has *in vitro* activity against *Fusarium* spp., black molds, *Lomentospora* spp., *Scedosporium*
2282 spp., and *P. lilacinum*²¹³⁸. This drug also was successful in a neutropenic mouse model of dissem-
2283 inated fusariosis²¹³⁹. To bring these promising new agents to clinical practice requires a concerted
2284 collaborative effort and partnerships between industry, regulators, and clinicians, which will be
2285 critical. Mechanisms of antifungal resistance in these rare molds should be further studied in or-
2286 der to develop new antifungal agents to overcome intrinsic resistance, an example being *L. pro-*
2287 *lificans* and triazoles²¹⁴⁰.

2288 Beyond drug therapy, adoptive T-cell therapy²¹⁴¹, chimeric antigen receptor (CAR) T cells (artifi-
2289 cially designed receptors that are introduced into T cells)²¹⁴² and neutrophils engineered with
2290 bifunctional small molecules that bind the antifungal targets and have immunostimulatory com-
2291 pounds to enhance the immune response²¹⁴³ are possibly feasible approaches, which should be
2292 assessed.

2293

2294 **3.** The mycobiome: The third research question is understanding the mycobiome of sites such as the
2295 respiratory tract, the gastrointestinal tract, and skin in healthy subjects and during immunosup-
2296 pression and if this is a factor in allowing rare molds to become invasive²¹⁴⁴⁻²¹⁴⁷.

2297

2298

2299 **Acknowledgment**

2300 We thank Christina Toebben and Dr. Nathalie Bauer for review and valuable contributions to the manu-
2301 script. The authors are indebted to Susann Blossfeld and Dr. Caroline Bruns for technical support with this
2302 manuscript.

2303

2304

2305 **References**

- 2306 1. Montagna MT, Caggiano G, Lovero G, et al. Epidemiology of invasive fungal infections in the
2307 intensive care unit: results of a multicenter Italian survey (AURORA Project). *Infection* 2013; **41**(3): 645-
2308 53.
- 2309 2. Neofytos D, Treadway S, Ostrander D, et al. Epidemiology, outcomes, and mortality predictors of
2310 invasive mold infections among transplant recipients: a 10-year, single-center experience. *Transplant*
2311 *infectious disease : an official journal of the Transplantation Society* 2013; **15**(3): 233-42.
- 2312 3. Pappas PG, Alexander BD, Andes DR, et al. Invasive fungal infections among organ transplant
2313 recipients: results of the Transplant-Associated Infection Surveillance Network (TRANSNET). *Clinical*
2314 *infectious diseases : an official publication of the Infectious Diseases Society of America* 2010; **50**(8):
2315 1101-11.
- 2316 4. Kontoyiannis DP, Marr KA, Park BJ, et al. Prospective Surveillance for Invasive Fungal Infections
2317 in Hematopoietic Stem Cell Transplant Recipients, 2001-2006: Overview of the Transplant-Associated
2318 Infection Surveillance Network (TRANSNET) Database. *Clinical infectious diseases : an official publication*
2319 *of the Infectious Diseases Society of America* 2010; **50**(8): 1091-100.
- 2320 5. Park BJ, Pappas PG, Wannemuehler KA, et al. Invasive non-Aspergillus mold infections in
2321 transplant recipients, United States, 2001-2006. *Emerging infectious diseases* 2011; **17**(10): 1855-64.
- 2322 6. Cornely OA, Maertens J, Winston DJ, et al. Posaconazole vs. fluconazole or itraconazole
2323 prophylaxis in patients with neutropenia. *The New England journal of medicine* 2007; **356**(4): 348-59.
- 2324 7. Jenks JD, Mehta SR, Hoenigl M. Broad spectrum triazoles for invasive mould infections in adults:
2325 Which drug and when? *Medical mycology* 2019; **57**(Supplement_2): S168-s78.
- 2326 8. Lamoth F, Chung SJ, Damonti L, Alexander BD. Changing Epidemiology of Invasive Mold
2327 Infections in Patients Receiving Azole Prophylaxis. *Clinical infectious diseases : an official publication of*
2328 *the Infectious Diseases Society of America* 2017; **64**(11): 1619-21.
- 2329 9. Jenks J, Reed SL, Seidel D, et al. Rare Mold Infections Caused by Mucorales, Lomentospora
2330 Prolificans and Fusarium, San Diego: The Role of Antifungal Combination Therapy. *Int J Antimicrob*
2331 *Agents* 2018.
- 2332 10. Stemler J, Salmanton-Garcia J, Seidel D, et al. Risk factors and mortality in invasive *Rasamsonia*
2333 spp. infection: Analysis of cases in the FungiScope(R) registry and from the literature. *Mycoses* 2019.
- 2334 11. Seidel D, Meissner A, Lackner M, et al. Prognostic factors in 264 adults with invasive
2335 *Scedosporium* spp. and *Lomentospora prolificans* infection reported in the literature and
2336 FungiScope((R)). *Crit Rev Microbiol* 2019; **45**(1): 1-21.
- 2337 12. Cornely OA, Alastruey-Izquierdo A, Arenz D, et al. Global guideline for the diagnosis and
2338 management of mucormycosis: an initiative of the European Confederation of Medical Mycology in
2339 cooperation with the Mycoses Study Group Education and Research Consortium. *The Lancet Infectious*
2340 *diseases* 2019.
- 2341 13. Tortorano AM, Richardson M, Roilides E, et al. ESCMID and ECMM joint guidelines on diagnosis
2342 and management of hyalohyphomycosis: *Fusarium* spp., *Scedosporium* spp. and others. *Clinical*

- 2343 *microbiology and infection : the official publication of the European Society of Clinical Microbiology and*
 2344 *Infectious Diseases* 2014; **20 Suppl 3**: 27-46.
- 2345 14. Chowdhary A, Meis JF, Guarro J, et al. ESCMID and ECMM joint clinical guidelines for the
 2346 diagnosis and management of systemic phaeohyphomycosis: diseases caused by black fungi. *Clinical*
 2347 *microbiology and infection : the official publication of the European Society of Clinical Microbiology and*
 2348 *Infectious Diseases* 2014; **20 Suppl 3**: 47-75.
- 2349 15. Blyth CC, Gilroy NM, Guy SD, et al. Consensus guidelines for the treatment of invasive mould
 2350 infections in haematological malignancy and haemopoietic stem cell transplantation, 2014. *Intern Med J*
 2351 2014; **44**(12b): 1333-49.
- 2352 16. Cornely OA, Lass-Flörl C, Lagrou K, Arsic-Arsenijevic V, Hoenigl M. Improving outcome of fungal
 2353 diseases - Guiding experts and patients towards excellence. *Mycoses* 2017.
- 2354 17. Hoenigl M, Gangneux JP, Segal E, et al. Global Guidelines and Initiatives from the European
 2355 Confederation of Medical Mycology to improve Patient Care and Research Worldwide: New Leadership
 2356 is about Working Together. *Mycoses* 2018.
- 2357 18. Muhammed M, Anagnostou T, Desalermos A, et al. Fusarium infection: report of 26 cases and
 2358 review of 97 cases from the literature. *Medicine (Baltimore)* 2013; **92**(6): 305-16.
- 2359 19. De Hoog GS, Guarro J., Gené, J., Ahmed, S., Al-Hatmi, A.M.S., Figueras, M.J., Vitale, R.G. . Atlas
 2360 of Clinical Fungi: Westerdijk Institute / Universitat Rovira i Virgili, Utrecht / Reus; 2019.
- 2361 20. Guarro J. Fusariosis, a complex infection caused by a high diversity of fungal species refractory
 2362 to treatment. *Eur J Clin Microbiol Infect Dis* 2013; **32**(12): 1491-500.
- 2363 21. Walther G, Stasch S, Kaerger K, et al. Fusarium Keratitis in Germany. *J Clin Microbiol* 2017;
 2364 **55**(10): 2983-95.
- 2365 22. Varon AG, Nouer SA, Barreiros G, et al. Superficial skin lesions positive for Fusarium are
 2366 associated with subsequent development of invasive fusariosis. *J Infect* 2014; **68**(1): 85-9.
- 2367 23. Guevara-Suarez M, Cano-Lira JF, de García MC, et al. Genotyping of Fusarium Isolates from
 2368 Onychomycoses in Colombia: Detection of Two New Species Within the Fusarium solani Species
 2369 Complex and In Vitro Antifungal Susceptibility Testing. *Mycopathologia* 2016; **181**(3-4): 165-74.
- 2370 24. Boral H, van Diepeningen A, Erdem E, et al. Mycotic Keratitis Caused by Fusarium solani sensu
 2371 stricto (FSSC5): A Case Series. *Mycopathologia* 2018; **183**(5): 835-40.
- 2372 25. Galimberti R, Torre AC, Baztan MC, Rodriguez-Chiappetta F. Emerging systemic fungal infections.
 2373 *Clin Dermatol* 2012; **30**(6): 633-50.
- 2374 26. Anaissie EJ, Kuchar RT, Rex JH, et al. Fusariosis associated with pathogenic fusarium species
 2375 colonization of a hospital water system: a new paradigm for the epidemiology of opportunistic mold
 2376 infections. *Clinical infectious diseases : an official publication of the Infectious Diseases Society of*
 2377 *America* 2001; **33**(11): 1871-8.
- 2378 27. Elder BL, Bullock JD, Warwar RE, Khamis HJ, Khalaf SZ. Pan-antimicrobial failure of alexidine as a
 2379 contact lens disinfectant when heated in Bausch & Lomb plastic containers: implications for the
 2380 worldwide Fusarium keratitis epidemic of 2004 to 2006. *Eye Contact Lens* 2012; **38**(4): 222-6.
- 2381 28. Nucci M, Marr KA, Vehreschild MJ, et al. Improvement in the outcome of invasive fusariosis in
 2382 the last decade. *Clin Microbiol Infect* 2014; **20**(6): 580-5.
- 2383 29. Sampathkumar P, Paya CV. Fusarium infection after solid-organ transplantation. *Clin Infect Dis*
 2384 2001; **32**(8): 1237-40.
- 2385 30. Nucci M, Anaissie E. Fusarium infections in immunocompromised patients. *Clin Microbiol Rev*
 2386 2007; **20**(4): 695-704.
- 2387 31. Schell WA. New aspects of emerging fungal pathogens. A multifaceted challenge. *Clin Lab Med*
 2388 1995; **15**(2): 365-87.
- 2389 32. Chen YJ, Chou CL, Lai KJ, Lin YL. Fusarium Brain Abscess in a Patient with Diabetes Mellitus and
 2390 Liver Cirrhosis. *Acta Neurol Taiwan* 2017; **26**(3): 128-32.
- 2391 33. Garcia RR, Min Z, Narasimhan S, Bhanot N. Fusarium brain abscess: case report and literature
 2392 review. *Mycoses* 2015; **58**(1): 22-6.
- 2393 34. Kleinschmidt-Demasters BK. Disseminated Fusarium infection with brain abscesses in a lung
 2394 transplant recipient. *Clin Neuropathol* 2009; **28**(6): 417-21.

- 2395 35. Nucci M, Anaissie E. Cutaneous infection by *Fusarium* species in healthy and
2396 immunocompromised hosts: implications for diagnosis and management. *Clinical infectious diseases : an*
2397 *official publication of the Infectious Diseases Society of America* 2002; **35**(8): 909-20.
- 2398 36. Nucci M, Marr KA, Queiroz-Telles F, et al. *Fusarium* infection in hematopoietic stem cell
2399 transplant recipients. *Clin Infect Dis* 2004; **38**(9): 1237-42.
- 2400 37. Nucci M, Garnica M, Gloria AB, et al. Invasive fungal diseases in haematopoietic cell transplant
2401 recipients and in patients with acute myeloid leukaemia or myelodysplasia in Brazil. *Clin Microbiol Infect*
2402 2013; **19**(8): 745-51.
- 2403 38. Rosa PDD, Ramirez-Castrillon M, Borges R, Aquino V, Meneghello Fuentefria A, Zubaran Goldani
2404 L. Epidemiological aspects and characterization of the resistance profile of *Fusarium* spp. in patients
2405 with invasive fusariosis. *J Med Microbiol* 2019; **68**(10): 1489-96.
- 2406 39. Alastruey-Izquierdo A, Mellado E, Pelaez T, et al. Population-Based Survey of Filamentous Fungi
2407 and Antifungal Resistance in Spain (FILPOP Study). *Antimicrob Agents Chemother* 2013; **57**(9): 4604.
- 2408 40. Fernandez-Cruz A, Semiglia MA, Guinea J, et al. A retrospective cohort of invasive fusariosis in
2409 the era of antimould prophylaxis. *Medical mycology* 2019.
- 2410 41. Dalyan Cilo B, Al-Hatmi AM, Seyedmousavi S, et al. Emergence of fusarioses in a university
2411 hospital in Turkey during a 20-year period. *Eur J Clin Microbiol Infect Dis* 2015; **34**(8): 1683-91.
- 2412 42. Nucci M, Varon AG, Garnica M, et al. Increased incidence of invasive fusariosis with cutaneous
2413 portal of entry, Brazil. *Emerg Infect Dis* 2013; **19**(10): 1567-72.
- 2414 43. Nir-Paz R, Strahilevitz J, Shapiro M, et al. Clinical and epidemiological aspects of infections
2415 caused by *Fusarium* species: a collaborative study from Israel. *J Clin Microbiol* 2004; **42**(8): 3456-61.
- 2416 44. Schwartz KL, Sheffield H, Richardson SE, Sung L, Morris SK. Invasive Fusariosis: A Single Pediatric
2417 Center 15-Year Experience. *J Pediatric Infect Dis Soc* 2015; **4**(2): 163-70.
- 2418 45. Leck AK, Thomas PA, Hagan M, et al. Aetiology of suppurative corneal ulcers in Ghana and south
2419 India, and epidemiology of fungal keratitis. *The British journal of ophthalmology* 2002; **86**(11): 1211-5.
- 2420 46. Nielsen SE, Nielsen E, Julian HO, et al. Incidence and clinical characteristics of fungal keratitis in a
2421 Danish population from 2000 to 2013. *Acta Ophthalmol* 2015; **93**(1): 54-8.
- 2422 47. Aggermann T, Haas P, Krepler K, Binder S, Hochwarter A. *Fusarium* endophthalmitis following
2423 refractive lens exchange for correction of high myopia. *J Cataract Refract Surg* 2009; **35**(8): 1468-70.
- 2424 48. Akers KS, Rowan MP, Niece KL, et al. Antifungal wound penetration of amphotericin and
2425 voriconazole in combat-related injuries: case report. *BMC Infect Dis* 2015; **15**: 184.
- 2426 49. Alastruey-Izquierdo A, Mellado E, Pelaez T, et al. Population-based survey of filamentous fungi
2427 and antifungal resistance in Spain (FILPOP Study). *Antimicrob Agents Chemother* 2013; **57**(7): 3380-7.
- 2428 50. Al-Hatmi AM, Bonifaz A, de Hoog GS, et al. Keratitis by *Fusarium temperatum*, a novel
2429 opportunist. *BMC Infect Dis* 2014; **14**: 588.
- 2430 51. Ali N, Adil SN, Shaikh MU. Bloodstream and central line isolates from hematopoietic stem cell
2431 transplant recipients: data from a developing country. *Transpl Infect Dis* 2014; **16**(1): 98-105.
- 2432 52. Alkhunaizi AM, Bazzi AM, Rabaan AA, Ahmed EA. *Fusarium* Infection in a Kidney Transplant
2433 Recipient Successfully Treated with Voriconazole. *Case Rep Infect Dis* 2018; **2018**: 3128081.
- 2434 53. Alnawaiseh M, Bohm MR, Idelevich EA, et al. [Successful treatment of *Fusarium*-associated
2435 keratitis with multiresistant pathogen and multimorbid patient]. *Ophthalmologie* 2014; **111**(3): 259-61.
- 2436 54. Alves da Costa Pertuiset PA, Logrono JF. *Fusarium* Endophthalmitis following Cataract Surgery:
2437 Successful Treatment with Intravitreal and Systemic Voriconazole. *Case Rep Ophthalmol Med* 2016;
2438 **2016**: 4593042.
- 2439 55. Amadasi S, Pelliccioli GF, Colombini P, et al. [Contact lens-related *Fusarium* keratitis: a case
2440 report]. *Infez Med* 2017; **25**(2): 166-8.
- 2441 56. Amescua G, Arboleda A, Nikpoor N, et al. Rose Bengal Photodynamic Antimicrobial Therapy: A
2442 Novel Treatment for Resistant *Fusarium* Keratitis. *Cornea* 2017; **36**(9): 1141-4.
- 2443 57. Antequera P, Garcia-Conca V, Martin-Gonzalez C, Ortiz-de-la-Tabla V. Multidrug resistant
2444 *Fusarium* keratitis. *Arch Soc Esp Oftalmol* 2015; **90**(8): 382-4.
- 2445 58. Aperlic K, Tietz HJ, Erhard M, Regnath T. [A 25-year-old patient with corneal infiltration].
2446 *Ophthalmologie* 2011; **108**(5): 463-6.

- 2447 59. Arboleda A, Miller D, Cabot F, et al. Assessment of rose bengal versus riboflavin photodynamic
2448 therapy for inhibition of fungal keratitis isolates. *Am J Ophthalmol* 2014; **158**(1): 64-70 e2.
- 2449 60. Arnoni MV, Paula CR, Auler ME, et al. Infections Caused by Fusarium Species in Pediatric Cancer
2450 Patients and Review of Published Literature. *Mycopathologia* 2018; **183**(6): 941-9.
- 2451 61. Atalla A, Garnica M, Maiolino A, Nucci M. Risk factors for invasive mold diseases in allogeneic
2452 hematopoietic cell transplant recipients. *Transpl Infect Dis* 2015; **17**(1): 7-13.
- 2453 62. Atty C, Alagiozian-Angelova VM, Kowal-Vern A. Black plaques and white nodules in a burn
2454 patient. Fusarium and Mucormycosis. *JAMA Dermatol* 2014; **150**(12): 1355-6.
- 2455 63. Avelino-Silva VI, Ramos JF, Leal FE, Testagrossa L, Novis YS. Disseminated Fusarium infection in
2456 autologous stem cell transplant recipient. *Braz J Infect Dis* 2015; **19**(1): 90-3.
- 2457 64. Avisar I, Weinberger D, Kremer I. [Fusarium keratitis and endophthalmitis treated by
2458 intravenous ambisome]. *Harefuah* 2009; **148**(1): 28-9, 88.
- 2459 65. Bandyopadhyay S, Das D, Mondal KK, Ghanta AK, Purkrit SK, Bhasrar R. Epidemiology and
2460 laboratory diagnosis of fungal corneal ulcer in the Sundarban Region of West Bengal, eastern India.
2461 *Nepal J Ophthalmol* 2012; **4**(1): 29-36.
- 2462 66. Bansal Y, Chander J, Kaistha N, Singla N, Sood S, van Diepeningen AD. Fusarium sacchari, a cause
2463 of mycotic keratitis among sugarcane farmers - a series of four cases from North India. *Mycoses* 2016;
2464 **59**(11): 705-9.
- 2465 67. Barbany M, Gris O, Guell JL. Therapeutic sectorial full-thickness sclero-keratoplasty for recurrent
2466 fungal keratitis. *Arch Soc Esp Ophthalmol* 2015; **90**(8): 385-8.
- 2467 68. Barranco-Fernandez I, Garcia-Salido A, Nieto-Moro M, et al. Enucleation Caused by Fusarium
2468 Infection in a Child With Toxic Epidermal Necrolysis. *Pediatr Infect Dis J* 2017; **36**(1): 115-7.
- 2469 69. Barrios Andres JL, Lopez-Soria LM, Alastruey Izquierdo A, et al. Endophthalmitis caused by
2470 Fusarium: An emerging problem in patients with corneal trauma. A case series. *Rev Iberoam Micol* 2018;
2471 **35**(2): 92-6.
- 2472 70. Barut Selver O, Egrilmez S, Palamar M, Arici M, Hilmioglu Polat S, Yagci A. Therapeutic Corneal
2473 Transplant for Fungal Keratitis Refractory to Medical Therapy. *Exp Clin Transplant* 2015; **13**(4): 355-9.
- 2474 71. Baysal M, Umit E, Boz IB, Kirkizlar O, Demir M. Fusarium Endophthalmitis, Unusual and
2475 Challenging Infection in an Acute Leukemia Patient. *Case Rep Hematol* 2018; **2018**: 9531484.
- 2476 72. Behrens-Baumann W, Seibold M, Hofmuller W, et al. Benefit of polyhexamethylene biguanide in
2477 Fusarium keratitis. *Ophthalmic Res* 2012; **48**(4): 171-6.
- 2478 73. Bellanger AP, Grenouillet F, Henon T, et al. Retrospective assessment of beta-D-(1,3)-glucan for
2479 presumptive diagnosis of fungal infections. *APMIS* 2011; **119**(4-5): 280-6.
- 2480 74. Biehl LM, Vehreschild JJ, Liss B, et al. A cohort study on breakthrough invasive fungal infections
2481 in high-risk patients receiving antifungal prophylaxis. *J Antimicrob Chemother* 2016; **71**(9): 2634-41.
- 2482 75. Boddu P, Chen PL, Nagarajan P, et al. Necrotizing fungal gingivitis in a patient with Acute
2483 Myelogenous Leukemia: visible yet obscure. *J Oral Maxillofac Surg Med Pathol* 2018; **30**(1): 50-4.
- 2484 76. Bonfanti P, Bellu R, Principe L, et al. Mother-To-Child Transmission of KPC Carbapenemase-
2485 Producing Klebsiella Pneumoniae at Birth. *Pediatr Infect Dis J* 2017; **36**(2): 228-9.
- 2486 77. Bordoloi P, Nath R, Borgohain M, et al. Subcutaneous mycoses: an aetiological study of 15 cases
2487 in a tertiary care hospital at Dibrugarh, Assam, northeast India. *Mycopathologia* 2015; **179**(5-6): 425-35.
- 2488 78. Borges DP, Santos AWA, Magalhaes SMM, et al. *J Mycol Med* 2018; **28**(2): 390-2.
- 2489 79. Bose P, Parekh HD, Holter JL, Greenfield RA. Disseminated fusariosis occurring in two patients
2490 despite posaconazole prophylaxis. *J Clin Microbiol* 2011; **49**(4): 1674-5.
- 2491 80. Bouanani N, Lamchahab M, Quachouh M, Soussi M, Quessar A, Benchekroun S. [Disseminated
2492 fusariosis during autologous stem cells transplant]. *J Mycol Med* 2013; **23**(2): 119-22.
- 2493 81. Bourgeois GP, Cafardi JA, Sellheyer K, Andea AA. Disseminated Fusarium infection originating
2494 from paronychia in a neutropenic patient: a case report and review of the literature. *Cutis* 2010; **85**(4):
2495 191-4.
- 2496 82. Bui DK, Carvounis PE. Favorable Outcomes of Filamentous Fungal Endophthalmitis Following
2497 Aggressive Management. *J Ocul Pharmacol Ther* 2016; **32**(9): 623-30.

- 2498 83. Busemann C, Kruger W, Schwesinger G, et al. Myocardial and aortal involvement in a case of
2499 disseminated infection with *Fusarium solani* after allogeneic stem cell transplantation: report of a case.
2500 *Mycoses* 2009; **52**(4): 372-6.
- 2501 84. Calcaterra D, Karam K, Suzuki Y. Computed tomography findings in a patient with fungal aortitis:
2502 acute aortic syndrome secondary to fusariosis. *Interact Cardiovasc Thorac Surg* 2013; **17**(1): 171-2.
- 2503 85. Camplesi MJ, Silva HM, Arantes AM, et al. Invasive fungal infection in patients with hematologic
2504 disorders in a Brazilian tertiary care hospital. *Rev Soc Bras Med Trop* 2017; **50**(1): 80-5.
- 2505 86. Candoni A, Caira M, Cesaro S, et al. Multicentre surveillance study on feasibility, safety and
2506 efficacy of antifungal combination therapy for proven or probable invasive fungal diseases in
2507 haematological patients: the SEIFEM real-life combo study. *Mycoses* 2014; **57**(6): 342-50.
- 2508 87. Candoni A, Klimko N, Busca A, et al. Fungal infections of the central nervous system and
2509 paranasal sinuses in onco-haematologic patients. Epidemiological study reporting the diagnostic-
2510 therapeutic approach and outcome in 89 cases. *Mycoses* 2019; **62**(3): 252-60.
- 2511 88. Capoor MR, Gupta S, Sarabahi S, Mishra A, Tiwari VK, Aggarwal P. Epidemiological and clinico-
2512 mycological profile of fungal wound infection from largest burn centre in Asia. *Mycoses* 2012; **55**(2):
2513 181-8.
- 2514 89. Capoor MR, Puri S, Raheja H, et al. Screening of invasive fungal infections by a real-time
2515 panfungal (pan-ACF) polymerase chain reaction assay in patients with haematological malignancy.
2516 *Indian J Med Microbiol* 2017; **35**(1): 41-7.
- 2517 90. Carrasco MA, Genesoni G. Treatment of severe fungal keratitis with subconjunctival
2518 amphotericin B. *Cornea* 2011; **30**(5): 608-11.
- 2519 91. Cavallini GM, Ducange P, Volante V, Benatti C. Successful treatment of *Fusarium* keratitis after
2520 photo refractive keratectomy. *Indian J Ophthalmol* 2013; **61**(11): 669-71.
- 2521 92. Cesaro S, Marinello S, Alessia B, et al. Successful treatment of disseminated fusariosis in a child
2522 with acute myelogenous leukaemia with medical and surgical approach. *Mycoses* 2010; **53**(2): 181-5.
- 2523 93. Chan CC, Holland EJ. Infectious keratitis after Boston type 1 keratoprosthesis implantation.
2524 *Cornea* 2012; **31**(10): 1128-34.
- 2525 94. Chan TS, Au-Yeung R, Chim CS, Wong SC, Kwong YL. Disseminated fusarium infection after
2526 ibrutinib therapy in chronic lymphocytic leukaemia. *Ann Hematol* 2017; **96**(5): 871-2.
- 2527 95. Chan TS, Gill H, Hwang YY, et al. Breakthrough invasive fungal diseases during echinocandin
2528 treatment in high-risk hospitalized hematologic patients. *Ann Hematol* 2014; **93**(3): 493-8.
- 2529 96. Chander J, Singla N, Gulati N, Sood S. *Fusarium sacchari*: a cause of exogenous fungal
2530 endophthalmitis: first case report and review of literature. *Mycopathologia* 2011; **171**(6): 431-4.
- 2531 97. Cheikhrouhou F, Makni F, Neji S, et al. Epidemiological profile of fungal keratitis in Sfax (Tunisia).
2532 *J Mycol Med* 2014; **24**(4): 308-12.
- 2533 98. Cheng P, Meng F, Zhang D. Fatal *Fusarium solani* infection after stem cell transplant for aplastic
2534 anemia. *Exp Clin Transplant* 2014; **12**(4): 384-7.
- 2535 99. Chew R, Woods ML. Epidemiology of fungal keratitis in Queensland, Australia. *Clin Exp*
2536 *Ophthalmol* 2019; **47**(1): 26-32.
- 2537 100. Chidambaram JD, Prajna NV, Larke N, et al. In vivo confocal microscopy appearance of *Fusarium*
2538 and *Aspergillus* species in fungal keratitis. *Br J Ophthalmol* 2017; **101**(8): 1119-23.
- 2539 101. Chidambaram JD, Venkatesh Prajna N, Srikanthi P, et al. Epidemiology, risk factors, and clinical
2540 outcomes in severe microbial keratitis in South India. *Ophthalmic Epidemiol* 2018; **25**(4): 297-305.
- 2541 102. Chiewchanvit S, Chongkae S, Mahanupab P, et al. Melanization of *Fusarium keratoplasticum* (*F.*
2542 *solani* Species Complex) During Disseminated Fusariosis in a Patient with Acute Leukemia.
2543 *Mycopathologia* 2017; **182**(9-10): 879-85.
- 2544 103. Cocchi S, Codeluppi M, Venturelli C, et al. *Fusarium verticillioides* fungemia in a liver
2545 transplantation patient: successful treatment with voriconazole. *Diagn Microbiol Infect Dis* 2011; **71**(4):
2546 438-41.
- 2547 104. Collado C, Medina L, Zorraquino A, et al. Cutaneous fusariosis by a species of the *Fusarium*
2548 *dimerum* species complex in a patient with acute myeloblastic leukemia. *Rev Iberoam Micol* 2013; **30**(2):
2549 119-21.

- 2550 105. Comer GM, Stem MS, Saxe SJ. Successful salvage therapy of Fusarium endophthalmitis
2551 secondary to keratitis: an interventional case series. *Clin Ophthalmol* 2012; **6**: 721-6.
- 2552 106. Cooke NS, Feighery C, Armstrong DK, Walsh M, Dempsey S. Cutaneous Fusarium solani infection
2553 in childhood acute lymphoblastic leukaemia. *Clin Exp Dermatol* 2009; **34**(5): e117-9.
- 2554 107. Cuellar-Rodriguez J, Bravo LT, Oethinger M, Fraser T, Mossad SB. Disseminated fusariosis in a
2555 recipient of a bone-marrow transplant. *Lancet Infect Dis* 2009; **9**(8): 520.
- 2556 108. Cvetkova N, Kostler J, Prahs P, Helbig H, Dietrich-Ntoukas T. [Prolonged topical natamycin 5 %
2557 therapy before and after keratoplasty for Fusarium keratitis]. *Ophthalmologe* 2016; **113**(5): 420-4.
- 2558 109. da Silva-Rocha WP, Zuza-Alves DL, Melo AS, Chaves GM. Fungal Peritonitis Due to Fusarium
2559 solani Species Complex Sequential Isolates Identified with DNA Sequencing in a Kidney Transplant
2560 Recipient in Brazil. *Mycopathologia* 2015; **180**(5-6): 397-401.
- 2561 110. Dabas Y, Bakhshi S, Xess I. Fatal Cases of Bloodstream Infection by Fusarium solani and Review
2562 of Published Literature. *Mycopathologia* 2016; **181**(3-4): 291-6.
- 2563 111. Dahlan R, Patel A, Haider S. Successful use of posaconazole to treat invasive cutaneous fungal
2564 infection in a liver transplant patient on sirolimus. *Can J Infect Dis Med Microbiol* 2012; **23**(2): e44-7.
- 2565 112. Dai W, Dharamsi JW, Soliman S, et al. Cutaneous fusariosis developing in a post-irradiation site.
2566 *Dermatol Online J* 2011; **17**(5): 5.
- 2567 113. Dananche C, Cassier P, Sautour M, et al. Fungaemia caused by Fusarium proliferatum in a
2568 patient without definite immunodeficiency. *Mycopathologia* 2015; **179**(1-2): 135-40.
- 2569 114. Das K, Bhattacharyya A, Chandy M, et al. Infection control challenges of infrequent and rare
2570 fungal pathogens: lessons from disseminated Fusarium and Kodamaea ohmeri infections. *Infect Control*
2571 *Hosp Epidemiol* 2015; **36**(7): 866-8.
- 2572 115. Das S, Sharma S, Mahapatra S, Sahu SK. Fusarium keratitis at a tertiary eye care centre in India.
2573 *Int Ophthalmol* 2015; **35**(3): 387-93.
- 2574 116. Davoudi S, Kumar VA, Jiang Y, Kupferman M, Kontoyiannis DP. Invasive mould sinusitis in
2575 patients with haematological malignancies: a 10 year single-centre study. *J Antimicrob Chemother* 2015;
2576 **70**(10): 2899-905.
- 2577 117. de Almeida JNJ, Sztajnbok J, da Silva ARJ, et al. Rapid identification of moulds and arthroconidial
2578 yeasts from positive blood cultures by MALDI-TOF mass spectrometry. *Medical mycology* 2016; **54**(8):
2579 885-9.
- 2580 118. de Almeida Junior JN, Ibrahim KY, Del Negro GM, et al. Rhizopus arrhizus and Fusarium solani
2581 Concomitant Infection in an Immunocompromised Host. *Mycopathologia* 2016; **181**(1-2): 125-9.
- 2582 119. de Leon-Borras R, DelPilar-Morales E, Rivera-Perez N, et al. Factors Associated to Invasive Fungal
2583 Infection in Hispanic Patients with Hematological Malignancies. *Bol Asoc Med P R* 2017; **109**(1): 43-8.
- 2584 120. De Pinho DB, Fernandes LL, Carvalho Barreiros Mda G, Quintella LP, Sodre CT, Ramos ESM.
2585 Disseminated fusariosis in a bone marrow transplant patient. *J Clin Aesthet Dermatol* 2012; **5**(12): 40-2.
- 2586 121. de Souza M, Matsuzawa T, Lyra L, et al. Fusarium napiforme systemic infection: case report with
2587 molecular characterization and antifungal susceptibility tests. *Springerplus* 2014; **3**: 492.
- 2588 122. del Alcazar E, Jaka A, Camino N, Gancho G, Tuneu A. Fever and skin lesions in an
2589 immunocompromised patient. *Clin Exp Dermatol* 2015; **40**(2): 219-21.
- 2590 123. Delia M, Monno R, Giannelli G, et al. Fusariosis in a Patient with Acute Myeloid Leukemia: A
2591 Case Report and Review of the Literature. *Mycopathologia* 2016; **181**(5-6): 457-63.
- 2592 124. Deorukhkar S, Katiyar R, Saini S. Epidemiological features and laboratory results of bacterial and
2593 fungal keratitis: a five-year study at a rural tertiary-care hospital in western Maharashtra, India.
2594 *Singapore Med J* 2012; **53**(4): 264-7.
- 2595 125. Diongue K, Sow AS, Nguer M, et al. [Keratomyces due to Fusarium oxysporum treated with the
2596 combination povidone iodine eye drops and oral fluconazole]. *J Mycol Med* 2015; **25**(4): e134-7.
- 2597 126. Direkel S, Otag F, Aslan G, Ulger M, Emekdas G. [Identification of filamentous fungi isolated from
2598 clinical samples by two different methods and their susceptibility results]. *Mikrobiyol Bul* 2012; **46**(1):
2599 65-78.

2600 127. Dony A, Perpoint T, Ducastelle S, Ferry T. Disseminated fusariosis with immune reconstitution
2601 syndrome and cracking mycotic aortic aneurysm in a 55-year-old patient with acute myeloid leukaemia.
2602 *BMJ Case Rep* 2013; **2013**.

2603 128. Dutta P, Premkumar A, Chakrabarti A, et al. Fusarium falciforme infection of foot in a patient
2604 with type 2 diabetes mellitus: a case report and review of the literature. *Mycopathologia* 2013; **176**(3-
2605 4): 225-32.

2606 129. Edelstein SL, Akduman L, Durham BH, Fothergill AW, Hsu HY. Resistant Fusarium keratitis
2607 progressing to endophthalmitis. *Eye Contact Lens* 2012; **38**(5): 331-5.

2608 130. Edupuganti S, Roupael N, Mehta A, et al. Fusarium falciforme vertebral abscess and
2609 osteomyelitis: case report and molecular classification. *J Clin Microbiol* 2011; **49**(6): 2350-3.

2610 131. Efe Iris N, Guvenc S, Ozcelik T, et al. Successful Treatment of Disseminated Fusariosis with the
2611 Combination of Voriconazole and Liposomal Amphotericin B. *Turk J Haematol* 2016; **33**(4): 363-4.

2612 132. Er-Rami M, Souhail H, Lemkhente Z, El Mellouki W, Lmimouni B. [Severe keratomycosis due to
2613 Fusarium solani induced by a telluric foreign body: About a case in moroccan Sahara]. *J Mycol Med*
2614 2011; **21**(3): 206-9.

2615 133. Ersal T, Al-Hatmi AS, Cilo BD, et al. Fatal disseminated infection with Fusarium petroliphilum.
2616 *Mycopathologia* 2015; **179**(1-2): 119-24.

2617 134. Esnakula AK, Summers I, Naab TJ. Fatal disseminated fusarium infection in a human
2618 immunodeficiency virus positive patient. *Case Rep Infect Dis* 2013; **2013**: 379320.

2619 135. Fan F, Lui G, Ip M, Lee N. Foot ulcer, skin nodules, and blurred vision. *Clin Infect Dis* 2012; **54**(5):
2620 706, 36-7.

2621 136. Fanci R, Pini G, Bartolesi AM, Pecile P. Refractory disseminated fusariosis by Fusarium
2622 verticillioides in a patient with acute myeloid leukaemia relapsed after allogeneic hematopoietic stem
2623 cell transplantation: a case report and literature review. *Rev Iberoam Micol* 2013; **30**(1): 51-3.

2624 137. Feramisco JD, Hsiao JL, Fox LP, Ruben BS. Angioinvasive Fusarium and concomitant Enterococcus
2625 infection arising in association with leukemia cutis. *J Cutan Pathol* 2011; **38**(11): 926-9.

2626 138. Gajjar DU, Pal AK, Ghodadra BK, Vasavada AR. Microscopic evaluation, molecular identification,
2627 antifungal susceptibility, and clinical outcomes in fusarium, Aspergillus and, dematiaceous keratitis.
2628 *Biomed Res Int* 2013; **2013**: 605308.

2629 139. Gamba P, Lombardi C. Eosinophil fungal rhinosinusitis caused by Fusarium infection secondary
2630 to odontogenic maxillary sinus disease: when collaboration between otolaryngologist and allergologist
2631 leads to the correct diagnosis and therapy. *Eur Ann Allergy Clin Immunol* 2017; **49**(3): 138-42.

2632 140. Gao Y, Chen N, Dong XG, Yuan GQ, Yu B, Xie LX. Surgical management of fungal endophthalmitis
2633 resulting from fungal keratitis. *Int J Ophthalmol* 2016; **9**(6): 848-53.

2634 141. Garcia-Delpech S, Diaz-Llopis M, Udaondo P, Salom D. Fusarium keratitis 3 weeks after healed
2635 corneal cross-linking. *J Refract Surg* 2010; **26**(12): 994-5.

2636 142. Garcia-Ruiz JC, Olazabal I, Adan Pedroso RM, et al. Disseminated fusariosis and hematologic
2637 malignancies, a still devastating association. Report of three new cases. *Rev Iberoam Micol* 2015; **32**(3):
2638 190-6.

2639 143. Gaur S, Rajgopal A, Ashbee R. A successfully treated case of peritonitis due to Fusarium
2640 dimerum. *J Infect* 2010; **61**(1): 86-8.

2641 144. Geddes ER, Polder K, Cutlan JE, Torres-Cabala CA, Hymes SR. Ulcerated plaque under a ruby ring
2642 in an immunosuppressed patient. *Dermatol Online J* 2010; **16**(8): 4.

2643 145. Georgiadou SP, Velegraki A, Arabatzis M, et al. Cluster of Fusarium verticillioides bloodstream
2644 infections among immunocompetent patients in an internal medicine department after reconstruction
2645 works in Larissa, Central Greece. *J Hosp Infect* 2014; **86**(4): 267-71.

2646 146. Ghosh AK, Gupta A, Rudramurthy SM, Paul S, Hallur VK, Chakrabarti A. Fungal Keratitis in North
2647 India: Spectrum of Agents, Risk Factors and Treatment. *Mycopathologia* 2016; **181**(11-12): 843-50.

2648 147. Ghosh S, Phillips A, Ghosh S, Singh A. Native valve endocarditis, fusarium and end-stage renal
2649 disease. *BMJ Case Rep* 2018; **2018**.

2650 148. Gitau AM, Ng'ang'a ZW, Sigilai W, Bii C, Mwangi M. Fungal infections among diabetic foot ulcer-
2651 patients attending diabetic clinic in Kenyatta National Hospital, Kenya. *East Afr Med J* 2011; **88**(1): 9-17.

2652 149. Guber I, Bergin C, Majo F. Repeated Intrastromal Injections of Voriconazole in Combination with
2653 Corneal Debridement for Recalcitrant Fungal Keratitis - a Case Series. *Klin Monbl Augenheilkd* 2016;
2654 **233**(4): 369-72.

2655 150. Gutierrez Paredes EM, Gamez Perez L, Gonzalez Rodriguez AJ, Ramon Quiles D, Monteagudo
2656 Castro C, Jorda Cuevas E. Disseminated fusariosis in immunocompromised patients. *Eur J Dermatol*
2657 2011; **21**(5): 753-5.

2658 151. Halliday CL, Chen SC, Kidd SE, et al. Antifungal susceptibilities of non-Aspergillus filamentous
2659 fungi causing invasive infection in Australia: support for current antifungal guideline recommendations.
2660 *Int J Antimicrob Agents* 2016; **48**(4): 453-8.

2661 152. Ham JC, Ruijs GJ, van Marwijk Kooy MR. [A man with neutropenic fever]. *Ned Tijdschr Geneesk*
2662 2013; **157**(12): A5997.

2663 153. Hasseine L, Cassaing S, Robert-Gangneux F, et al. High negative predictive value diagnostic
2664 strategies for the reevaluation of early antifungal treatment: A multicenter prospective trial in patients
2665 at risk for invasive fungal infections. *J Infect* 2015; **71**(2): 258-65.

2666 154. Hassler A, Lieb A, Seidel D, et al. Disseminated Fusariosis in Immunocompromised Children-
2667 Analysis of Recent Cases Identified in the Global Fungiscope Registry. *Pediatr Infect Dis J* 2017; **36**(2):
2668 230-1.

2669 155. Hayashida MZ, Seque CA, Enokihara M, Porro AM. Disseminated fusariosis with cutaneous
2670 involvement in hematologic malignancies: report of six cases with high mortality rate. *An Bras Dermatol*
2671 2018; **93**(5): 726-9.

2672 156. Hiebert RM, Welliver RC, Yu Z. Fusarium Osteomyelitis in a Patient With Pearson Syndrome:
2673 Case Report and Review of the Literature. *Open Forum Infect Dis* 2016; **3**(4): ofw183.

2674 157. Hoarau G, Albrieux M, Martin-Phipps T, et al. [Fungal keratitis: A 5-year monocentric
2675 retrospective study on Reunion Island]. *J Fr Ophtalmol* 2018; **41**(4): 321-5.

2676 158. Hu JW, Shu XR, Ren J, et al. [Fusarium solani infection in a patient after allogeneic hematopoietic
2677 stem cell transplantation: case report and literature review]. *Zhonghua Jie He He Hu Xi Za Zhi* 2010;
2678 **33**(10): 730-3.

2679 159. Inano S, Kimura M, Iida J, Arima N. Combination therapy of voriconazole and terbinafine for
2680 disseminated fusariosis: case report and literature review. *J Infect Chemother* 2013; **19**(6): 1173-80.

2681 160. Jacoby E, Keller N, Barkai G. [Combination antifungal therapy in hematopoietic stem cell
2682 transplantation patients]. *Harefuah* 2012; **151**(8): 455-7, 99, 98.

2683 161. Jain R, Singhal SK, Singla N, Punia RS, Chander J. Mycological Profile and Antifungal Susceptibility
2684 of Fungal Isolates from Clinically Suspected Cases of Fungal Rhinosinusitis in a Tertiary Care Hospital in
2685 North India. *Mycopathologia* 2015; **180**(1-2): 51-9.

2686 162. Jenks JD, Reed SL, Seidel D, et al. Rare mould infections caused by Mucorales, Lomentospora
2687 prolificans and Fusarium, in San Diego, CA: the role of antifungal combination therapy. *International*
2688 *journal of antimicrobial agents* 2018; **52**(5): 706-12.

2689 163. Jiang K, Brownstein S, Baig K, Lam K, Toye B. Clinicopathologic case reports of Alternaria and
2690 Fusarium keratitis in Canada. *Can J Ophthalmol* 2013; **48**(6): e151-4.

2691 164. Jorgensen JS, Prause JU, Kiilgaard JF. Bilateral endogenous Fusarium solani endophthalmitis in a
2692 liver-transplanted patient: a case report. *J Med Case Rep* 2014; **8**: 101.

2693 165. Joseph J, Chaurasia S, Sharma S. Case Report: Corneal Coinfection with Fungus and Amoeba:
2694 Report of Two Patients and Literature Review. *Am J Trop Med Hyg* 2018; **99**(3): 805-8.

2695 166. Jossi M, Ambrosioni J, Macedo-Vinas M, Garbino J. Invasive fusariosis with prolonged fungemia
2696 in a patient with acute lymphoblastic leukemia: case report and review of the literature. *Int J Infect Dis*
2697 2010; **14**(4): e354-6.

2698 167. Kadri SS, Remy KE, Strich JR, Gea-Banacloche J, Leitman SF. Role of granulocyte transfusions in
2699 invasive fusariosis: systematic review and single-center experience. *Transfusion* 2015; **55**(9): 2076-85.

2700 168. Kah TA, Yong KC, Rahman RA. Disseminated fusariosis and endogenous fungal endophthalmitis
2701 in acute lymphoblastic leukemia following platelet transfusion possibly due to transfusion-related
2702 immunomodulation. *BMC Ophthalmol* 2011; **11**: 30.

2703 169. Kalaiselvi G, Narayana S, Krishnan T, Sengupta S. Intrastromal voriconazole for deep recalcitrant
2704 fungal keratitis: a case series. *Br J Ophthalmol* 2015; **99**(2): 195-8.

2705 170. Kang Y, Li L, Zhu J, Zhao Y, Zhang Q. Identification of *Fusarium* from a patient with fungemia
2706 after multiple organ injury. *Mycopathologia* 2013; **176**(1-2): 151-5.

2707 171. Kapp M, Schargus M, Deuchert T, et al. Endophthalmitis as primary clinical manifestation of fatal
2708 fusariosis in an allogeneic stem cell recipient. *Transpl Infect Dis* 2011; **13**(4): 374-9.

2709 172. Kassas O, Charfi M, Trabelsi H, Hammami R, Elloumi M. *Fusarium solani* endocarditis in an acute
2710 leukemia patient. *Med Mal Infect* 2016; **46**(1): 57-9.

2711 173. Katz T, Wasiak J, Cleland H, Padiglione A. Incidence of non-candidal fungal infections in severe
2712 burn injury: an Australian perspective. *Burns* 2014; **40**(5): 881-6.

2713 174. Kebabci N, van Diepeningen AD, Ener B, et al. Fatal breakthrough infection with *Fusarium*
2714 andiyazi: new multi-resistant aetiological agent cross-reacting with *Aspergillus galactomannan* enzyme
2715 immunoassay. *Mycoses* 2014; **57**(4): 249-55.

2716 175. Khan S, Pillai GS, Vivek V, Dinesh K, Karim PM. Post-operative endophthalmitis due to *Fusarium*
2717 dimerum. *Southeast Asian J Trop Med Public Health* 2012; **43**(6): 1484-8.

2718 176. Khetan S, Khetan P, Katkar V, Kusulkar M. Urinary tract infection due to *Fusarium oxysporum* in
2719 an immunocompetent patient with chronic kidney disease. *J Biomed Res* 2018; **32**(2): 157-60.

2720 177. Khor WB, Prajna VN, Garg P, et al. The Asia Cornea Society Infectious Keratitis Study: A
2721 Prospective Multicenter Study of Infectious Keratitis in Asia. *Am J Ophthalmol* 2018; **195**: 161-70.

2722 178. Kim MS, Lee SM, Sung HS, et al. Clinical analysis of deep cutaneous mycoses: a 12-year
2723 experience at a single institution. *Mycoses* 2012; **55**(6): 501-6.

2724 179. King BA, Seropian S, Fox LP. Disseminated fusarium infection with muscle involvement. *Journal*
2725 *of the American Academy of Dermatology* 2011; **65**(1): 235-7.

2726 180. Kitahata M, Suzuki T, Oka N, Toriyama K, Ohashi Y. Anterior Segment Optical Coherence
2727 Tomography of Patients With Late-Onset Tunnel Fungal Infections With Endophthalmitis After Cataract
2728 Surgery. *Cornea* 2016; **35**(8): 1138-40.

2729 181. Koltze A, Rath P, Schoning S, et al. beta-D-Glucan Screening for Detection of Invasive Fungal
2730 Disease in Children Undergoing Allogeneic Hematopoietic Stem Cell Transplantation. *J Clin Microbiol*
2731 2015; **53**(8): 2605-10.

2732 182. Kordelas L, Gromke T, Trenchel R, Ditschkowski M, Koldehoff M, Beelen DW. CD34+ highly
2733 enriched allogeneic stem cell transplantation in a patient with mixed phenotype acute leukemia and
2734 *Fusarium solani* sepsis. *Ann Hematol* 2016; **95**(1): 155-6.

2735 183. Kulkarni VL, Kinikar AG, Bhalerao DS, Roushani S. A Case of Keratomycosis Caused by *Fusarium*
2736 *Solani* at Rural Tertiary Care Center. *J Clin Diagn Res* 2017; **11**(9): DD01-DD3.

2737 184. Kumari I, Singh SK, Chauhan RK, Kaushal SK. Disseminated cutaneous fusariosis in human
2738 immunodeficiency virus-infected patient and dramatic response with oral itraconazole. *Indian J*
2739 *Dermatol Venereol Leprol* 2018; **84**(3): 362-8.

2740 185. Kurosawa S, Doki N, Sekiya N, Ikuta S, Takaki Y, Ohashi K. Sudden blindness as an initial
2741 manifestation of localized fusariosis in ethmoid sinus and optic nerve. *Ann Hematol* 2017; **96**(10): 1771-
2742 2.

2743 186. Kurosawa S, Sekiya N, Muraosa Y, et al. [Disseminated fusariosis in patients with acute leukemia:
2744 a retrospective analysis of three cases]. *Rinsho Ketsueki* 2017; **58**(12): 2375-9.

2745 187. Labbe A, Gabison E, Cochereau I, Baudouin C. Diagnosis of fungal keratitis by in vivo confocal
2746 microscopy: a case report. *Eye (Lond)* 2011; **25**(7): 956-8.

2747 188. Labiris G, Troeber L, Gatziofas Z, Stavridis E, Seitz B. Bilateral *Fusarium oxysporum* keratitis
2748 after laser in situ keratomileusis. *J Cataract Refract Surg* 2012; **38**(11): 2040-4.

2749 189. Labois A, Gray C, Lepretre S. Successful treatment of disseminated fusariosis with voriconazole
2750 in an acute lymphoblastic leukaemia patient. *Mycoses* 2011; **54 Suppl 4**: 8-11.

2751 190. Lai J, Pandya V, McDonald R, Sutton G. Management of *Fusarium* keratitis and its associated
2752 fungal iris nodule with intracameral voriconazole and amphotericin B. *Clinical & experimental optometry*
2753 2014; **97**(2): 181-3.

- 2754 191. Lalitha P, Shapiro BL, Loh AR, et al. Amphotericin B and natamycin are not synergistic in vitro
2755 against *Fusarium* and *Aspergillus* spp. isolated from keratitis. *Br J Ophthalmol* 2011; **95**(5): 744-5.
- 2756 192. Latif AL, Harper C, Macdonald I, Morrison A. Splenectomy as an effective debulking therapy for
2757 disseminated mould infection in acute myeloid leukaemia following adjuvant therapy with interferon
2758 gamma and liposomal amphotericin. *Medical mycology case reports* 2012; **1**(1): 82-4.
- 2759 193. Le Clech L, Hutin P, Le Gal S, Guillerm G. Skin nodules in a patient with acute lymphoblastic
2760 leukaemia. *BMJ Case Rep* 2014; **2014**.
- 2761 194. Lerolle N, Raffoux E, Socie G, et al. Breakthrough invasive fungal disease in patients receiving
2762 posaconazole primary prophylaxis: a 4-year study. *Clinical microbiology and infection : the official
2763 publication of the European Society of Clinical Microbiology and Infectious Diseases* 2014; **20**(11): O952-
2764 9.
- 2765 195. Lin CC, Lalitha P, Srinivasan M, et al. Seasonal trends of microbial keratitis in South India. *Cornea*
2766 2012; **31**(10): 1123-7.
- 2767 196. Lin HC, Lin JL, Lin-Tan DT, Ma HK, Chen HC. Early keratectomy in the treatment of moderate
2768 *Fusarium* keratitis. *PLoS One* 2012; **7**(8): e42126.
- 2769 197. Lipovy B, Rihova H, Hanslianova M, et al. Unsuccessful therapy of combined mycotic infection in
2770 a severely burned patient: a case study. *Acta Chir Plast* 2009; **51**(3-4): 83-4.
- 2771 198. Ghanem A, Little SJ, Drumright L, Liu L, Morris S, Garfein RS. High-risk behaviors associated with
2772 injection drug use among recently HIV-infected men who have sex with men in San Diego, CA. *AIDS and
2773 behavior* 2011; **15**(7): 1561-9.
- 2774 199. Liu YS, Wang NC, Ye RH, Kao WY. Disseminated *Fusarium* infection in a patient with acute
2775 lymphoblastic leukemia: A case report and review of the literature. *Oncol Lett* 2014; **7**(2): 334-6.
- 2776 200. Loffler KU, Holz FG, Herwig-Carl MC. [Therapy Resistant *Fusarium* Keratitis with Intraocular
2777 Involvement - Potential Sources of a Persisting Infection]. *Klin Monbl Augenheilkd* 2018; **235**(7): 797-
2778 800.
- 2779 201. Lortholary O, Obenga G, Biswas P, et al. International retrospective analysis of 73 cases of
2780 invasive fusariosis treated with voriconazole. *Antimicrobial agents and chemotherapy* 2010; **54**(10):
2781 4446-50.
- 2782 202. Lubke J, Auw-Hadrach C, Meyer-Ter-Vehn T, Emrani E, Reinhard T. [*Fusarium* keratitis with
2783 dramatic outcome]. *Ophthalmologe* 2017; **114**(5): 462-5.
- 2784 203. Malek I, Bouguila H, Nacef L, Ayed S. [Favorable outcome in a case of complicated fungal
2785 keratitis]. *J Fr Ophthalmol* 2013; **36**(3): 289-91.
- 2786 204. Mansur AT, Artunkal S, Ener B. *Fusarium oxysporum* infection of stasis ulcer: eradication with
2787 measures aimed to improve stasis. *Mycoses* 2011; **54**(4): e205-7.
- 2788 205. Mapelli ET, Cerri A, Borghi E, et al. A rare case of subcutaneous fusariosis in an
2789 immunocompetent patient. *G Ital Dermatol Venereol* 2017; **152**(2): 178-80.
- 2790 206. Maquera-Afaray J, Perez-Lazo G, Rodriguez R, et al. [Invasive Fusariosis: Report of Three Cases in
2791 Peru]. *Rev Peru Med Exp Salud Publica* 2018; **35**(3): 523-6.
- 2792 207. Marcoux D, Jafarian F, Joncas V, Buteau C, Kokta V, Moghrabi A. Deep cutaneous fungal
2793 infections in immunocompromised children. *Journal of the American Academy of Dermatology* 2009;
2794 **61**(5): 857-64.
- 2795 208. Mehta A, Bellam N. Disseminated fusariosis during acute myelogenous leukemia induction
2796 treatment. *Blood* 2014; **123**(22): 3379.
- 2797 209. Mellouli F, Ksouri H, Barbouche R, et al. Successful treatment of *Fusarium solani* ecthyma
2798 gangrenosum in a patient affected by leukocyte adhesion deficiency type 1 with granulocytes
2799 transfusions. *BMC Dermatol* 2010; **10**: 10.
- 2800 210. Mena R, Carrasco E, Godoy-Martinez P, Stchigel AM, Cano-Lira JF, Zaror L. [A case of mycotic
2801 keratitis due to *Fusarium solani* in Valdivia, Chile]. *Rev Iberoam Micol* 2015; **32**(2): 106-10.
- 2802 211. Menon BS, Juraida E, Manaf Z, Mohamed M, Ibrahim H. Disseminated fusarium. *Int J Infect Dis*
2803 2009; **13**(5): e333-4.
- 2804 212. Meriglier E, Puyade M, Cateau E, Maillard N. [Nodular skin lesions revealing fusariosis in a severe
2805 aplastic anemia patient]. *Presse Med* 2015; **44**(5): 574-6.

2806 213. Meyer SA, Jones BM. Treatment of a Locally Invasive Cutaneous Fusarium Species Infection With
2807 Voriconazole and Liposomal Amphotericin B in a Patient With Relapsed Acute Myeloid Leukemia. *J Adv*
2808 *Pract Oncol* 2017; **8**(5): 522-6.

2809 214. Mochizuki K, Shiraki I, Murase H, Ohkusu K, Nishimura K. Identification and sensitivity of two
2810 rare fungal species isolated from two patients with Fusarium keratomycosis. *J Infect Chemother* 2012;
2811 **18**(6): 939-44.

2812 215. Mohanty NK, Sahu S. Fusarium solani infection in a kidney transplant recipient. *Indian J Nephrol*
2813 2014; **24**(5): 312-4.

2814 216. Morel LN, Cid PM, De Celada RM, et al. Disseminated fusariosis in a pediatric population. *Pediatr*
2815 *Dermatol* 2013; **30**(6): e255-6.

2816 217. Moretti ML, Busso-Lopes AF, Tararam CA, et al. Airborne transmission of invasive fusariosis in
2817 patients with hematologic malignancies. *PLoS One* 2018; **13**(4): e0196426.

2818 218. Moroti RV, Gheorghita V, Al-Hatmi AM, de Hoog GS, Meis JF, Netea MG. Fusarium ramigenum, a
2819 novel human opportunist in a patient with common variable immunodeficiency and cellular immune
2820 defects: case report. *BMC Infect Dis* 2016; **16**: 79.

2821 219. Mosquera Gordillo MA, Baron Cano N, Garralda Luquin A, et al. Keratitis secondary to Fusarium
2822 spp. in Spain 2012-2014. *Arch Soc Esp Oftalmol* 2018; **93**(6): 283-9.

2823 220. Muller C, Schumacher U, Gregor M, Lamprecht G. How immunocompromised are short bowel
2824 patients receiving home parenteral nutrition? Apropos a case of disseminated Fusarium oxysporum
2825 sepsis. *JPEN J Parenter Enteral Nutr* 2009; **33**(6): 717-20.

2826 221. Muraosa Y, Oguchi M, Yahiro M, Watanabe A, Yaguchi T, Kamei K. Epidemiological Study of
2827 Fusarium Species Causing Invasive and Superficial Fusariosis in Japan. *Med Mycol J* 2017; **58**(1): E5-E13.

2828 222. Nakai K, Yoneda K, Imataki O, et al. Transepidermal growth in disseminated Fusarium infection. *J*
2829 *Dermatol* 2014; **41**(8): 770-1.

2830 223. Nambiar P, Cober E, Johnson L, Brizendine KD. Fatal Fusarium infection manifesting as
2831 osteomyelitis following previous treatment with amphotericin B in a multi-visceral transplant: Case
2832 report and review of Fusarium infections in solid organ transplantation. *Transpl Infect Dis* 2018; **20**(3):
2833 e12872.

2834 224. Narayanan G, Nath SR. Disseminated Fusarium fungemia in a Patient With Acute Myeloid
2835 Leukemia. *Mayo Clin Proc* 2016; **91**(4): 542-3.

2836 225. Neji S, Trabelsi H, Cheikhrouhou F, et al. [Fusariosis diagnosed in the laboratory of an UH in
2837 Tunisia: epidemiological, clinical and mycological study]. *J Mycol Med* 2013; **23**(2): 130-5.

2838 226. Nenoff P, Bernhardt A, Tintelnot K, et al. [Cutaneous infection due to Fusarium oxysporum in a
2839 female diabetic: molecular biological detection of the mold from formalin-fixed paraffin embedded
2840 tissue using sequencing of the ITS region of the rDNA]. *Hautarzt* 2014; **65**(6): 542-7.

2841 227. Nentwich MM, Bordon M, di Martino DS, et al. Clinical and epidemiological characteristics of
2842 infectious keratitis in Paraguay. *Int Ophthalmol* 2015; **35**(3): 341-6.

2843 228. Hoenigl M, Smith DM, Anderson CM, Green NL, Mehta S, Little S. Influence of voluntary repeat
2844 HIV testing on sexual risk behavior among MSM. *Conference on Retroviruses and Opportunistic*
2845 *Infections 2015* 2015; **Abstract 1022**.

2846 229. Nucci F, Nouer SA, Capone D, Nucci M. Invasive mould disease in haematologic patients:
2847 comparison between fusariosis and aspergillosis. *Clin Microbiol Infect* 2018; **24**(10): 1105 e1- e4.

2848 230. Nucci M, Carlesse F, Cappellano P, et al. Earlier diagnosis of invasive fusariosis with Aspergillus
2849 serum galactomannan testing. *PloS one* 2014; **9**(1): e87784.

2850 231. Nucci M, Shoham S, Abdala E, et al. Outcomes of patients with invasive fusariosis who undergo
2851 further immunosuppressive treatments, is there a role for secondary prophylaxis? *Mycoses* 2019; **62**(5):
2852 413-7.

2853 232. Nunes Mdo C, Barbosa FB, Gomes GH, Braulio R, Nicolliello MF, Ferrari TC. Fatal right-sided
2854 endocarditis caused by Fusarium in an immunocompromised patient: a case report. *Mycoses* 2011;
2855 **54**(5): 460-2.

2856 233. Ocampo-Garza J, Herz-Ruelas ME, Chavez-Alvarez S, et al. Disseminated fusariosis with
2857 endophthalmitis after skin trauma in acute lymphoblastic leukaemia. *J Eur Acad Dermatol Venereol*
2858 2016; **30**(11): e121-e3.

2859 234. Okada K, Endo T, Hashimoto D, et al. Disseminated fusariosis emerged from prolonged local
2860 genital infection after cord blood transplantation. *J Infect Chemother* 2018; **24**(8): 660-3.

2861 235. Okura Y, Kawamura N, Okano M, et al. Fusarium falciforme infection in a patient with chronic
2862 granulomatous disease: Unique long-term course of epidural abscess. *Pediatr Int* 2015; **57**(1): e4-6.

2863 236. Olivares R, Luppi M, Diaz MC. [Successful treatment of disseminated fusariosis in a febrile
2864 neutropenic patient with combined antifungal therapy of voriconazol plus amphotericin B
2865 deoxycholate]. *Rev Chilena Infectol* 2018; **35**(4): 448-52.

2866 237. Ong HS, Fung SSM, Macleod D, Dart JKG, Tuft SJ, Burton MJ. Altered Patterns of Fungal Keratitis
2867 at a London Ophthalmic Referral Hospital: An Eight-Year Retrospective Observational Study. *Am J*
2868 *Ophthalmol* 2016; **168**: 227-36.

2869 238. Palmore TN, Shea YR, Childs RW, Sherry RM, Walsh TJ. Fusarium proliferatum soft tissue
2870 infection at the site of a puncture by a plant: recovery, isolation, and direct molecular identification. *J*
2871 *Clin Microbiol* 2010; **48**(1): 338-42.

2872 239. Pang KA, Godet C, Fekkar A, et al. Breakthrough invasive mould infections in patients treated
2873 with caspofungin. *J Infect* 2012; **64**(4): 424-9.

2874 240. Patterson TF, Mackool BT, Gilman MD, Piris A. Case records of the Massachusetts General
2875 Hospital. Case 22-2009. A 59-year-old man with skin and pulmonary lesions after chemotherapy for
2876 leukemia [corrected]. *N Engl J Med* 2009; **361**(3): 287-96.

2877 241. Pellegrino F, Carrasco MA. Argon laser phototherapy in the treatment of refractory fungal
2878 keratitis. *Cornea* 2013; **32**(1): 95-7.

2879 242. Peponis V, Rosenberg P, Chalkiadakis SE, Insler M, Amariotakis A. Fungal scleral keratitis and
2880 endophthalmitis following pterygium excision. *Eur J Ophthalmol* 2009; **19**(3): 478-80.

2881 243. Pereira GH, de Angelis DA, Brasil RA, et al. Disseminated amphotericin-resistant fusariosis in
2882 acute leukemia patients: report of two cases. *Mycopathologia* 2013; **175**(1-2): 107-14.

2883 244. Perini GF, Camargo LF, Lottenberg CL, Hamerschlak N. Disseminated fusariosis with
2884 endophthalmitis in a patient with hematologic malignancy. *Einstein (Sao Paulo)* 2013; **11**(4): 545-6.

2885 245. Peterson A, Pham MH, Lee B, et al. Intracranial fusarium fungal abscess in an immunocompetent
2886 patient: case report and review of the literature. *J Neurol Surg Rep* 2014; **75**(2): e241-5.

2887 246. Phikulsod P, Suwannawiboon B, Chayakulkeeree M. Invasive Fungal Infection among Febrile
2888 Patients with Chemotherapy-Induced Neutropenia in Thailand. *Southeast Asian J Trop Med Public Health*
2889 2017; **48**(1): 159-69.

2890 247. Posteraro B, De Pascale G, Tumbarello M, et al. Early diagnosis of candidemia in intensive care
2891 unit patients with sepsis: a prospective comparison of (1-->3)-beta-D-glucan assay, Candida score, and
2892 colonization index. *Crit Care* 2011; **15**(5): R249.

2893 248. Punia RS, Kundu R, Chander J, Arya SK, Handa U, Mohan H. Spectrum of fungal keratitis:
2894 clinicopathologic study of 44 cases. *Int J Ophthalmol* 2014; **7**(1): 114-7.

2895 249. Rajmane VS, Rajmane ST, Patil VC, Patil AB, Mohite ST. Maxillary rhinosinusitis due to Fusarium
2896 species leading to cavernous sinus thrombosis. *J Mycol Med* 2013; **23**(1): 53-6.

2897 250. Rawat A, Vignesh P, Sharma A, et al. Infection Profile in Chronic Granulomatous Disease: a 23-
2898 Year Experience from a Tertiary Care Center in North India. *J Clin Immunol* 2017; **37**(3): 319-28.

2899 251. Refojo N, Minervini P, Hevia AI, et al. Keratitis caused by moulds in Santa Lucia Ophthalmology
2900 Hospital in Buenos Aires, Argentina. *Rev Iberoam Micol* 2016; **33**(1): 1-6.

2901 252. Relimpio-Lopez MI, Gessa-Sorroche M, Garrido-Hermosilla AM, et al. Extreme Surgical
2902 Maneuvers in Fungal Endophthalmitis. *Ophthalmologica* 2018; **239**(4): 233.

2903 253. Richetta AG, Lichtener M, Mattozzi C, et al. Fusariosis and skin T cell lymphoma: concomitant
2904 more than a differential diagnosis. *Clin Ter* 2010; **161**(3): 265-7.

2905 254. Ricna D, Lengerova M, Palackova M, et al. Disseminated fusariosis by Fusarium proliferatum in a
2906 patient with aplastic anaemia receiving primary posaconazole prophylaxis - case report and review of
2907 the literature. *Mycoses* 2016; **59**(1): 48-55.

- 2908 255. Rieger KE, Ridky TW, Sundram UN. Skin nodules in a patient with acute myeloid leukemia and
 2909 neurological deterioration--quiz case. Disseminated fusariosis. *Arch Dermatol* 2010; **146**(9): 1037-42.
- 2910 256. Rizzello I, Castagnetti F, Toschi PG, et al. Successful treatment of bilateral endogenous *Fusarium*
 2911 *solani* endophthalmitis in a patient with acute lymphocytic leukaemia. *Mycoses* 2018; **61**(1): 53-60.
- 2912 257. Romano C, Caposciutti P, Ghilardi A, Miracco C, Fimiani M. A case of primary localized cutaneous
 2913 infection due to *Fusarium oxysporum*. *Mycopathologia* 2010; **170**(1): 39-46.
- 2914 258. Rosa PD, Sheid K, Locatelli C, Marinho D, Goldani L. *Fusarium solani* keratitis: role of antifungal
 2915 susceptibility testing and identification to the species level for proper management. *Braz J Infect Dis*
 2916 2019; **23**(3): 197-9.
- 2917 259. Rosanova MT, Brizuela M, Villasboas M, et al. *Fusarium* spp infections in a pediatric burn unit:
 2918 nine years of experience. *Braz J Infect Dis* 2016; **20**(4): 389-92.
- 2919 260. Rossetto JD, Cavuoto KM, Osigian CJ, et al. Paediatric infectious keratitis: a case series of 107
 2920 children presenting to a tertiary referral centre. *Br J Ophthalmol* 2017; **101**(11): 1488-92.
- 2921 261. Roth M, Daas L, Renner-Wilde A, et al. [The German keratomycosis registry : Initial results of a
 2922 multicenter survey]. *Ophthalmologie* 2019; **116**(10): 957-66.
- 2923 262. Ruangritchankul K, Chindamporn A, Worasilchai N, Poumsuk U, Keelawat S, Bychkov A. Invasive
 2924 fungal disease in university hospital: a PCR-based study of autopsy cases. *Int J Clin Exp Pathol* 2015;
 2925 **8**(11): 14840-52.
- 2926 263. Schwartz KL, Sheffield H, Richardson SE, Sung L, Morris SK. Invasive Fusariosis: A Single Pediatric
 2927 Center 15-Year Experience. *Journal of the Pediatric Infectious Diseases Society* 2015; **4**(2): 163-70.
- 2928 264. Salehi E, Hedayati MT, Zoll J, et al. Discrimination of Aspergillosis, Mucormycosis, Fusariosis, and
 2929 Scedosporiosis in Formalin-Fixed Paraffin-Embedded Tissue Specimens by Use of Multiple Real-Time
 2930 Quantitative PCR Assays. *J Clin Microbiol* 2016; **54**(11): 2798-803.
- 2931 265. Sassi C, Stanzani M, Lewis RE, et al. Radiologic findings of *Fusarium* pneumonia in neutropenic
 2932 patients. *Mycoses* 2017; **60**(2): 73-8.
- 2933 266. Satpathy G, Nayak N, Wadhvani M, et al. Clinicomicrobiological profile of endophthalmitis: A 10
 2934 year experience in a Tertiary Care Center in North India. *Indian J Pathol Microbiol* 2017; **60**(2): 214-20.
- 2935 267. Schaal JV, Leclerc T, Soler C, et al. Epidemiology of filamentous fungal infections in burned
 2936 patients: A French retrospective study. *Burns* 2015; **41**(4): 853-63.
- 2937 268. Scheel CM, Hurst SF, Barreiros G, Akiti T, Nucci M, Balajee SA. Molecular analyses of *Fusarium*
 2938 isolates recovered from a cluster of invasive mold infections in a Brazilian hospital. *BMC Infect Dis* 2013;
 2939 **13**: 49.
- 2940 269. Schlaen A, Ingolotti M, Lorenzon P, et al. *Fusarium Solani* Subretinal Abscess in a Patient with
 2941 Acute Myeloid Leukemia. *Retin Cases Brief Rep* 2018; **12**(3): 181-3.
- 2942 270. Seban RD, Bonardel G, Guernou M, Lussato D, Queneau M. The Use of FDG PET-CT Imaging for
 2943 the Assessment of Early Antifungal Treatment Response in Disseminated Fusariosis. *Clin Nucl Med* 2017;
 2944 **42**(7): 569-70.
- 2945 271. Sganga G, Bianco G, Fiori B, et al. Surveillance of bacterial and fungal infections in the
 2946 postoperative period following liver transplantation: a series from 2005-2011. *Transplant Proc* 2013;
 2947 **45**(7): 2718-21.
- 2948 272. Sganga G, Bianco G, Frongillo F, Lirosi MC, Nure E, Agnes S. Fungal infections after liver
 2949 transplantation: incidence and outcome. *Transplant Proc* 2014; **46**(7): 2314-8.
- 2950 273. Shah PJ, Bergman S, Vegi S, Sundareshan V. *Fusarium* peritonitis successfully managed with
 2951 posaconazole and catheter removal. *Perit Dial Int* 2014; **34**(5): 566-8.
- 2952 274. Sharma N, Agarwal P, Sinha R, Titiyal JS, Velpandian T, Vajpayee RB. Evaluation of intrastromal
 2953 voriconazole injection in recalcitrant deep fungal keratitis: case series. *Br J Ophthalmol* 2011; **95**(12):
 2954 1735-7.
- 2955 275. Sheela S, Ito S, Strich JR, et al. Successful salvage chemotherapy and allogeneic transplantation
 2956 of an acute myeloid leukemia patient with disseminated *Fusarium solani* infection. *Leuk Res Rep* 2017; **8**:
 2957 4-6.
- 2958 276. Shigeyasu C, Yamada M, Aoki K, et al. Metagenomic analysis for detecting *Fusarium solani* in a
 2959 case of fungal keratitis. *J Infect Chemother* 2018; **24**(8): 664-8.

- 2960 277. Siatiri H, Daneshgar F, Siatiri N, Khodabande A. The effects of intrastromal voriconazole injection
2961 and topical voriconazole in the treatment of recalcitrant Fusarium keratitis. *Cornea* 2011; **30**(8): 872-5.
- 2962 278. Sidhu S, Chander J, Singh K. Perinephric abscess caused by Fusarium chlamyosporum in an
2963 immunocompetent child: case report and identification of the morphologically atypical fungal strain.
2964 *Indian J Pathol Microbiol* 2013; **56**(3): 312-4.
- 2965 279. Silva GM, Silveira AR, Betania CA, Macedo DP, Neves RP. Disseminated fusariosis secondary to
2966 neuroblastoma with fatal outcome. *Mycopathologia* 2013; **176**(3-4): 233-6.
- 2967 280. Simon L, Gastaud L, Martiano D, Bailleux C, Hasseine L, Gari-Toussaint M. *J Mycol Med* 2018;
2968 **28**(2): 403-6.
- 2969 281. Singhal KV, Saoji V, Saoji SV. Fusarium skin infection: a case report. *Dermatol Online J* 2012;
2970 **18**(4): 6.
- 2971 282. Spriet I, Delaere L, Lagrou K, Peetermans WE, Maertens J, Willems L. Intraocular penetration of
2972 voriconazole and caspofungin in a patient with fungal endophthalmitis. *J Antimicrob Chemother* 2009;
2973 **64**(4): 877-8.
- 2974 283. Sradhanjali S, Yein B, Sharma S, Das S. In vitro synergy of natamycin and voriconazole against
2975 clinical isolates of Fusarium, Candida, Aspergillus and Curvularia spp. *Br J Ophthalmol* 2018; **102**(1): 142-
2976 5.
- 2977 284. Sreedharan Namboothiri P, Nair SN, Vijayan K, Visweswaran V. Disseminated Fusarium
2978 oxysporum neurospinal infection. *Indian J Orthop* 2014; **48**(2): 220-2.
- 2979 285. Stempel JM, Hammond SP, Sutton DA, Weiser LM, Marty FM. Invasive Fusariosis in the
2980 Voriconazole Era: Single-Center 13-Year Experience. *Open Forum Infect Dis* 2015; **2**(3): ofv099.
- 2981 286. Sun S, Zhao G, Sun X, Wang Q, Yu B. [Etiology and pathogens of fungal endophthalmitis].
2982 *Zhonghua Yan Ke Za Zhi* 2014; **50**(11): 808-13.
- 2983 287. Taj-Aldeen SJ, Salah H, Al-Hatmi AM, et al. In vitro resistance of clinical Fusarium species to
2984 amphotericin B and voriconazole using the EUCAST antifungal susceptibility method. *Diagn Microbiol*
2985 *Infect Dis* 2016; **85**(4): 438-43.
- 2986 288. Takahashi T, Kida J, Matsumoto K, et al. [Picture in clinical hematology no. 71: Case of fungemia
2987 caused by Fusarium complicated with intractable acute myeloid leukemia]. *Rinsho Ketsueki* 2014; **55**(3):
2988 287.
- 2989 289. Takenaka M. A Case of Cutaneous Fusariosis of the Scrotum as a Complication of Acute Myeloid
2990 Leukemia. *Med Mycol J* 2016; **57**(2): J65-70.
- 2991 290. Tan R, Ng KP, Gan GG, Na SL. Fusarium sp. infection in a patient with Acute Lymphoblastic
2992 Leukaemia. *Med J Malaysia* 2013; **68**(6): 479-80.
- 2993 291. Tanase A, Colita A, Ianosi G, et al. Rare case of disseminated fusariosis in a young patient with
2994 graft vs. host disease following an allogeneic transplant. *Exp Ther Med* 2016; **12**(4): 2078-82.
- 2995 292. Tascini C, Urbani L, Doria R, et al. Breakthrough Fusarium spp fungemia during caspofungin
2996 therapy in an ABO-incompatible orthotopic liver transplant patient. *J Chemother* 2009; **21**(2): 236-8.
- 2997 293. Taylan Sekeroglu H, Erdem E, Yagmur M, et al. Successful medical management of recalcitrant
2998 Fusarium solani keratitis: molecular identification and susceptibility patterns. *Mycopathologia* 2012;
2999 **174**(3): 233-7.
- 3000 294. Terada M, Fujita J, Watanabe S, et al. Olecranon bursa with Fusarium solani infection in an
3001 otherwise healthy patient. *Mycoses* 2011; **54**(6): e853-5.
- 3002 295. Terasaki JM, Shah SK, Schnadig VJ, Valentine VG. Airway complication contributing to
3003 disseminated fusariosis after lung transplantation. *Transpl Infect Dis* 2014; **16**(4): 621-4.
- 3004 296. Tezcan G, Ozhak-Baysan B, Alastruey-Izquierdo A, et al. Disseminated fusariosis caused by
3005 Fusarium verticillioides in an acute lymphoblastic leukemia patient after allogeneic hematopoietic stem
3006 cell transplantation. *Journal of clinical microbiology* 2009; **47**(1): 278-81.
- 3007 297. Tupaki-Sreepurna A, Thanneru V, Natarajan S, et al. Phylogenetic Diversity and In Vitro
3008 Susceptibility Profiles of Human Pathogenic Members of the Fusarium fujikuroi Species Complex Isolated
3009 from South India. *Mycopathologia* 2018; **183**(3): 529-40.

3010 298. Uemura S, Tamura A, Yamamoto N, et al. Successful Combination Therapy of Liposomal
3011 Amphotericin B and Caspofungin for Disseminated Fusariosis in a Pediatric Patient With Acute
3012 Lymphoblastic Leukemia. *The Pediatric infectious disease journal* 2018; **37**(10): e251-e3.
3013 299. Unal A, Kocyigit I, Sipahioglu MH, Tokgoz B, Oymak O, Utas C. Fungal peritonitis in peritoneal
3014 dialysis: an analysis of 21 cases. *Int Urol Nephrol* 2011; **43**(1): 211-3.
3015 300. Tsuji G, Takei K, Takahara M, et al. Cutaneous *Pseudallescheria boydii*/Scedosporium
3016 apiospermum complex infection in immunocompromised patients: A report of two cases. *J Dermatol*
3017 2017; **44**(9): 1067-8.
3018 301. Vallerini D, Forghieri F, Lagreca I, et al. Detection of Fusarium-specific T cells in hematologic
3019 patients with invasive fusariosis. *J Infect* 2017; **74**(3): 314-8.
3020 302. Varon AG, Nouer SA, Barreiros G, Trope BM, Akiti T, Nucci M. Antimold Prophylaxis May Reduce
3021 the Risk of Invasive Fusariosis in Hematologic Patients with Superficial Skin Lesions with Positive Culture
3022 for Fusarium. *Antimicrobial agents and chemotherapy* 2016; **60**(12): 7290-4.
3023 303. Vasantha Ruban V, Geraldine P, Kaliamurthy J, Jesudasan CA, Thomas PA. Keratitis due to
3024 *Fusarium langsethiae*: clinical profile, molecular identification, and susceptibility to antifungals.
3025 *Mycopathologia* 2015; **179**(5-6): 453-8.
3026 304. Vesikari T, Becker T, Vertruyen AF, et al. A Phase III Randomized, Double-blind, Clinical Trial of
3027 an Investigational Hexavalent Vaccine Given at Two, Three, Four and Twelve Months. *Pediatr Infect Dis J*
3028 2017; **36**(2): 209-15.
3029 305. Vinh D, Yim M, Dutta A, Jones JK, Zhang W, Sitton M. Pediatric invasive fungal rhinosinusitis: An
3030 investigation of 17 patients. *Int J Pediatr Otorhinolaryngol* 2017; **99**: 111-6.
3031 306. Warkentien T, Rodriguez C, Lloyd B, et al. Invasive mold infections following combat-related
3032 injuries. *Clin Infect Dis* 2012; **55**(11): 1441-9.
3033 307. Warkentien TE, Shaikh F, Weintrob AC, et al. Impact of Mucorales and Other Invasive Molds on
3034 Clinical Outcomes of Polymicrobial Traumatic Wound Infections. *J Clin Microbiol* 2015; **53**(7): 2262-70.
3035 308. West EK, Mehta M, Patil VV, Chamberland R. Skin lesion in a patient after hematopoietic stem
3036 cell transplant. *Transpl Infect Dis* 2017; **19**(5).
3037 309. Wu CH, Lu PL, Hsiao HH, et al. Breakthrough *Fusarium solani* infection in a patient with acute
3038 myeloid leukemia receiving posaconazole prophylaxis. *Ann Hematol* 2014; **93**(6): 1079-81.
3039 310. Xu LJ, Song XS, Zhao J, Sun SY, Xie LX. Hypopyon in patients with fungal keratitis. *Chin Med J*
3040 *(Engl)* 2012; **125**(3): 470-5.
3041 311. Yan X, Yu C, Shi Z, Wang S, Zhang F. Nasal cutaneous infection in a healthy boy caused by
3042 *Fusarium moniliforme*. *Pediatr Dermatol* 2013; **30**(4): e43-e5.
3043 312. Yang YS. Results of extensive surgical treatment of seven consecutive cases of postoperative
3044 fungal endophthalmitis. *Korean J Ophthalmol* 2009; **23**(3): 159-63.
3045 313. Yoshida M, Kiyota N, Maruyama K, et al. Endogenous *Fusarium* Endophthalmitis During
3046 Treatment for Acute Myeloid Leukemia, Successfully Treated with 25-Gauge Vitrectomy and Antifungal
3047 Medications. *Mycopathologia* 2018; **183**(2): 451-7.
3048 314. Yu J, Chen Y, Fang J, Zhang K. Successful treatment of disseminated fusariosis in a patient with
3049 acute lymphoblastic leukemia: A case report and literature review. *Medicine (Baltimore)* 2019; **98**(26):
3050 e16246.
3051 315. Zaigraykina N, Tomkins O, Garzosi HJ, Potasman I. *Fusarium* keratitis acquired during travel to
3052 Namibia. *J Travel Med* 2010; **17**(3): 209-11.
3053 316. Zbiba W, Baba A, Bouayed E, Abdessalem N, Daldoul A. A 5-year retrospective review of fungal
3054 keratitis in the region of Cap Bon. *J Fr Ophtalmol* 2016; **39**(10): 843-8.
3055 317. Zhang CZ, Fung MA, Eisen DB. Disseminated fusariosis presenting as panniculitis-like lesions on
3056 the legs of a neutropenic girl with acute lymphoblastic leukemia. *Dermatol Online J* 2009; **15**(10): 5.
3057 318. Zhang M, Xu GZ, Jiang R, et al. Pediatric Infectious Endophthalmitis: A 271-case Retrospective
3058 Study at a Single Center in China. *Chin Med J (Engl)* 2016; **129**(24): 2936-43.
3059 319. Zou Y, Bi Y, Bu H, He Y, Guo L, Shi D. Infective meningitis caused by *Phialemonium curvatum*. *J*
3060 *Clin Microbiol* 2014; **52**(8): 3111-3.

3061 320. Zribi J, Boudaya S, Sallemi A, et al. [Atypical cutaneous Fusarium infection in an
3062 immunocompetent patient]. *Ann Dermatol Venereol* 2010; **137**(10): 630-4.

3063 321. Dadax. Countries in the world by population (2018). 2018.
3064 <http://www.worldometers.info/world-population/population-by-country/> (accessed June 20 2018).

3065 322. Bertero A, Moretti A, Spicer LJ, Caloni F. Fusarium Molds and Mycotoxins: Potential Species-
3066 Specific Effects. *Toxins (Basel)* 2018; **10**(6): 244.

3067 323. Hennequin C, Ranaivoarimalala C, Chouaki T, et al. Comparison of aerobic standard medium
3068 with specific fungal medium for detecting fusarium spp in blood cultures. *Eur J Clin Microbiol Infect Dis*
3069 2002; **21**(10): 748-50.

3070 324. Liu K, Howell DN, Perfect JR, Schell WA. Morphologic criteria for the preliminary identification of
3071 Fusarium, Paecilomyces, and Acremonium species by histopathology. *Am J Clin Pathol* 1998; **109**(1): 45-
3072 54.

3073 325. Hayden RT, Isotalo PA, Parrett T, et al. In situ hybridization for the differentiation of Aspergillus,
3074 Fusarium, and Pseudallescheria species in tissue section. *Diagn Mol Pathol* 2003; **12**(1): 21-6.

3075 326. Walsh TJ, McCarthy MW. The expanding use of matrix-assisted laser desorption/ionization-time
3076 of flight mass spectroscopy in the diagnosis of patients with mycotic diseases. *Expert Rev Mol Diagn*
3077 2019; **19**(3): 241-8.

3078 327. Sanguinetti M, Posteraro B. Identification of Molds by Matrix-Assisted Laser Desorption
3079 Ionization-Time of Flight Mass Spectrometry. *Journal of clinical microbiology* 2017; **55**(2): 369-79.

3080 328. Chalupova J, Raus M, Sedlarova M, Sebela M. Identification of fungal microorganisms by MALDI-
3081 TOF mass spectrometry. *Biotechnol Adv* 2014; **32**(1): 230-41.

3082 329. Triest D, Stubbe D, De Cremer K, et al. Use of matrix-assisted laser desorption ionization-time of
3083 flight mass spectrometry for identification of molds of the Fusarium genus. *J Clin Microbiol* 2015; **53**(2):
3084 465-76.

3085 330. Dannaoui E, Espinel-Ingroff A. Antifungal Susceptibility Testing by Concentration Gradient Strip
3086 Etest Method for Fungal Isolates: A Review. *J Fungi (Basel)* 2019; **5**(4).

3087 331. Espinel-Ingroff A, Colombo AL, Cordoba S, et al. International Evaluation of MIC Distributions
3088 and Epidemiological Cutoff Value (ECV) Definitions for Fusarium Species Identified by Molecular
3089 Methods for the CLSI Broth Microdilution Method. *Antimicrobial agents and chemotherapy* 2016; **60**(2):
3090 1079-84.

3091 332. Lamoth F, Damonti L, Alexander BD. Role of Antifungal Susceptibility Testing in Non-Aspergillus
3092 Invasive Mold Infections. *J Clin Microbiol* 2016; **54**(6): 1638-40.

3093 333. Nucci M, Barreiros G, Reis H, Paixao M, Akiti T, Nouer SA. Performance of 1,3-beta-D-glucan in
3094 the diagnosis and monitoring of invasive fusariosis. *Mycoses* 2019; **62**(7): 570-5.

3095 334. Nucci F, Nouer SA, Capone D, Nucci M. Invasive mould disease in haematologic patients:
3096 comparison between fusariosis and aspergillosis. *Clinical microbiology and infection : the official
3097 publication of the European Society of Clinical Microbiology and Infectious Diseases* 2018; **24**(10):
3098 1105.e1-.e4.

3099 335. Thornton CR. Development of an immunochromatographic lateral-flow device for rapid
3100 serodiagnosis of invasive aspergillosis. *Clinical and vaccine immunology : CVI* 2008; **15**(7): 1095-105.

3101 336. Hoenigl M, Prattes J, Spiess B, et al. Performance of Galactomannan, Beta-D-Glucan, Aspergillus
3102 Lateral-Flow Device, Conventional Culture and PCR tests for Diagnosis of Invasive Pulmonary
3103 Aspergillosis in Bronchoalveolar Lavage Fluid. *J Clin Microbiol* 2014.

3104 337. Boch T, Reinwald M, Postina P, et al. Identification of invasive fungal diseases in
3105 immunocompromised patients by combining an Aspergillus specific PCR with a multifungal DNA-
3106 microarray from primary clinical samples. *Mycoses* 2015; **58**(12): 735-45.

3107 338. Lau A, Sorrell TC, Chen S, Stanley K, Iredell J, Halliday C. Multiplex tandem PCR: a novel platform
3108 for rapid detection and identification of fungal pathogens from blood culture specimens. *J Clin Microbiol*
3109 2008; **46**(9): 3021-7.

3110 339. Landlinger C, Preuner S, Willinger B, et al. Species-specific identification of a wide range of
3111 clinically relevant fungal pathogens by use of Luminex xMAP technology. *J Clin Microbiol* 2009; **47**(4):
3112 1063-73.

3113 340. Landlinger C, Baskova L, Preuner S, Willinger B, Buchta V, Lion T. Identification of fungal species
3114 by fragment length analysis of the internally transcribed spacer 2 region. *Eur J Clin Microbiol Infect Dis*
3115 2009; **28**(6): 613-22.

3116 341. Lau A, Chen S, Sorrell T, et al. Development and clinical application of a panfungal PCR assay to
3117 detect and identify fungal DNA in tissue specimens. *J Clin Microbiol* 2007; **45**(2): 380-5.

3118 342. de Souza M, Matsuzawa T, Sakai K, et al. Comparison of DNA Microarray, Loop-Mediated
3119 Isothermal Amplification (LAMP) and Real-Time PCR with DNA Sequencing for Identification of *Fusarium*
3120 spp. Obtained from Patients with Hematologic Malignancies. *Mycopathologia* 2017; **182**(7-8): 625-32.

3121 343. Landlinger C, Preuner S, Baskova L, et al. Diagnosis of invasive fungal infections by a real-time
3122 panfungal PCR assay in immunocompromised pediatric patients. *Leukemia* 2010; **24**(12): 2032-8.

3123 344. Spiess B, Seifarth W, Hummel M, et al. DNA microarray-based detection and identification of
3124 fungal pathogens in clinical samples from neutropenic patients. *Journal of clinical microbiology* 2007;
3125 **45**(11): 3743-53.

3126 345. Hennequin C, Abachin E, Symoens F, et al. Identification of *Fusarium* species involved in human
3127 infections by 28S rRNA gene sequencing. *Journal of clinical microbiology* 1999; **37**(11): 3586-9.

3128 346. Hue FX, Huerre M, Rouffault MA, de Bievre C. Specific detection of *Fusarium* species in blood
3129 and tissues by a PCR technique. *Journal of clinical microbiology* 1999; **37**(8): 2434-8.

3130 347. Herkert PF, Al-Hatmi AMS, de Oliveira Salvador GL, et al. Molecular Characterization and
3131 Antifungal Susceptibility of Clinical *Fusarium* Species From Brazil. *Frontiers in microbiology* 2019; **10**:
3132 737.

3133 348. Gaviria-Rivera A, Giraldo-López A, Santa-Cardona C, Cano-Restrepo L. Molecular identification of
3134 clinical isolates of *Fusarium* in Colombia. *Rev Salud Publica (Bogota)* 2018; **20**(1): 94-102.

3135 349. Dallé Rosa P, Ramirez-Castrillon M, Valente P, Meneghello Fuentesfria A, Van Diepeningen AD,
3136 Goldani LZ. *Fusarium* *riograndense* sp. nov., a new species in the *Fusarium solani* species complex
3137 causing fungal rhinosinusitis. *Journal de mycologie medicale* 2018; **28**(1): 29-35.

3138 350. Al-Hatmi AM, Bonifaz A, Tirado-Sanchez A, Meis JF, de Hoog GS, Ahmed SA. *Fusarium* species
3139 causing eumycetoma: Report of two cases and comprehensive review of the literature. *Mycoses* 2017;
3140 **60**(3): 204-12.

3141 351. Healy M, Reece K, Walton D, et al. Use of the Diversi Lab System for species and strain
3142 differentiation of *Fusarium* species isolates. *J Clin Microbiol* 2005; **43**(10): 5278-80.

3143 352. Thomas B, Contet Audonneau N, Machouart M, Debourogogne A. Molecular identification of
3144 *Fusarium* species complexes: Which gene and which database to choose in clinical practice? *J Mycol*
3145 *Med* 2019; **29**(1): 56-8.

3146 353. O'Donnell K, Sutton DA, Rinaldi MG, et al. Genetic diversity of human pathogenic members of
3147 the *Fusarium oxysporum* complex inferred from multilocus DNA sequence data and amplified fragment
3148 length polymorphism analyses: evidence for the recent dispersion of a geographically widespread clonal
3149 lineage and nosocomial origin. *J Clin Microbiol* 2004; **42**(11): 5109-20.

3150 354. Nucci F, Nouér SA, Capone D, Anaissie E, Nucci M. Fusariosis. *Semin Respir Crit Care Med* 2015;
3151 **36**(5): 706-14.

3152 355. Marom EM, Holmes AM, Bruzzi JF, Truong MT, O'Sullivan PJ, Kontoyiannis DP. Imaging of
3153 pulmonary fusariosis in patients with hematologic malignancies. *AJR Am J Roentgenol* 2008; **190**(6):
3154 1605-9.

3155 356. Ahmad S, Khan ZU, Theyyathel AM. Development of a nested PCR assay for the detection of
3156 *Fusarium solani* DNA and its evaluation in the diagnosis of invasive fusariosis using an experimental
3157 mouse model. *Mycoses* 2010; **53**(1): 40-7.

3158 357. Bernal-Martinez L, Buitrago MJ, Castelli MV, Rodriguez-Tudela JL, Cuenca-Estrella M. Detection
3159 of invasive infection caused by *Fusarium solani* and non-*Fusarium solani* species using a duplex
3160 quantitative PCR-based assay in a murine model of fusariosis. *Medical mycology* 2012; **50**(3): 270-5.

3161 358. Dolton MJ, Ray JE, Chen SC, Ng K, Pont LG, McLachlan AJ. Voriconazole Pharmacokinetics and
3162 Therapeutic Drug Monitoring: A Multi-Center Study. *Antimicrobial agents and chemotherapy* 2012.

3163 359. Lenczuk D, Zinke-Cerwenka W, Greinix H, et al. Antifungal prophylaxis with Posaconazole
3164 delayed-release tablet and oral suspension in a Real-life setting: plasma levels, efficacy and tolerability.
3165 *Antimicrobial agents and chemotherapy* 2018.

3166 360. Dolton MJ, Ray JE, Marriott D, McLachlan AJ. Posaconazole exposure-response relationship:
3167 evaluating the utility of therapeutic drug monitoring. *Antimicrobial Agents and Chemotherapy* 2012;
3168 **56**(6): 2806-13.

3169 361. Jenks JD, Salzer HJ, Prattes J, Krause R, Buchheidt D, Hoenigl M. Spotlight on isavuconazole in
3170 the treatment of invasive aspergillosis and mucormycosis: design, development, and place in therapy.
3171 *Drug design, development and therapy* 2018; **12**: 1033-44.

3172 362. Alastruey-Izquierdo A, Cadranel J, Flick H, et al. Treatment of Chronic Pulmonary Aspergillosis:
3173 Current Standards and Future Perspectives. *Respiration; international review of thoracic diseases* 2018:
3174 1-12.

3175 363. Bekersky I, Fielding RM, Dressler DE, Lee JW, Buell DN, Walsh TJ. Pharmacokinetics, excretion,
3176 and mass balance of liposomal amphotericin B (AmBisome) and amphotericin B deoxycholate in
3177 humans. *Antimicrobial agents and chemotherapy* 2002; **46**(3): 828-33.

3178 364. Alexander BD, Wingard JR. Study of renal safety in amphotericin B lipid complex-treated
3179 patients. *Clinical infectious diseases : an official publication of the Infectious Diseases Society of America*
3180 2005; **40 Suppl 6**: S414-21.

3181 365. Stone NR, Bicanic T, Salim R, Hope W. Liposomal Amphotericin B (AmBisome((R))): A Review of
3182 the Pharmacokinetics, Pharmacodynamics, Clinical Experience and Future Directions. *Drugs* 2016; **76**(4):
3183 485-500.

3184 366. Tissot F, Agrawal S, Pagano L, et al. ECIL-6 guidelines for the treatment of invasive candidiasis,
3185 aspergillosis and mucormycosis in leukemia and hematopoietic stem cell transplant patients.
3186 *Haematologica* 2017; **102**(3): 433-44.

3187 367. Jenks JD, Seidel D, Cornely OA, et al. Voriconazole plus terbinafine combination antifungal
3188 therapy for invasive *Lomentospora prolificans* infections: analysis of 41 patients from the FungiScope®
3189 registry 2008-2019. *Clinical microbiology and infection : the official publication of the European Society*
3190 *of Clinical Microbiology and Infectious Diseases* 2020: S1198-743X(20)30037-9.

3191 368. Dolton MJ, Perera V, Pont LG, McLachlan AJ. Terbinafine in Combination with Other Antifungal
3192 Agents for Treatment of Resistant or Refractory Mycoses: Investigating Optimal Dosing Regimens Using
3193 a Physiologically Based Pharmacokinetic Model. *Antimicrobial agents and chemotherapy* 2014; **58**(1):
3194 48.

3195 369. Smith J, Andes D. Therapeutic drug monitoring of antifungals: pharmacokinetic and
3196 pharmacodynamic considerations. *Therapeutic drug monitoring* 2008; **30**(2): 167-72.

3197 370. Cornely OA, Hoenigl M, Lass-Flörl C, et al. Defining breakthrough invasive fungal infection-
3198 Position paper of the mycoses study group education and research consortium and the European
3199 Confederation of Medical Mycology. *Mycoses* 2019; **62**(9): 716-29.

3200 371. Cudillo L, Girmenia C, Santilli S, et al. Breakthrough fusariosis in a patient with acute
3201 lymphoblastic leukemia receiving voriconazole prophylaxis. *Clinical infectious diseases : an official*
3202 *publication of the Infectious Diseases Society of America* 2005; **40**(8): 1212-3.

3203 372. Bowen CD, Tallman GB, Hakki M, Lewis JS. Isavuconazole to prevent invasive fungal infection in
3204 immunocompromised adults: Initial experience at an academic medical centre. *Mycoses* 2019; **62**(8):
3205 665-72.

3206 373. Fontana L, Perlin DS, Zhao Y, et al. Isavuconazole prophylaxis in patients with hematologic
3207 malignancies and hematopoietic-cell transplant recipients. *Clinical infectious diseases : an official*
3208 *publication of the Infectious Diseases Society of America* 2019.

3209 374. Garnica M, Sinhorelo A, Madeira L, Portugal R, Nucci M. Diagnostic-driven antifungal therapy in
3210 neutropenic patients using the D-index and serial serum galactomannan testing. *Braz J Infect Dis* 2016;
3211 **20**(4): 354-9.

3212 375. Fleming RV, Kantarjian HM, Husni R, et al. Comparison of Amphotericin B Lipid Complex (ABLC)
3213 vs. AmBisome in the Treatment of Suspected or Documented Fungal Infections in Patients with
3214 Leukemia. *Leukemia & Lymphoma* 2001; **40**(5-6): 511-20.

3215 376. Perfect JR, Marr KA, Walsh TJ, et al. Voriconazole treatment for less-common, emerging, or
3216 refractory fungal infections. *Clinical infectious diseases : an official publication of the Infectious Diseases*
3217 *Society of America* 2003; **36**(9): 1122-31.

3218 377. Stanzani M, Tumietto F, Vianelli N, Bacarani M. Update on the treatment of disseminated
3219 fusariosis: Focus on voriconazole. *Ther Clin Risk Manag* 2007; **3**(6): 1165-73.

3220 378. Perfect JR. Treatment of non-Aspergillus moulds in immunocompromised patients, with
3221 amphotericin B lipid complex. *Clinical infectious diseases : an official publication of the Infectious*
3222 *Diseases Society of America* 2005; **40 Suppl 6**: S401-8.

3223 379. Musa MO, Al Eisa A, Halim M, et al. The spectrum of Fusarium infection in immunocompromised
3224 patients with haematological malignancies and in non-immunocompromised patients: a single
3225 institution experience over 10 years. *Br J Haematol* 2000; **108**(3): 544-8.

3226 380. Jensen TG, Gahrn-Hansen B, Arendrup M, Bruun B. Fusarium fungaemia in
3227 immunocompromised patients. *Clinical microbiology and infection : the official publication of the*
3228 *European Society of Clinical Microbiology and Infectious Diseases* 2004; **10**(6): 499-501.

3229 381. Cornely OA, Mullane KM, Ostrosky-Zeichner L, et al. Isavuconazole for treatment of rare invasive
3230 fungal diseases. *Mycoses* 2018.

3231 382. Herbrecht R, Kessler R, Kravanja C, Meyer MH, Waller J, Letscher-Bru V. Successful treatment of
3232 Fusarium proliferatum pneumonia with posaconazole in a lung transplant recipient. *J Heart Lung*
3233 *Transplant* 2004; **23**(12): 1451-4.

3234 383. Apostolidis J, Bouzani M, Platsouka E, et al. Resolution of fungemia due to Fusarium species in a
3235 patient with acute leukemia treated with caspofungin. *Clinical infectious diseases : an official publication*
3236 *of the Infectious Diseases Society of America* 2003; **36**(10): 1349-50.

3237 384. Jenks JD, Reed SL, Seidel D, et al. Rare mould infections caused by Mucorales, Lomentospora
3238 prolificans and Fusarium, in San Diego, CA: the role of antifungal combination therapy. *International*
3239 *journal of antimicrobial agents* 2018.

3240 385. Horn DL, Freifeld AG, Schuster MG, Azie NE, Franks B, Kauffman CA. Treatment and outcomes of
3241 invasive fusariosis: review of 65 cases from the PATH Alliance((R)) registry. *Mycoses* 2014; **57**(11): 652-8.

3242 386. Janum S, Afshari A. Central venous catheter (CVC) removal for patients of all ages with
3243 candidaemia. *Cochrane Database Syst Rev* 2016; **7**(7): CD011195-CD.

3244 387. Bose P, Parekh HD, Holter JL, Greenfield RA. Disseminated fusariosis occurring in two patients
3245 despite posaconazole prophylaxis. *Journal of clinical microbiology* 2011; **49**(4): 1674-5.

3246 388. Cudillo L, Tendas A, Picardi A, et al. Successful treatment of disseminated fusariosis with high
3247 dose liposomal amphotericin-B in a patient with acute lymphoblastic leukemia. *Annals of hematology*
3248 2006; **85**(2): 136-8.

3249 389. Campo M, Lewis RE, Kontoyiannis DP. Invasive fusariosis in patients with hematologic
3250 malignancies at a cancer center: 1998-2009. *The Journal of infection* 2010; **60**(5): 331-7.

3251 390. Rothe A, Seibold M, Hoppe T, et al. Combination therapy of disseminated Fusarium oxysporum
3252 infection with terbinafine and amphotericin B. *Annals of hematology* 2004; **83**(6): 394-7.

3253 391. Rezai KA, Elliott D, Plous O, Vazquez JA, Abrams GW. Disseminated Fusarium infection presenting
3254 as bilateral endogenous endophthalmitis in a patient with acute myeloid leukemia. *Arch Ophthalmol*
3255 2005; **123**(5): 702-3.

3256 392. Malavade SS, Mai M, Pavan P, Nasr G, Sandin R, Greene J. Endogenous Fusarium
3257 Endophthalmitis in Hematologic Malignancy: Short Case Series and Review of Literature. *Infectious*
3258 *Diseases in Clinical Practice* 2013; **21**(1): 6-11.

3259 393. Milligan AL, Gruener AM, Milligan ID, O'Hara GA, Stanford MR. Isolated endogenous Fusarium
3260 endophthalmitis in an immunocompetent adult after a thorn prick to the hand. *Am J Ophthalmol Case*
3261 *Rep* 2017; **6**: 45-7.

3262 394. Mithal K, Pathengay A, Bawdekar A, et al. Filamentous fungal endophthalmitis: results of
3263 combination therapy with intravitreal amphotericin B and voriconazole. *Clin Ophthalmol* 2015; **9**: 649-
3264 55.

3265 395. Buchta V, Feuermannova A, Vasa M, et al. Outbreak of fungal endophthalmitis due to Fusarium
3266 oxysporum following cataract surgery. *Mycopathologia* 2014; **177**(1-2): 115-21.

3267 396. Gungel H, Eren MH, Pinarci EY, et al. An outbreak of *Fusarium solani* endophthalmitis after
3268 cataract surgery in an eye training and research hospital in Istanbul. *Mycoses* 2011; **54**(6): e767-74.
3269 397. Cakir M, Imamoglu S, Cekic O, et al. An outbreak of early-onset endophthalmitis caused by
3270 *Fusarium* species following cataract surgery. *Curr Eye Res* 2009; **34**(11): 988-95.
3271 398. Ferrer C, Alio J, Rodriguez A, Andreu M, Colom F. Endophthalmitis caused by *Fusarium*
3272 *proliferatum*. *J Clin Microbiol* 2005; **43**(10): 5372-5.
3273 399. Troke P, Obenga G, Gaujoux T, et al. The efficacy of voriconazole in 24 ocular *Fusarium*
3274 infections. *Infection* 2013; **41**(1): 15-20.
3275 400. Comer GM, Stem MS, Saxe SJ. Successful salvage therapy of *Fusarium* endophthalmitis
3276 secondary to keratitis: an interventional case series. *Clinical ophthalmology (Auckland, NZ)* 2012; **6**: 721-
3277 6.
3278 401. Sponsel WE, Graybill JR, Nevarez HL, Dang D. Ocular and systemic posaconazole(SCH-56592)
3279 treatment of invasive *Fusarium solani* keratitis and endophthalmitis. *Br J Ophthalmol* 2002; **86**(7): 829-
3280 30.
3281 402. Stott KE, Hope WW. Therapeutic drug monitoring for invasive mould infections and disease:
3282 pharmacokinetic and pharmacodynamic considerations. *The Journal of antimicrobial chemotherapy*
3283 2017; **72**(suppl_1): i12-i8.
3284 403. Boutati EI, Anaissie EJ. *Fusarium*, a significant emerging pathogen in patients with hematologic
3285 malignancy: ten years' experience at a cancer center and implications for management. *Blood* 1997;
3286 **90**(3): 999-1008.
3287 404. Nucci M, Anaissie EJ, Queiroz-Telles F, et al. Outcome predictors of 84 patients with hematologic
3288 malignancies and *Fusarium* infection. *Cancer* 2003; **98**(2): 315-9.
3289 405. Almyroudis NG, Kontoyiannis DP, Sepkowitz KA, DePauw BE, Walsh TJ, Segal BH. Issues related
3290 to the design and interpretation of clinical trials of salvage therapy for invasive mold infection. *Clinical*
3291 *infectious diseases : an official publication of the Infectious Diseases Society of America* 2006; **43**(11):
3292 1449-55.
3293 406. Raad II, Graybill JR, Bustamante AB, et al. Safety of long-term oral posaconazole use in the
3294 treatment of refractory invasive fungal infections. *Clinical infectious diseases : an official publication of*
3295 *the Infectious Diseases Society of America* 2006; **42**(12): 1726-34.
3296 407. Marty FM, Cornely OA, Mullane KM, et al. Isavuconazole for treatment of invasive fungal
3297 diseases caused by more than one fungal species. *Mycoses* 2018; **61**(7): 485-97.
3298 408. Baden LR, Katz JT, Franck L, et al. Successful toxoplasmosis prophylaxis after orthotopic cardiac
3299 transplantation with trimethoprim-sulfamethoxazole. *Transplantation* 2003; **75**(3): 339-43.
3300 409. Neuburger S, Massenkeil G, Seibold M, et al. Successful salvage treatment of disseminated
3301 cutaneous fusariosis with liposomal amphotericin B and terbinafine after allogeneic stem cell
3302 transplantation. *Transplant infectious disease : an official journal of the Transplantation Society* 2008;
3303 **10**(4): 290-3.
3304 410. Tu EY, McCartney DL, Beatty RF, Springer KL, Levy J, Edward D. Successful treatment of resistant
3305 ocular fusariosis with posaconazole (SCH-56592). *American journal of ophthalmology* 2007; **143**(2): 222-
3306 7.
3307 411. Koehler P, Tacke D, Cornely OA. Bone and joint infections by Mucorales, *Scedosporium*,
3308 *Fusarium* and even rarer fungi. *Crit Rev Microbiol* 2016; **42**(1): 158-71.
3309 412. Lupinetti FM, Giller RH, Trigg ME. Operative treatment of *Fusarium* fungal infection of the lung.
3310 *Ann Thorac Surg* 1990; **49**(6): 991-2.
3311 413. Janum S, Afshari A. Central venous catheter (CVC) removal for patients of all ages with
3312 candidaemia. *Cochrane Database Syst Rev* 2016; **7**: Cd011195.
3313 414. Koehler P, Tacke D, Cornely OA. Bone and joint infections by Mucorales, *Scedosporium*,
3314 *Fusarium* and even rarer fungi. *Critical Reviews in Microbiology* 2016; **42**(1): 158-71.
3315 415. Alves da Costa Pertuiset PA, Logroño JFB. *Fusarium* Endophthalmitis following Cataract Surgery:
3316 Successful Treatment with Intravitreal and Systemic Voriconazole. *Case reports in ophthalmological*
3317 *medicine* 2016; **2016**: 4593042-.

3318 416. Milligan AL, Gruener AM, Milligan ID, O'Hara GA, Stanford MR. Isolated endogenous Fusarium
3319 endophthalmitis in an immunocompetent adult after a thorn prick to the hand. *American journal of*
3320 *ophthalmology case reports* 2016; **6**: 45-7.

3321 417. Litvinov N, da Silva MT, van der Heijden IM, et al. An outbreak of invasive fusariosis in a
3322 children's cancer hospital. *Clinical microbiology and infection : the official publication of the European*
3323 *Society of Clinical Microbiology and Infectious Diseases* 2015; **21**(3): 268.e1-7.

3324 418. Hassler A, Lieb A, Seidel D, et al. Disseminated Fusariosis in Immunocompromised Children-
3325 Analysis of Recent Cases Identified in the Global Fungiscope Registry. *The Pediatric infectious disease*
3326 *journal* 2017; **36**(2): 230-1.

3327 419. Richardson SE, Bannatyne RM, Summerbell RC, Milliken J, Gold R, Weitzman SS. Disseminated
3328 Fusarial Infection in the Immunocompromised Host. *Reviews of Infectious Diseases* 1988; **10**(6): 1171-
3329 81.

3330 420. Hsu CM, Lee PI, Chen JM, et al. Fatal Fusarium endocarditis complicated by hemolytic anemia
3331 and thrombocytopenia in an infant. *The Pediatric infectious disease journal* 1994; **13**(12): 1146-8.

3332 421. Albisetti M, Lauener RP, Gungör T, Schär G, Niggli FK, Nadal D. Disseminated Fusarium
3333 oxysporum infection in hemophagocytic lymphohistiocytosis. *Infection* 2004; **32**(6): 364-6.

3334 422. Alvarez-Franco M, Reyes-Mugica M, Paller AS. Cutaneous Fusarium infection in an adolescent
3335 with acute leukemia. *Pediatr Dermatol* 1992; **9**(1): 62-5.

3336 423. Ammari LK, Puck JM, McGowan KL. Catheter-related Fusarium solani fungemia and pulmonary
3337 infection in a patient with leukemia in remission. *Clinical infectious diseases : an official publication of*
3338 *the Infectious Diseases Society of America* 1993; **16**(1): 148-50.

3339 424. Repiso T, García-Patos V, Martín N, Creus M, Bastida P, Castells A. Disseminated fusariosis.
3340 *Pediatr Dermatol* 1996; **13**(2): 118-21.

3341 425. Seban R-D, Bonardel G, Guernou M, Lussato D, Queneau M. The Use of FDG PET-CT Imaging for
3342 the Assessment of Early Antifungal Treatment Response in Disseminated Fusariosis. *Clin Nucl Med* 2017;
3343 **42**(7): 569-70.

3344 426. Silva GM, Silveira ARC, Betânia CAR, Macêdo DPC, Neves RP. Disseminated fusariosis secondary
3345 to neuroblastoma with fatal outcome. *Mycopathologia* 2013; **176**(3-4): 233-6.

3346 427. Litvinov N, da Silva MTN, van der Heijden IM, et al. An outbreak of invasive fusariosis in a
3347 children's cancer hospital. *Clinical microbiology and infection : the official publication of the European*
3348 *Society of Clinical Microbiology and Infectious Diseases* 2015; **21**(3): 268.e1-e2687.

3349 428. Carlesse F, Amaral A-PC, Gonçalves SS, et al. Outbreak of Fusarium oxysporum infections in
3350 children with cancer: an experience with 7 episodes of catheter-related fungemia. *Antimicrob Resist*
3351 *Infect Control* 2017; **6**: 93-.

3352 429. Vallerini D, Forghieri F, Lagreca I, et al. Detection of Fusarium-specific T cells in hematologic
3353 patients with invasive fusariosis. *The Journal of infection* 2017; **74**(3): 314-8.

3354 430. Vagace J-M, Sanz-Rodriguez C, Casado M-S, et al. Resolution of disseminated fusariosis in a child
3355 with acute leukemia treated with combined antifungal therapy: a case report. *BMC infectious diseases*
3356 2007; **7**: 40-.

3357 431. Cesaro S, Marinello S, Alessia B, et al. Successful treatment of disseminated fusariosis in a child
3358 with acute myelogenous leukaemia with medical and surgical approach. *Mycoses* 2010; **53**(2): 181-5.

3359 432. Hol JA, Wolfs TFW, Bierings MB, et al. Predictors of invasive fungal infection in pediatric
3360 allogeneic hematopoietic SCT recipients. *Bone marrow transplantation* 2014; **49**(1): 95-101.

3361 433. Morel LN, Cid PM, De Celada RMA, et al. Disseminated fusariosis in a pediatric population.
3362 *Pediatr Dermatol* 2013; **30**(6): e255-e6.

3363 434. Rodriguez CA, Luján-Zilbermann J, Woodard P, Andreansky M, Adderson EE. Successful
3364 treatment of disseminated fusariosis. *Bone Marrow Transplantation* 2003; **31**(5): 411-2.

3365 435. Kivivuori S-M, Hovi L, Vettenranta K, Saarinen-Pihkala UM. Invasive fusariosis in two
3366 transplanted children. *Eur J Pediatr* 2004; **163**(11): 692-3.

3367 436. Guzman-Cottrill JA, Zheng X, Chadwick EG. Fusarium solani endocarditis successfully treated
3368 with liposomal amphotericin B and voriconazole. *The Pediatric infectious disease journal* 2004; **23**(11):
3369 1059-61.

- 3370 437. Kah TA, Yong KC, Rahman RA. Disseminated fusariosis and endogenous fungal endophthalmitis
3371 in acute lymphoblastic leukemia following platelet transfusion possibly due to transfusion-related
3372 immunomodulation. *BMC Ophthalmol* 2011; **11**: 30-.
- 3373 438. Bassiri-Jahromi S, Doostkam A. Fungal infection and increased mortality in patients with chronic
3374 granulomatous disease. *Journal de mycologie medicale* 2012; **22**(1): 52-7.
- 3375 439. Lackner M, Sybren de Hoog GS, Yang L, et al. Proposed nomenclature for *Pseudallescheria*,
3376 *Scedosporium* and related genera. *Fungal Diversity* 2014; **67**(1): 1-10.
- 3377 440. Heath CH, Slavin MA, Sorrell TC, et al. Population-based surveillance for scedosporiosis in
3378 Australia: epidemiology, disease manifestations and emergence of *Scedosporium aurantiacum* infection.
3379 *Clin Microbiol Infect* 2009; **15**(7): 689-93.
- 3380 441. Rodriguez-Tudela JL, Berenguer J, Guarro J, et al. Epidemiology and outcome of *Scedosporium*
3381 *prolificans* infection, a review of 162 cases. *Medical mycology* 2009; **47**(4): 359-70.
- 3382 442. Husain S, Alexander BD, Munoz P, et al. Opportunistic mycelial fungal infections in organ
3383 transplant recipients: emerging importance of non-*Aspergillus* mycelial fungi. *Clin Infect Dis* 2003; **37**(2):
3384 221-9.
- 3385 443. Grenouillet F, Botterel F, Crouzet J, et al. *Scedosporium prolificans*: an emerging pathogen in
3386 France? *Medical mycology* 2009; **47**(4): 343-50.
- 3387 444. Lamaris GA, Chamilos G, Lewis RE, Safdar A, Raad, II, Kontoyiannis DP. *Scedosporium* infection in
3388 a tertiary care cancer center: a review of 25 cases from 1989-2006. *Clinical infectious diseases : an*
3389 *official publication of the Infectious Diseases Society of America* 2006; **43**(12): 1580-4.
- 3390 445. Ramirez-Garcia A, Pellon A, Rementeria A, et al. *Scedosporium* and *Lomentospora*: an updated
3391 overview of underrated opportunists. *Medical mycology* 2018; **56**(suppl_1): 102-25.
- 3392 446. Maertens J, Lagrou K, Deweerdt H, et al. Disseminated infection by *Scedosporium prolificans*: an
3393 emerging fatality among haematology patients. Case report and review. *Ann Hematol* 2000; **79**(6): 340-
3394 4.
- 3395 447. Husain S, Munoz P, Forrest G, et al. Infections due to *Scedosporium apiospermum* and
3396 *Scedosporium prolificans* in transplant recipients: clinical characteristics and impact of antifungal agent
3397 therapy on outcome. *Clinical infectious diseases : an official publication of the Infectious Diseases Society*
3398 *of America* 2005; **40**(1): 89-99.
- 3399 448. Chen TC, Ho MW, Chien WC, Lin HH. Disseminated *Scedosporium apiospermum* infection in a
3400 near-drowning patient. *J Formos Med Assoc* 2016; **115**(3): 213-4.
- 3401 449. He XH, Wu JY, Wu CJ, Halm-Lutterodt NV, Zhang J, Li CS. *Scedosporium Apiospermum* Infection
3402 after Near-drowning. *Chin Med J (Engl)* 2015; **128**(15): 2119-23.
- 3403 450. Leon M, Alave J, Chaparro E, Bustamante B, Seas C. A 13-year-old boy with ataxia 4 weeks after
3404 a near-drowning accident. *Clin Infect Dis* 2010; **51**(3): 326-7, 63-4.
- 3405 451. Nakamura Y, Suzuki N, Nakajima Y, et al. *Scedosporium aurantiacum* brain abscess after near-
3406 drowning in a survivor of a tsunami in Japan. *Respir Investig* 2013; **51**(4): 207-11.
- 3407 452. Nakamura Y, Utsumi Y, Suzuki N, et al. Multiple *Scedosporium apiospermum* abscesses in a
3408 woman survivor of a tsunami in northeastern Japan: a case report. *J Med Case Rep* 2011; **5**: 526.
- 3409 453. Ortmann C, Wullenweber J, Brinkmann B, Fracasso T. Fatal mycotic aneurysm caused by
3410 *Pseudallescheria boydii* after near drowning. *Int J Legal Med* 2010; **124**(3): 243-7.
- 3411 454. Shimizu J, Yoshimoto M, Takebayashi T, Ida K, Tanimoto K, Yamashita T. Atypical fungal vertebral
3412 osteomyelitis in a tsunami survivor of the Great East Japan Earthquake. *Spine (Phila Pa 1976)* 2014;
3413 **39**(12): E739-42.
- 3414 455. Wang XY, Yu SL, Chen S, Zhang WH. CNS infection caused by *Pseudallescheria boydii* in a near-
3415 drowning traveller from a traffic accident. *J Travel Med* 2016; **23**(2): tav018.
- 3416 456. Schwarz C, Brandt C, Melichar V, et al. Combined antifungal therapy is superior to monotherapy
3417 in pulmonary scedosporiosis in cystic fibrosis. *J Cyst Fibros* 2019; **18**(2): 227-32.
- 3418 457. Ahmad S, Zia S, Sarwari AR. *Scedosporium prolificans* endocarditis: case report and review of
3419 literature. *W V Med J* 2010; **106**(6): 24-6.

3420 458. Ananda-Rajah MR, Grigg A, Slavin MA. Breakthrough disseminated *Scedosporium prolificans*
3421 infection in a patient with relapsed leukaemia on prolonged voriconazole followed by posaconazole
3422 prophylaxis. *Mycopathologia* 2008; **166**(2): 83-6.

3423 459. Arthur S, Steed LL, Apple DJ, Peng Q, Howard G, Escobar-Gomez M. *Scedosporium prolificans*
3424 keratouveitis in association with a contact lens retained intraocularly over a long term. *J Clin Microbiol*
3425 2001; **39**(12): 4579-82.

3426 460. Baden LR, Katz JT, Fishman JA, et al. Salvage therapy with voriconazole for invasive fungal
3427 infections in patients failing or intolerant to standard antifungal therapy. *Transplantation* 2003; **76**(11):
3428 1632-7.

3429 461. Balaguer Rosello A, Bataller L, Lorenzo I, et al. Infections of the Central Nervous System after
3430 Unrelated Donor Umbilical Cord Blood Transplantation or Human Leukocyte Antigen-Matched Sibling
3431 Transplantation. *Biol Blood Marrow Transplant* 2017; **23**(1): 134-9.

3432 462. Balandin B, Aguilar M, Sanchez I, et al. *Scedosporium apiospermum* and *S. prolificans* mixed
3433 disseminated infection in a lung transplant recipient: An unusual case of long-term survival with
3434 combined systemic and local antifungal therapy in intensive care unit. *Med Mycol Case Rep* 2016; **11**:
3435 53-6.

3436 463. Bhagavatula S, Vale L, Evans J, Carpenter C, Barnes RA. *Scedosporium prolificans* osteomyelitis
3437 following penetrating injury: A case report. *Medical mycology case reports* 2014; **4**: 26-9.

3438 464. Bhat SV, Paterson DL, Rinaldi MG, Veldkamp PJ. *Scedosporium prolificans* brain abscess in a
3439 patient with chronic granulomatous disease: successful combination therapy with voriconazole and
3440 terbinafine. *Scand J Infect Dis* 2007; **39**(1): 87-90.

3441 465. Carod-Artal FJ, Ferreira-Coral L, Mauro-Couto J, Gomes E, de Agassiz-Vasques M. Chronic spinal
3442 epidural abscess caused by *Scedosporium prolificans* in an immunocompetent patient. *Spine (Phila Pa*
3443 *1976)* 2009; **34**(9): E330-2.

3444 466. Carreter de Granda ME, Richard C, Conde E, et al. Endocarditis caused by *Scedosporium*
3445 *prolificans* after autologous peripheral blood stem cell transplantation. *Eur J Clin Microbiol Infect Dis*
3446 2001; **20**(3): 215-7.

3447 467. Chiam N, Rose LV, Waters KD, Elder JE. *Scedosporium prolificans* endogenous endophthalmitis. *J*
3448 *aaapos* 2013; **17**(6): 627-9.

3449 468. Cobo F, Lara-Oya A, Rodriguez-Granger J, Sampedro A, Aliaga-Martinez L, Navarro-Mari JM.
3450 Infections caused by *Scedosporium/Lomentospora* species: Clinical and microbiological findings in 21
3451 cases. *Medical mycology* 2018; **56**(8): 917-25.

3452 469. Cooley L, Spelman D, Thursky K, Slavin M. Infection with *Scedosporium apiospermum* and *S.*
3453 *prolificans*, Australia. *Emerg Infect Dis* 2007; **13**(8): 1170-7.

3454 470. Cordonnier C, Rovira M, Maertens J, et al. Voriconazole for secondary prophylaxis of invasive
3455 fungal infections in allogeneic stem cell transplant recipients: results of the VOSIFI study. *Haematologica*
3456 2010; **95**(10): 1762-8.

3457 471. Daniele L, Le M, Parr AF, Brown LM. *Scedosporium prolificans* Septic Arthritis and Osteomyelitis
3458 of the Hip Joints in an Immunocompetent Patient: A Case Report and Literature Review. *Case Rep*
3459 *Orthop* 2017; **2017**: 3809732.

3460 472. de Batlle J, Motje M, Balanza R, Guardia R, Ortiz R. Disseminated infection caused by
3461 *Scedosporium prolificans* in a patient with acute multilineal leukemia. *J Clin Microbiol* 2000; **38**(4): 1694-
3462 5.

3463 473. Delhaes L, Harun A, Chen SC, et al. Molecular typing of Australian *Scedosporium* isolates
3464 showing genetic variability and numerous *S. aurantiacum*. *Emerg Infect Dis* 2008; **14**(2): 282-90.

3465 474. Ference EH, Kubak BM, Zhang P, Suh JD. Successful Treatment of *Scedosporium* Sinusitis in Two
3466 Lung Transplant Recipients: Review of the Literature and Recommendations for Management. *Allergy*
3467 *Rhinol (Providence)* 2019; **10**: 2152656719827253.

3468 475. Ferguson LM, Dreisbach AW, Csongradi E, Juncos LA, Fulop T. Recurring extracorporeal circuit
3469 clotting during continuous renal replacement therapy in fungal sepsis: successful treatment with
3470 argatroban. *Am J Med Sci* 2013; **345**(3): 256-8.

3471 476. Fernandez Guerrero ML, Askari E, Prieto E, Gadea I, Roman A. Emerging infectious endocarditis
3472 due to *Scedosporium prolificans*: a model of therapeutic complexity. *Eur J Clin Microbiol Infect Dis* 2011;
3473 **30**(11): 1321-4.

3474 477. Fernandez-Mosteirin N, Salvador-Osuna C, Mayayo P, Garcia-Zueco JC. [*Scedosporium*
3475 *prolificans*: disseminated infection in immunocompromised patient]. *Med Clin (Barc)* 2003; **120**(8): 317-
3476 8.

3477 478. Garcia-Vidal C, Cabellos C, Ayats J, Font F, Ferran E, Fernandez-Viladrich P. Fungal postoperative
3478 spondylodiscitis due to *Scedosporium prolificans*. *Spine J* 2009; **9**(9): e1-7.

3479 479. Gosbell IB, Toumasatos V, Yong J, Kuo RS, Ellis DH, Perrie RC. Cure of orthopaedic infection with
3480 *Scedosporium prolificans*, using voriconazole plus terbinafine, without the need for radical surgery.
3481 *Mycoses* 2003; **46**(5-6): 233-6.

3482 480. Greig JR, Khan MA, Hopkinson NS, Marshall BG, Wilson PO, Rahman SU. Pulmonary infection
3483 with *Scedosporium prolificans* in an immunocompetent individual. *J Infect* 2001; **43**(1): 15-7.

3484 481. Guadalajara MCV, Hernandez Gonzalez A, Carrasco Garcia de Leon S, Rojo MG, Del Real Francia
3485 MA. Mycotic Cerebral Aneurysms Secondary to *Scedosporium Prolificans* Infection in a Patient with
3486 Multiple Sclerosis. *J Clin Neurol* 2018; **14**(4): 601-3.

3487 482. Hanmantgad M, Nog R, Seiter K. Acute myeloid leukemia and fatal *Scedosporium prolificans*
3488 sepsis after eculizumab treatment for paroxysmal nocturnal hemoglobinuria: a case report. *Stem Cell*
3489 *Investig* 2017; **4**: 100.

3490 483. Harkness B, Andresen D, Kesson A, Isaacs D. Infections following lawnmower and farm
3491 machinery-related injuries in children. *J Paediatr Child Health* 2009; **45**(9): 525-8.

3492 484. Holmes NE, Trevillyan JM, Kidd SE, Leong TY. Locally extensive angio-invasive *Scedosporium*
3493 *prolificans* infection following resection for squamous cell lung carcinoma. *Medical mycology case*
3494 *reports* 2013; **2**: 98-102.

3495 485. Horre R, Marklein G. Isolation and clinical significance of *Pseudallescheria* and *Scedosporium*
3496 species. *Medical mycology* 2009; **47**(4): 415-21.

3497 486. Howden BP, Slavin MA, Schwarzer AP, Mijch AM. Successful control of disseminated
3498 *Scedosporium prolificans* infection with a combination of voriconazole and terbinafine. *Eur J Clin*
3499 *Microbiol Infect Dis* 2003; **22**(2): 111-3.

3500 487. Idigoras P, Garcia-Arenzana JM, Saenz JR, Pineiro L, Marin J. [Isolation of *Scedosporium*
3501 *prolificans* from the air in the room of a patient with leukemia and disseminated infection with this
3502 fungus]. *Enferm Infecc Microbiol Clin* 2000; **18**(8): 426-7.

3503 488. Inoda S, Sato Y, Arai Y, et al. [Bilateral Endogenous Fungal Subretinal Abscesses due to
3504 *Scedosporium prolificans*: a Case Report]. *Nippon Ganka Gakkai Zasshi* 2015; **119**(9): 632-9.

3505 489. Jain P, Nagarajan P, Prayag P, et al. Mixed angioinvasive exserohilum and scedosporium
3506 infection in a patient with AML. *Am J Hematol* 2017; **92**(1): 119-20.

3507 490. Jenks JD, Seidel D, Cornely OA, et al. Clinical Characteristics and Outcomes of invasive
3508 *Lomentospora prolificans* Infections: Analysis of Patients in the FungiScope(R) Registry. *Mycoses* 2020.

3509 491. Jeong JC, Lee H, Lee SW, et al. Fungal peritonitis due to *Scedosporium prolificans*. *Perit Dial Int*
3510 2011; **31**(2): 213-5.

3511 492. Jhanji V, Yohendran J, Constantinou M, Sheorey H, Vajpayee RB. *Scedosporium* scleritis or
3512 keratitis or both: case series. *Eye Contact Lens* 2009; **35**(6): 312-5.

3513 493. Johnson LS, Shields RK, Clancy CJ. Epidemiology, clinical manifestations, and outcomes of
3514 *Scedosporium* infections among solid organ transplant recipients. *Transpl Infect Dis* 2014; **16**(4): 578-87.

3515 494. Jover-Saenz A, Altermir-Martinez V, Barcenilla-Gaite F, Garrido-Calvo S. [Infectious arthritis with
3516 osteomyelitis due to *Scedosporium prolificans* in an immunocompetent patient]. *Med Clin (Barc)* 2016;
3517 **146**(3): e15-6.

3518 495. Kelly M, Stevens R, Konecny P. *Lomentospora prolificans* endocarditis--case report and literature
3519 review. *BMC Infect Dis* 2016; **16**: 36.

3520 496. Kesson AM, Bellemore MC, O'Mara TJ, Ellis DH, Sorrell TC. *Scedosporium prolificans*
3521 osteomyelitis in an immunocompetent child treated with a novel agent, hexadecylphosphocholine

3522 (miltefosine), in combination with terbinafine and voriconazole: a case report. *Clin Infect Dis* 2009;
3523 **48**(9): 1257-61.

3524 497. Kikuti K. [Photo quiz: Deep-seated mycosis]. *Med Mycol J* 2012; **53**(2): 93-4.

3525 498. Kimura M, Maenishi O, Ito H, Ohkusu K. Unique histological characteristics of *Scedosporium* that
3526 could aid in its identification. *Pathol Int* 2010; **60**(2): 131-6.

3527 499. Kite BW, Heng T. An atypical foot infection. *Aust Fam Physician* 2016; **45**(11): 819-20.

3528 500. Kubisiak-Rzepczyk H, Gil L, Zawirska A, et al. *Scedosporium prolificans* fungaemia in a patient
3529 with acute lymphoblastic leukaemia. *J Mycol Med* 2013; **23**(4): 261-4.

3530 501. Li JY, Yong TY, Grove DI, Coates PT. Successful control of *Scedosporium prolificans* septic arthritis
3531 and probable osteomyelitis without radical surgery in a long-term renal transplant recipient. *Transpl
3532 Infect Dis* 2008; **10**(1): 63-5.

3533 502. Lopez L, Gaztelurrutia L, Cuenca-Estrella M, et al. [Infection and colonization by *Scedosporium
3534 prolificans*]. *Enferm Infecc Microbiol Clin* 2001; **19**(7): 308-13.

3535 503. Marco de Lucas E, Sadaba P, Lastra Garcia-Baron P, et al. Cerebral scedosporiosis: an emerging
3536 fungal infection in severe neutropenic patients: CT features and CT pathologic correlation. *Eur Radiol
3537* 2006; **16**(2): 496-502.

3538 504. Masukane S, Kitahara Y, Okumoto J, Sasaki K, Nakano K. The Effective Treatment of Lung
3539 Infection Due to *Scedosporium prolificans* with Voriconazole and Surgery. *Intern Med* 2017; **56**(8): 973-
3540 7.

3541 505. Matlani M, Kaur R, Shweta. A case of *scedosporium prolificans* osteomyelitis in an
3542 immunocompetent child, misdiagnosed as tubercular osteomyelitis. *Indian J Dermatol* 2013; **58**(1): 80-1.

3543 506. Morales P, Galan G, Sanmartin E, Monte E, Tarrazona V, Santos M. Intrabronchial instillation of
3544 amphotericin B lipid complex: a case report. *Transplant Proc* 2009; **41**(6): 2223-4.

3545 507. Nakadate T, Nakamura Y, Yamauchii K, Endo S. Two cases of severe pneumonia after the 2011
3546 Great East Japan Earthquake. *Western Pac Surveill Response J* 2012; **3**(4): 67-70.

3547 508. Nishimori M, Takahashi T, Suzuki E, et al. Fatal fungemia with *Scedosporium prolificans* in a
3548 patient with acute myeloid leukemia. *Med Mycol J* 2014; **55**(4): E63-70.

3549 509. Nishio H, Utsumi T, Nakamura Y, Suzuki T, Kamei K, Saitoh T. [Fungemia caused by *Scedosporium
3550 prolificans* in myelodysplastic syndrome]. *Kansenshogaku Zasshi* 2012; **86**(1): 22-6.

3551 510. Ochi Y, Hiramoto N, Takegawa H, et al. Infective endocarditis caused by *Scedosporium
3552 prolificans* infection in a patient with acute myeloid leukemia undergoing induction chemotherapy. *Int J
3553 Hematol* 2015; **101**(6): 620-5.

3554 511. Ohashi R, Kato M, Katsura Y, et al. Breakthrough lung *Scedosporium prolificans* infection with
3555 multiple cavity lesions in a patient receiving voriconazole for probable invasive aspergillosis associated
3556 with monoclonal gammopathy of undetermined significance (MGUS). *Med Mycol J* 2011; **52**(1): 33-8.

3557 512. O'Hearn TM, Geiseler PJ, Bhatti RA, Elliott D. Control of disseminated *scedosporium prolificans*
3558 infection and endophthalmitis. *Retin Cases Brief Rep* 2010; **4**(1): 18-9.

3559 513. Pace CS, Frankenhoff JA, Isaacs JE. *Scedosporium prolificans* Septic Arthritis. *J Hand Microsurg*
3560 2017; **9**(1): 37-8.

3561 514. Park BJ, Pappas PG, Wannemuehler KA, et al. Invasive non-*Aspergillus* mold infections in
3562 transplant recipients, United States, 2001-2006. *Emerg Infect Dis* 2011; **17**(10): 1855-64.

3563 515. Pellon Daben R, Marco de Lucas E, Martin Cuesta L, et al. Imaging findings of pulmonary
3564 infection caused by *Scedosporium prolificans* in a deep immunocompromised patient. *Emerg Radiol
3565* 2008; **15**(1): 47-9.

3566 516. Penteado FD, Litvinov N, Sztajn bok J, et al. *Lomentospora prolificans* fungemia in hematopoietic
3567 stem cell transplant patients: First report in South America and literature review. *Transpl Infect Dis*
3568 2018; **20**(4): e12908.

3569 517. Reinoso R, Carreno E, Hileeto D, et al. Fatal disseminated *Scedosporium prolificans* infection
3570 initiated by ophthalmic involvement in a patient with acute myeloblastic leukemia. *Diagn Microbiol
3571 Infect Dis* 2013; **76**(3): 375-8.

3572 518. Revankar SG, Baddley JW, Chen SC, et al. A Mycoses Study Group International Prospective
3573 Study of Phaeohyphomycosis: An Analysis of 99 Proven/Probable Cases. *Open Forum Infect Dis* 2017;
3574 **4**(4): ofx200.

3575 519. Rivier A, Perny J, Debourgogne A, et al. Fatal disseminated infection due to *Scedosporium*
3576 *prolificans* in a patient with acute myeloid leukemia and posaconazole prophylaxis. *Leuk Lymphoma*
3577 2011; **52**(8): 1607-10.

3578 520. Rojas R, Molina JR, Jarque I, et al. Outcome of Antifungal Combination Therapy for Invasive
3579 Mold Infections in Hematological Patients is Independent of the Chosen Combination. *Mediterr J*
3580 *Hematol Infect Dis* 2012; **4**(1): e2012011.

3581 521. Romero Gomez MP, Garcia Rodriguez J. [Invasive fungal infection in a patient with Burkitt
3582 lymphoma]. *Rev Iberoam Micol* 2010; **27**(4): 214-5.

3583 522. Sayah DM, Schwartz BS, Kukreja J, Singer JP, Golden JA, Leard LE. *Scedosporium prolificans*
3584 pericarditis and mycotic aortic aneurysm in a lung transplant recipient receiving voriconazole
3585 prophylaxis. *Transpl Infect Dis* 2013; **15**(2): E70-4.

3586 523. Seidel D, Hassler A, Salmanton-Garcia J, et al. Invasive *Scedosporium* spp. and *Lomentospora*
3587 *prolificans* infections in pediatric patients: Analysis of 55 cases from FungiScope(R) and the literature. *Int*
3588 *J Infect Dis* 2019; **92**: 114-22.

3589 524. Slavin M, van Hal S, Sorrell TC, et al. Invasive infections due to filamentous fungi other than
3590 *Aspergillus*: epidemiology and determinants of mortality. *Clin Microbiol Infect* 2015; **21**(5): 490 e1-10.

3591 525. Smita S, Sunil S, Amarjeet K, Anil B, Yatin M. Surviving a recurrent *Scedosporium prolificans*
3592 endocarditis: Mention if consent was taken. *Indian J Med Microbiol* 2015; **33**(4): 588-90.

3593 526. Song MJ, Lee JH, Lee NY. Fatal *Scedosporium prolificans* infection in a paediatric patient with
3594 acute lymphoblastic leukaemia. *Mycoses* 2011; **54**(1): 81-3.

3595 527. Spanevello M, Morris KL, Kennedy GA. Pseudoaneurysm formation by *Scedosporium prolificans*
3596 infection in acute leukaemia. *Intern Med J* 2010; **40**(11): 793.

3597 528. Stefanovic A, Wright A, Tang V, Hoang L. Positive blood cultures in a patient recovering from
3598 febrile neutropenia. *JMM Case Rep* 2016; **3**(3): e005038.

3599 529. Steinbach WJ, Schell WA, Miller JL, Perfect JR. *Scedosporium prolificans* osteomyelitis in an
3600 immunocompetent child treated with voriconazole and caspofungin, as well as locally applied
3601 polyhexamethylene biguanide. *J Clin Microbiol* 2003; **41**(8): 3981-5.

3602 530. Studahl M, Backteman T, Stalhammar F, Chryssanthou E, Petrini B. Bone and joint infection after
3603 traumatic implantation of *Scedosporium prolificans* treated with voriconazole and surgery. *Acta*
3604 *Paediatr* 2003; **92**(8): 980-2.

3605 531. Tamaki M, Nozaki K, Onishi M, Yamamoto K, Ujiie H, Sugahara H. Fungal meningitis caused by
3606 *Lomentospora prolificans* after allogeneic hematopoietic stem cell transplantation. *Transpl Infect Dis*
3607 2016; **18**(4): 601-5.

3608 532. Tascini C, Bongiorno MG, Leonildi A, et al. Pacemaker endocarditis with pulmonary cavitory
3609 lesion due to *Scedosporium prolificans*. *J Chemother* 2006; **18**(6): 667-9.

3610 533. Tintelnot K, Just-Nubling G, Horre R, et al. A review of German *Scedosporium prolificans* cases
3611 from 1993 to 2007. *Medical mycology* 2009; **47**(4): 351-8.

3612 534. Tong SY, Peleg AY, Yoong J, Handke R, Szer J, Slavin M. Breakthrough *Scedosporium prolificans*
3613 infection while receiving voriconazole prophylaxis in an allogeneic stem cell transplant recipient. *Transpl*
3614 *Infect Dis* 2007; **9**(3): 241-3.

3615 535. Trubiano JA, Paratz E, Wolf M, et al. Disseminated *Scedosporium prolificans* infection in an
3616 'extensive metaboliser': navigating the minefield of drug interactions and pharmacogenomics. *Mycoses*
3617 2014; **57**(9): 572-6.

3618 536. Uno K, Kasahara K, Kutsuna S, et al. Infective endocarditis and meningitis due to *Scedosporium*
3619 *prolificans* in a renal transplant recipient. *J Infect Chemother* 2014; **20**(2): 131-3.

3620 537. Vagefi MR, Kim ET, Alvarado RG, Duncan JL, Howes EL, Crawford JB. Bilateral endogenous
3621 *Scedosporium prolificans* endophthalmitis after lung transplantation. *Am J Ophthalmol* 2005; **139**(2):
3622 370-3.

3623 538. Wakabayashi Y, Okugawa S, Tatsuno K, et al. Scedosporium prolificans Endocarditis: Case Report
3624 and Literature Review. *Intern Med* 2016; **55**(1): 79-82.

3625 539. Walls G, Noonan L, Wilson E, Holland D, Briggs S. Successful use of locally applied
3626 polyhexamethylene biguanide as an adjunct to the treatment of fungal osteomyelitis. *Can J Infect Dis*
3627 *Med Microbiol* 2013; **24**(2): 109-12.

3628 540. Whyte M, Irving H, O'Regan P, Nissen M, Siebert D, Labrom R. Disseminated Scedosporium
3629 prolificans infection and survival of a child with acute lymphoblastic leukemia. *Pediatr Infect Dis J* 2005;
3630 **24**(4): 375-7.

3631 541. Cortez KJ, Roilides E, Quiroz-Telles F, et al. Infections caused by Scedosporium spp. *Clin*
3632 *Microbiol Rev* 2008; **21**(1): 157-97.

3633 542. Lackner M, Rezusta A, Villuendas MC, Palacian MP, Meis JF, Klaassen CH. Infection and
3634 colonisation due to Scedosporium in Northern Spain. An in vitro antifungal susceptibility and molecular
3635 epidemiology study of 60 isolates. *Mycoses* 2011; **54** Suppl 3: 12-21.

3636 543. Sedlacek L, Graf B, Schwarz C, et al. Prevalence of Scedosporium species and Lomentospora
3637 prolificans in patients with cystic fibrosis in a multicenter trial by use of a selective medium. *J Cyst Fibros*
3638 2015; **14**(2): 237-41.

3639 544. Blyth CC, Harun A, Middleton PG, et al. Detection of occult Scedosporium species in respiratory
3640 tract specimens from patients with cystic fibrosis by use of selective media. *J Clin Microbiol* 2010; **48**(1):
3641 314-6.

3642 545. Horre R, Marklein G, Siekmeier R, Reiffert SM. Detection of hyphomycetes in the upper
3643 respiratory tract of patients with cystic fibrosis. *Mycoses* 2011; **54**(6): 514-22.

3644 546. Hong G, Miller HB, Allgood S, Lee R, Lechtzin N, Zhang SX. Use of Selective Fungal Culture Media
3645 Increases Rates of Detection of Fungi in the Respiratory Tract of Cystic Fibrosis Patients. *J Clin Microbiol*
3646 2017; **55**(4): 1122-30.

3647 547. Schwarz C, Vandeputte P, Rougeron A, et al. Developing collaborative works for faster progress
3648 on fungal respiratory infections in cystic fibrosis. *Medical mycology* 2018; **56**(suppl_1): 42-59.

3649 548. Pellon A, Ramirez-Garcia A, Buldain I, Antoran A, Rementeria A, Hernando FL.
3650 Immunoproteomics-Based Analysis of the Immunocompetent Serological Response to Lomentospora
3651 prolificans. *J Proteome Res* 2016; **15**(2): 595-607.

3652 549. Pellon A, Ramirez-Garcia A, Antoran A, et al. Scedosporium prolificans immunomes against
3653 human salivary immunoglobulin A. *Fungal Biol* 2014; **118**(1): 94-105.

3654 550. Buldain I, Pellon A, Zaldibar B, et al. Study of Humoral Responses against
3655 Lomentospora/Scedosporium spp. and Aspergillus fumigatus to Identify L. prolificans Antigens of
3656 Interest for Diagnosis and Treatment. *Vaccines (Basel)* 2019; **7**(4).

3657 551. Bouchara JP, Hsieh HY, Croquefer S, et al. Development of an oligonucleotide array for direct
3658 detection of fungi in sputum samples from patients with cystic fibrosis. *J Clin Microbiol* 2009; **47**(1): 142-
3659 52.

3660 552. Harun A, Blyth CC, Gilgado F, Middleton P, Chen SC, Meyer W. Development and validation of a
3661 multiplex PCR for detection of Scedosporium spp. in respiratory tract specimens from patients with
3662 cystic fibrosis. *J Clin Microbiol* 2011; **49**(4): 1508-12.

3663 553. Lu Q, Gerrits van den Ende AH, Bakkers JM, et al. Identification of Pseudallescheria and
3664 Scedosporium species by three molecular methods. *J Clin Microbiol* 2011; **49**(3): 960-7.

3665 554. Lu Q, van den Ende AH, de Hoog GS, et al. Reverse line blot hybridisation screening of
3666 Pseudallescheria/Scedosporium species in patients with cystic fibrosis. *Mycoses* 2011; **54** Suppl 3: 5-11.

3667 555. Ziesing S, Suerbaum S, Sedlacek L. Fungal epidemiology and diversity in cystic fibrosis patients
3668 over a 5-year period in a national reference center. *Medical mycology* 2016; **54**(8): 781-6.

3669 556. Wangchinda W, Chongtrakool P, Tanboon J, Jitmuang A. Lomentospora prolificans vertebral
3670 osteomyelitis with spinal epidural abscess in an immunocompetent woman: Case report and literature
3671 review. *Medical mycology case reports* 2018; **21**: 26-9.

3672 557. Elizondo-Zertuche M, Montoya AM, Robledo-Leal E, et al. Comparative Pathogenicity of
3673 Lomentospora prolificans (Scedosporium prolificans) Isolates from Mexican Patients. *Mycopathologia*
3674 2017; **182**(7-8): 681-9.

3675 558. Schwarz C, Brandt C, Antweiler E, et al. Prospective multicenter German study on pulmonary
3676 colonization with *Scedosporium* /*Lomentospora* species in cystic fibrosis: Epidemiology and new
3677 association factors. *PLoS one* 2017; **12**(2): e0171485.

3678 559. Alastruey-Izquierdo A, Alcazar-Fuoli L, Rivero-Menendez O, et al. Molecular Identification and
3679 Susceptibility Testing of Molds Isolated in a Prospective Surveillance of Triazole Resistance in Spain
3680 (FILPOP2 Study). *Antimicrob Agents Chemother* 2018; **62**(9).

3681 560. Biswas C, Law D, Birch M, et al. In vitro activity of the novel antifungal compound F901318
3682 against Australian *Scedosporium* and *Lomentospora* fungi. *Medical mycology* 2018; **56**(8): 1050-4.

3683 561. Sandoval-Denis M, Sutton DA, Fothergill AW, et al. *Scopulariopsis*, a poorly known opportunistic
3684 fungus: spectrum of species in clinical samples and in vitro responses to antifungal drugs. *J Clin Microbiol*
3685 2013; **51**(12): 3937-43.

3686 562. Berenguer J, Rodriguez-Tudela JL, Richard C, et al. Deep infections caused by *Scedosporium*
3687 *prolificans*. A report on 16 cases in Spain and a review of the literature. *Scedosporium Prolificans*
3688 Spanish Study Group. *Medicine (Baltimore)* 1997; **76**(4): 256-65.

3689 563. McKelvie PA, Wong EY, Chow LP, Hall AJ. *Scedosporium* endophthalmitis: two fatal disseminated
3690 cases of *Scedosporium* infection presenting with endophthalmitis. *Clin Exp Ophthalmol* 2001; **29**(5): 330-
3691 4.

3692 564. Taj-Aldeen SJ, Rammaert B, Gamaletsou M, et al. Osteoarticular Infections Caused by Non-
3693 *Aspergillus* Filamentous Fungi in Adult and Pediatric Patients: A Systematic Review. *Medicine (Baltimore)*
3694 2015; **94**(50): e2078.

3695 565. Bouza E, Munoz P, Vega L, Rodriguez-Creixems M, Berenguer J, Escudero A. Clinical resolution of
3696 *Scedosporium prolificans* fungemia associated with reversal of neutropenia following administration of
3697 granulocyte colony-stimulating factor. *Clinical infectious diseases : an official publication of the*
3698 *Infectious Diseases Society of America* 1996; **23**(1): 192-3.

3699 566. Salesa R, Burgos A, Ondiviela R, Richard C, Quindos G, Ponton J. Fatal disseminated infection by
3700 *Scedosporium inflatum* after bone marrow transplantation. *Scand J Infect Dis* 1993; **25**(3): 389-93.

3701 567. Pickles RW, Pacey DE, Muir DB, Merrell WH. Experience with infection by *Scedosporium*
3702 *prolificans* including apparent cure with fluconazole therapy. *The Journal of infection* 1996; **33**(3): 193-7.

3703 568. Idigoras P, Perez-Trallero E, Pineiro L, et al. Disseminated infection and colonization by
3704 *Scedosporium prolificans*: a review of 18 cases, 1990-1999. *Clinical infectious diseases : an official*
3705 *publication of the Infectious Diseases Society of America* 2001; **32**(11): E158-65.

3706 569. Guadalajara MCV, Hernández González A, Carrasco García de León S, Rojo MG, Del Real Francia
3707 MÁ. Mycotic Cerebral Aneurysms Secondary to *Scedosporium Prolificans* Infection in a Patient with
3708 Multiple Sclerosis. *J Clin Neurol* 2018; **14**(4): 601-3.

3709 570. Sitterlé E, Giraud S, Leto J, et al. Matrix-assisted laser desorption ionization-time of flight mass
3710 spectrometry for fast and accurate identification of *Pseudallescheria*/*Scedosporium* species. *Clinical*
3711 *microbiology and infection : the official publication of the European Society of Clinical Microbiology and*
3712 *Infectious Diseases* 2014; **20**(9): 929-35.

3713 571. Kimura M, Maenishi O, Ito H, Ohkusu K. Unique histological characteristics of *Scedosporium* that
3714 could aid in its identification. *Pathol Int* 2010; **60**(2): 131-6.

3715 572. Cuenca-Estrella M, Gomez-Lopez A, Mellado E, Buitrago MJ, Monzon A, Rodriguez-Tudela JL.
3716 Head-to-head comparison of the activities of currently available antifungal agents against 3,378 Spanish
3717 clinical isolates of yeasts and filamentous fungi. *Antimicrob Agents Chemother* 2006; **50**(3): 917-21.

3718 573. Meletiadiis J, Meis JF, Mouton JW, Rodriguez-Tudela JL, Donnelly JP, Verweij PE. In vitro activities
3719 of new and conventional antifungal agents against clinical *Scedosporium* isolates. *Antimicrob Agents*
3720 *Chemother* 2002; **46**(1): 62-8.

3721 574. Troke P, Aguirrebengoa K, Arteaga C, et al. Treatment of scedosporiosis with voriconazole:
3722 clinical experience with 107 patients. *Antimicrobial agents and chemotherapy* 2008; **52**(5): 1743-50.

3723 575. Jenks JD, Seidel D, Cornely OA, et al. Voriconazole plus terbinafine combination antifungal
3724 therapy for invasive *Lomentospora prolificans* infections: analysis of 41 patients from the FungiScope®
3725 registry 2008-2019. *Clinical Microbiology and Infection* 2020.

3726 576. Yustes C, Guarro J. In vitro synergistic interaction between amphotericin B and micafungin
3727 against *Scedosporium* spp. *Antimicrob Agents Chemother* 2005; **49**(8): 3498-500.

3728 577. Afeltra J, Dannaoui E, Meis JFGM, Rodriguez-Tudela JL, Verweij PE. In vitro synergistic
3729 interaction between amphotericin B and pentamidine against *Scedosporium prolificans*. *Antimicrobial*
3730 *agents and chemotherapy* 2002; **46**(10): 3323-6.

3731 578. Schemuth H, Dittmer S, Lackner M, et al. In vitro activity of colistin as single agent and in
3732 combination with antifungals against filamentous fungi occurring in patients with cystic fibrosis.
3733 *Mycoses* 2013; **56**(3): 297-303.

3734 579. Meletiadiis J, Mouton JW, Meis JF, Verweij PE. In vitro drug interaction modeling of
3735 combinations of azoles with terbinafine against clinical *Scedosporium prolificans* isolates. *Antimicrob*
3736 *Agents Chemother* 2003; **47**(1): 106-17.

3737 580. Dolton MJ, Perera V, Pont LG, McLachlan AJ. Terbinafine in combination with other antifungal
3738 agents for treatment of resistant or refractory mycoses: investigating optimal dosing regimens using a
3739 physiologically based pharmacokinetic model. *Antimicrob Agents Chemother* 2014; **58**(1): 48-54.

3740 581. Jenks JD, Seidel D, Cornely OA, et al. Clinical Characteristics and Outcomes of invasive
3741 *Lomentospora prolificans* Infections: Analysis of Patients in the FungiScope® Registry. *Mycoses* 2020:
3742 10.1111/myc.13067.

3743 582. Masukane S, Kitahara Y, Okumoto J, Sasaki K, Nakano K. The Effective Treatment of Lung
3744 Infection Due to *Scedosporium prolificans* with Voriconazole and Surgery. *Internal medicine (Tokyo,*
3745 *Japan)* 2017; **56**(8): 973-7.

3746 583. Sparrow SA, Hallam LA, Wild BE, Baker DL. *Scedosporium inflatum*: first case report of
3747 disseminated infection and review of the literature. *Pediatr Hematol Oncol* 1992; **9**(3): 293-5.

3748 584. Seidel D, Hassler A, Salmanton-Garcia J, et al. Invasive *Scedosporium* spp. and *Lomentospora*
3749 *prolificans* Infections in Pediatric Patients: Analysis of 55 Cases from FungiScope(R) and the Literature.
3750 *Int J Infect Dis* 2019.

3751 585. Seidel D, Hassler A, Salmanton-Garcia J, et al. Invasive *Scedosporium* spp. and *Lomentospora*
3752 *prolificans* infections in pediatric patients: Analysis of 55 cases from FungiScope(R) and the literature. *Int*
3753 *J Infect Dis* 2019; **92**: 114-22.

3754 586. Kaltseis J, Rainer J, De Hoog GS. Ecology of *Pseudallescheria* and *Scedosporium* species in
3755 human-dominated and natural environments and their distribution in clinical samples. *Medical*
3756 *mycology* 2009; **47**(4): 398-405.

3757 587. Rougeron A, Schuliar G, Leto J, et al. Human-impacted areas of France are environmental
3758 reservoirs of the *Pseudallescheria boydii*/*Scedosporium apiospermum* species complex. *Environ*
3759 *Microbiol* 2015; **17**(4): 1039-48.

3760 588. Dinh A, Demay O, Rottman M, et al. Case of femoral pseudarthrosis due to *Scedosporium*
3761 *apiospermum* in an immunocompetent patient with successful conservative treatment and review of
3762 literature. *Mycoses* 2018; **61**(6): 400-9.

3763 589. Kondo M, Goto H, Yamanaka K. Case of *Scedosporium aurantiacum* infection detected in a
3764 subcutaneous abscess. *Medical mycology case reports* 2018; **20**: 26-7.

3765 590. Zouhair R, Rougeron A, Razafimandimby B, Kobi A, Bouchara JP, Giraud S. Distribution of the
3766 different species of the *Pseudallescheria boydii*/*Scedosporium apiospermum* complex in French patients
3767 with cystic fibrosis. *Medical mycology* 2013; **51**(6): 603-13.

3768 591. Gilgado F, Cano J, Gene J, Sutton DA, Guarro J. Molecular and phenotypic data supporting
3769 distinct species statuses for *Scedosporium apiospermum* and *Pseudallescheria boydii* and the proposed
3770 new species *Scedosporium dehoogii*. *J Clin Microbiol* 2008; **46**(2): 766-71.

3771 592. Chen S, Aronow ME, Wang C, Shen D, Chan CC. Classical pathology of sympathetic ophthalmia
3772 presented in a unique case. *Open Ophthalmol J* 2014; **8**: 32-8.

3773 593. Li FG, Yang YP, Li W, et al. Spontaneous Remission of Subcutaneous *Scedosporiosis* Caused by
3774 *Scedosporium dehoogii* in a Psoriatic Patient. *Mycopathologia* 2017; **182**(5-6): 561-7.

3775 594. Sakata Y, Taga F, Ushigami T, et al. A Case of Cutaneous Mycosis Caused by *Scedosporium*
3776 *dehoogii* on an Immunocompromised Patient. *Mycopathologia* 2018; **183**(2): 465-70.

3777 595. Pang KR, Wu JJ, Huang DB, Tying SK. Subcutaneous fungal infections. *Dermatol Ther* 2004;
3778 **17**(6): 523-31.

3779 596. Chang A, Musk M, Lavender M, et al. Epidemiology of invasive fungal infections in lung
3780 transplant recipients in Western Australia. *Transpl Infect Dis* 2019; **21**(3): e13085.

3781 597. Lee MG, Choi JG, Son BC. Scedosporium apiospermum: An Emerging Fatal Cause of Fungal
3782 Abscess and Ventriculitis after Near-drowning. *Asian J Neurosurg* 2018; **13**(3): 792-6.

3783 598. Signore SC, Dohm CP, Schutze G, Bahr M, Kermer P. Scedosporium apiospermum brain
3784 abscesses in a patient after near-drowning - a case report with 10-year follow-up and a review of the
3785 literature. *Med Mycol Case Rep* 2017; **17**: 17-9.

3786 599. Leek R, Aldag E, Nadeem I, et al. Scedosporiosis in a Combined Kidney and Liver Transplant
3787 Recipient: A Case Report of Possible Transmission from a Near-Drowning Donor. *Case Rep Transplant*
3788 2016; **2016**: 1879529.

3789 600. Kim SH, Ha YE, Youn JC, et al. Fatal scedosporiosis in multiple solid organ allografts transmitted
3790 from a nearly-drowned donor. *Am J Transplant* 2015; **15**(3): 833-40.

3791 601. Nochez Y, Arsene S, Le Guellec C, et al. Unusual pharmacokinetics of intravitreal and systemic
3792 voriconazole in a patient with Scedosporium apiospermum endophthalmitis. *J Ocul Pharmacol Ther*
3793 2008; **24**(1): 87-90.

3794 602. Taylor A, Wiffen SJ, Kennedy CJ. Post-traumatic Scedosporium inflatum endophthalmitis. *Clin*
3795 *Exp Ophthalmol* 2002; **30**(1): 47-8.

3796 603. Zarkovic A, Guest S. Scedosporium apiospermum traumatic endophthalmitis successfully treated
3797 with voriconazole. *Int Ophthalmol* 2007; **27**(6): 391-4.

3798 604. Kepez Yildiz B, Hasanreisoglu M, Aktas Z, Aksu G, Kocak BC, Akata F. Fungal keratitis secondary
3799 to Scedosporium apiospermum infection and successful treatment with surgical and medical
3800 intervention. *Int Ophthalmol* 2014; **34**(2): 305-8.

3801 605. Wu Z, Ying H, Yiu S, Irvine J, Smith R. Fungal keratitis caused by Scedosporium apiospermum:
3802 report of two cases and review of treatment. *Cornea* 2002; **21**(5): 519-23.

3803 606. Peghin M, Monforte V, Martin-Gomez MT, et al. Epidemiology of invasive respiratory disease
3804 caused by emerging non-Aspergillus molds in lung transplant recipients. *Transpl Infect Dis* 2016; **18**(1):
3805 70-8.

3806 607. Giri S, Kindo AJ, Rao S, Kumar AR. Unusual causes of fungal rhinosinusitis: a study from a tertiary
3807 care centre in South India. *Indian J Med Microbiol* 2013; **31**(4): 379-84.

3808 608. Abgrall S, Pizzocolo C, Bouges-Michel C, et al. Scedosporium apiospermum lung infection with
3809 fatal subsequent postoperative outcome in an immunocompetent host. *Clin Infect Dis* 2007; **45**(4): 524-
3810 5.

3811 609. Acharya A, Ghimire A, Khanal B, Bhattacharya S, Kumari N, Kanungo R. Brain abscess due to
3812 Scedosporium apiospermum in a non immunocompromised child. *Indian J Med Microbiol* 2006; **24**(3):
3813 231-2.

3814 610. Agatha D, Krishnan KU, Dillirani VA, Selvi R. Invasive lung infection by Scedosporium
3815 apiospermum in an immunocompetent individual. *Indian J Pathol Microbiol* 2014; **57**(4): 635-7.

3816 611. Ahmed J, Ditmars DM, Sheppard T, del Busto R, Venkat KK, Parasuraman R. Recurrence of
3817 Scedosporium apiospermum infection following renal re-transplantation. *Am J Transplant* 2004; **4**(10):
3818 1720-4.

3819 612. Al Refai M, Duhamel C, Le Rochais JP, Icard P. Lung scedosporiosis: a differential diagnosis of
3820 aspergillosis. *Eur J Cardiothorac Surg* 2002; **21**(5): 938-9.

3821 613. Al-Jehani H, Guiot MC, Torres C, Marcoux J. Scedosporium cerebral abscesses after extra-
3822 corporeal membrane oxygenation. *Can J Neurol Sci* 2010; **37**(5): 671-6.

3823 614. Allen PB, Koka R, Kleinberg ME, Baer MR. Scedosporium apiospermum soft tissue infection as
3824 the initial presentation of acute myeloid leukemia: a case report. *J Clin Oncol* 2013; **31**(7): e98-100.

3825 615. Alpaydin S, Guler A, Celebisoy N, Polat SH, Turhan T. Pseudallescheria boydii infection of the
3826 central nervous system: first reported case from Turkey. *Acta Neurol Belg* 2015; **115**(3): 489-92.

3827 616. Annam V, Athaniker VS, Yelikar BR. Isolated frontal sinusitis due to Pseudallescheria boydii.
3828 *Indian J Pathol Microbiol* 2008; **51**(3): 435-6.

3829 617. Apostolova LG, Johnson EK, Adams HP, Jr. Disseminated *Pseudallescheria boydii* infection
3830 successfully treated with voriconazole. *J Neurol Neurosurg Psychiatry* 2005; **76**(12): 1741-2.

3831 618. Auffret N, Janssen F, Chevalier P, Guillemain R, Amrein C, Le Beller C. [Voriconazole
3832 photosensitivity: 7 cases]. *Ann Dermatol Venereol* 2006; **133**(4): 330-2.

3833 619. Awaya Y, Nagao Y, Murakami I, Shigetou E, Okimasa S, Shibata S. [Case of pulmonary
3834 pseudallescheriasis responding successfully to treatment with voriconazole]. *Nihon Kokyuki Gakkai*
3835 *Zasshi* 2007; **45**(10): 788-92.

3836 620. Azofra MM, Somovilla JL, Porras MC, Carrillo LH, Perez RD. Use of intralesional voriconazole for
3837 the treatment of cutaneous *Scedosporium apiospermum* infection. *Clin Infect Dis* 2010; **51**(2): 255-7.

3838 621. Baidya A, Gupta N, Basu A, et al. *Scedosporium apiospermum* as a rare cause of fungal
3839 rhinosinusitis. *J Family Med Prim Care* 2019; **8**(2): 766-8.

3840 622. Baradkar VP, Mathur M, Kumar S. Invasive fungal sinusitis resulting in orbital apex syndrome in
3841 HIV patient. *Indian J Pathol Microbiol* 2010; **53**(4): 862-3.

3842 623. Bashir G, Shakeel S, Wani T, Kakru DK. Pulmonary pseudallescheriasis in a patient with healed
3843 tuberculosis. *Mycopathologia* 2004; **158**(3): 289-91.

3844 624. Bates DD, Mims JW. Invasive fungal sinusitis caused by *Pseudallescheria boydii*: case report and
3845 literature review. *Ear, nose, & throat journal* 2006; **85**(11): 729-37.

3846 625. Baumgartner BJ, Rakita RM, Backous DD. *Scedosporium apiospermum* otomycosis. *Am J*
3847 *Otolaryngol* 2007; **28**(4): 254-6.

3848 626. Beier F, Kittan N, Holzmann T, et al. Successful treatment of *Scedosporium apiospermum* soft
3849 tissue abscess with caspofungin and voriconazole in a severely immunocompromised patient with acute
3850 myeloid leukemia. *Transpl Infect Dis* 2010; **12**(6): 538-42.

3851 627. Belenitsky MP, Liu C, Tsui I. *Scedosporium apiospermum* endophthalmitis treated early with
3852 intravitreal voriconazole results in recovery of vision. *J Ophthalmic Inflamm Infect* 2012; **2**(3): 157-60.

3853 628. Benamu E, Yu AT, Xie L, Fernandez-Pol S, Liu AY, Ho DY. *Scedosporium apiospermum* infection of
3854 the urinary system with a review of treatment options and cases in the literature. *Transpl Infect Dis*
3855 2018; **20**(1).

3856 629. Bernhardt A, Seibold M, Rickerts V, Tintelnot K. Cluster analysis of *Scedosporium boydii*
3857 infections in a single hospital. *Int J Med Microbiol* 2015; **305**(7): 724-8.

3858 630. Bhally HS, Shields C, Lin SY, Merz WG. Otitis caused by *Scedosporium apiospermum* in an
3859 immunocompetent child. *Int J Pediatr Otorhinolaryngol* 2004; **68**(7): 975-8.

3860 631. Bhatk V, Naseeruddin K. Invasive sino-nasal pseudallescheriasis in a non-immunocompromised
3861 patient. *Indian J Otolaryngol Head Neck Surg* 2001; **53**(2): 148-50.

3862 632. Bhuta S, Hsu CC, Kwan GN. *Scedosporium apiospermum* endophthalmitis: diffusion-weighted
3863 imaging in detecting subchoroidal abscess. *Clin Ophthalmol* 2012; **6**: 1921-4.

3864 633. Bibashi E, de Hoog GS, Kostopoulou E, Tsivitanidou M, Sevastidou J, Geleris P. Invasive infection
3865 caused by *Pseudallescheria boydii* in an immunocompetent patient. *Hippokratia* 2009; **13**(3): 184-6.

3866 634. Blasco-Lucas A, Reyes-Juarez JL, Nazarena Pizzi M, Permanyer E, Evangelista A, Galinanes M.
3867 Aortic Arch Mycotic Aneurysm Due to *Scedosporium Apiospermum* Reconstructed With Homografts.
3868 *Ann Thorac Surg* 2015; **99**(6): 2218-20.

3869 635. Bonatti H, Goegele H, Tabarelli D, et al. *Pseudallescheria boydii* infection after liver
3870 retransplantation. *Liver Transpl* 2007; **13**(7): 1068-9.

3871 636. Borok J, Aleshin M, Sarantopoulos G, Worswick S. Image Gallery: Immunocompromised patient
3872 presenting with inguinal rash: a case of *Scedosporium apiospermum*. *Br J Dermatol* 2017; **176**(4): e39.

3873 637. Bose B, Sharma S, Derrington P, Divi D. *Scedosporium apiospermum* peritonitis in a patient
3874 undergoing peritoneal dialysis. *Nephrology (Carlton)* 2012; **17**(5): 521-2.

3875 638. Bosma F, Voss A, van Hamersvelt HW, et al. Two cases of subcutaneous *Scedosporium*
3876 *apiospermum* infection treated with voriconazole. *Clin Microbiol Infect* 2003; **9**(7): 750-3.

3877 639. Boyce Z, Collins N. *Scedosporium apiospermum*: An unreported cause of fungal sporotrichoid-
3878 like lymphocutaneous infection in Australia and review of the literature. *Australas J Dermatol* 2015;
3879 **56**(2): e39-42.

3880 640. Boyd ME, Dao H, Estep JD, Huttenbach YT, Hemmige V. Utilization of voriconazole drug
3881 monitoring in the treatment of cutaneous *Scedosporium apiospermum* infection. *Medical mycology case*
3882 *reports* 2018; **22**: 52-4.

3883 641. Bradley JC, Hirsch BA, Kimbrough RC, 3rd, McCartney DL. *Pseudallescheria boydii* keratitis. *Scand*
3884 *J Infect Dis* 2006; **38**(11-12): 1101-3.

3885 642. Brizio A, Nosari A, Lombardi G, Riva M, Cantoni S, Morra E. Oral voriconazole for neutropenia: a
3886 leukemia patient with probable pulmonary aspergillosis and scedosporidiosis. *J Chemother* 2011; **23**(1):
3887 53-4.

3888 643. Bunya VY, Hammersmith KM, Rapuano CJ, Ayres BD, Cohen EJ. Topical and oral voriconazole in
3889 the treatment of fungal keratitis. *Am J Ophthalmol* 2007; **143**(1): 151-3.

3890 644. Buzina W, Feierl G, Haas D, et al. Lethal brain abscess due to the fungus *Scedosporium*
3891 *apiospermum* (teleomorph *Pseudallescheria boydii*) after a near-drowning incident: case report and
3892 review of the literature. *Medical mycology* 2006; **44**(5): 473-7.

3893 645. Caggiano G, Cantisani P, Rolli M, Gianfreda CD, Pizzolante M, Montagna MT. The importance of
3894 a proper aetiological diagnosis in the management of patients with invasive mycoses: a case report of a
3895 brain abscess by *Scedosporium apiospermum*. *Mycopathologia* 2011; **172**(4): 317-22.

3896 646. Campagnaro EL, Woodside KJ, Early MG, et al. Disseminated *Pseudallescheria boydii*
3897 (*Scedosporium apiospermum*) infection in a renal transplant patient. *Transpl Infect Dis* 2002; **4**(4): 207-
3898 11.

3899 647. Campa-Thompson MM, West JA, Guileyardo JM, Spak CW, Sloan LM, Beal SG. Clinical and
3900 morphologic findings in disseminated *Scedosporium apiospermum* infections in immunocompromised
3901 patients. *Proc (Bayl Univ Med Cent)* 2014; **27**(3): 253-6.

3902 648. Canet JJ, Pagerols X, Sanchez C, Vives P, Garau J. Lymphocutaneous syndrome due to
3903 *Scedosporium apiospermum*. *Clin Microbiol Infect* 2001; **7**(11): 648-50.

3904 649. Cardoso JC, Serra D, Cardoso R, Reis JP, Tellechea O, Figueiredo A. Cutaneous *pseudallescheria*
3905 *boydii* infection in a renal transplant patient: A case report. *Dermatol Online J* 2009; **15**(10): 8.

3906 650. Caroti L, Zanazzi M, Rogasi P, et al. Subcutaneous nodules and infectious complications in renal
3907 allograft recipients. *Transplant Proc* 2010; **42**(4): 1146-7.

3908 651. Caston JJ, Linares MJ, Rivero A, Casal M, Torre-Cisneros J. Clinical differences between invasive
3909 pulmonary infection by *Scedosporium apiospermum* and invasive pulmonary aspergillosis. *Mycoses*
3910 2011; **54**(5): e468-73.

3911 652. Ceccarelli L, Calisti G, Delle Rose D, et al. Dapsone hypersensitivity syndrome complicated by
3912 *Scedosporium apiospermum* pneumonia in an immunocompetent patient. *Infection* 2012; **40**(4): 459-62.

3913 653. Centellas Perez FJ, Martinez Antolinos C, Piqueras Sanchez S, Lorenzo Gonzalez I, Llamas Fuentes
3914 F, Gomez Roldan C. [*Scedosporium apiospermum* infection in a kidney transplant recipient]. *Rev*
3915 *Iberoam Micol* 2019; **36**(1): 48-50.

3916 654. Cetrulo CL, Jr., Leto Barone AA, Jordan K, et al. A multi-disciplinary approach to the management
3917 of fungal osteomyelitis: current concepts in post-traumatic lower extremity reconstruction: a case
3918 report. *Microsurgery* 2012; **32**(2): 144-7.

3919 655. Chakrabarti A, Shivaprakash MR, Singh R, et al. Fungal endophthalmitis: fourteen years'
3920 experience from a center in India. *Retina* 2008; **28**(10): 1400-7.

3921 656. Chakraborty A, Workman MR, Bullock PR. *Scedosporium apiospermum* brain abscess treated
3922 with surgery and voriconazole. Case report. *J Neurosurg* 2005; **103**(1 Suppl): 83-7.

3923 657. Chandrakala C, Tharini GK. Subcutaneous Scedosporiosis with Dissemination. *Indian J Dermatol*
3924 2019; **64**(4): 315-7.

3925 658. Chaney S, Gopalan R, Berggren RE. Pulmonary *Pseudallescheria boydii* infection with cutaneous
3926 zygomycosis after near drowning. *South Med J* 2004; **97**(7): 683-7.

3927 659. Chanqueo L, Gutierrez C, Tapia C, Silva V, Razeto L, Misad C. [*Scedosporium apiospermum*
3928 rhinosinusual infection in an immunocompetent host]. *Rev Chilena Infectol* 2009; **26**(5): 453-6.

3929 660. Chaveiro MA, Vieira R, Cardoso J, Afonso A. Cutaneous infection due to *Scedosporium*
3930 *apiospermum* in an immunosuppressed patient. *J Eur Acad Dermatol Venereol* 2003; **17**(1): 47-9.

3931 661. Chen FK, Chen SD, Tay-Kearney ML. Intravitreal voriconazole for the treatment of endogenous
3932 endophthalmitis caused by *Scedosporium apiospermum*. *Clin Exp Ophthalmol* 2007; **35**(4): 382-5.

3933 662. Clement ME, Maziarz EK, Schroder JN, Patel CB, Perfect JR. *Scedosporium apiospermum* infection
3934 of the "Native" valve: Fungal endocarditis in an orthotopic heart transplant recipient. *Medical mycology*
3935 *case reports* 2015; **9**: 34-6.

3936 663. Colombo LGR, Gregorini ER, Dalmaso H, et al. [*Scedosporium* spp. osteomyelitis: A case report].
3937 *Rev Argent Microbiol* 2019.

3938 664. Cruysmans C, Rodriguez-Villalobos H, Fomekong E, Dumitriu D, Nassogne MC, Van der Linden D.
3939 Epidural Abscess Caused by *Scedosporium apiospermum* in an Immunocompetent Child. *Pediatr Infect*
3940 *Dis J* 2015; **34**(11): 1277-8.

3941 665. Cruz R, Barros M, Reyes M. [Pulmonary non invasive infection by *Scedosporium apiospermum*].
3942 *Rev Chilena Infectol* 2015; **32**(4): 472-5.

3943 666. Cuetara MS, Alhambra A, Moragues MD, Gonzalez-Elorza E, Ponton J, del Palacio A. Detection of
3944 (1->3)-beta-D-glucan as an adjunct to diagnosis in a mixed population with uncommon proven invasive
3945 fungal diseases or with an unusual clinical presentation. *Clin Vaccine Immunol* 2009; **16**(3): 423-6.

3946 667. Cumbo-Nacheli G, de Sanctis J, Holden D. *Pseudallescheria boydii* pneumonia in an
3947 immunocompetent host. *Am J Case Rep* 2012; **13**: 163-5.

3948 668. D V, T N, Jv S. Diabetic foot ulcer due to *scedosporium apiospermum*. *J Clin Diagn Res* 2013;
3949 **7**(11): 2579-80.

3950 669. Dan M, Mereuta AI, Burcoveanu C. [Disseminated infections due to *Scedosporium apiospermum*
3951 in a patient with anaplastic large cell lymphoma. A case study]. *Rev Med Chir Soc Med Nat Iasi* 2005;
3952 **109**(3): 638-41.

3953 670. Danaher PJ, Walter EA. Successful treatment of chronic meningitis caused by *Scedosporium*
3954 *apiospermum* with oral voriconazole. *Mayo Clin Proc* 2004; **79**(5): 707-8.

3955 671. Denton EJ, Smibert O, Gooi J, et al. Invasive *Scedosporium* sternal osteomyelitis following lung
3956 transplant: Cured. *Med Mycol Case Rep* 2016; **12**: 14-6.

3957 672. D'Hondt K, Parys-Van Ginderdeuren R, Foets B. Fungal keratitis caused by *Pseudallescheria*
3958 *boydii* (*Scedosporium apiospermum*). *Bull Soc Belge Ophtalmol* 2000; (277): 53-6.

3959 673. Diaz-Valle D, Benitez del Castillo JM, Amor E, Toledano N, Carretero MM, Diaz-Valle T. Severe
3960 keratomycosis secondary to *Scedosporium apiospermum*. *Cornea* 2002; **21**(5): 516-8.

3961 674. Doss M, Doss D. Skull base osteomyelitis secondary to *Scedosporium apiospermum* infection.
3962 *Radiol Case Rep* 2018; **13**(4): 759-63.

3963 675. Drinkwater DC, Davidson-Moncada J, Heckendorn E, Myers J, Whitman TJ. Photo quiz: A patient
3964 with ulcerated nodules on his face. *Clin Infect Dis* 2014; **58**(6): 839, 901-2.

3965 676. Durand CM, Durand DJ, Lee R, Ray SC, Neofytos D. A 61 year-old female with a prior history of
3966 tuberculosis presenting with hemoptysis. *Clin Infect Dis* 2011; **52**(7): 910, 57-9.

3967 677. Eldin C, Chiche L, Thomas G, et al. *Scedosporium apiospermum* catheter-related soft-tissue
3968 infection: a case report and review of the literature. *Medical mycology* 2012; **50**(6): 627-30.

3969 678. Elm MK, Ahmed A, Goksel D, Henning JS. Cutaneous and systemic infection with *Scedosporium*
3970 *apiospermum*. *Cutis* 2009; **84**(5): 275-8.

3971 679. Enshaieh SH, Darouge A, Asilian A, et al. Disseminated subcutaneous nodules caused by
3972 *Pseudallescheria boydii* in an atopic patient. *Int J Dermatol* 2006; **45**(3): 289-91.

3973 680. Ergin C, Kutlu M, Arikan Akdagli S, et al. [Isolation of *Scedosporium apiospermum* (teleomorph:
3974 *Pseudallescheria apiosperma*) from an acute myeloid leukemia patient]. *Mikrobiyol Bul* 2013; **47**(2): 351-
3975 5.

3976 681. Ezzedine K, Wissing KM, Jacobs F, Rodriguez H, Malvy D, Simonart T. Recurrent *Scedosporium*
3977 *apiospermum* skin infection in a renal transplant recipient. *J Eur Acad Dermatol Venereol* 2009; **23**(1):
3978 95-6.

3979 682. Fadzillah MT, Ishak SR, Ibrahim M. Refractory *Scedosporium apiospermum* Keratitis Successfully
3980 Treated with Combination of Amphotericin B and Voriconazole. *Case Rep Ophthalmol Med* 2013; **2013**:
3981 413953.

3982 683. Farina C, Arosio M, Marchesi G, Amer M. Scedosporium apiospermum post-traumatic cranial
3983 infection. *Brain Inj* 2002; **16**(7): 627-31.

3984 684. Farina C, Gotti E, Suter F, Goglio A. Scedosporium apiospermum soft-tissue infection: a case
3985 report and review of kidney transplant literature. *Transplant Proc* 2006; **38**(5): 1333-5.

3986 685. Faschinger C, Grisold A, Halle-Schober E, Jetzl J, Kleinert R. [Corneal abscess with the threat of
3987 perforation]. *Ophthalmologe* 2003; **100**(4): 334-6.

3988 686. Fays S, Di Cesare MP, Antunes A, Truchetet F. [Cutaneous and osteoarticular Scedosporium
3989 apiospermum infection]. *Ann Med Interne (Paris)* 2002; **153**(8): 537-9.

3990 687. Fernandez-Flores A, Lopez-Medrano R, Fuster-Foz C. Histopathological clues in the diagnosis of
3991 fungal infection by Scedosporium in a case of endophthalmitis starting as conjunctivitis. *J Cutan Pathol*
3992 2016; **43**(5): 461-7.

3993 688. Fietz T, Knauf W, Schwartz S, Thiel E. Intramedullary abscess in a patient with disseminated
3994 Scedosporium apiospermum infection. *Br J Haematol* 2003; **120**(5): 724.

3995 689. Figueroa MS, Fortun J, Clement A, De Arevalo BF. Endogenous endophthalmitis caused by
3996 Scedosporium apiospermum treated with voriconazole. *Retina* 2004; **24**(2): 319-20.

3997 690. Foo H, Ooi SY, Giles R, Jones P. Scedosporium apiospermum pacemaker endocarditis. *Int J*
3998 *Cardiol* 2009; **131**(2): e81-2.

3999 691. Fortun J, Martin-Davila P, Sanchez MA, et al. Voriconazole in the treatment of invasive mold
4000 infections in transplant recipients. *Eur J Clin Microbiol Infect Dis* 2003; **22**(7): 408-13.

4001 692. Galvis V, Berrospi R, Tello A, Ramirez D, Villarreal D. Mycotic keratitis caused by Scedosporium
4002 apiospermum in an immunocompetent patient. *Arch Soc Esp Oftalmol* 2018; **93**(12): 613-6.

4003 693. Garduno E, Hidalgo R, Bigorra L, Torres JP. [Fungal keratitis in an immunocompetent patient].
4004 *Enferm Infecc Microbiol Clin* 2011; **29**(2): 154-5.

4005 694. Garzoni C, Emonet S, Legout L, et al. Atypical infections in tsunami survivors. *Emerg Infect Dis*
4006 2005; **11**(10): 1591-3.

4007 695. Gaviani P, Schwartz RB, Hedley-Whyte ET, et al. Diffusion-weighted imaging of fungal cerebral
4008 infection. *AJNR Am J Neuroradiol* 2005; **26**(5): 1115-21.

4009 696. Gelabert-Gonzalez M, Llovo-Taboada J, Reyes-Santias R, et al. [Scedosporium apiospermum
4010 brain abscess. Report of one case with literature review]. *Neurocirugia (Astur)* 2010; **21**(2): 125-31.

4011 697. German JW, Kellie SM, Pai MP, Turner PT. Treatment of a chronic Scedosporium apiospermum
4012 vertebral osteomyelitis. Case report. *Neurosurg Focus* 2004; **17**(6): E9.

4013 698. Ghosh R, Mishra P, Maiti PK, Debnandi A. Prompt diagnosis of Scedosporium apiospermum soft
4014 tissue infection: Life-saving in a renal transplant recipient. *J Postgrad Med* 2017; **63**(3): 200-2.

4015 699. Goldman C, Akiyama MJ, Torres J, Louie E, Meehan SA. Scedosporium apiospermum infections
4016 and the role of combination antifungal therapy and GM-CSF: A case report and review of the literature.
4017 *Med Mycol Case Rep* 2016; **11**: 40-3.

4018 700. Gompels MM, Bethune CA, Jackson G, Spickett GP. Scedosporium apiospermum in chronic
4019 granulomatous disease treated with an HLA matched bone marrow transplant. *J Clin Pathol* 2002;
4020 **55**(10): 784-6.

4021 701. Gonzalez-Garcia FJ, Guzman-Puche J, Redel-Montero J, Moreno P. Fatal bilateral
4022 haemopneumothoraces following double-lung transplantation caused by pretransplant colonization by
4023 Scedosporium apiospermum. *Eur J Cardiothorac Surg* 2017; **51**(6): 1209.

4024 702. Gopinath M, Cherian A, Baheti NN, Das A, Antony M, Sarada C. An elusive diagnosis:
4025 Scedosporium apiospermum infection after near-drowning. *Ann Indian Acad Neurol* 2010; **13**(3): 213-5.

4026 703. Gottesman-Yekutieli T, Shwartz O, Edelman A, Hendel D, Dan M. Pseudallescheria boydii
4027 infection of a prosthetic hip joint--an uncommon infection in a rare location. *Am J Med Sci* 2011; **342**(3):
4028 250-3.

4029 704. Guignard S, Hubert D, Dupont B, et al. Multifocal Scedosporium apiospermum spondylitis in a
4030 cystic fibrosis patient. *J Cyst Fibros* 2008; **7**(1): 89-91.

4031 705. Hagari Y, Ishioka S, Ohyama F, Mihara M. Cutaneous infection showing sporotrichoid spread
4032 caused by Pseudallescheria boydii (Scedosporium apiospermum): successful detection of fungal DNA in
4033 formalin-fixed, paraffin-embedded sections by seminested PCR. *Arch Dermatol* 2002; **138**(2): 271-2.

4034 706. Harrison MK, Hiatt KH, Smoller BR, Cheung WL. A case of cutaneous *Scedosporium* infection in
4035 an immunocompromised patient. *J Cutan Pathol* 2012; **39**(4): 458-60.

4036 707. Hell M, Neureiter J, Wojna A, et al. Post-traumatic *Pseudallescheria apiosperma* osteomyelitis:
4037 positive outcome of a young immunocompetent male patient due to surgical intervention and
4038 voriconazole therapy. *Mycoses* 2011; **54 Suppl 3**: 43-7.

4039 708. Henao-Martinez AF, Castillo-Mancilla JR, Barron MA, Nichol AC. Combination Antifungal Therapy
4040 in the Treatment of *Scedosporium apiospermum* Central Nervous System Infections. *Case Rep Infect Dis*
4041 2013; **2013**: 589490.

4042 709. Hernandez Prats C, Llinares Tello F, Burgos San Jose A, Selva Otaolaurruchi J, Ordovas Baines JP.
4043 Voriconazole in fungal keratitis caused by *Scedosporium apiospermum*. *Ann Pharmacother* 2004; **38**(3):
4044 414-7.

4045 710. Hirschi S, Letscher-Bru V, Pottecher J, et al. Disseminated *Trichosporon mycotoxinivorans*,
4046 *Aspergillus fumigatus*, and *Scedosporium apiospermum* coinfection after lung and liver transplantation
4047 in a cystic fibrosis patient. *J Clin Microbiol* 2012; **50**(12): 4168-70.

4048 711. Holle J, Leichsenring M, Meissner PE. Nebulized voriconazole in infections with *Scedosporium*
4049 *apiospermum*--case report and review of the literature. *J Cyst Fibros* 2014; **13**(4): 400-2.

4050 712. Hornbeek H, Ackerman BH, Reigart CL, et al. *Pseudallescheria boydii* infection of the brain. *Surg*
4051 *Infect (Larchmt)* 2012; **13**(3): 179-80.

4052 713. Horre R, Feil E, Stangel AP, et al. [Scedosporiosis of the brain with fatal outcome after
4053 traumatization of the foot. case report]. *Mycoses* 2000; **43 Suppl 2**: 33-6.

4054 714. Horre R, Jovanic B, Marklein G, et al. Fatal pulmonary scedosporiosis. *Mycoses* 2003; **46**(9-10):
4055 418-21.

4056 715. Hoshino S, Tachibana I, Kijima T, et al. A 60-year-old woman with cough, fever, and upper-lobe
4057 cavitary consolidation. *Chest* 2007; **132**(2): 708-10.

4058 716. Hot A, Maunoury C, Poiree S, et al. Diagnostic contribution of positron emission tomography
4059 with [¹⁸F]fluorodeoxyglucose for invasive fungal infections. *Clin Microbiol Infect* 2011; **17**(3): 409-17.

4060 717. Hu H, Chen J. Scedosporiosis presenting with subcutaneous nodules in an immunocompromised
4061 patient. *Indian J Dermatol Venereol Leprol* 2017; **83**(1): 71-3.

4062 718. Ikewaki J, Imaizumi M, Nakamuro T, et al. Peribulbar fungal abscess and endophthalmitis
4063 following posterior subtenon injection of triamcinolone acetonide. *Acta Ophthalmol* 2009; **87**(1): 102-4.

4064 719. Ishii S, Hiruma M, Hayakawa Y, et al. Cutaneous *Pseudallescheria boydii*/*Scedosporium*
4065 *apiospermum* Complex (Molecular type: *Scedosporium apiospermum* [Clade 4]) Infection: A Case Report
4066 and Literature Review of Cases from Japan. *Med Mycol J* 2015; **56**(4): E25-30.

4067 720. Issakainen J, Salonen JH, Anttila VJ, et al. Deep, respiratory tract and ear infections caused by
4068 *Pseudallescheria* (*Scedosporium*) and *Microascus* (*Scopulariopsis*) in Finland. A 10-year retrospective
4069 multi-center study. *Medical mycology* 2010; **48**(3): 458-65.

4070 721. Jain A, Egbert P, McCulley TJ, Blumenkranz MS, Moshfeghi DM. Endogenous *Scedosporium*
4071 *apiospermum* endophthalmitis. *Arch Ophthalmol* 2007; **125**(9): 1286-9.

4072 722. Jalava-Karvinen P, Nyman M, Gardberg M, Harju I, Hohenthal U, Oksi J. *Scedosporium*
4073 *apiospermum* as a rare cause of central skull base osteomyelitis. *Medical mycology case reports* 2016;
4074 **11**: 28-30.

4075 723. Jayamohan Y, Ribes JA. *Pseudallescheriasis*: a summary of patients from 1980-2003 in a tertiary
4076 care center. *Arch Pathol Lab Med* 2006; **130**(12): 1843-6.

4077 724. Joob B, Wiwanitkit V. CNS *Pseudallescheria boydii* infection. *Acta Neurol Belg* 2015; **115**(4): 747.

4078 725. Jutley G, Koukoulis A, Forbes J, Sharma V. Unusual case of *Scedosporium apiospermum* keratitis
4079 following phacoemulsification in a systemically well patient. *J Cataract Refract Surg* 2015; **41**(1): 230-3.

4080 726. Kalkan Akcay E, Acikgoz ZC, Can ME, Celikbilek N, Dereli Can G, Cagil N. [Fungal keratitis caused
4081 by *Scedosporium apiospermum*: first report from Turkey]. *Mikrobiyol Bul* 2013; **47**(4): 727-33.

4082 727. Kanafani ZA, Comair Y, Kanj SS. *Pseudallescheria boydii* cranial osteomyelitis and subdural
4083 empyema successfully treated with voriconazole: a case report and literature review. *Eur J Clin Microbiol*
4084 *Infect Dis* 2004; **23**(11): 836-40.

4085 728. Katragkou A, Dotis J, Kotsiou M, Tamiolaki M, Roilides E. Scedosporium apiospermum infection
4086 after near-drowning. *Mycoses* 2007; **50**(5): 412-21.

4087 729. Kennedy B, Larcombe R, Chaptini C, Gordon DL. Interaction between voriconazole and
4088 flucloxacillin during treatment of disseminated Scedosporium apiospermum infection. *J Antimicrob*
4089 *Chemother* 2015; **70**(7): 2171-3.

4090 730. Khan SA. A fatal pseudallescheria boydii brain abscess. *Neurosciences (Riyadh)* 2000; **5**(2): 125-7.

4091 731. Khoueir N, Verillaud B, Herman P. Scedosporium apiospermum invasive sinusitis presenting as
4092 extradural abscess. *Eur Ann Otorhinolaryngol Head Neck Dis* 2019; **136**(2): 119-21.

4093 732. Kim CM, Lim SC, Kim J, et al. Tenosynovitis caused by Scedosporium apiospermum infection
4094 misdiagnosed as an Alternaria species: a case report. *BMC Infect Dis* 2017; **17**(1): 72.

4095 733. Kim DY, Moon HI, Joe SG, Kim JG, Yoon YH, Lee JY. Recent Clinical Manifestation and Prognosis
4096 of Fungal Endophthalmitis: A 7-Year Experience at a Tertiary Referral Center in Korea. *J Korean Med Sci*
4097 2015; **30**(7): 960-4.

4098 734. Kim H, Ahn JY, Chung IY, et al. A case report of infectious scleritis with corneal ulcer caused by
4099 Scedosporium aurantiacum. *Medicine (Baltimore)* 2019; **98**(27): e16063.

4100 735. Kiratli H, Uzun O, Kiraz N, Eldem B. Scedosporium apiospermum chorioretinitis. *Acta Ophthalmol*
4101 *Scand* 2001; **79**(5): 540-2.

4102 736. Kishimoto I, Shinohara S, Ueda T, Tani S, Yoshimura H, Imai Y. Orbital apex syndrome secondary
4103 to a fungal nasal septal abscess caused by Scedosporium apiospermum in a patient with uncontrolled
4104 diabetes: a case report. *BMC Infect Dis* 2017; **17**(1): 649.

4105 737. Klinken EM, Stevenson BR, Kwok CHR, Hockley JA, Lucas M. Diffuse inflammatory aneurysmal
4106 aortitis secondary to Scedosporium apiospermum complex in an immunocompetent individual.
4107 *Pathology* 2019; **51**(3): 316-8.

4108 738. Klopfenstein KJ, Rosselet R, Termuhlen A, Powell D. Successful treatment of Scedosporium
4109 pneumonia with voriconazole during AML therapy and bone marrow transplantation. *Med Pediatr Oncol*
4110 2003; **41**(5): 494-5.

4111 739. Konishi M, Yonekawa S, Nakagawa C, et al. [Case of Scedosporium apiospermum cutaneous soft
4112 tissue infection treated with voriconazole]. *Kansenshogaku Zasshi* 2008; **82**(2): 82-5.

4113 740. Kooijman CM, Kampinga GA, de Hoog GS, Goudswaard WB, Reijnen MM. Successful treatment
4114 of Scedosporium aurantiacum osteomyelitis in an immunocompetent patient. *Surg Infect (Larchmt)*
4115 2007; **8**(6): 605-10.

4116 741. Kowacs PA, Soares Silvado CE, Monteiro de Almeida S, et al. Infection of the CNS by
4117 Scedosporium apiospermum after near drowning. Report of a fatal case and analysis of its confounding
4118 factors. *J Clin Pathol* 2004; **57**(2): 205-7.

4119 742. Kumashi PR, Safdar A, Chamilos G, Chemaly RF, Raad, II, Kontoyiannis DP. Fungal osteoarticular
4120 infections in patients treated at a comprehensive cancer centre: a 10-year retrospective review. *Clin*
4121 *Microbiol Infect* 2006; **12**(7): 621-6.

4122 743. Kusne S, Ariyanayagam-Baksh S, Strollo DC, Abernethy J. Invasive Scedosporium apiospermum
4123 infection in a heart transplant recipient presenting with multiple skin nodules and a pulmonary
4124 consolidation. *Transpl Infect Dis* 2000; **2**(4): 194-6.

4125 744. Lackner M, De Man FH, Eygendaal D, et al. Severe prosthetic joint infection in an
4126 immunocompetent male patient due to a therapy refractory Pseudallescheria apiosperma. *Mycoses*
4127 2011; **54 Suppl 3**: 22-7.

4128 745. Lahmer T, Messer M, Ehmer U, et al. Pseudallescheria boydii with Aspergillus fumigatus and
4129 Aspergillus terreus in a Critically Ill Hematopoietic Stem Cell Recipient with ARDS. *Mycopathologia* 2016;
4130 **181**(3-4): 267-71.

4131 746. Lainscak M, Hocevar A, Logar D, Beovic B, Matos T, Tomsic M. Subcutaneous infection with
4132 Pseudallescheria boydii in an immunocompromised patient. *Clin Rheumatol* 2007; **26**(6): 1023-4.

4133 747. Lam SM, Lau AC, Ma MW, Yam LY. Pseudallescheria boydii or Aspergillus fumigatus in a lady
4134 with an unresolving lung infiltrate, and a literature review. *Respirology* 2008; **13**(3): 478-80.

4135 748. Lamaris GA, Esmaeli B, Chamilos G, et al. Fungal endophthalmitis in a tertiary care cancer
4136 center: a review of 23 cases. *Eur J Clin Microbiol Infect Dis* 2008; **27**(5): 343-7.

4137 749. Larbcharoensub N, Chongtrakool P, Wirojtananugoon C, et al. Treatment of a brain abscess
4138 caused by *Scedosporium apiospermum* and *Phaeoacremonium parasiticum* in a renal transplant
4139 recipient. *Southeast Asian J Trop Med Public Health* 2013; **44**(3): 484-9.

4140 750. Larocco A, Jr., Barron JB. Endogenous *scedosporium apiospermum* endophthalmitis. *Retina*
4141 2005; **25**(8): 1090-3.

4142 751. Laurini JA, Carter JE, Kahn AG. Tricuspid valve and pacemaker endocarditis due to
4143 *Pseudallescheria boydii* (*Scedosporium apiospermum*). *South Med J* 2009; **102**(5): 515-7.

4144 752. Lavy D, Morin O, Venet G, Maugars Y, Prost A, Berthelot JM. *Pseudallescheria boydii* knee
4145 arthritis in a young immunocompetent adult two years after a compound patellar fracture. *Joint Bone*
4146 *Spine* 2001; **68**(6): 517-20.

4147 753. Leck A, Matheson M, Tuft S, Waheed K, Lagonowski H. *Scedosporium apiospermum*
4148 keratomycosis with secondary endophthalmitis. *Eye (Lond)* 2003; **17**(7): 841-3.

4149 754. Leechawengwongs M, Milindankura S, Liengudom A, Chanakul K, Viranuvatti K, Clongsusuek P.
4150 Multiple *Scedosporium apiospermum* brain abscesses after near-drowning successfully treated with
4151 surgery and long-term voriconazole: a case report. *Mycoses* 2007; **50**(6): 512-6.

4152 755. Levesque E, Rizk F, Noorah Z, et al. Detection of (1,3)-beta-d-Glucan for the Diagnosis of Invasive
4153 Fungal Infection in Liver Transplant Recipients. *Int J Mol Sci* 2017; **18**(4).

4154 756. Levine NB, Kurokawa R, Fichtenbaum CJ, Howington JA, Kuntz Ct. An immunocompetent patient
4155 with primary *Scedosporium apiospermum* vertebral osteomyelitis. *J Spinal Disord Tech* 2002; **15**(5): 425-
4156 30.

4157 757. Lin D, Kamili Q, Lai S, Musher DM, Hamill R. Cerebral *Scedosporium apiospermum* infection
4158 presenting with intestinal manifestations. *Infection* 2013; **41**(3): 723-6.

4159 758. Linares Sicilia MJ, Santos Lacomba M, Solis Cuesta F, SanchezPedraza R, Nieves Gomez T, Casal
4160 Roman M. *Scedosporium apiospermum* keratitis. *Rev Iberoam Micol* 2003; **20**(2): 68-70.

4161 759. Lindsley MD, Guarro J, Khairy RN, Williams J, Iqbal N, Pancholi P. *Pseudallescheria fusioidea*, a
4162 new cause of osteomyelitis. *J Clin Microbiol* 2008; **46**(6): 2141-3.

4163 760. Loh UL, Tai PY, Hussein A, F AQ. *Scedosporium apiospermum*: A Rare Cause of Aggressive Orbital
4164 Apex Syndrome. *Cureus* 2018; **10**(12): e3743.

4165 761. Lonser RR, Brodke DS, Dailey AT. Vertebral osteomyelitis secondary to *Pseudallescheria boydii*. *J*
4166 *Spinal Disord* 2001; **14**(4): 361-4.

4167 762. Luijk B, Ekkelenkamp MB, De Jong PA, et al. Effective Prolonged Therapy with Voriconazole in a
4168 Lung Transplant Recipient with Spondylodiscitis Induced by *Scedosporium apiospermum*. *Case Rep*
4169 *Infect Dis* 2011; **2011**: 460313.

4170 763. Luu KK, Scott IU, Miller D, Davis JL. Endogenous *Pseudallescheria boydii* endophthalmitis in a
4171 patient with ring-enhancing brain lesions. *Ophthalmic Surg Lasers* 2001; **32**(4): 325-9.

4172 764. Makino K, Fukushima S, Maruo K, Egawa K, Nishimoto K, Ihn H. Cutaneous hyalohyphomycosis
4173 by *Scedosporium apiospermum* in an immunocompromised patient. *Mycoses* 2011; **54**(3): 259-61.

4174 765. Malini A, Madhusudan NS, Sinhasan SP, Harthimath BC. A masquerading subcutaneous swelling
4175 caused by *Scedosporium apiospermum*: an emerging pathogen. *Indian J Pathol Microbiol* 2015; **58**(1):
4176 115-7.

4177 766. Malinowski MJ, Halandras P. Arterial reconstruction for atypical mycotic aneurysms. *Vasc*
4178 *Endovascular Surg* 2013; **47**(1): 45-7.

4179 767. Mancini N, Ossi CM, Perotti M, et al. Direct sequencing of *Scedosporium apiospermum* DNA in
4180 the diagnosis of a case of keratitis. *J Med Microbiol* 2005; **54**(Pt 9): 897-900.

4181 768. Marques DS, Pinho Vaz C, Branca R, et al. Rhizomucor and *scedosporium* infection post
4182 hematopoietic stem-cell transplant. *Case Rep Med* 2011; **2011**: 830769.

4183 769. Martinez-Morillo M, Mateo Soria L, Riveros Frutos A, Tejera Segura B. [Fungal osteoarticular
4184 infection: report of 5 cases]. *Med Clin (Barc)* 2013; **141**(9): 412-4.

4185 770. Matsumoto Y, Oh IT, Nagai A, Ohyama F, Ooishi T, Tsuboi R. Case of cutaneous *Scedosporium*
4186 *apiospermum* infection successfully treated with voriconazole. *J Dermatol* 2009; **36**(2): 98-102.

4187 771. Mays R, Gordon R, Wilson JM, et al. Persistent erythematous plaque after minor trauma in an
4188 immunocompromised woman. *Dermatol Online J* 2012; **18**(4): 2.

4189 772. Mazumder SA, Cleveland KO, Norwood J. Scedosporium apiospermum infection presenting as a
4190 pneumothorax and cavitary lung lesions in a patient with acquired immune deficiency syndrome. *South*
4191 *Med J* 2010; **103**(9): 960-2.

4192 773. Mei Y, Chen X, Sun K, Lv J, Sun H, Zhang J. Scedosporium apiospermum infection: lethal
4193 complication after extracorporeal cardiopulmonary resuscitation. *Perfusion* 2018; **33**(1): 71-3.

4194 774. Mellinghoff IK, Winston DJ, Mukwaya G, Schiller GJ. Treatment of Scedosporium apiospermum
4195 brain abscesses with posaconazole. *Clinical infectious diseases : an official publication of the Infectious*
4196 *Diseases Society of America* 2002; **34**(12): 1648-50.

4197 775. Mesfin FB, Tobin E, Adamo MA, Dirisio D. Fungal vertebral osteomyelitis due to Scedosporium
4198 apiospermum after near-drowning. *J Neurosurg Spine* 2008; **9**(1): 58-61.

4199 776. Messori A, Lanza C, De Nicola M, et al. Mycotic aneurysms as lethal complication of brain
4200 pseudallescheriasis in a near-drowned child: a CT demonstration. *AJNR Am J Neuroradiol* 2002; **23**(10):
4201 1697-9.

4202 777. Miele PS, Levy CS, Smith MA, et al. Primary cutaneous fungal infections in solid organ
4203 transplantation: a case series. *Am J Transplant* 2002; **2**(7): 678-83.

4204 778. Misselbrook GP, Lillie P, Thomas CP. An unusual pathogen in ambulatory care: two cases of
4205 Scedosporium soft tissue infections presenting as "unresponsive cellulitis". *Acute Med* 2016; **15**(2): 88-
4206 91.

4207 779. Mohan R, Gopakumar TS. Clinico-radiological improvement in an immunocompetent patient
4208 presented with scedosporium apiospermum osteomyelitis. *J Clin Orthop Trauma* 2016; **7**(Suppl 1): 134-
4209 7.

4210 780. Montejo M, Muniz ML, Zarraga S, et al. Case Reports. Infection due to Scedosporium
4211 apiospermum in renal transplant recipients: a report of two cases and literature review of central
4212 nervous system and cutaneous infections by Pseudallescheria boydii/Sc. apiospermum. *Mycoses* 2002;
4213 **45**(9-10): 418-27.

4214 781. Morio F, Horeau-Langlard D, Gay-Andrieu F, et al. Disseminated Scedosporium/Pseudallescheria
4215 infection after double-lung transplantation in patients with cystic fibrosis. *J Clin Microbiol* 2010; **48**(5):
4216 1978-82.

4217 782. Motokawa N, Miyazaki T, Hara A, et al. Pulmonary Scedosporium apiospermum Infection with
4218 Pulmonary Tumorlet in an Immunocompetent Patient. *Intern Med* 2018; **57**(23): 3485-90.

4219 783. Munoz P, Marin M, Tornero P, Martin Rabadan P, Rodriguez-Creixems M, Bouza E. Successful
4220 outcome of Scedosporium apiospermum disseminated infection treated with voriconazole in a patient
4221 receiving corticosteroid therapy. *Clin Infect Dis* 2000; **31**(6): 1499-501.

4222 784. Mursch K, Trnovec S, Ratz H, et al. Successful treatment of multiple Pseudallescheria boydii
4223 brain abscesses and ventriculitis/ependymitis in a 2-year-old child after a near-drowning episode. *Childs*
4224 *Nerv Syst* 2006; **22**(2): 189-92.

4225 785. Musk M, Chambers D, Chin W, Murray R, Gabbay E. Successful treatment of disseminated
4226 scedosporium infection in 2 lung transplant recipients: review of the literature and recommendations
4227 for management. *J Heart Lung Transplant* 2006; **25**(10): 1268-72.

4228 786. Nath R, Gogoi RN, Saikia L. Keratomycosis due to Scedosporium apiospermum. *Indian J Med*
4229 *Microbiol* 2010; **28**(4): 414-5.

4230 787. Negroni R, Arechavala AI, Maiolo E, et al. [Clinical cases in Medical Mycology. Case No. 29]. *Rev*
4231 *Iberoam Micol* 2007; **24**(4): 327-9.

4232 788. Nesky MA, McDougal EC, Peacock JE, Jr. Pseudallescheria boydii brain abscess successfully
4233 treated with voriconazole and surgical drainage: case report and literature review of central nervous
4234 system pseudallescheriasis. *Clin Infect Dis* 2000; **31**(3): 673-7.

4235 789. Ngai JC, Lam R, Ko FW, To KW, Hui DS. Pulmonary scedosporium infection as a complication of
4236 infliximab therapy for ankylosing spondylitis. *Thorax* 2009; **64**(2): 184.

4237 790. Nguyen BD. Pseudallescheriasis of the lung and central nervous system: multimodality imaging.
4238 *AJR Am J Roentgenol* 2001; **176**(1): 257-8.

4239 791. Nguyen CT, Raychaudhuri SP. SCEDOSPORIUM INFECTION IN A PATIENT WITH ANTI-TNFalpha
4240 THERAPY. *Indian J Dermatol* 2011; **56**(1): 82-3.

4241 792. Nonaka D, Yfantis H, Southall P, Sun CC. Pseudallescheriasis as an aggressive opportunistic
4242 infection in a bone marrow transplant recipient. *Arch Pathol Lab Med* 2002; **126**(2): 207-9.

4243 793. Nulens E, Eggink C, Rijs AJ, Wesseling P, Verweij PE. Keratitis caused by *Scedosporium*
4244 *apiospermum* successfully treated with a cornea transplant and voriconazole. *J Clin Microbiol* 2003;
4245 **41**(5): 2261-4.

4246 794. O'Bryan TA, Browne FA, Schonder JF. *Scedosporium apiospermum* (*Pseudallescheria boydii*)
4247 endocarditis. *J Infect* 2002; **44**(3): 189-92.

4248 795. Ochiai N, Shimazaki C, Uchida R, et al. Disseminated infection due to *Scedosporium*
4249 *apiospermum* in a patient with acute myelogenous leukemia. *Leuk Lymphoma* 2003; **44**(2): 369-72.

4250 796. O'Connor C, Fitzpatrick F, Looby S, O'Connell K. Beware of Rim-Enhancing Lesions: A Rare Case
4251 of Multiple *Scedosporium apiospermum* and Vancomycin-Resistant *Enterococcus faecium* Intra-Cranial
4252 Abscesses. *Surg Infect (Larchmt)* 2016; **17**(4): 500-1.

4253 797. O'Doherty M, Hannan M, Fulcher T. Voriconazole in the treatment of fungal osteomyelitis of the
4254 orbit in the immunocompromised host. *Orbit* 2005; **24**(4): 285-9.

4255 798. Ogata R, Hagiwara E, Shiihara J, Ogura T, Takahashi H, Kamei K. [A case of lung scedosporiosis
4256 successfully treated with monitoring of plasma voriconazole concentration level]. *Nihon Kokyuki Gakkai*
4257 *Zasshi* 2011; **49**(5): 388-92.

4258 799. Ogawa Y, Sato M, Tashiro M, et al. Rapid development of a mycotic aneurysm of the intracranial
4259 artery secondary to *Scedosporium apiospermum* sinusitis. *Medical mycology case reports* 2016; **14**: 30-
4260 2.

4261 800. Oh IK, Baek S, Huh K, Oh J. Periocular abscess caused by *Pseudallescheria boydii* after a posterior
4262 subtenon injection of triamcinolone acetonide. *Graefes Arch Clin Exp Ophthalmol* 2007; **245**(1): 164-6.

4263 801. Ong A, Blyth CC, Bency R, et al. Fatal mycotic aneurysms due to *Scedosporium* and
4264 *Pseudallescheria* infection. *J Clin Microbiol* 2011; **49**(5): 2067-71.

4265 802. Ouchi T, Sato T, Yoshizawa N, et al. [Case of cutaneous *Pseudallescheria boydii* infection caused
4266 by trauma]. *Nihon Ishinkin Gakkai Zasshi* 2008; **49**(2): 119-23.

4267 803. Ozkurt Y, Oral Y, Kulekci Z, Benzonana N, Ustaoglu R, Dogan OK. *Pseudallescheria boydii*
4268 keratitis. *J Pediatr Ophthalmol Strabismus* 2006; **43**(2): 114-5.

4269 804. Paajanen J, Halme M, Palomaki M, Anttila VJ. Disseminated *Scedosporium apiospermum* central
4270 nervous system infection after lung transplantation: A case report with successful recovery. *Medical*
4271 *mycology case reports* 2019; **24**: 37-40.

4272 805. Pagano L, Caira M, Candoni A, et al. The epidemiology of fungal infections in patients with
4273 hematologic malignancies: the SEIFEM-2004 study. *Haematologica* 2006; **91**(8): 1068-75.

4274 806. Panichpisal K, Nugent K, Sarria JC. Central nervous system pseudallescheriasis after near-
4275 drowning. *Clin Neurol Neurosurg* 2006; **108**(4): 348-52.

4276 807. Parta M, Hilligoss D, Kelly C, et al. Haploidentical Hematopoietic Cell Transplantation with Post-
4277 Transplant Cyclophosphamide in a Patient with Chronic Granulomatous Disease and Active Infection: A
4278 First Report. *J Clin Immunol* 2015; **35**(7): 675-80.

4279 808. Patel MS, Wright AJ, Kohn R, Markmann JF, Kotton CN, Vagefi PA. Successful long-term
4280 management of invasive cerebral fungal infection following liver transplantation. *Mycoses* 2015; **58**(3):
4281 181-6.

4282 809. Patel R, Orlandi RR. Fungal septal abscess complicating maxillary sinus fungus balls in an
4283 immunocompetent host. *Allergy Rhinol (Providence)* 2015; **6**(3): 184-7.

4284 810. Pennekamp PH, Diedrich O, Zhou H, Kraft CN. [Foot injury as a rare cause of scendosporiosis
4285 with fetal outcome]. *Unfallchirurg* 2003; **106**(10): 865-8.

4286 811. Perthroth MG, Miller J. *Pseudoallescheria boydii* pneumonia and empyema: a rare complication
4287 of heart transplantation cured with voriconazole. *J Heart Lung Transplant* 2004; **23**(5): 647-9.

4288 812. Perry HD, Doshi SJ, Donnenfeld ED, Bai GS. Topical cyclosporin A in the management of
4289 therapeutic keratoplasty for mycotic keratitis. *Cornea* 2002; **21**(2): 161-3.

4290 813. Ponchel C, Cassaing S, Linas MD, Arne JL, Fournie P. [Fungal keratitis caused by *Scedosporium*
4291 *apiospermum*]. *J Fr Ophthalmol* 2007; **30**(9): 933-7.

4292 814. Porte L, Khatibi S, Hajj LE, et al. Scedosporium apiospermum mycetoma with bone involvement
4293 successfully treated with voriconazole. *Trans R Soc Trop Med Hyg* 2006; **100**(9): 891-4.

4294 815. Posteraro P, Frances C, Didona B, Dorent R, Posteraro B, Fadda G. Persistent subcutaneous
4295 Scedosporium apiospermum infection. *Eur J Dermatol* 2003; **13**(6): 603-5.

4296 816. Poza G, Montoya J, Redondo C, et al. Meningitis caused by Pseudallescheria boydii treated with
4297 voriconazole. *Clin Infect Dis* 2000; **30**(6): 981-2.

4298 817. Rahman FU, Irfan M, Fasih N, Jabeen K, Sharif H. Pulmonary scedosporiosis mimicking
4299 aspergilloma in an immunocompetent host: a case report and review of the literature. *Infection* 2016;
4300 **44**(1): 127-32.

4301 818. Raj R, Frost AE. Scedosporium apiospermum fungemia in a lung transplant recipient. *Chest* 2002;
4302 **121**(5): 1714-6.

4303 819. Ramakrishnan S, Mandlik K, Sathe TS, Gubert J, Krishnan T, Baskaran P. Ocular infections caused
4304 by Scedosporium apiospermum: A case series. *Indian J Ophthalmol* 2018; **66**(1): 137-40.

4305 820. Ramos Martinez A, Orden Martinez B, Polo Laborda J, et al. [Slow onset septic arthritis by
4306 Scedosporium apiospermum after periarticular infiltration]. *Rev Iberoam Micol* 2012; **29**(4): 241-4.

4307 821. Raparia K, Powell SZ, Cernoch P, Takei H. Cerebral mycosis: 7-year retrospective series in a
4308 tertiary center. *Neuropathology* 2010; **30**(3): 218-23.

4309 822. Rathi HS, Venugopal A, Rengappa R, Ravindran M. Scedosporium Keratitis: An Experience From a
4310 Tertiary Eye Hospital in South India. *Cornea* 2016; **35**(12): 1575-7.

4311 823. Rathi M, Gundlapalli S, Ramachandran R, et al. A rare case of Cytomegalovirus, Scedosporium
4312 apiospermum and Mycobacterium tuberculosis in a renal transplant recipient. *BMC Infect Dis* 2014; **14**:
4313 259.

4314 824. Reimann D, Bussemaker E, Gross P. Successful treatment due to vacuum seal technique of a
4315 severe Scedosporium apiospermum skin infection in a renal transplant recipient. *Nephrol Dial*
4316 *Transplant* 2004; **19**(1): 245-8.

4317 825. Rogasi PG, Zanazzi M, Nocentini J, et al. Disseminated Scedosporium apiospermum infection in
4318 renal transplant recipient: long-term successful treatment with voriconazole: a case report. *Transplant*
4319 *Proc* 2007; **39**(6): 2033-5.

4320 826. Rollot F, Blanche P, Richaud-Thiriez B, et al. Pneumonia due to Scedosporium apiospermum in a
4321 patient with HIV infection. *Scand J Infect Dis* 2000; **32**(4): 439.

4322 827. Roy R, Panigrahi PK, Pal SS, Mukherjee A, Bhargava M. Post-traumatic Endophthalmitis
4323 Secondary to Keratomycosis Caused by Scedosporium apiospermum. *Ocul Immunol Inflamm* 2016;
4324 **24**(1): 107-9.

4325 828. Ruangchanasetr P, Lauhawata B, Leawseng S, Kitpanich S, Lumpaopong A, Thirakhupt P.
4326 Malignancy in renal transplant recipients: a single-center experience in Thailand. *J Med Assoc Thai* 2012;
4327 **95 Suppl 5**: S12-6.

4328 829. Ruinemans GM, Haagsma CJ, Hendrix R. Tenosynovitis caused by a pseudallescheria boydii
4329 infection and symptoms of reflex sympathetic dystrophy after a dog bite. *J Clin Rheumatol* 2011; **17**(7):
4330 363-4.

4331 830. Rumelt S, Cohen I, Lefler E, Rehany U. Corneal co-infection with Scedosporium apiospermum
4332 and Acanthamoeba after sewage-contaminated ocular injury. *Cornea* 2001; **20**(1): 112-6.

4333 831. Rynga D, Capoor MR, Varshney S, Naik M, Gupta V. Scedosporium apiospermum, an emerging
4334 pathogen in India: Case series and review of literature. *Indian J Pathol Microbiol* 2017; **60**(4): 550-5.

4335 832. Safdar A, Papadopoulos EB, Young JW. Breakthrough Scedosporium apiospermum
4336 (Pseudallescheria boydii) brain abscess during therapy for invasive pulmonary aspergillosis following
4337 high-risk allogeneic hematopoietic stem cell transplantation. Scedosporiasis and recent advances in
4338 antifungal therapy. *Transpl Infect Dis* 2002; **4**(4): 212-7.

4339 833. Sahi H, Avery RK, Minai OA, et al. Scedosporium apiospermum (Pseudoallescheria boydii)
4340 infection in lung transplant recipients. *J Heart Lung Transplant* 2007; **26**(4): 350-6.

4341 834. Santos T, Aguiar B, Santos L, et al. Invasive Fungal Infections After Kidney Transplantation: A
4342 Single-center Experience. *Transplant Proc* 2015; **47**(4): 971-5.

- 4343 835. Saracli MA, Erdem U, Gonlum A, Yildiran ST. Scedosporium apiospermum keratitis treated with
4344 itraconazole. *Medical mycology* 2003; **41**(2): 111-4.
- 4345 836. Sarva ST, Manjunath SK, Baldwin HS, Robins DB, Freire AX. Lung scedosporiosis in human
4346 immunodeficiency virus/acquired immunodeficiency syndrome. *Am J Med Sci* 2010; **339**(3): 300-3.
- 4347 837. Sateesh CS, Makannavar JH. Chronic sino-naso-orbital fungal infection due to Pseudallescheria
4348 boydii in a nonimmunocompromised host--a case report. *Indian J Pathol Microbiol* 2001; **44**(3): 359-61.
- 4349 838. Satirapoj B, Ruangkanchanasetr P, Treewatchareekorn S, Supasyndh O, Luesutthiviboon L,
4350 Supaporn T. Pseudallescheria boydii brain abscess in a renal transplant recipient: first case report in
4351 Southeast Asia. *Transplant Proc* 2008; **40**(7): 2425-7.
- 4352 839. Schaenman JM, DiGiulio DB, Mirels LF, et al. Scedosporium apiospermum soft tissue infection
4353 successfully treated with voriconazole: potential pitfalls in the transition from intravenous to oral
4354 therapy. *J Clin Microbiol* 2005; **43**(2): 973-7.
- 4355 840. Schiedler V, Scott IU, Flynn HW, Jr., Davis JL, Benz MS, Miller D. Culture-proven endogenous
4356 endophthalmitis: clinical features and visual acuity outcomes. *Am J Ophthalmol* 2004; **137**(4): 725-31.
- 4357 841. Scott M, Wanat K, Pappas-Taffer L. Sporotrichoid eruption in a patient after lung
4358 transplantation. Scedosporium apiospermum fungal thrombophlebitis and sporotrichoid nodules. *JAMA*
4359 *Dermatol* 2014; **150**(1): 83-4.
- 4360 842. Sen P, Gopal L, Sen PR. Intravitreal voriconazole for drug-resistant fungal endophthalmitis: case
4361 series. *Retina* 2006; **26**(8): 935-9.
- 4362 843. Shah SB, Murr AH, Lee KC. Nontraumatic nasal septal abscesses in the immunocompromised:
4363 etiology, recognition, treatment, and sequelae. *Am J Rhinol* 2000; **14**(1): 39-43.
- 4364 844. Shand JM, Albrecht RM, Burnett HF, 3rd, Miyake A. Invasive fungal infection of the midfacial and
4365 orbital complex due to Scedosporium apiospermum and mucormycosis. *J Oral Maxillofac Surg* 2004;
4366 **62**(2): 231-4.
- 4367 845. Shankar S, Biswas J, Gopal L, Bagyalakshmi R, Therese L, Borse NJ. Anterior chamber exudative
4368 mass due to Scedosporium apiospermum in an immunocompetent individual. *Indian J Ophthalmol* 2007;
4369 **55**(3): 226-7.
- 4370 846. Sharma A, Singh D. Scedosporium apiospermum causing brain abscess in a renal allograft
4371 recipient. *Saudi J Kidney Dis Transpl* 2015; **26**(6): 1253-6.
- 4372 847. Sheu R, Bricker AO, Sahi H, Mohammed TL. Pseudallescheria boydii (Scedosporium species) in 3
4373 lung transplant recipients: computed tomography findings and literature review. *J Comput Assist*
4374 *Tomogr* 2009; **33**(2): 247-52.
- 4375 848. Shoham S, Ostrander D, Marr K. Posaconazole liquid suspension in solid organ transplant
4376 recipients previously treated with voriconazole. *Transpl Infect Dis* 2015; **17**(3): 493-6.
- 4377 849. Shu T, Green JM, Orihuela E. Testicular involvement in disseminated fungal infection by
4378 Pseudallescheria boydii. *Urology* 2004; **63**(5): 981-2.
- 4379 850. Sireesha P, Manoj Kumar CH, Setty CR. Thyroid abscess due to Scedosporium apiospermum.
4380 *Indian J Med Microbiol* 2010; **28**(4): 409-11.
- 4381 851. Slone HW, Kontzialis M, Kiani B, Triola C, Oettel DJ, Bourekas EC. MRI with Magnetic Resonance
4382 Spectroscopy of multiple brain abscesses secondary to Scedosporium apiospermum in two
4383 immunocompromised patients. *Clin Imaging* 2013; **37**(2): 361-6.
- 4384 852. Sole A. [Scedosporium apiospermum disseminated infection in a single lung transplant
4385 recipient]. *Rev Iberoam Micol* 2011; **28**(3): 139-42.
- 4386 853. Sole A, Garcia-Robles AA, Jorda C, et al. Salvage therapy with topical posaconazole in lung
4387 transplant recipients with invasive Scedosporium infection. *Am J Transplant* 2018; **18**(2): 504-9.
- 4388 854. Soontrapa P, Larbcharoensub N, Luxameechanporn T, et al. Fungal rhinosinusitis: a retrospective
4389 analysis of clinicopathologic features and treatment outcomes at Ramathibodi Hospital. *Southeast Asian*
4390 *J Trop Med Public Health* 2010; **41**(2): 442-9.
- 4391 855. Sridhar MS, Garg P, Bansal AK, Sharma S. Fungal keratitis after laser in situ keratomileusis. *J*
4392 *Cataract Refract Surg* 2000; **26**(4): 613-5.
- 4393 856. Stalpers XL, Smink-Bol M, Verweij PE, Wesseling P, van Dijk GW. Fatal consequences of an ear
4394 infection. *Lancet* 2009; **373**(9675): 1658.

- 4395 857. Stelzmueller I, Lass-Floerl C, Geltner C, et al. Zygomycosis and other rare filamentous fungal
4396 infections in solid organ transplant recipients. *Transpl Int* 2008; **21**(6): 534-46.
- 4397 858. Stoneham AC, Stoneham SE, Wyllie SA, Pandya AN. Surgical resection of a rare cutaneous
4398 manifestation of *Scedosporium apiospermum* in a patient who underwent renal transplant. *BMJ Case*
4399 *Rep* 2017; **2017**.
- 4400 859. Stoyanova EI, Riemens A, Lokhorst HM, te Boome L, Rothova A. Absence of intraocular
4401 infections after hematopoietic stem cell transplantation at a single center: the experience with current
4402 preventive regimens. *Ocul Immunol Inflamm* 2014; **22**(2): 116-20.
- 4403 860. Stripeli F, Pasparakis D, Velegraki A, et al. *Scedosporium apiospermum* skeletal infection in an
4404 immunocompetent child. *Medical mycology* 2009; **47**(4): 441-4.
- 4405 861. Strunk T, Blume JH, Szeimies RM. [Deep skin infection with *Scedosporium apiospermum*-
4406 infection in a renal transplant patient]. *Hautarzt* 2015; **66**(3): 195-8.
- 4407 862. Stur-Hofmann K, Stos S, Saxa-Enenkel M, Rappersberger K. Primary cutaneous infection with
4408 *Scedosporium apiospermum* successfully treated with voriconazole. *Mycoses* 2011; **54**(4): e201-4.
- 4409 863. Sunagawa K, Uchino Y, Ishimoto S, et al. Mycotic pseudoaneurysm of a pulmonary artery branch
4410 caused by *Cladosporium*. *Pathol Int* 2018; **68**(1): 47-52.
- 4411 864. Sydnor MK, Kaushik S, Knight TE, Jr., Bridges CL, McCarty JM. Mycotic osteomyelitis due to
4412 *Scedosporium Apiospermum*: MR imaging-pathologic correlation. *Skeletal Radiol* 2003; **32**(11): 656-60.
- 4413 865. Symoens F, Knoop C, Schrooyen M, et al. Disseminated *Scedosporium apiospermum* infection in
4414 a cystic fibrosis patient after double-lung transplantation. *J Heart Lung Transplant* 2006; **25**(5): 603-7.
- 4415 866. Tabatabaei SA, Tabatabaei M, Soleimani M, Tafti ZF. Fungal keratitis caused by rare organisms. *J*
4416 *Curr Ophthalmol* 2018; **30**(1): 91-6.
- 4417 867. Takeuchi M, Yoshida C, Ota Y, Fujiwara Y. Deep skin infection of *Scedosporium apiospermum* in
4418 a patient with refractory idiopathic thrombocytopenic purpura. *Intern Med* 2011; **50**(12): 1339-43.
- 4419 868. Talbot TR, Hatcher J, Davis SF, Pierson RN, 3rd, Barton R, Dummer S. *Scedosporium*
4420 *apiospermum* pneumonia and sternal wound infection in a heart transplant recipient. *Transplantation*
4421 2002; **74**(11): 1645-7.
- 4422 869. Tammer I, Seibold M, Krause H, Tintelnot K, Konig W, Konig B. Successful topical therapy with
4423 voriconazole: pseudallescheriasis after injury. *J Trauma* 2007; **62**(5): 1295-7.
- 4424 870. Tan TY, Liou CW, Kung LC. Meningitis caused by *Pseudallescheria boydii*. *Chang Gung Med J*
4425 2004; **27**(3): 228-32.
- 4426 871. Tarabishy AB, Khatib OF, Nocero JR, Budev M, Kaiser PK. Ocular complications in patients with
4427 lung transplants. *Br J Ophthalmol* 2011; **95**(9): 1295-8.
- 4428 872. Tarrand JJ, Lichterfeld M, Warraich I, et al. Diagnosis of invasive septate mold infections. A
4429 correlation of microbiological culture and histologic or cytologic examination. *Am J Clin Pathol* 2003;
4430 **119**(6): 854-8.
- 4431 873. Thiagalingam S, Fernando GT, Tan K, O'Donnell BA, Weeks K, Branley M. Orbital apex syndrome
4432 secondary to *Pseudallescheria boydii* fungal sinusitis in an immunocompetent patient. *Clin Exp*
4433 *Ophthalmol* 2004; **32**(5): 545-7.
- 4434 874. Thomson S, Alibhai K, Winkelaar G, et al. Case report of vertebral osteomyelitis and mycotic
4435 abdominal aortic aneurysm caused by *Scedosporium apiospermum* in a lung transplant patient with
4436 cystic fibrosis. *Transplant Proc* 2015; **47**(1): 204-9.
- 4437 875. Tilakaratne D, Ryan E, Pearce A. Concurrent pyoderma gangrenosum and infection with
4438 *Scedosporium apiospermum*. *Australas J Dermatol* 2016; **57**(2): e46-8.
- 4439 876. Tintelnot K, Wagner N, Seibold M, de Hoog GS, Horre R. Re-identification of clinical isolates of
4440 the *Pseudallescheria boydii*-complex involved in near-drowning. *Mycoses* 2008; **51 Suppl 3**: 11-6.
- 4441 877. Tirado-Miranda R, Solera-Santos J, Brasero JC, Haro-Estarriol M, Cascales-Sanchez P, Iguualada JB.
4442 Septic arthritis due to *Scedosporium apiospermum*: case report and review. *J Infect* 2001; **43**(3): 210-2.
- 4443 878. Todokoro D, Hoshino J, Yo A, Makimura K, Hirato J, Akiyama H. *Scedosporium apiospermum*
4444 infectious scleritis following posterior subtenon triamcinolone acetate injection: a case report and
4445 literature review. *BMC Ophthalmol* 2018; **18**(1): 40.

4446 879. Torres-Sanchez MJ, Hernandez-Garcia E, Gomez-Sanchez J, et al. Severe *Scedosporium*
4447 *apiospermum* Infection in a Recent Renal Transplant Recipient: Case Report. *Transplant Proc* 2018;
4448 **50**(2): 683-4.

4449 880. Toth EJ, Nagy GR, Homa M, et al. Recurrent *Scedosporium apiospermum* mycetoma successfully
4450 treated by surgical excision and terbinafine treatment: a case report and review of the literature. *Ann*
4451 *Clin Microbiol Antimicrob* 2017; **16**(1): 31.

4452 881. Safdar A. Progressive cutaneous hyalohyphomycosis due to *Paecilomyces lilacinus*: rapid
4453 response to treatment with caspofungin and itraconazole. *Clin Infect Dis* 2002; **34**(10): 1415-7.

4454 882. Tsukagoshi S, Kasahara H, Sekine A, Fujita Y, Tsutsumi Y, Ikeda Y. [A case of filamentous fungal
4455 infection showing tumor-like expansion in the cisterns]. *Rinsho Shinkeigaku* 2014; **54**(10): 814-8.

4456 883. Uenotsuchi T, Moroi Y, Urabe K, et al. Cutaneous *Scedosporium apiospermum* infection in an
4457 immunocompromised patient and a review of the literature. *Acta Derm Venereol* 2005; **85**(2): 156-9.

4458 884. Vanhooteghem O, Gillard P, Dezfoulian B, de la Brassinne M. *Scedosporium apiospermum*
4459 septicemia following a wedge excision of an ingrown toenail. *Int J Dermatol* 2009; **48**(10): 1137-9.

4460 885. Vanzzini-Zago V, Corredor-Casas S, Rodriguez-Reyes A, et al. Endophthalmitis of probable
4461 endogenous origin caused by *Scedosporium boydii*: A case report. *Rev Iberoam Micol* 2016; **33**(2): 122-5.

4462 886. Vasoo S, Yeo SB, Lim PL, Ang BS, Lye DC. Efficacy of voriconazole for *Scedosporium*
4463 *apiospermum* skull base osteomyelitis: case report and literature review. *Int J Antimicrob Agents* 2008;
4464 **31**(2): 184-5.

4465 887. Vazquez R, Vazquez-Guillamet MC, Suarez J, Mooney J, Montoya JG, Dhillon GS. Invasive mold
4466 infections in lung and heart-lung transplant recipients: Stanford University experience. *Transpl Infect Dis*
4467 2015; **17**(2): 259-66.

4468 888. Verghese S, Padmaja P, Chellamma MT, Leelavathy S, Nayar P. Prosthetic valve endocarditis
4469 caused by *Scedosporium apiospermum*. *Indian J Med Microbiol* 2005; **23**(4): 264-6.

4470 889. Vergoulidou M, Krause L, Foerster MH, Thiel E, Schwartz S. Endogenous filamentous fungal
4471 endophthalmitis--single-centre survey in patients with acute leukaemia or postallogeic stem cell
4472 transplantation and review of the literature. *Mycoses* 2011; **54**(6): e704-11.

4473 890. Wang H, Liu Y, Chen SC, Long Y, Kong F, Xu YC. *Chaetomium atrobrunneum* and *Aspergillus*
4474 *fumigatus* in multiple tracheal aspirates: Copathogens or symbiosis. *J Microbiol Immunol Infect* 2016;
4475 **49**(2): 281-5.

4476 891. Watanabe S, Anzawa K, Mochizuki T. Case of mycotic cyst caused by *Scedosporium*
4477 *apiospermum* developed liver dysfunction following administration of voriconazole. *J Dermatol* 2017;
4478 **44**(11): e296-e7.

4479 892. Williams JR, Tenforde MW, Chan JD, Ko A, Graham SM. Safety and clinical response of
4480 intraventricular caspofungin for *Scedosporium apiospermum* complex central nervous system infection.
4481 *Medical mycology case reports* 2016; **13**: 1-4.

4482 893. Wilson HL, Kennedy KJ. *Scedosporium apiospermum* brain abscesses in an immunocompetent
4483 man with silicosis. *Medical mycology case reports* 2013; **2**: 75-8.

4484 894. Xiao W, Han P, Xu Z, Huang M. Pulmonary scedosporiosis in a patient with acute hematopoietic
4485 failure: Diagnosis aided by next-generation sequencing. *Int J Infect Dis* 2019; **85**: 114-6.

4486 895. Yoneda K, Nakai K, Moriue T, et al. *Scedosporium apiospermum* skin infection mimicking
4487 tuberculous xanthoma. *J Dermatol* 2012; **39**(3): 316-8.

4488 896. Yoon S, Kim S, Lee KA, Kim H. [A case of *Scedosporium apiospermum* keratitis confirmed by a
4489 molecular genetic method]. *Korean J Lab Med* 2008; **28**(4): 307-11.

4490 897. Yu Z, Hu L, Jiang M, et al. Dermatic *Scedosporium apiospermum* infection after autologous bone
4491 marrow transplantation. *Intern Med* 2013; **52**(6): 689-93.

4492 898. Zaas D. Cases from the Osler Medical Service at Johns Hopkins University. *Scedosporium*
4493 *apiospermum* mycetoma of the lung. *Am J Med* 2002; **113**(9): 760-2.

4494 899. Tammer I, Tintelnot K, Braun-Dullaes RC, et al. Infections due to
4495 *Pseudallescheria/Scedosporium* species in patients with advanced HIV disease--a diagnostic and
4496 therapeutic challenge. *Int J Infect Dis* 2011; **15**(6): e422-9.

4497 900. Mina S, Marot-Leblond A, Cimon B, et al. Purification and characterization of a mycelial catalase
4498 from *Scedosporium boydii*, a useful tool for specific antibody detection in patients with cystic fibrosis.
4499 *Clin Vaccine Immunol* 2015; **22**(1): 37-45.

4500 901. Nagano Y, Elborn JS, Millar BC, et al. Comparison of techniques to examine the diversity of fungi
4501 in adult patients with cystic fibrosis. *Medical mycology* 2010; **48**(1): 166-76.e1.

4502 902. Hedayati MT, Tavakoli M, Maleki M, et al. Fungal epidemiology in cystic fibrosis patients with a
4503 special focus on *Scedosporium* species complex. *Microb Pathog* 2019; **129**: 168-75.

4504 903. Lackner M, Najafzadeh MJ, Sun J, Lu Q, Hoog GS. Rapid identification of *Pseudallescheria* and
4505 *Scedosporium* strains by using rolling circle amplification. *Appl Environ Microbiol* 2012; **78**(1): 126-33.

4506 904. Buelow DR, Gu Z, Walsh TJ, Hayden RT. Evaluation of multiplexed PCR and liquid-phase array for
4507 identification of respiratory fungal pathogens. *Medical mycology* 2012; **50**(7): 775-80.

4508 905. Matray O, Mouhajir A, Giraud S, et al. Semi-automated repetitive sequence-based PCR
4509 amplification for species of the *Scedosporium apiospermum* complex. *Medical mycology* 2016; **54**(4):
4510 409-19.

4511 906. Guinea J, Pelaez T, Recio S, Torres-Narbona M, Bouza E. In vitro antifungal activities of
4512 isavuconazole (BAL4815), voriconazole, and fluconazole against 1,007 isolates of zygomycete, *Candida*,
4513 *Aspergillus*, *Fusarium*, and *Scedosporium* species. *Antimicrobial agents and chemotherapy* 2008; **52**(4):
4514 1396-400.

4515 907. Lackner M, Hagen F, Meis JF, et al. Susceptibility and diversity in the therapy-refractory genus
4516 *scedosporium*. *Antimicrobial agents and chemotherapy* 2014; **58**(10): 5877-85.

4517 908. Lackner M, de Hoog GS, Verweij PE, et al. Species-specific antifungal susceptibility patterns of
4518 *Scedosporium* and *Pseudallescheria* species. *Antimicrobial agents and chemotherapy* 2012; **56**(5): 2635-
4519 42.

4520 909. Espinel-Ingroff A, Fothergill A, Ghannoum M, et al. Quality control and reference guidelines for
4521 CLSI broth microdilution susceptibility method (M 38-A document) for amphotericin B, itraconazole,
4522 posaconazole, and voriconazole. *J Clin Microbiol* 2005; **43**(10): 5243-6.

4523 910. Zimmerli W. Clinical practice. Vertebral osteomyelitis. *N Engl J Med* 2010; **362**(11): 1022-9.

4524 911. Walts AE. *Pseudallescheria*: an underdiagnosed fungus? *Diagn Cytopathol* 2001; **25**(3): 153-7.

4525 912. Parize P, Boussaud V, Poinsignon V, et al. Clinical outcome of cystic fibrosis patients colonized by
4526 *Scedosporium* species following lung transplantation: A single-center 15-year experience. *Transpl Infect*
4527 *Dis* 2017; **19**(5).

4528 913. Girmenia C, Luzi G, Monaco M, Martino P. Use of voriconazole in treatment of *Scedosporium*
4529 *apiospermum* infection: case report. *J Clin Microbiol* 1998; **36**(5): 1436-8.

4530 914. Tamm M, Malouf M, Glanville A. Pulmonary *scedosporium* infection following lung
4531 transplantation. *Transpl Infect Dis* 2001; **3**(4): 189-94.

4532 915. Moloney TP, Park J. *Pseudallescheria* endophthalmitis: four cases over 15 years in Queensland,
4533 Australia, and a review of the literature. *Retina* 2014; **34**(8): 1683-701.

4534 916. Sarvat B, Sarria JC. Implantable cardioverter-defibrillator infection due to *Scedosporium*
4535 *apiospermum*. *J Infect* 2007; **55**(4): e109-13.

4536 917. Mellinghoff IK, Winston DJ, Mukwaya G, Schiller GJ. Treatment of *Scedosporium apiospermum*
4537 brain abscesses with posaconazole. *Clinical infectious diseases : an official publication of the Infectious*
4538 *Diseases Society of America* 2002; **34**(12): 1648-50.

4539 918. Schwartz S, Reisman A, Troke PF. The efficacy of voriconazole in the treatment of 192 fungal
4540 central nervous system infections: a retrospective analysis. *Infection* 2011; **39**(3): 201-10.

4541 919. Caira M, Girmenia C, Valentini CG, et al. *Scedosporiosis* in patients with acute leukemia: a
4542 retrospective multicenter report. *Haematologica* 2008; **93**(1): 104-10.

4543 920. Salamat AA, Archer C, Basarab A, et al. *Scedosporium apiospermum* causing otomycosis in an
4544 immunocompetent child with tympanostomy tubes: Management of this rare entity. *Int J Pediatr*
4545 *Otorhinolaryngol* 2015; **79**(10): 1785-7.

4546 921. Jabado N, Casanova JL, Haddad E, et al. Invasive pulmonary infection due to *Scedosporium*
4547 *apiospermum* in two children with chronic granulomatous disease. *Clin Infect Dis* 1998; **27**(6): 1437-41.

- 4548 922. Brandt ME, Warnock DW. Epidemiology, clinical manifestations, and therapy of infections
4549 caused by dematiaceous fungi. *J Chemother* 2003; **15 Suppl 2**: 36-47.
- 4550 923. Revankar SG, Patterson JE, Sutton DA, Pullen R, Rinaldi MG. Disseminated phaeohyphomycosis:
4551 review of an emerging mycosis. *Clinical infectious diseases : an official publication of the Infectious*
4552 *Diseases Society of America* 2002; **34(4)**: 467-76.
- 4553 924. Revankar SG, Sutton DA, Rinaldi MG. Primary central nervous system phaeohyphomycosis: a
4554 review of 101 cases. *Clin Infect Dis* 2004; **38(2)**: 206-16.
- 4555 925. Revankar SG, Sutton DA. Melanized fungi in human disease. *Clin Microbiol Rev* 2010; **23(4)**: 884-
4556 928.
- 4557 926. Ferrandiz-Pulido C, Martin-Gomez MT, Repiso T, et al. Cutaneous infections by dematiaceous
4558 opportunistic fungi: Diagnosis and management in 11 solid organ transplant recipients. *Mycoses* 2019;
4559 **62(2)**: 121-7.
- 4560 927. Isa-Isa R, Garcia C, Isa M, Arenas R. Subcutaneous phaeohyphomycosis (mycotic cyst). *Clin*
4561 *Dermatol* 2012; **30(4)**: 425-31.
- 4562 928. Satpathy G, Ahmed NH, Nayak N, et al. Spectrum of mycotic keratitis in north India: Sixteen
4563 years study from a tertiary care ophthalmic centre. *J Infect Public Health* 2019; **12(3)**: 367-71.
- 4564 929. Severo CB, Oliveira Fde M, Pilar EF, Severo LC. Phaeohyphomycosis: a clinical-epidemiological
4565 and diagnostic study of eighteen cases in Rio Grande do Sul, Brazil. *Mem Inst Oswaldo Cruz* 2012; **107(7)**:
4566 854-8.
- 4567 930. Garg N, Devi IB, Vajramani GV, et al. Central nervous system cladospiriosis: an account of ten
4568 culture-proven cases. *Neurol India* 2007; **55(3)**: 282-8.
- 4569 931. McCarthy M, Rosengart A, Schuetz AN, Kontoyiannis DP, Walsh TJ. Mold infections of the central
4570 nervous system. *The New England journal of medicine* 2014; **371(2)**: 150-60.
- 4571 932. Smith RM, Schaefer MK, Kainer MA, et al. Fungal infections associated with contaminated
4572 methylprednisolone injections. *N Engl J Med* 2013; **369(17)**: 1598-609.
- 4573 933. Velasco J, Revankar S. CNS Infections Caused by Brown-Black Fungi. *J Fungi (Basel)* 2019; **5(3)**.
- 4574 934. Berger JS, Cusumano LR, Derosé JJ, Sarwar UN. Exophiala (Wangiella) dermatitidis Prosthetic
4575 Aortic Valve Endocarditis and Prosthetic Graft Infection in an Immune Competent Patient. *Case Rep*
4576 *Infect Dis* 2017; **2017**: 4839314.
- 4577 935. Patel AK, Patel KK, Darji P, Singh R, Shivaprakash MR, Chakrabarti A. Exophiala dermatitidis
4578 endocarditis on native aortic valve in a postrenal transplant patient and review of literature on E.
4579 dermatitidis infections. *Mycoses* 2013; **56(3)**: 365-72.
- 4580 936. Guedri Y, Dammek N, Yaacoub A, et al. Alternaria alternata peritonitis in a patient undergoing
4581 continuous ambulatory peritoneal dialysis. *Saudi J Kidney Dis Transpl* 2017; **28(6)**: 1440-2.
- 4582 937. Liu Y, Gong W, Yu Y, Jiang L. Exserohilum Peritonitis in Peritoneal Dialysis in Northern China: A
4583 Case Report. *Perit Dial Int* 2019; **39(2)**: 175-6.
- 4584 938. Subramanyam H, Elumalai R, Kindo AJ, Periasamy S. Curvularia lunata, a rare fungal peritonitis in
4585 continuous ambulatory peritoneal dialysis (CAPD); a rare case report. *J Nephroarmacol* 2016; **5(1)**: 61-
4586 2.
- 4587 939. Campigotto A, Richardson SE, Sebert M, McElvania TeKippe E, Chakravarty A, Doern CD. Low
4588 Utility of Pediatric Isolator Blood Culture System for Detection of Fungemia in Children: a 10-Year
4589 Review. *J Clin Microbiol* 2016; **54(9)**: 2284-7.
- 4590 940. Chakrabarti A, Kaur H, Rudramurthy SM, et al. Brain abscess due to Cladophialophora bantiana:
4591 a review of 124 cases. *Medical mycology* 2016; **54(2)**: 111-9.
- 4592 941. Abbey AM, Shah NV, Forster RK, Suh LH. Infectious Pseudomonas and Bipolaris scleritis
4593 following history of pterygium surgery. *Indian J Ophthalmol* 2016; **64(9)**: 674-6.
- 4594 942. Abdolrasouli A, Gonzalo X, Jatan A, et al. Subcutaneous Phaeohyphomycosis Cyst Associated
4595 with Medicopsis romeroi in an Immunocompromised Host. *Mycopathologia* 2016; **181(9-10)**: 717-21.
- 4596 943. Adamopoulou A, Sakellaris D, Koronis S, et al. Rare Persistent Corneal Infection by Phoma sp. - A
4597 Case Report. *Ophthalmol Ther* 2019; **8(1)**: 143-8.
- 4598 944. Agarwal R, Kalita J, Marak RS, Misra UK. Spectrum of fungal infection in a neurology tertiary care
4599 center in India. *Neurol Sci* 2012; **33(6)**: 1305-10.

4600 945. Aggarwal A, Salunke P, Mohindra S, Garg R, Radotra BD. A case of cerebral phaeohyphomycosis in
4601 an immunocompetent patient: emphasis on intraoperative findings. *Neurol India* 2014; **62**(5): 551-2.

4602 946. Aggarwal S, Yamaguchi T, Dana R, Hamrah P. Exophiala phaeomuriformis Fungal Keratitis: Case
4603 Report and In Vivo Confocal Microscopy Findings. *Eye Contact Lens* 2017; **43**(2): e4-e6.

4604 947. Ahmad M, Jacobs D, Wu HH, et al. Cladophialophora Bantiana : A Rare Intracerebral Fungal
4605 Abscess-Case Series and Review of Literature. *Surg J (N Y)* 2017; **3**(2): e62-e8.

4606 948. Aizawa T, Domoto T, Aoki S, Azuma R, Kiyosawa T. Phaeoacremonium Tenosynovitis of the
4607 Wrist. *J Hand Surg Am* 2017; **42**(5): 393 e1- e3.

4608 949. Alabaz D, Kibar F, Arikan S, et al. Systemic phaeohyphomycosis due to Exophiala (Wangiella) in
4609 an immunocompetent child. *Med Mycol* 2009; **47**(6): 653-7.

4610 950. Alastruey-Izquierdo A, Cuesta I, Ros L, Mellado E, Rodriguez-Tudela JL. Antifungal susceptibility
4611 profile of clinical Alternaria spp. identified by molecular methods. *J Antimicrob Chemother* 2011; **66**(11):
4612 2585-7.

4613 951. Alayeto Ortega J, Alier Fabrego A, Puig Verdie L, Sorli Redo ML, Horcajada Gallego JP, Portillo
4614 Bordonabe ME. [Subcutaneous phaeohyphomycosis caused by Phaeoacremonium parasiticum]. *Rev
4615 Iberoam Micol* 2015; **32**(4): 265-8.

4616 952. Alex D, Li D, Calderone R, Peters SM. Identification of Curvularia lunata by polymerase chain
4617 reaction in a case of fungal endophthalmitis. *Medical mycology case reports* 2013; **2**: 137-40.

4618 953. Alhmali N, Lindenlaub P, Ghebremedhin B, Franke I, Gollnick H, Bonnekoh B. Deep cutaneous
4619 mycosis due to Alternaria infectoria after liver transplantation: successful treatment with fluconazole.
4620 *Eur J Dermatol* 2013; **23**(1): 100-2.

4621 954. Aljuboori Z, Hruska R, Yaseen A, Arnold F, Wojda B, Nauta H. Fungal brain abscess caused by
4622 "Black Mold" (Cladophialophora bantiana) - A case report of successful treatment with an emphasis on
4623 how fungal brain abscess may be different from bacterial brain abscess. *Surg Neurol Int* 2017; **8**: 46.

4624 955. Alonso R, Pisa D, Fernandez-Fernandez AM, Carrasco L. Infection of Fungi and Bacteria in Brain
4625 Tissue From Elderly Persons and Patients With Alzheimer's Disease. *Front Aging Neurosci* 2018; **10**: 159.

4626 956. Al-Tawfiq JA, Boukhamseen A. Cerebral phaeohyphomycosis due to Rhinocladiella mackenziei
4627 (formerly Ramichloridium mackenziei): case presentation and literature review. *J Infect Public Health*
4628 2011; **4**(2): 96-102.

4629 957. Amazan E, Desbois N, Fidelin G, et al. [First case of phaeohyphomycosis due to Pleurostoma
4630 ootheca in a kidney transplant recipient in Martinique (French West Indies)]. *Med Sante Trop* 2014;
4631 **24**(3): 323-5.

4632 958. Andhavarapu S, Tan WW. Medical image. papules of unknown aetiology. Disseminated
4633 Curvularia. *N Z Med J* 2012; **125**(1361): 102-4.

4634 959. Andrade SL, Leal AFG, Filho AML, Macedo DPC, Abreu ELM, Neves RP. Oral phaeohyphomycosis
4635 in a patient with squamocellular carcinoma of the lip: second case report. *Braz J Microbiol* 2017; **48**(2):
4636 208-10.

4637 960. Angurana SK, Suthar R, Mehta A, et al. Cerebral Phaeohyphomycosis: Fulminant Encephalitic
4638 Presentation. *Indian J Pediatr* 2017; **84**(12): 955-6.

4639 961. Aoyama Y, Nomura M, Yamanaka S, Ogawa Y, Kitajima Y. Subcutaneous phaeohyphomycosis
4640 caused by Exophiala xenobiotica in a non-Hodgkin lymphoma patient. *Medical mycology* 2009; **47**(1): 95-
4641 9.

4642 962. Aragon-Miguel R, Calleja-Algarra A, Morales-Raya C, et al. Alternaria infectoria skin infection in a
4643 renal transplant recipient: an emerging phaeohyphomycosis of occidental countries? *Int J Dermatol*
4644 2017; **56**(7): e153-e5.

4645 963. Aranegui B, Feal C, Garcia CP, et al. Subcutaneous phaeohyphomycosis caused by Exophiala
4646 jeanselmei treated with wide surgical excision and posaconazole: case report. *Int J Dermatol* 2013;
4647 **52**(2): 255-6.

4648 964. Arango-Franco CA, Moncada-Velez M, Beltran CP, et al. Early-Onset Invasive Infection Due to
4649 Corynespora cassiicola Associated with Compound Heterozygous CARD9 Mutations in a Colombian
4650 Patient. *J Clin Immunol* 2018; **38**(7): 794-803.

4651 965. Arora R, Gupta D, Goyal J, Kaur R. Voriconazole versus natamycin as primary treatment in fungal
4652 corneal ulcers. *Clin Exp Ophthalmol* 2011; **39**(5): 434-40.

4653 966. Asahina A, Kobayashi M, Nakano K, et al. Deep cutaneous infection with *Microsphaeropsis*
4654 *arundinis*: report of two Japanese cases. *Acta Derm Venereol* 2015; **95**(7): 855-7.

4655 967. Astolfo MF, Canazares P, Majek E, et al. [Invasive acute sinusitis by *Exserohilum rostratum* in a
4656 patient with medullary relapse of acute lymphoblastic leukemia]. *Arch Argent Pediatr* 2018; **116**(4):
4657 e594-e8.

4658 968. Atalay MA, Koc AN, Koyuncu S, Ulu Kilic A, Kurtsoy A, Alp Mese E. [Cladophilaphora bantiana
4659 brain abscess treated with voriconazole in an immunocompetent patient]. *Mikrobiyol Bul* 2014; **48**(3):
4660 501-6.

4661 969. Aydin M, Ozcelik U, Cevik H, Cinar O, Evren E, Demirag A. Multiple Brain Abscesses Due to
4662 *Phialemonium* in a Renal Transplant Recipient: First Case Report in the Literature. *Exp Clin Transplant*
4663 2015; **13 Suppl 3**: 77-80.

4664 970. Babu K, Murthy PR, Prakash PY, et al. Chronic endophthalmitis due to *Pyrenocheta romeroi* in an
4665 immunocompetent host--a case report from southern India. *Retin Cases Brief Rep* 2014; **8**(3): 197-9.

4666 971. Badali H, Chander J, Bansal S, et al. First autochthonous case of *Rhinocladiella mackenziei*
4667 cerebral abscess outside the Middle East. *J Clin Microbiol* 2010; **48**(2): 646-9.

4668 972. Badali H, Chander J, Bayat M, et al. Multiple subcutaneous cysts due to *Exophiala spinifera* in an
4669 immunocompetent patient. *Medical mycology* 2012; **50**(2): 207-13.

4670 973. Badali H, Chander J, Gupta A, et al. Fatal cerebral phaeohyphomycosis in an immunocompetent
4671 individual due to *Thielavia subthermophila*. *J Clin Microbiol* 2011; **49**(6): 2336-41.

4672 974. Badali H, de Hoog GS, Curfs-Breuker I, Klaassen CH, Meis JF. Use of amplified fragment length
4673 polymorphism to identify 42 *Cladophialophora* strains related to cerebral phaeohyphomycosis with in
4674 vitro antifungal susceptibility. *J Clin Microbiol* 2010; **48**(7): 2350-6.

4675 975. Badali H, Hedayati MT, Bahoosh M, et al. *Exophiala oligosperma* involved in a refractory chronic
4676 rhinosinusitis. *Eur Rev Med Pharmacol Sci* 2011; **15**(3): 319-23.

4677 976. Badiee P, Gandomi B, Sabz G, Khodami B, Choopanizadeh M, Jafarian H. Evaluation of nested
4678 PCR in diagnosis of fungal rhinosinusitis. *Iran J Microbiol* 2015; **7**(1): 62-6.

4679 977. Baer RA, Killen JP, Cho Y, Mantha M. Non-candidal fungal peritonitis in Far North Queensland: a
4680 case series. *Perit Dial Int* 2013; **33**(5): 559-64.

4681 978. Bagla P, Loeffelholz M, Blanton LS. Cerebral phaeohyphomycosis by *Fonsecaea monopora*:
4682 Report in a patient with AIDS and a ring enhancing lesion. *Medical mycology case reports* 2016; **12**: 4-7.

4683 979. Bajwa R, Wojciechowski AL, Hsiao CB. Cutaneous alternariosis in a renal transplant patient
4684 successfully treated with posaconazole: Case report and literature review. *Medical mycology case*
4685 *reports* 2017; **15**: 16-20.

4686 980. Bakhshizadeh M, Hashemian HR, Najafzadeh MJ, Dolatabadi S, Zarrinfar H. First report of
4687 rhinosinusitis caused by *Neoscytalidium dimidiatum* in Iran. *J Med Microbiol* 2014; **63**(Pt 7): 1017-9.

4688 981. Bakri SJ, Omar AF. Delayed scleral buckle infection due to *Alternaria* species. *Semin Ophthalmol*
4689 2013; **28**(1): 9-10.

4690 982. Balla A, Pierson J, Hugh J, Wojewoda C, Gibson P, Greene L. Disseminated cutaneous *Curvularia*
4691 infection in an immunocompromised host; diagnostic challenges and experience with voriconazole. *J*
4692 *Cutan Pathol* 2016; **43**(4): 383-7.

4693 983. Balne PK, Nalamada S, Kodiganti M, Taneja M. Fungal keratitis caused by *Chaetomium*
4694 *atrobrunneum*. *Cornea* 2012; **31**(1): 94-5.

4695 984. Baradkar VP, Kumar S. Subcutaneous granulomatous infection caused by *phaeoacremonium*
4696 *infalities* on foot. *Indian J Dermatol* 2011; **56**(2): 244-5.

4697 985. Baradkar VP, Mathur M, Kumar S. Phaeohyphomycosis of subcutaneous tissue caused by
4698 *Phaeoacremonium parasiticum*. *Indian J Med Microbiol* 2009; **27**(1): 66-9.

4699 986. Barde F, Billaud E, Goldwirt L, et al. Low Central Nervous System Posaconazole Concentrations
4700 during Cerebral Phaeohyphomycosis. *Antimicrob Agents Chemother* 2019; **63**(11).

4701 987. Bashir G, Hussain W, Rizvi A. *Bipolaris hawaiiensis* keratomycosis and endophthalmitis.
4702 *Mycopathologia* 2009; **167**(1): 51-3.

4703 988. Batra N, Kaur H, Mohindra S, Singh S, Shamanth AS, Rudramurthy SM. Cladosporium
4704 sphaerospermum causing brain abscess, a saprophyte turning pathogen: Case and review of published
4705 reports. *J Mycol Med* 2019; **29**(2): 180-4.

4706 989. Bay C, Gonzalez T, Munoz G, Legarraga P, Vizcaya C, Abarca K. [Nasal phaeohyphomycosis by
4707 *Curvularia spicifera* in pediatric patient with neutropenia and acute myeloid leukemia]. *Rev Chilena*
4708 *Infectol* 2017; **34**(3): 280-6.

4709 990. Berbel RF, Casella AM, de Freitas D, Hofling-Lima AL. *Curvularia lunata* endophthalmitis. *J Ocul*
4710 *Pharmacol Ther* 2011; **27**(5): 535-7.

4711 991. Berger AP, Little AJ, Wanat KA. Circumscribed nodule in a renal transplant patient. *Cutis* 2016;
4712 **98**(2): 81;98;100.

4713 992. Bermudez-Ruiz MP, Gomez-Moyano E, Sainz-Rodriguez R, Garin-Ferreira R. Infectious keratitis in
4714 a patient with KID syndrome. *Enferm Infecc Microbiol Clin* 2019; **37**(1): 56-7.

4715 993. Bernasconi M, Voinea C, Hauser PM, Nicod LP, Lazor R. *Ochroconis gallopava* bronchitis
4716 mimicking haemoptysis in a patient with bronchiectasis. *Respir Med Case Rep* 2017; **22**: 215-7.

4717 994. Bhala S, Narang S, Sood S, Mithal C, Arya SK, Gupta V. Microbial contamination in open globe
4718 injury. *Nepal J Ophthalmol* 2012; **4**(1): 84-9.

4719 995. Bhardwaj S, Capoor MR, Kolte S, et al. Phaeohyphomycosis Due to *Exophiala jeanselmei*: An
4720 Emerging Pathogen in India--Case Report and Review. *Mycopathologia* 2016; **181**(3-4): 279-84.

4721 996. Bhat S, Stull JD, Wang ML. Management of a Dermocutaneous Black Mold Abscess of the Finger
4722 with Flexor Sheath Involvement. *JBJS Case Connect* 2016; **6**(2): e41.

4723 997. Bonatti H, Brandacher G, Margreiter R, Schneeberger S. Infectious complications in three double
4724 hand recipients: experience from a single center. *Transplant Proc* 2009; **41**(2): 517-20.

4725 998. Bonnet C, Garcia-Hermoso D, Bertandeau E, Lortholary O, Kervinio C, Bonnan M.
4726 [Cladophialophora bantiana brain abscess: a case with long survival in metropolitan France]. *Rev Neurol*
4727 *(Paris)* 2014; **170**(2): 146-8.

4728 999. Bras S, Sabino R, Laureano A, et al. Cutaneous infection by different *Alternaria* species in a liver
4729 transplant recipient. *Medical mycology case reports* 2015; **8**: 1-4.

4730 1000. Bulloch MN. The treatment of pulmonary *Wangiella dermatitidis* infection with oral
4731 voriconazole. *J Clin Pharm Ther* 2011; **36**(3): 433-6.

4732 1001. Cai Q, Lv GX, Jiang YQ, et al. The first case of phaeohyphomycosis caused by *Rhinocladiella*
4733 *basitona* in an immunocompetent child in China. *Mycopathologia* 2013; **176**(1-2): 101-5.

4734 1002. Campos-Herrero MI, Tandon L, Horcajada I, Medina-Rivero F. Endophthalmitis caused by
4735 *Phialophora verrucosa*: a case report and literature review of *Phialophora* ocular infections. *Enferm*
4736 *Infecc Microbiol Clin* 2012; **30**(3): 163-5.

4737 1003. Capoor MR, Agarwal P, Goel M, et al. Invasive pulmonary mycosis due to *Chaetomium globosum*
4738 with false-positive galactomannan test: a case report and literature review. *Mycoses* 2016; **59**(3): 186-
4739 93.

4740 1004. Cardeau-Desangles I, Fabre A, Cointault O, et al. Disseminated *Ochroconis gallopava* infection in
4741 a heart transplant patient. *Transpl Infect Dis* 2013; **15**(3): E115-8.

4742 1005. Cariello PF, Wickes BL, Sutton DA, et al. *Phomopsis bougainvilleicola* prepatellar bursitis in a
4743 renal transplant recipient. *J Clin Microbiol* 2013; **51**(2): 692-5.

4744 1006. Cerar D, Malallah YM, Howard SJ, Bowyer P, Denning DW. Isolation, identification and
4745 susceptibility of *Pyrenochaeta romeroi* in a case of eumycetoma of the foot in the UK. *Int J Antimicrob*
4746 *Agents* 2009; **34**(6): 617-8.

4747 1007. Ch K, Thejaswids P, Kini H, Shenoy S, Prabhu S. Phaeohyphomycotic cyst in the Foot by
4748 *Exophiala*. *J Clin Diagn Res* 2014; **8**(11): ND10-1.

4749 1008. Chahal J, Dhotar HS, Anastakis DJ. Phaeohyphomycosis infection leading to flexor tendon
4750 rupture: a case report. *Hand (N Y)* 2009; **4**(3): 335-8.

4751 1009. Chaidaroon W, Supalaset S, Tananuvat N, Vanittanakom N. Corneal Phaeohyphomycosis Caused
4752 by *Bipolaris hawaiiensis*. *Case Rep Ophthalmol* 2016; **7**(2): 364-71.

4753 1010. Chalkias S, Alonso CD, Levine JD, Wong MT. Emerging pathogen in immunocompromised hosts:
4754 *Exophiala dermatitidis* mycosis in graft-versus-host disease. *Transpl Infect Dis* 2014; **16**(4): 616-20.

4755 1011. Chamroensakchai T, Leedumrongwattanakul K, Takkavatakarn K, Manuprasert W, Kanjanabuch
4756 T. Peritoneal dialysis (PD) catheter-related peritonitis from *Aureobasidium pullulans* caused by poor
4757 caregiver's hand hygiene. *Medical mycology case reports* 2019; **25**: 35-8.

4758 1012. Chan YY, Tan AL, Tan BH. Subcutaneous abscess due to *Pyrenochaeta romeroi* in a renal
4759 transplant recipient. *Singapore Med J* 2014; **55**(4): e64-6.

4760 1013. Chang GH, Wang WH. Intranasal fungal (*Alternaria*) infection related to nasal steroid spray. *Am J*
4761 *Otolaryngol* 2013; **34**(6): 743-5.

4762 1014. Chang X, Li R, Yu J, Bao X, Qin J. Phaeohyphomycosis of the central nervous system caused by
4763 *Exophiala dermatitidis* in a 3-year-old immunocompetent host. *J Child Neurol* 2009; **24**(3): 342-5.

4764 1015. Chang YC, Graf E, Green AM. Invasive *Curvularia* Infection in Pediatric Patients With
4765 Hematologic Malignancy Identified by Fungal Sequencing. *J Pediatric Infect Dis Soc* 2019; **8**(1): 87-91.

4766 1016. Chatterjee S, Agrawal D. Fungal keratitis in lattice dystrophy. *Indian J Ophthalmol* 2010; **58**(2):
4767 162-4.

4768 1017. Chawla B, Sharma N, Titiyal JS, Nayak N, Satpathy G. *Aureobasidium Pullulans* Keratitis Following
4769 Automated Lamellar Therapeutic Keratoplasty. *Ophthalmic Surg Lasers Imaging* 2010: 1-3.

4770 1018. Chen CY, Lu PL, Lee KM, et al. Acute meningitis caused by *Cladosporium sphaerospermum*. *Am J*
4771 *Med Sci* 2013; **346**(6): 523-5.

4772 1019. Chen M, Zhang J, Dong Z, Wang F. Cutaneous phaeohyphomycosis caused by *Exophiala*
4773 *dermatitidis*: A case report and literature review. *Indian J Dermatol Venereol Leprol* 2016; **82**(2): 173-7.

4774 1020. Chen YC, Su YC, Tsai CC, Lai NS, Fan KS, Liu KC. Subcutaneous phaeohyphomycosis caused by
4775 *Exophiala jeanselmei*. *J Microbiol Immunol Infect* 2014; **47**(6): 546-9.

4776 1021. Cheng SC, Lin YY, Kuo CN, Lai LJ. *Cladosporium* keratitis - a case report and literature review.
4777 *BMC Ophthalmol* 2015; **15**: 106.

4778 1022. Chew FLM, Subrayan V, Chong PP, Goh MC, Ng KP. *Cladosporium cladosporioides*
4779 keratomycosis: a case report. *Jpn J Ophthalmol* 2009; **53**(6): 657-9.

4780 1023. Chhabra V, Rastogi S, Barua M, Kumar S. *Alternaria alternata* infection associated osteomyelitis
4781 of maxilla: a rare disease entity. *Indian J Dent Res* 2013; **24**(5): 639-41.

4782 1024. Chhonkar A, Kataria D, Tambe S, Nayak CS. Three rare cases of cutaneous phaeohyphomycosis.
4783 *Indian J Plast Surg* 2016; **49**(2): 271-4.

4784 1025. Chintagunta S, Arakkal G, Damarla SV, Vodapalli AK. Subcutaneous phaeohyphomycosis in an
4785 immunocompetent Individual: A case report. *Indian Dermatol Online J* 2017; **8**(1): 29-31.

4786 1026. Cho KJ, Kim MS. Fungal hyphae growing into anterior chamber from cornea. *Can J Ophthalmol*
4787 2014; **49**(6): e151-4.

4788 1027. Choi J, Lee Y, Chung HS, et al. Subcutaneous phaeohyphomycosis caused by *Phaeoacremonium*
4789 species in a kidney transplant patient: the first case in Korea. *Korean J Lab Med* 2011; **31**(3): 201-4.

4790 1028. Choudhury S, Aggarwal R, Supraja C, Rao S, D'Cruz A. 29 cladophialophora bantiana causing
4791 brain abscess following liver transplant-a case report. *J Clin Exp Hepatol* 2011; **1**(2): 146.

4792 1029. Ciralsky J, Papaliadis GN, Foster CS, Dohlman CH, Chodosh J. Keratoprosthesis in autoimmune
4793 disease. *Ocul Immunol Inflamm* 2010; **18**(4): 275-80.

4794 1030. Clamp MF, Jumper JM, Ku CW, et al. Chronic exogenous *exophiala dermatitidis* endophthalmitis.
4795 *Retin Cases Brief Rep* 2014; **8**(4): 265-8.

4796 1031. Cohen YZ, Stead W. *Exophiala* Pneumonia Presenting with a Cough Productive of Black Sputum.
4797 *Case Rep Infect Dis* 2015; **2015**: 821049.

4798 1032. Colombier MA, Alanio A, Denis B, et al. Dual Invasive Infection with *Phaeoacremonium*
4799 *parasiticum* and *Paraconiothyrium cyclothyrioides* in a Renal Transplant Recipient: Case Report and
4800 Comprehensive Review of the Literature of *Phaeoacremonium* Phaeohyphomycosis. *J Clin Microbiol*
4801 2015; **53**(7): 2084-94.

4802 1033. Corvilain E, Casanova JL, Puel A. Inherited CARD9 Deficiency: Invasive Disease Caused by
4803 Ascomycete Fungi in Previously Healthy Children and Adults. *J Clin Immunol* 2018; **38**(6): 656-93.

4804 1034. Corzo-Leon DE, Satlin MJ, Soave R, et al. Epidemiology and outcomes of invasive fungal
4805 infections in allogeneic haematopoietic stem cell transplant recipients in the era of antifungal
4806 prophylaxis: a single-centre study with focus on emerging pathogens. *Mycoses* 2015; **58**(6): 325-36.

4807 1035. Costa RO. Subcutaneous phaeohyphomycosis. *An Bras Dermatol* 2010; **85**(5): 727-8.

4808 1036. Coussens E, Rogge S, Haspesslagh M, et al. Cutaneous infection by *Alternaria infectoria* in a liver
4809 transplant recipient: a case report. *Acta Gastroenterol Belg* 2014; **77**(2): 256-8.

4810 1037. Coutinho I, Teixeira V, Gameiro A, et al. Cutaneous alternariosis--a case series of an increasing
4811 phaeohyphomycosis. *J Eur Acad Dermatol Venereol* 2015; **29**(10): 2053-4.

4812 1038. Crawford SJ, Chen SC, Halliday C, Rangan GK, Gottlieb T, Reid AB. *Microsphaeropsis arundinis*
4813 skin and soft tissue infection in renal transplant recipients: three case reports and a review of the
4814 literature. *Transpl Infect Dis* 2015; **17**(6): 915-20.

4815 1039. Cuenca-Barrales C, De Salazar A, Chueca N, Saenz-Guirado S, Ruiz-Villaverde R.
4816 Phaeohyphomycosis due to *Pleurostomophora richardsiae*: an uncommon cutaneous fungal infection. *J*
4817 *Eur Acad Dermatol Venereol* 2018; **32**(10): e376-e7.

4818 1040. Cunha D, Amaro C, Vieira MR, et al. Phaeohyphomycosis caused by *Alternaria infectoria*
4819 presenting as multiple vegetating lesions in a renal transplant patient. *Rev Iberoam Micol* 2012; **29**(1):
4820 44-6.

4821 1041. da Cunha KC, Sutton DA, Fothergill AW, et al. In vitro antifungal susceptibility and molecular
4822 identity of 99 clinical isolates of the opportunistic fungal genus *Curvularia*. *Diagn Microbiol Infect Dis*
4823 2013; **76**(2): 168-74.

4824 1042. Daboit TC, Duquia RP, Magagnin CM, et al. A case of *Exophiala spinifera* infection in Southern
4825 Brazil: Molecular identification and antifungal susceptibility. *Medical mycology case reports* 2012; **1**(1):
4826 72-5.

4827 1043. Dadwal SS, Thompson R, Jandial R, Tegtmeier B, Chen MY. Chronic Leptomeningitis and Spinal
4828 Intradural Mass Secondary to *Alternaria* Infection in a Patient with Ventriculoperitoneal Shunt. *Case Rep*
4829 *Infect Dis* 2016; **2016**: 4693409.

4830 1044. Daglar D, Akman-Karakas A, Ozhak-Baysan B, et al. Cutaneous *Alternaria infectoria* infection
4831 diagnosed by molecular techniques in a renal transplant patient. *Clin Lab* 2014; **60**(9): 1569-72.

4832 1045. Dalla Gasperina D, Lombardi D, Rovelli C, et al. Successful treatment with isavuconazole of
4833 subcutaneous phaeohyphomycosis in a kidney transplant recipient. *Transpl Infect Dis* 2019: e13197.

4834 1046. Dan J, Zhou Q, Zhai H, et al. Clinical analysis of fungal keratitis in patients with and without
4835 diabetes. *PLoS One* 2018; **13**(5): e0196741.

4836 1047. Davies EC, Daly MK, Siracuse-Lee D. A rare case of *Phialemonium obovatum* keratitis. *Am J*
4837 *Ophthalmol Case Rep* 2017; **5**: 81-4.

4838 1048. de Oliveira WR, Borsato MF, Dabronzo ML, Festa Neto C, Rocha LA, Nunes RS.
4839 Phaeohyphomycosis in renal transplantation: report of two cases. *An Bras Dermatol* 2016; **91**(1): 89-92.

4840 1049. Demirci M, Baran N, Uzun A, Calli AO, Gul-Yurtsever S, Demirdal T. Cutaneous Alternariosis in a
4841 Patient With Renal Transplant. *Jundishapur J Microbiol* 2015; **8**(5): e19082.

4842 1050. Deng S, Pan W, Liao W, et al. Combination of Amphotericin B and Flucytosine against
4843 Neurotropic Species of Melanized Fungi Causing Primary Cerebral Phaeohyphomycosis. *Antimicrob*
4844 *Agents Chemother* 2016; **60**(4): 2346-51.

4845 1051. Derber C, Elam K, Bearman G. Invasive sinonasal disease due to dematiaceous fungi in
4846 immunocompromised individuals: case report and review of the literature. *Int J Infect Dis* 2010; **14** **Suppl**
4847 **3**: e329-32.

4848 1052. Desmet S, Smets L, Lagrou K, et al. *Cladophialophora bantiana* osteomyelitis in a renal transplant
4849 patient. *Medical mycology case reports* 2016; **12**: 17-20.

4850 1053. Desoubeaux G, Garcia D, Bailly E, et al. Subcutaneous phaeohyphomycosis due to
4851 *Phialemoniopsis ocularis* successfully treated by voriconazole. *Medical mycology case reports* 2014; **5**: 4-
4852 8.

4853 1054. Dessinioti C, Soumalevris A, Papadogeorgaki E, et al. Cutaneous alternariosis in an
4854 immunocompetent patient successfully treated with oral fluconazole. *Eur J Dermatol* 2013; **23**(4): 545-7.

4855 1055. Detroyer D, Deraedt K, Schoffski P, et al. Resolution of diffuse skin and systemic Kaposi's
4856 sarcoma in a renal transplant recipient after introduction of everolimus: a case report. *Transpl Infect Dis*
4857 2015; **17**(2): 303-7.

4858 1056. Dewar CL, Sigler L. Fungal arthritis of the knee caused by *Mycoleptodiscus indicus*. *Clin Rheumatol* 2010; **29**(9): 1061-5.

4859

4860 1057. Dharmic S, Nair S, Harish M. An unusual cause of fungal pneumonia. *J Pharm Bioallied Sci* 2015; 7(Suppl 1): S67-9.

4861

4862 1058. Didehdar M, Gokanian A, Sofian M, et al. First fatal cerebral phaeohyphomycosis due to *Rhinocladiella mackenziei* in Iran, based on ITS rDNA. *J Mycol Med* 2015; **25**(1): 81-6.

4863

4864 1059. Diernaes JE, Hjuler KF, Kristensen L, Deleuran M. Subcutaneous Phaeohyphomycosis due to *Alternaria dennisii* in an Immunocompromised Patient. *Acta Derm Venereol* 2016; **96**(5): 701-2.

4865

4866 1060. Dinh A, Levy B, Bouchand F, et al. Subcutaneous Phaeohyphomycosis Due to *Pyrenochaeta romeroi* Mimicking a Synovial Cyst. *Front Microbiol* 2016; **7**: 1405.

4867

4868 1061. Dionne B, Neff L, Lee SA, et al. Pulmonary Fungal Infection Caused by *Neoscytalidium dimidiatum*. *J Clin Microbiol* 2015; **53**(7): 2381-4.

4869

4870 1062. Dobias R, Filip M, Vragova K, et al. Successful surgical excision of cerebral abscess caused by *Fonsecaea monophora* in an immunocompetent patient and review of literature. *Folia Microbiol (Praha)* 2019; **64**(3): 383-8.

4871

4872

4873 1063. Dobinson HC, Down G, Clark JE. *Exserohilum* infections in Australian Queensland children. *Mycoses* 2019; **62**(2): 181-5.

4874

4875 1064. Duquia RP, de Almeida HL, Jr., Vettorato G, Rocha NM, de Castro LA. Ecthyma-like phaeohyphomycosis caused by *Cladosporium cladosporioides*. *Mycoses* 2010; **53**(6): 541-3.

4876

4877 1065. Echavez MI, Agahan AL, Carino NS. Fungal Keratitis Caused by *Drechslera* spp. Treated with Voriconazole: A Case Report. *Case Rep Ophthalmol Med* 2013; **2013**: 626704.

4878

4879 1066. Edelmayer L, Ito C, Lee WS, Kimbrough J, Kountakis SE, Byrd JK. Conversion to Chronic Invasive Fungal Sinusitis From Allergic Fungal Sinusitis in Immunocompetence. *Laryngoscope* 2019; **129**(11): 2447-50.

4880

4881

4882 1067. Ehlers JP, Chavala SH, Woodward JA, Postel EA. Delayed recalcitrant fungal endophthalmitis secondary to *Curvularia*. *Can J Ophthalmol* 2011; **46**(2): 199-200.

4883

4884 1068. El Helou G, Palavecino E, Nunez M. Double invasive fungal infection due to dematiaceous moulds in a renal transplant patient. *BMJ Case Rep* 2018; **2018**.

4885

4886 1069. Elinav H, Izhar U, Benenson S, et al. Invasive *Scytalidium dimidiatum* infection in an immunocompetent adult. *J Clin Microbiol* 2009; **47**(4): 1259-63.

4887

4888 1070. Enomoto S, Shigemi H, Kitazaki Y, et al. *Cladophialophora bantiana* infection mimicking neuromyelitis optica. *J Neurol Sci* 2019; **399**: 169-71.

4889

4890 1071. Escamilla Carpintero Y, Espasa Soley M, Bella Cueto MR, Prenafeta Moreno M. [Sphenoid sinusitis with intracranial extension produced by an emergent fungus]. *Acta Otorrinolaringol Esp* 2011; **62**(2): 158-60.

4891

4892

4893 1072. Esposito E, Maccio JP, Monti R, Cervi L, Serra HM, Urrets-Zavalía JA. *Alternaria* keratitis and hypopyon after clear-cornea phacoemulsification. *J Cataract Refract Surg* 2014; **40**(2): 331-4.

4894

4895 1073. Essabbah N, Gorsane I, Youssef M, et al. Cutaneous alternariosis in a renal transplant recipient. *Cutis* 2014; **93**(5): 237-40.

4896

4897 1074. Eswarappa M, Varma PV, Madhyastha R, et al. Unusual fungal infections in renal transplant recipients. *Case Rep Transplant* 2015; **2015**: 292307.

4898

4899 1075. Fan YM, Huang WM, Li SF, Wu GF, Li W, Chen RY. Cutaneous phaeohyphomycosis of foot caused by *Curvularia clavata*. *Mycoses* 2009; **52**(6): 544-6.

4900

4901 1076. Fang G, Zhang Q, Zhu L, Li D. [Clinical study of chronic invasive sinusitis caused by dematiaceous fungi]. *Lin Chung Er Bi Yan Hou Tou Jing Wai Ke Za Zhi* 2011; **25**(20): 916-9.

4902

4903 1077. Fernandez AL, Andres PO, Vecino CH, Nagel CB, Mujica MT. Subcutaneous infection by *Graphium basitruncatum* in a heart transplant patient. *Braz J Infect Dis* 2017; **21**(6): 670-4.

4904

4905 1078. Fernandez-Pittol MJ, Alejo-Cancho I, Rubio E, et al. Cutaneous infection by *Phaeoacremonium parasiticum*. *Rev Iberoam Micol* 2019; **36**(2): 90-2.

4906

4907 1079. Ferreira Ide S, Teixeira G, Abecasis M. *Alternaria alternata* invasive fungal infection in a patient with Fanconi's anemia after an unrelated bone marrow transplant. *Clin Drug Investig* 2013; **33** Suppl 1: S33-6.

4908

4909

4910 1080. Ferrer C, Perez-Santonja JJ, Rodriguez AE, et al. New pyrenochaeta species causing keratitis. *J Clin Microbiol* 2009; **47**(5): 1596-8.

4912 1081. Fintelmann RE, Gilmer W, Bloomer MM, Jeng BH. Recurrent Lecythophora mutabilis keratitis and endophthalmitis after deep anterior lamellar keratoplasty. *Arch Ophthalmol* 2011; **129**(1): 108-10.

4913 1082. Fox AR, Houser KH, Morris WR, Walton RC. Dematiaceous fungal endophthalmitis: report of a case and review of the literature. *J Ophthalmic Inflamm Infect* 2016; **6**(1): 43.

4914 1083. Frank T, Esquenazi Y, Nigo M, Wanger A, Portnoy B, Shepard S. Disseminated Phaeohyphomycosis with Brain Abscess and Biliary Invasion Due to Bipolaris spp. in an Immunocompetent Patient. *Ann Clin Lab Sci* 2016; **46**(4): 439-42.

4918 1084. Frassetto-Artes JS, Peman J, Blanes M, et al. [Cerebral phaeohyphomycosis: description of a case and review of the literature]. *Rev Iberoam Micol* 2014; **31**(3): 197-202.

4919 1085. Freda R, Dal Pizzol MM, Fortes Filho JB. Phialemonium curvatum infection after phacoemulsification: a case report. *Eur J Ophthalmol* 2011; **21**(6): 834-6.

4920 1086. Fukai T, Hiruma M, Ogawa Y, et al. A case of phaeohyphomycosis caused by Exophiala oligosperma successfully treated with local hyperthermia. *Med Mycol J* 2013; **54**(3): 297-301.

4921 1087. Furudate S, Sasai S, Numata Y, Fujimura T, Aiba S. Phaeohyphomycosis Caused by Phaeoacremonium rubrigenum in an Immunosuppressive Patient: A Case Report and Review of the Literature. *Case Rep Dermatol* 2012; **4**(2): 119-24.

4922 1088. Gadgil N, Kupferman M, Smitherman S, Fuller GN, Rao G. Curvularia brain abscess. *J Clin Neurosci* 2013; **20**(1): 173-5.

4923 1089. Gajjar DU, Pal AK, Parmar TJ, et al. Fungal scleral keratitis caused by Phomopsis phoenicicola. *J Clin Microbiol* 2011; **49**(6): 2365-8.

4924 1090. Gajjar DU, Pal AK, Santos JM, Ghodadra BK, Vasavada AR. Severe pigmented keratitis caused by Cladorrhinum bulbillosum. *Indian J Med Microbiol* 2011; **29**(4): 434-7.

4925 1091. Ganju SA, Bhagra S, Kanga AK, Singh DV, Guleria RC. A case report of an uncommon phaeoid fungal infection in nasal polyposis and review of literature. *Indian J Med Microbiol* 2013; **31**(2): 196-8.

4926 1092. Garcia-Hermoso D, Valenzuela-Lopez N, Rivero-Menendez O, et al. Diversity of coelomycetous fungi in human infections: A 10-y experience of two European reference centres. *Fungal Biol* 2019; **123**(4): 341-9.

4927 1093. Garcia-Reyne A, Lopez-Medrano F, Morales JM, et al. Cutaneous infection by Phomopsis longicolla in a renal transplant recipient from Guinea: first report of human infection by this fungus. *Transpl Infect Dis* 2011; **13**(2): 204-7.

4928 1094. Garinet S, Turret J, Barete S, et al. Invasive cutaneous Neoscytalidium infections in renal transplant recipients: a series of five cases. *BMC Infect Dis* 2015; **15**: 535.

4929 1095. Gautier M, Michel J, Normand AC, Cassagne C, Piarroux R, Ranque S. Cochliobolus hawaiiensis Sinusitis, a Tropical Disease? A Case Report and Review of the Literature. *Mycopathologia* 2015; **180**(1-2): 117-21.

4930 1096. Ge H, Pan M, Chen G, Liu X, Shi T, Zhang F. The first case of cutaneous phaeohyphomycosis caused by Bipolaris spicifera in Northern China: A case report. *Exp Ther Med* 2017; **14**(3): 1875-8.

4931 1097. Ge YP, Lv GX, Shen YN, et al. First report of subcutaneous phaeohyphomycosis caused by Ochroconis tshawytschae in an immunocompetent patient. *Medical mycology* 2012; **50**(6): 637-40.

4932 1098. Goel RS, Gupta S, Dua V, Kumar R. Cerebral Phaeohyphomycosis with Onychomycosis: Case Report and Review of Literature. *Asian J Neurosurg* 2019; **14**(2): 575-7.

4933 1099. Gomes J, Vilarinho C, Duarte Mda L, Brito C. Cutaneous Phaeohyphomycosis Caused by Alternaria alternata Unresponsive to Itraconazole Treatment. *Case Rep Dermatol Med* 2011; **2011**: 385803.

4934 1100. Gomez-Moyano E, Crespo-Erchiga V, Sanz-Trelles A, Crespo-Erchiga A. [Ulcerated nodule with satellite lesions on the pulp of the first finger of an elderly male patient]. *Actas Dermosifiliogr* 2009; **100**(9): 813-4.

4935 1101. Gongidi P, Sarkar D, Behling E, Brody J. Cerebral phaeohyphomycosis in a patient with neurosarcoidosis on chronic steroid therapy secondary to recreational marijuana usage. *Case Rep Radiol* 2013; **2013**: 191375.

4936

4937

4938

4939

4940

4941

4942

4943

4944

4945

4946

4947

4948

4949

4950

4951

4952

4953

4954

4955

4956

4957

4958

4959

4960

4961

4962 1102. Gonzales Zamora JA, Varadarajalu Y. Fatal Curvularia brain abscess in a heart and kidney
4963 transplant recipient. *IDCases* 2019; **17**: e00576.

4964 1103. Gonzalez-Vela MC, Armesto S, Unda-Villafuerte F, Val-Bernal JF. Cutaneous infection with
4965 *Alternaria triticina* in a Bilateral lung transplant recipient. *Actas Dermosifiliogr* 2014; **105**(8): e51-4.

4966 1104. Gopalakrishnan R, Sethuraman N, Madhumitha R, et al. Cladophialophora bantiana brain
4967 abscess: A report of two cases treated with voriconazole. *Indian J Med Microbiol* 2017; **35**(4): 620-2.

4968 1105. Gordon RA, Sutton DA, Thompson EH, et al. Cutaneous phaeohyphomycosis caused by
4969 *Paraconiothyrium cyclothyrioides*. *J Clin Microbiol* 2012; **50**(11): 3795-8.

4970 1106. Grava S, Lopes FA, Cavallazzi RS, Grassi MF, Svidzinski TI. A rare case of hemorrhagic pneumonia
4971 due to *Cladosporium cladosporioides*. *J Bras Pneumol* 2016; **42**(5): 392-4.

4972 1107. Green KK, Barham HP, Allen GC, Chan KH. Prognostic Factors in the Outcome of Invasive Fungal
4973 Sinusitis in a Pediatric Population. *Pediatr Infect Dis J* 2016; **35**(4): 384-6.

4974 1108. Gschwend A, Degot T, Denis J, et al. Brain abscesses caused by *Cladophialophora bantiana* in a
4975 lung transplant patient: A case report and review of the literature. *Transpl Infect Dis* 2017; **19**(6).

4976 1109. Guimaraes LF, Halpern M, de Lemos AS, et al. Invasive Fungal Disease in Renal Transplant
4977 Recipients at a Brazilian Center: Local Epidemiology Matters. *Transplant Proc* 2016; **48**(7): 2306-9.

4978 1110. Guo Y, Zhu Z, Gao J, et al. The Phytopathogenic Fungus *Pallidocercospora crystallina*-Caused
4979 Localized Subcutaneous Phaeohyphomycosis in a Patient with a Homozygous Missense CARD9
4980 Mutation. *J Clin Immunol* 2019; **39**(7): 713-25.

4981 1111. Gupta A, Xess I, Sharma SC, Mallick S. Invasive rhinosinusitis by *Exserohilum rostratum* in an
4982 immunocompetent child. *BMJ Case Rep* 2014; **2014**.

4983 1112. Gupta AJ, Singh M, Yadav S, et al. Phaeohyphomycosis breast masquerading as fibroadenoma in
4984 a young teenage girl. *Diagn Cytopathol* 2017; **45**(10): 939-42.

4985 1113. Gupta N, Kumar A, Singh G, Ratnakar G, Vinod KS, Wig N. Breakthrough mucormycosis after
4986 voriconazole use in a case of invasive fungal rhinosinusitis due to *Curvularia lunata*. *Drug Discov Ther*
4987 2017; **11**(6): 349-52.

4988 1114. Gupta N, Samantaray JC, Duggal S, Srivastava V, Dhull CS, Chaudhary U. *Acanthamoeba* keratitis
4989 with *Curvularia* co-infection. *Indian J Med Microbiol* 2010; **28**(1): 67-71.

4990 1115. Gurcan S, Piskin S, Kilic H, Temelli BA, Yalcin O. [Cutaneous infection caused by *Alternaria*
4991 *alternata* in an immunocompetent host]. *Mikrobiyol Bul* 2009; **43**(1): 163-7.

4992 1116. Salmanton-García J, Koehler P, Kindo A, et al. Needles in a haystack: Extremely rare invasive
4993 fungal infections reported in FungiScope® - Global Registry for Emerging Fungal Infections. *The Journal*
4994 *of infection* 2020.

4995 1117. Hall MR, Brumble LM, Mayes MA, Snow JL, Keeling JH. Cutaneous *Microsphaeropsis arundinis*
4996 infection initially interpreted as squamous cell carcinoma. *Int J Dermatol* 2013; **52**(1): 84-6.

4997 1118. Hanashiro F, Yamaguchi S, Awazawa R, Sano A, Takahashi K. Cutaneous phaeohyphomycosis
4998 caused by *Microsphaeropsis arundinis* in a Japanese patient with cardiac sarcoidosis. *J Dermatol* 2019;
4999 **46**(5): e170-e2.

5000 1119. Haridasan S, Parameswaran S, Bheemanathi SH, et al. Subcutaneous phaeohyphomycosis in
5001 kidney transplant recipients: A series of seven cases. *Transpl Infect Dis* 2017; **19**(6).

5002 1120. Hariri A, Choudhury N, Saleh HA. *Scytalidium dimidiatum* associated invasive fungal sinusitis in
5003 an immunocompetent patient. *J Laryngol Otol* 2014; **128**(11): 1018-21.

5004 1121. Hasei M, Takeda K, Anzawa K, Nishibu A, Tanabe H, Mochizuki T. Case of phaeohyphomycosis
5005 producing sporotrichoid lesions. *J Dermatol* 2013; **40**(8): 638-40.

5006 1122. Haston JC, Rostad CA, Jerris RC, et al. Prospective Cohort Study of Next-Generation Sequencing
5007 as a Diagnostic Modality for Unexplained Encephalitis in Children. *J Pediatric Infect Dis Soc* 2019.

5008 1123. Hattab Z, Ben Lasfar N, Abid M, et al. *Alternaria alternata* infection causing rhinosinusitis and
5009 orbital involvement in an immunocompetent patient. *New Microbes New Infect* 2019; **32**: 100561.

5010 1124. Helbig S, Thuermer A, Dengl M, Krukowski P, de With K. Cerebral Abscess by *Fonsecaea*
5011 *monophora*-The First Case Reported in Germany. *Open Forum Infect Dis* 2018; **5**(6): ofy129.

5012 1125. Hemmaway C, Laverse E, Nicholas M, Nagy Z. Cerebellar Cladophialophora bantiana infection in
5013 a patient with marginal zone lymphoma treated with immunochemotherapy including rituximab. *Br J*
5014 *Haematol* 2011; **154**(4): 423.

5015 1126. Hipolito E, Faria E, Alves AF, et al. Alternaria infectoria brain abscess in a child with chronic
5016 granulomatous disease. *Eur J Clin Microbiol Infect Dis* 2009; **28**(4): 377-80.

5017 1127. Hochfelder J, Fetto J. Phialophora verrucosa as a cause of deep infection following total knee
5018 arthroplasty. *American journal of orthopedics (Belle Mead, NJ)* 2013; **42**(11): 515-8.

5019 1128. Homa M, Manikandan P, Saravanan V, et al. Exophiala dermatitidis Endophthalmitis: Case
5020 Report and Literature Review. *Mycopathologia* 2018; **183**(3): 603-9.

5021 1129. Hong KH, Kim JW, Jang SJ, Yu E, Kim EC. Liver cirrhosis caused by Exophiala dermatitidis. *J Med*
5022 *Microbiol* 2009; **58**(Pt 5): 674-7.

5023 1130. Hong KH, Ryoo NH, Chang SD. Phialemonium obovatum keratitis after penetration injury of the
5024 cornea. *Korean J Ophthalmol* 2012; **26**(6): 465-8.

5025 1131. Howlett S, Sullivan T, Abdolrasouli A, et al. A black mould death: A case of fatal cerebral
5026 phaeohyphomycosis caused by Cladophialophora bantiana. *Med Mycol Case Rep* 2019; **24**: 23-6.

5027 1132. Hsiao CH, Yeh LK, Chen HC, et al. Clinical characteristics of alternaria keratitis. *J Ophthalmol*
5028 2014; **2014**: 536985.

5029 1133. Hsiao YW, Chia JH, Lu CF, Chung WH. Molecular diagnosis and therapeutic experience of
5030 subcutaneous Pyrenochaeta romeroi infection: a case report and review of the literature. *Int J Dermatol*
5031 2013; **52**(10): 1237-40.

5032 1134. Hsu CC, Chang SS, Lee PC, Chao SC. Cutaneous alternariosis in a renal transplant recipient: a case
5033 report and literature review. *Asian J Surg* 2015; **38**(1): 47-57.

5034 1135. Hu B, Li S, Hu H, et al. [Central nervous system infection caused by Exophiala dermatitidis in a
5035 case and literature review]. *Zhonghua Er Ke Za Zhi* 2014; **52**(8): 620-4.

5036 1136. Hu W, Ran Y, Zhuang K, Lama J, Zhang C. Alternaria arborescens infection in a healthy individual
5037 and literature review of cutaneous alternariosis. *Mycopathologia* 2015; **179**(1-2): 147-52.

5038 1137. Huang C, Zhang Y, Song Y, Wan Z, Wang X, Li R. Phaeohyphomycosis caused by Phialophora
5039 americana with CARD9 mutation and 20-year literature review in China. *Mycoses* 2019; **62**(10): 908-19.

5040 1138. Huang J, Liu Z. The first case of Acrophialophora levis-induced severe pneumonia: a case report
5041 and literature review. *BMC Infect Dis* 2019; **19**(1): 843.

5042 1139. Huang WM, Fan YM, Li W, Yang WW. Brain abscess caused by Cladophialophora bantiana in
5043 China. *J Med Microbiol* 2011; **60**(Pt 12): 1872-4.

5044 1140. Huang YT, Liao CH, Hsueh PR. Image Gallery: Cutaneous infections caused by Alternaria
5045 alternata and Mucor irregularis 1 year apart in a patient with iatrogenic Cushing syndrome. *Br J*
5046 *Dermatol* 2016; **174**(6): e82.

5047 1141. Huerva V, Soldevila J. Alternaria alternata keratitis. *Med Clin (Barc)* 2017; **149**(10): 466.

5048 1142. Husova L, Kocmanova I, Zampachova V, et al. Cladophialophora bantiana in a liver transplant
5049 recipient. *Surg Infect (Larchmt)* 2015; **16**(2): 211-2.

5050 1143. Ikram A, Hussain W, Satti ML, Wiqar MA. Invasive infection in a young immunocompetent
5051 soldier caused by Scytalidium dimidiatum. *J Coll Physicians Surg Pak* 2009; **19**(1): 64-6.

5052 1144. Ito A, Yamada N, Kimura R, et al. Concurrent Double Fungal Infections of the Skin Caused by
5053 Phialemoniopsis endophytica and Exophiala jeanselmei in a Patient with Microscopic Polyangiitis. *Acta*
5054 *Derm Venereol* 2017; **97**(9): 1142-4.

5055 1145. Jabeen K, Farooqi J, Zafar A, et al. Rhinocladiella mackenziei as an emerging cause of cerebral
5056 phaeohyphomycosis in Pakistan: a case series. *Clinical infectious diseases : an official publication of the*
5057 *Infectious Diseases Society of America* 2011; **52**(2): 213-7.

5058 1146. Jahan-Tigh RR, Shelton M, Rapini R. Extensive Exserohilum infection in a burn patient. *JAAD Case*
5059 *Rep* 2015; **1**(4): 188-90.

5060 1147. Jain NS, Horn CB, Coleoglou Centeno AA, et al. Femoral Osteomyelitis Caused by
5061 Cladophialophora in a Patient without Known Immunocompromise. *Surg Infect (Larchmt)* 2018; **19**(5):
5062 544-7.

5063 1148. Jain S, Tarai B, Tuli P, Das P. Unusual fungal sepsis of *Alternaria alternata* in acute lymphoblastic
5064 leukaemia in an adult patient. *Indian J Med Microbiol* 2015; **33**(4): 599-600.

5065 1149. Jaiswal S, Vij M, Prasad N, Kaul A, Marak RS, Pandey R. Diagnostic pitfalls in cytological diagnosis
5066 of subcutaneous fungal infection in renal transplant recipients. *Diagn Cytopathol* 2012; **40**(3): 255-61.

5067 1150. Jaramillo S, Varon CL. *Curvularia lunata* endophthalmitis after penetrating ocular trauma. *Retin*
5068 *Cases Brief Rep* 2013; **7**(4): 315-8.

5069 1151. Jayasinghe RD, Abeysinghe W, Jayasekara PI, Mohomed YS, Siriwardena B. Unilateral Cervical
5070 Lymphadenopathy due to *Cladosporium oxysporum*: A Case Report and Review of the Literature. *Case*
5071 *Rep Pathol* 2017; **2017**: 5036514.

5072 1152. Jayasudha R, Sharma S, Kalra P, Mishra DK. Exserohilum keratitis: Clinical profile of nine patients
5073 and comparison of morphology versus ITS-Based DNA sequencing for species identification of the fungal
5074 isolates. *Indian J Med Microbiol* 2018; **36**(4): 564-8.

5075 1153. Jennings Z, Kable K, Halliday CL, et al. *Verruconis gallopava* cardiac and endovascular infection
5076 with dissemination after renal transplantation: Case report and lessons learned. *Medical mycology case*
5077 *reports* 2017; **15**: 5-8.

5078 1154. Jeragh A, Ahmad S, Khan Z, et al. Subcutaneous phaeohyphomycosis caused by *Amesia*
5079 *atrobrunnea* in Kuwait. *J Mycol Med* 2019; **29**(2): 193-7.

5080 1155. Jinkala SR, Basu D, Neelaiah S, Stephen N, Bheemanati Hanuman S, Singh R. Subcutaneous
5081 Phaeohyphomycosis: A Clinical Mimic of Skin and Soft Tissue Neoplasms-A Descriptive Study from India.
5082 *World J Surg* 2018; **42**(12): 3861-6.

5083 1156. Joseph NM, Kumar MA, Stephen S, Kumar S. Keratomycosis caused by *Exserohilum rostratum*.
5084 *Indian J Pathol Microbiol* 2012; **55**(2): 248-9.

5085 1157. Joshi A, Singh R, Shah MS, Umesh S, Khattry N. Subcutaneous mycosis and fungemia by
5086 *Aureobasidium pullulans*: a rare pathogenic fungus in a post allogeneic BM transplant patient. *Bone*
5087 *Marrow Transplant* 2010; **45**(1): 203-4.

5088 1158. Joshi P, Agarwal S, Singh G, Xess I, Bhowmik D. "A fine needle aspiration cytology in time saves
5089 nine" - cutaneous phaeohyphomycosis caused by *Exophiala jeanselmei* in a renal transplant patient:
5090 Diagnosis by fine needle aspiration cytology. *J Cytol* 2016; **33**(1): 55-7.

5091 1159. Juhas E, Reyes-Mugica M, Michaels MG, Grunwaldt LJ, Gehris RP. Exserohilum infection in an
5092 immunocompromised neonate. *Pediatr Dermatol* 2013; **30**(6): e232-3.

5093 1160. Jung NY, Kim E. Cerebral phaeohyphomycosis: a rare cause of brain abscess. *J Korean Neurosurg*
5094 *Soc* 2014; **56**(5): 444-7.

5095 1161. Kalawat U, Reddy GS, Sandeep Y, et al. Successfully treated *Curvularia lunata* peritonitis in a
5096 peritoneal dialysis patient. *Indian J Nephrol* 2012; **22**(4): 318-9.

5097 1162. Kaliamurthy J, Kalavathy CM, Nelson Jesudasan CA, Thomas PA. Keratitis due to *Chaetomium* sp.
5098 *Case Rep Ophthalmol Med* 2011; **2011**: 696145.

5099 1163. Kan T, Takahagi S, Kamegashira A, Ooiwa H, Yaguchi T, Hide M. Disseminated subcutaneous
5100 phaeohyphomycosis caused by *Exophiala oligosperma* in a patient with Wegener's granulomatosis. *Acta*
5101 *Derm Venereol* 2013; **93**(3): 356-7.

5102 1164. Kang RB, Simonson DC, Stoner SE, Hughes SR, Agger WA. The Clinical Presentation of
5103 Subcutaneous Phaeohyphomycosis: A Case Series from Ytebon, Ethiopia. *Clin Med Res* 2017; **15**(3-4):
5104 88-92.

5105 1165. Kantarcioglu AS, Guarro J, de Hoog GS, et al. A case of central nervous system infection due to
5106 *Cladophialophora bantiana*. *Rev Iberoam Micol* 2016; **33**(4): 237-41.

5107 1166. Karatas Togral A, Gulec AT. Tzanck smear as an accurate and rapid diagnostic tool for cutaneous
5108 alternariosis in a renal transplant recipient. *Clin Exp Dermatol* 2016; **41**(7): 747-50.

5109 1167. Karuppall R, Kumaran CM, Marthya A, et al. Tibial osteomyelitis due to *Fonsecaea pedrosoi* in an
5110 immunocompetent patient: case report. *J Foot Ankle Surg* 2009; **48**(5): 569-72.

5111 1168. Kaur R, Bala K. Unilateral renal phaeohyphomycosis due to *Bipolaris spicifera* in an
5112 immunocompetent child - rare case presentation and review of literature. *Mycoses* 2015; **58**(7): 437-44.

5113 1169. Kaur R, Dhakad MS, Goyal R, Bhalla P, Dewan R. Spectrum of Opportunistic Fungal Infections in
5114 HIV/AIDS Patients in Tertiary Care Hospital in India. *Can J Infect Dis Med Microbiol* 2016; **2016**: 2373424.

5115 1170. Kerchner KR, Swing DC, Jr., Williford PR. A verrucous plaque of the eyebrow. *Am J Dermatopathol* 2009; **31**(5): 506-8.

5116

5117 1171. Khader A, Ambooken B, Binitha MP, Francis S, Kuttiyil AK, Sureshan DN. Disseminated cutaneous phaeohyphomycosis due to *Cladophialophora bantiana*. *Indian J Dermatol Venereol Leprol* 2015; **81**(5): 491-4.

5118

5119

5120 1172. Khaliq MF, Ihle RE, Schirtzinger CP. *Cladophialophora bantiana* Cerebral Phaeohyphomycosis Complicated by Pulmonary Nocardiosis: A Tale of Two Infections. *Case Rep Infect Dis* 2019; **2019**: 4352040.

5121

5122

5123 1173. Khan Z, Ahmad S, Jeragh A, et al. First isolation of *Ascotricha chartarum* from bronchoalveolar lavage of two patients with pulmonary infections. *New Microbes New Infect* 2019; **28**: 11-6.

5124

5125 1174. Khan Z, Ahmad S, Kapila K, et al. *Pyrenochaeta romeroi*: a causative agent of phaeohyphomycotic cyst. *J Med Microbiol* 2011; **60**(Pt 6): 842-6.

5126

5127 1175. Khetan SP, Agrawal VA, Qazi MS. Cerebral phaeohyphomycosis--could early diagnosis have saved the patient? *Indian J Med Microbiol* 2014; **32**(4): 440-2.

5128

5129 1176. Khohtali S, Hriz A, Abid F, Khairallah-Ksiaa I, Jelliti B, Khairallah M. *Alternaria* keratitis after uneventful phacoemulsification in an otherwise healthy adult. *J Ophthalmic Inflamm Infect* 2016; **6**(1): 4.

5130

5131 1177. Kim EL, Patel SR, George MS, Ameri H. *Ochroconis Gallopava* Endophthalmitis Successfully Treated with Intravitreal Voriconazole and Amphotericin B. *Retin Cases Brief Rep* 2018; **12**(4): 310-3.

5132

5133 1178. Kindo AJ, Anita S, Kalpana S. *Nattrassia mangiferae* causing fungal keratitis. *Indian J Med Microbiol* 2010; **28**(2): 178-81.

5134

5135 1179. Kindo AJ, Pramod C, Anita S, Mohanty S. Maxillary sinusitis caused by *Lasiodiplodia theobromae*. *Indian J Med Microbiol* 2010; **28**(2): 167-9.

5136

5137 1180. Kindo AJ, Ramalakshmi S, Giri S, Abraham G. A fatal case of prostatic abscess in a post-renal transplant recipient caused by *Cladophialophora carrionii*. *Saudi J Kidney Dis Transpl* 2013; **24**(1): 76-9.

5138

5139 1181. Klasinc R, Riesenhuber M, Bacher A, Willinger B. Invasive Fungal Infection Caused by *Exophiala dermatitidis* in a Patient After Lung Transplantation: Case Report and Literature Review. *Mycopathologia* 2019; **184**(1): 107-13.

5140

5141 1182. Kohashi S, Toyama T, Hashimoto N, et al. Sinusitis caused by *Exserohilum rostratum* after cord blood transplantation for myelodysplastic syndrome: A case report and literature review. *Transpl Infect Dis* 2018; **20**(1).

5142

5143

5144 1183. Konidaris V, Mersinoglou A, Vyzantiadis TA, Papadopoulou D, Boboridis KG, Ekonomidis P. Corneal Transplant Infection due to *Alternaria alternata*: A Case Report. *Case Rep Ophthalmol Med* 2013; **2013**: 589620.

5145

5146

5147 1184. Koo S, Klompas M, Marty FM. *Fonsecaea monophora* cerebral phaeohyphomycosis: case report of successful surgical excision and voriconazole treatment and review. *Medical mycology* 2010; **48**(5): 769-74.

5148

5149

5150 1185. Koo S, Sutton DA, Yeh WW, et al. Invasive *Mycocleptodiscus* fungal cellulitis and myositis. *Medical mycology* 2012; **50**(7): 740-5.

5151

5152 1186. Korem M, Polacheck I, Michael-Gayego A, Strahilevitz J. Galactomannan testing for early diagnosis of *Exserohilum rostratum* infection. *J Clin Microbiol* 2013; **51**(8): 2800-1.

5153

5154 1187. Kotwal A, Biswas D, Kakati B, Bahadur H, Gupta N. Non traumatic keratitis due to *colletotrichum coccodes*: a case report. *J Clin Diagn Res* 2015; **9**(2): DD01-2.

5155

5156 1188. Kpodzo DS, Calderwood MS, Ruchelsman DE, et al. Primary subcutaneous *Alternaria alternata* infection of the hand in an immunocompromised host. *Medical mycology* 2011; **49**(5): 543-7.

5157

5158 1189. Kuan CS, Cham CY, Singh G, et al. Genomic Analyses of *Cladophialophora bantiana*, a Major Cause of Cerebral Phaeohyphomycosis Provides Insight into Its Lifestyle, Virulence and Adaptation in Host. *PLoS One* 2016; **11**(8): e0161008.

5159

5160

5161 1190. Kulkarni M, Jamale T, Hase N, Ubale M, Keskar V, Jagadish PK. Subcutaneous Phaeohyphomycosis Caused By *Pyrenochaeta romeroi* in a Kidney Transplant Recipient: A Case Report. *Exp Clin Transplant* 2017; **15**(2): 226-7.

5162

5163 1191. Kumar A, Khurana A, Sharma M, Chauhan L. Causative fungi and treatment outcome of dematiaceous fungal keratitis in North India. *Indian J Ophthalmol* 2019; **67**(7): 1048-53.

5164

5165

5166

5167 1192. Kumar GN, Nair SP. Phaeohyphomycosis presenting as a solitary nodulocystic lesion in a renal
5168 transplant patient. *Indian Dermatol Online J* 2015; **6**(5): 359-61.

5169 1193. Kumar KV, Mallikarjuna HM, Gokulnath, Jayanthi S. Fungal peritonitis in continuous ambulatory
5170 peritoneal dialysis: The impact of antifungal prophylaxis on patient and technique outcomes. *Indian J*
5171 *Nephrol* 2014; **24**(5): 297-301.

5172 1194. Kumar P, Thomas S, Papagiannuli E, Hardman SC, Jenkins D, Prydal J. A case of Phoma fungal
5173 keratitis in a contact lens user. *JRSM Open* 2015; **6**(3): 2054270415577760.

5174 1195. Kumaran MS, Bhagwan S, Savio J, et al. Disseminated cutaneous Ochroconis gallopava infection
5175 in an immunocompetent host: an unusual concurrence - a case report and review of cases reported. *Int J*
5176 *Dermatol* 2015; **54**(3): 327-31.

5177 1196. Kumarguru B, Srinivas T, Jagadish MH. A case of subcutaneous phaeohyphomycosis in a diabetic
5178 patient: a cryptic entity. *J Glob Infect Dis* 2014; **6**(1): 45-6.

5179 1197. Kutlesa M, Mlinaric-Missoni E, Hatvani L, et al. Chronic fungal meningitis caused by
5180 *Aureobasidium proteae*. *Diagn Microbiol Infect Dis* 2012; **73**(3): 271-2.

5181 1198. Lahiri Mukhopadhyay S, Mahadevan A, Bahubali VH, et al. A rare case of multiple brain abscess
5182 and probably disseminated phaeohyphomycosis due to *Cladophialophora bantiana* in an
5183 immunosuppressed individual from India. *J Mycol Med* 2017; **27**(3): 391-5.

5184 1199. Lalueza A, Lopez-Medrano F, del Palacio A, et al. *Cladosporium macrocarpum* brain abscess after
5185 endoscopic ultrasound-guided celiac plexus block. *Endoscopy* 2011; **43** Suppl 2 UCTN: E9-10.

5186 1200. Lang R, Minion J, Skinner S, Wong A. Disseminated *Exophiala dermatitidis* causing septic arthritis
5187 and osteomyelitis. *BMC Infect Dis* 2018; **18**(1): 255.

5188 1201. Lanternier F, Barbati E, Meinzer U, et al. Inherited CARD9 deficiency in 2 unrelated patients with
5189 invasive *Exophiala* infection. *J Infect Dis* 2015; **211**(8): 1241-50.

5190 1202. Lapadat R, Schreckenberger PC. Photo quiz: heart transplant patient with knee drainage.
5191 Answer: *Alternaria* spp. *J Clin Microbiol* 2014; **52**(5): 1313, 810.

5192 1203. Larsen CG, Arendrup MC, Krarup E, Pedersen M, Thybo S, Larsen FG. Subcutaneous
5193 phaeohyphomycosis in a renal transplant recipient successfully treated with voriconazole. *Acta Derm*
5194 *Venerol* 2009; **89**(6): 657-8.

5195 1204. Lastoria C, Cascina A, Bini F, et al. Pulmonary *Cladophialophora boppii* infection in a lung
5196 transplant recipient: case report and literature review. *J Heart Lung Transplant* 2009; **28**(6): 635-7.

5197 1205. Le Naoures C, Bonhomme J, Terzi N, Duhamel C, Galateau-Salle F. A fatal case with disseminated
5198 *Myceliophthora thermophila* infection in a lymphoma patient. *Diagn Microbiol Infect Dis* 2011; **70**(2):
5199 267-9.

5200 1206. Leahy TR, Punnett AS, Richardson SE, Gharabaghi F, Wadhwa A. Molecular identification of
5201 phaeohyphomycosis due to *Alternaria infectoria* in a patient with acute myeloid leukemia--a case
5202 report. *Diagn Microbiol Infect Dis* 2010; **66**(3): 318-21.

5203 1207. Lee AS, Sullivan TJ. Orbital mycoses in a pediatric subtropical population: a case series. *J AAPOS*
5204 2019; **23**(5): 270 e1- e7.

5205 1208. Lee KC, Kim MJ, Chae SY, et al. A Case of Phaeohyphomycosis Caused by *Exophiala lecanii-corni*.
5206 *Ann Dermatol* 2016; **28**(3): 385-7.

5207 1209. Lee SY, Yeo CL, Lee WH, Kwa AL, Koh LP, Hsu LY. Prevalence of invasive fungal disease in
5208 hematological patients at a tertiary university hospital in Singapore. *BMC research notes* 2011; **4**: 42.

5209 1210. Lee WJ, Eun DH, Jang YH, Lee SJ, Bang YJ, Jun JB. A Case of Phaeohyphomycosis on the Wrist:
5210 Identification of *Exophiala spinifera* in Korea. *Ann Dermatol* 2018; **30**(2): 232-3.

5211 1211. Li CW, Lee HC, Chang TC, et al. *Acrophialophora fusispora* brain abscess in a patient with
5212 acquired immunodeficiency syndrome: a case report and review of the literature. *Diagn Microbiol Infect*
5213 *Dis* 2013; **76**(3): 368-71.

5214 1212. Li DM, Li RY, De Hoog GS, Wang YX, Wang DL. *Exophiala asiatica*, a new species from a fatal case
5215 in China. *Medical mycology* 2009; **47**(1): 101-9.

5216 1213. Lief MH, Caplivski D, Bottone EJ, Lerner S, Vidal C, Huprikar S. *Exophiala jeanselmei* infection in
5217 solid organ transplant recipients: report of two cases and review of the literature. *Transpl Infect Dis*
5218 2011; **13**(1): 73-9.

5219 1214. Lim A, Speers D, Inderjeeth C. Cladophialophora (Xylohypha) bantiana--an unusual cause of
5220 septic arthritis. *Rheumatology (Oxford)* 2013; **52**(5): 958-9.

5221 1215. Lin SC, Sun PL, Ju YM, Chan YJ. Cutaneous phaeohyphomycosis caused by Exserohilum rostratum
5222 in a patient with cutaneous T-cell lymphoma. *Int J Dermatol* 2009; **48**(3): 295-8.

5223 1216. Lin YP, Li W, Yang YP, Huang WM, Fan YM. Cutaneous phaeohyphomycosis caused by Exophiala
5224 spinifera in a patient with systemic lupus erythematosus. *Lupus* 2012; **21**(5): 548-51.

5225 1217. Litchevski V, Goldschmidt A, Nass D, Rahav G, Cohen ZR. Cerebral phaeohyphomycosis in an
5226 immunocompetent patient: a case report and literature summary. *Clin Neurol Neurosurg* 2014; **124**:
5227 179-81.

5228 1218. Liu AW, Bateman AC, Greenbaum A, Garvin K, Clarridge J, Grim J. Cutaneous
5229 phaeohyphomycosis in a hematopoietic stem cell transplant patient caused by Alternaria rosae: First
5230 case report. *Transpl Infect Dis* 2017; **19**(3).

5231 1219. Liu H, Zhang J, Chen Y, et al. Phaeohyphomycosis due to Exophiala spinifera greatly improved by
5232 ALA-PDT: A case report. *Photodiagnosis Photodyn Ther* 2019.

5233 1220. Liu M, Xin X, Li J, Chen S. The first case of endophthalmitis due to Rhinocladiella basitona in an
5234 immunocompetent patient. *Diagn Microbiol Infect Dis* 2015; **83**(1): 49-52.

5235 1221. Liu W, Zhao Y, Liu JW, Qian YT, Ma DL. Image Gallery: Cutaneous Phialophora verrucosa
5236 infection in a 28-year-old farmer. *Br J Dermatol* 2019; **180**(5): e143.

5237 1222. Llamas R, Al-Hatmi AM, Martinez G, et al. Non-traumatic keratitis due to Colletotrichum
5238 truncatum. *JMM Case Rep* 2016; **3**(4): e005047.

5239 1223. Lopes L, Borges-Costa J, Soares-Almeida L, et al. Cutaneous Alternariosis Caused by Alternaria
5240 infectoria: Three Cases in Kidney Transplant Patients. *Healthcare (Basel)* 2013; **1**(1): 100-6.

5241 1224. Los-Arcos I, Royuela M, Martin-Gomez MT, et al. Phaeohyphomycosis caused by Medicopsis
5242 romeroi in solid organ transplant recipients: Report of two cases and comprehensive review of the
5243 literature. *Transpl Infect Dis* 2019; **21**(3): e13072.

5244 1225. Lou AY, Wannemuehler TJ, Russell PT, Barahimi B, Sobel RK. Orbital apex syndrome caused by
5245 Alternaria species: A novel invasive fungus and new treatment paradigm. *Orbit* 2019: 1-4.

5246 1226. Lyskova P, Kubanek M, Hubka V, et al. Successful Posaconazole Therapy of Disseminated
5247 Alternariosis due to Alternaria infectoria in a Heart Transplant Recipient. *Mycopathologia* 2017; **182**(3-
5248 4): 297-303.

5249 1227. Madhugiri VS, Bhagavatula ID, Mahadevan A, Siddaiah N. An unusual infection, an unusual
5250 outcome--Fonsecaea pedrosoi cerebral granuloma. *J Neurosurg Pediatr* 2011; **8**(2): 229-32.

5251 1228. Madhugiri VS, Singh R, Vyavahare M, et al. Opportunistic Fonsecaea pedrosoi brain abscess in a
5252 patient with non-cirrhotic portal fibrosis-induced hypersplenism--a novel association. *Br J Neurosurg*
5253 2013; **27**(5): 690-3.

5254 1229. Maduri A, Patnayak R, Verma A, Mudgeti N, Kalawat U, Asha T. Subcutaneous infection by
5255 Cladosporium sphaerospermum-A rare case report. *Indian J Pathol Microbiol* 2015; **58**(3): 406-7.

5256 1230. Mahajan VK, Sharma V, Prabha N, et al. A rare case of subcutaneous phaeohyphomycosis
5257 caused by a Rhytidhysterion species: a clinico-therapeutic experience. *Int J Dermatol* 2014; **53**(12): 1485-
5258 9.

5259 1231. Malakzai MO, Sahak JG, Campbell R, et al. Multifocal but non-disseminated phaeohyphomycosis
5260 in a healthy man via a unique mechanism: Ejection from motor vehicle accident into a vegetable field in
5261 Afghanistan resulting in multiple contaminated skin wounds. *J Cutan Pathol* 2017; **44**(7): 620-4.

5262 1232. Mandell KJ, Colby KA. Penetrating keratoplasty for invasive fungal keratitis resulting from a
5263 thorn injury involving Phomopsis species. *Cornea* 2009; **28**(10): 1167-9.

5264 1233. Manoharan M, Shanmugam N, Veeriyar S. A rare case of a subcutaneous phaeomycotic cyst
5265 with a brief review of literature. *Malays J Med Sci* 2011; **18**(2): 78-81.

5266 1234. Mansour A, Jordan K. Disseminated Cladophialophora bantiana disease in a patient with
5267 prediabetes. *BMJ Case Rep* 2014; **2014**.

5268 1235. Maquine GA, Rodrigues MHG, Schettini APM, Morais PM, Frota MZM. Subcutaneous
5269 phaeohyphomycosis due to Cladophialophora bantiana: a first case report in an immunocompetent
5270 patient in Latin America and a brief literature review. *Rev Soc Bras Med Trop* 2019; **52**: e20180480.

5271 1236. Martanto W, Tee SI, Pan JY. Exophiala deep fungal infection complicating dermatitis artefacta of
5272 the arms responding to itraconazole. *J Eur Acad Dermatol Venereol* 2014; **28**(9): 1262-3.

5273 1237. Martin Ramirez A, Erro Iribarren M, Buendia Moreno B, Maria Giron R. Clinical Deterioration
5274 Due to Exophiala Dermatitis in a Patient with Cystic Fibrosis. *Arch Bronconeumol* 2019; **55**(3): 162-3.

5275 1238. Martinez-Lamas L, Alvarez M, Llovo J, Gene J, Cano J. Phaeohyphomycosis caused by
5276 Cladophialophora bantiana. *Rev Iberoam Micol* 2014; **31**(3): 203-6.

5277 1239. Martone G, Pichierri P, Franceschini R, et al. In vivo confocal microscopy and anterior segment
5278 optical coherence tomography in a case of alternaria keratitis. *Cornea* 2011; **30**(4): 449-53.

5279 1240. Matoba AY, Barrett R, Lehmann AE. Cure Rate of Fungal Keratitis With Antibacterial Therapy.
5280 *Cornea* 2017; **36**(5): 578-80.

5281 1241. Matson DR, Eudy JD, Matson SC. Cutaneous alternariosis in an adolescent patient. *Pediatr*
5282 *Dermatol* 2010; **27**(1): 98-100.

5283 1242. Mattei AS, Severo CB, Guazzelli LS, et al. Cutaneous infection by Diaporthe phaseolorum in
5284 Brazil. *Medical mycology case reports* 2013; **2**: 85-7.

5285 1243. Matthews BJ, Partridge D, Sheard RM, Rennie IG, Mudhar HS. A unique case of
5286 phaeohyphomycosis subretinal abscess in a patient with arthropathy and lung pathology. *Indian J*
5287 *Ophthalmol* 2013; **61**(12): 763-5.

5288 1244. Maudgil A, Johnson Z, Rogers N, Mudhar HS. Unusual ocular presentations of ocular
5289 phaeohyphomycosis. *Eye (Lond)* 2016; **30**(11): 1517-9.

5290 1245. Mazzurco JD, Ramirez J, Fivenson DP. Phaeohyphomycosis caused by Phaeoacremonium species
5291 in a patient taking infliximab. *Journal of the American Academy of Dermatology* 2012; **66**(2): 333-5.

5292 1246. McNeil CJ, Luo RF, Vogel H, Banaei N, Ho DY. Brain abscess caused by Phaeoacremonium
5293 parasiticum in an immunocompromised patient. *J Clin Microbiol* 2011; **49**(3): 1171-4.

5294 1247. Mehta SR, Johns S, Stark P, Fierer J. Successful treatment of Aureobasidium pullulans central
5295 catheter-related fungemia and septic pulmonary emboli. *IDCases* 2017; **10**: 65-7.

5296 1248. Meriden Z, Marr KA, Lederman HM, et al. Ochroconis gallopava infection in a patient with
5297 chronic granulomatous disease: case report and review of the literature. *Med Mycol* 2012; **50**(8): 883-9.

5298 1249. Merlo C, Merlo P, Holzinger F, Pranghofer S, Pfeiffer D, Nuesch R. [A very slow growing ankle
5299 swelling in a healthy male]. *Praxis (Bern 1994)* 2014; **103**(17): 1023-6.

5300 1250. Mershon-Shier KL, Deville JG, Delair S, et al. Aureobasidium pullulans var. melanigenum
5301 fungemia in a pediatric patient. *Medical mycology* 2011; **49**(1): 80-3.

5302 1251. Michelon M, Greenlaw S, O'Donnell P, Geist D, Levin NA. Multifocal cutaneous alternariosis in a
5303 70-year-old Kenyan renal transplant patient. *Dermatol Online J* 2014; **20**(7).

5304 1252. Miqueleiz Zapatero A, Hernando C, Barba J, Buendia B. [First report of a case of fungal keratitis
5305 due to Curvularia hominis in Spain]. *Rev Iberoam Micol* 2018; **35**(3): 155-8.

5306 1253. Miqueleiz-Zapatero A, Santa Olalla C, Buendia B, Barba J. Dermatomycosis due to
5307 Neoscytalidium spp. *Enferm Infecc Microbiol Clin* 2017; **35**(2): 130-1.

5308 1254. Mirhendi H, Fatemi MJ, Bateni H, et al. First case of disseminated phaeohyphomycosis in an
5309 immunocompetent individual due to Alternaria malorum. *Medical mycology* 2013; **51**(2): 196-202.

5310 1255. Mishra D, Singal M, Rodha MS, Subramanian A. Subcutaneous phaeohyphomycosis of foot in an
5311 immunocompetent host. *J Lab Physicians* 2011; **3**(2): 122-4.

5312 1256. Mishra K, Das S, Goyal S, et al. Subcutaneous mycoses caused by Rhytidhysterion species in an
5313 immunocompetent patient. *Medical mycology case reports* 2014; **5**: 32-4.

5314 1257. Mittal J, Szymczak WA, Pirofski LA, Galen BT. Fungemia caused by Aureobasidium pullulans in a
5315 patient with advanced AIDS: a case report and review of the medical literature. *JMM Case Rep* 2018;
5316 **5**(4): e005144.

5317 1258. Miyagawa F, Shobatake C, Fukumoto T, et al. Cutaneous phaeohyphomycosis caused by
5318 Exophiala jeanselmei in a healthy individual. *J Dermatol* 2018; **45**(1): 106-8.

5319 1259. Miyakubo T, Todokoro D, Makimura K, Akiyama H. Fungal keratitis caused by Didymella
5320 gardeniae (formerly Phoma gardeniae) successfully treated with topical voriconazole and miconazole.
5321 *Medical mycology case reports* 2019; **24**: 90-2.

- 5322 1260. Mohammadi R, Mohammadi A, Ashtari F, et al. Cerebral phaeohyphomycosis due to
5323 Rhinocladiella mackenziei in Persian Gulf region: A case and review. *Mycoses* 2018; **61**(4): 261-5.
- 5324 1261. Mohammed A, Rahnama-Moghadam S. Following the Track to an Unexpected Diagnosis:
5325 Phaeohyphomycosis. *Am J Med* 2019; **132**(9): 1047-9.
- 5326 1262. Mohd Tap R, Sabaratnam P, Ahmad NA, Abd Razak MF, Hashim R, Ahmad N. Chaetomium
5327 globosum Cutaneous Fungal Infection Confirmed by Molecular Identification: A Case Report from
5328 Malaysia. *Mycopathologia* 2015; **180**(1-2): 137-41.
- 5329 1263. Monaganti S, Santos CA, Markwardt A, Pence MA, Brennan DC. Pulmonary phaeohyphomycosis
5330 caused by phaeoacremonium in a kidney transplant recipient: successful treatment with posaconazole.
5331 *Case Rep Med* 2014; **2014**: 902818.
- 5332 1264. Monno R, Alessio G, Guerriero S, et al. Alternaria is an Infrequent Cause of Keratitis: A Case
5333 Report and Review of the Literature. *Eye Contact Lens* 2015; **41**(4): e14-7.
- 5334 1265. Montone KT, LiVolsi VA, Lanza DC, et al. In situ hybridization for specific fungal organisms in
5335 acute invasive fungal rhinosinusitis. *Am J Clin Pathol* 2011; **135**(2): 190-9.
- 5336 1266. Moody MN, Tschen J, Mesko M. Cutaneous Curvularia infection of the forearm. *Cutis* 2012;
5337 **89**(2): 65-8.
- 5338 1267. Morais OO, Porto C, Coutinho AS, Reis CM, Teixeira Mde M, Gomes CM. Infection of the
5339 lymphatic system by Aureobasidium pullulans in a patient with erythema nodosum leprosum. *Braz J*
5340 *Infect Dis* 2011; **15**(3): 288-92.
- 5341 1268. Morales AM, Charlez L, Remon L, Sanz P, Aspiroz C. [Cutaneous alternariosis in a heart
5342 transplant recipient]. *Actas Dermosifiliogr* 2010; **101**(4): 370-2.
- 5343 1269. Moran C, Delafield NL, Kenny G, et al. A case of Verruconis gallopava infection in a heart
5344 transplant recipient successfully treated with posaconazole. *Transpl Infect Dis* 2019; **21**(2): e13044.
- 5345 1270. Morio F, Berre JY, Garcia-Hermoso D, et al. Phaeohyphomycosis due to Exophiala xenobiotica as
5346 a cause of fungal arthritis in an HIV-infected patient. *Medical mycology* 2012; **50**(5): 513-7.
- 5347 1271. Morio F, Fraissinet F, Gastinne T, et al. Invasive Myceliophthora thermophila infection mimicking
5348 invasive aspergillosis in a neutropenic patient: a new cause of cross-reactivity with the Aspergillus
5349 galactomannan serum antigen assay. *Medical mycology* 2011; **49**(8): 883-6.
- 5350 1272. Mostofi K, Jeanbourquin D, Charles JI. Cervical spondylitis due to Phaeoacremonium
5351 venezuelense in an immunocompetent patient. A first case report. *J Mycol Med* 2012; **22**(2): 197-200.
- 5352 1273. Moutran R, Maatouk I, Wehbe J, Abadjian G, Obeid G. [Subcutaneous infection spread by
5353 Scytalidium (Neoscytalidium) dimidiatum]. *Ann Dermatol Venereol* 2012; **139**(3): 204-8.
- 5354 1274. Mudhigeti N, Patnayak R, Kalawat U, Yeddula SRC. Subcutaneous Rhytidhysterion Infection: A
5355 Case Report from South India with Literature Review. *Cureus* 2018; **10**(4): e2406.
- 5356 1275. Mudholkar VG, Acharya AS, Ramteke RV. Disseminated cutaneous phaeohyphomycosis in
5357 immunocompetent child. *Pediatr Dermatol* 2011; **28**(1): 30-1.
- 5358 1276. Mukai Y, Nureki S, Hata M, et al. Exophiala dermatitidis pneumonia successfully treated with
5359 long-term itraconazole therapy. *J Infect Chemother* 2014; **20**(7): 446-9.
- 5360 1277. Mulcahy H, Chew FS. Phaeoacremonium parasiticum myositis: A case report with imaging
5361 findings. *Radiol Case Rep* 2011; **6**(2): 485.
- 5362 1278. Naik M, Mohd S, Sheth J, Sunderamoorthy SK. Alternaria keratitis after deep anterior lamellar
5363 keratoplasty. *Middle East Afr J Ophthalmol* 2014; **21**(1): 92-4.
- 5364 1279. Naik V, Ahmed FU, Gupta A, et al. Intracranial Fungal Granulomas: A Single Institutional
5365 Clinicopathologic Study of 66 Patients and Review of the Literature. *World Neurosurg* 2015; **83**(6): 1166-
5366 72.
- 5367 1280. Najafzadeh MJ, Fata A, Naseri A, et al. Implantation phaeohyphomycosis caused by a non-
5368 sporulating Chaetomium species. *J Mycol Med* 2014; **24**(2): 161-5.
- 5369 1281. Najafzadeh MJ, Suh MK, Lee MH, et al. Subcutaneous phaeohyphomycosis caused by Exophiala
5370 equina, with susceptibility to eight antifungal drugs. *J Med Microbiol* 2013; **62**(Pt 5): 797-800.
- 5371 1282. Nalcacioglu H, Yakupoglu YK, Genc G, et al. Disseminated fungal infection by Aureobasidium
5372 pullulans in a renal transplant recipient. *Pediatr Transplant* 2018; **22**(3): e13152.

- 5373 1283. Nandedkar S, Bajpai T, Bhatambare GS, Sakhi P. Cerebral phaeohyphomycosis: A rare case from
5374 central India. *Asian J Neurosurg* 2015; **10**(2): 142-4.
- 5375 1284. Nath R, Baruah S, Saikia L, Devi B, Borthakur AK, Mahanta J. Mycotic corneal ulcers in upper
5376 Assam. *Indian J Ophthalmol* 2011; **59**(5): 367-71.
- 5377 1285. Nayyar C, Gulati N, Sherwal BL. A rare case of phaeohyphomycosis caused by *Fonsecaea*
5378 *pedrosoi* in a child with nephrotic syndrome. *Indian J Nephrol* 2016; **26**(3): 220-2.
- 5379 1286. Nelson G, Fermo O, Thakur K, et al. Resolution of a fungal mycotic aneurysm after a
5380 contaminated steroid injection: a case report. *BMC research notes* 2014; **7**: 327.
- 5381 1287. Neoh CF, Leung L, Vajpayee RB, Stewart K, Kong DC. Treatment of *Alternaria* keratitis with
5382 intrastromal and topical caspofungin in combination with intrastromal, topical, and oral voriconazole.
5383 *Ann Pharmacother* 2011; **45**(5): e24.
- 5384 1288. Nguyen Y, Dodds T, Lowe P. Cutaneous *Microspora arundinis* infection in renal transplant
5385 recipients-A report of 2 cases and review of the literature. *JAAD Case Rep* 2018; **4**(5): 415-7.
- 5386 1289. Nieto-Rios JF, Villafane-Bermudez DR, Guerrero-Tinoco GA, et al. Brain abscess caused by
5387 *Cladophialophora bantiana* after renal allograft loss: A case report. *Biomedica* 2019; **39**(Supl. 2): 20-5.
- 5388 1290. Noguchi H, Hiruma M, Matsumoto T, et al. Subcutaneous cystic phaeohyphomycosis due to
5389 *Pleurostomophora richardsiae*. *J Dermatol* 2017; **44**(4): e62-e3.
- 5390 1291. Nomura M, Maeda M, Seishima M. Subcutaneous phaeohyphomycosis caused by *Exophiala*
5391 *jeanselmei* in collagen disease patient. *J Dermatol* 2010; **37**(12): 1046-50.
- 5392 1292. Ochiai H, Kawano H, Minato S, Yoneyama T, Shimao Y. Cerebral phaeohyphomycosis: case
5393 report. *Neuropathology* 2012; **32**(2): 202-6.
- 5394 1293. Oehler RL, Katzman JH, Kraitman N, Vega-Rodriguez V, Toney JF. Sticks and bones: Traumatic
5395 phaeohyphomycosis presenting as an epidural scalp abscess and cranial osteomyelitis. *Medical*
5396 *mycology case reports* 2019; **24**: 75-7.
- 5397 1294. Ogawa M, Reis V, Godoy P, Gatti de Menezes F, Enokihara M, Tomimori J. [Phaeohyphomycosis
5398 caused by *Colletotrichum gloeosporioides* and *Alternaria infectoria* in renal transplant recipient]. *Rev*
5399 *Chilena Infectol* 2014; **31**(4): 468-72.
- 5400 1295. Okamoto Y, Yamaguchi S, Sonosaki T, Sano A, Takahashi K. Subcutaneous phaeohyphomycosis
5401 caused by *Veronaea botryosa* in a Japanese patient with adult T-cell lymphoma. *J Dermatol* 2018; **45**(5):
5402 e124-e5.
- 5403 1296. Oliveira LR, Moraes-Souza H, Maltos AL, Santos KC, Molina RJ, Barata CH. *Aureobasidium*
5404 *pullulans* infection in a patient with chronic lymphocytic leukemia. *Rev Soc Bras Med Trop* 2013; **46**(5):
5405 660-2.
- 5406 1297. Osmond GW, Walters RW, Puri PK. Cutaneous alternariosis microscopically mimicking
5407 blastomycosis. *J Cutan Pathol* 2011; **38**(11): 923-5.
- 5408 1298. Ottaviani S, Gill G, Choudat L, Rioux C, Dieude P. Nodule of Achilles tendon in a patient with
5409 kidney transplant revealing phaeohyphomycosis. *Int J Dermatol* 2018; **57**(7): 867-8.
- 5410 1299. Ozdemir HG, Kandemir H, Curuk A, Ilkit M, Seyedmousavi S. Infrequent Production of
5411 Xanthomegnin by Fungal Strains Recovered from Patients with Ocular Mycoses. *Mycopathologia* 2016;
5412 **181**(3-4): 241-6.
- 5413 1300. Oztas E, Odemis B, Kekilli M, et al. Systemic phaeohyphomycosis resembling primary sclerosing
5414 cholangitis caused by *Exophiala dermatitidis*. *J Med Microbiol* 2009; **58**(Pt 9): 1243-6.
- 5415 1301. Pai HV, Jamal E, Yegneswaran PP. Corneal ulcer due to a rare pleosporalean member of the
5416 genus *Bipolaris* following cow tail injury to the eye: A case report and review of literature. *Indian J*
5417 *Ophthalmol* 2017; **65**(5): 403-5.
- 5418 1302. Palavutitotai N, Chongtrakoo P, Ngamskulrungraj P, Chayakulkeeree M. Nocardia Beijingensis
5419 Psoas Abscess and Subcutaneous Phaeohyphomycosis Caused by *Phaeoacremonium Parasiticum* in a
5420 Renal Transplant Recipient: The First Case Report in Thailand. *Southeast Asian J Trop Med Public Health*
5421 2015; **46**(6): 1049-54.
- 5422 1303. Palmisano A, Morio F, Le Pape P, et al. Multifocal phaeohyphomycosis caused by *Exophiala*
5423 *xenobiotica* in a kidney transplant recipient. *Transpl Infect Dis* 2015; **17**(2): 297-302.

5424 1304. Papakostas TD, Kohanim S, Skondra D, Lo K, Chodosh J. Medical management of *Alternaria*
5425 keratitis with endophthalmitis in a patient with a corneal graft. *Clin Exp Ophthalmol* 2014; **42**(5): 496-7.
5426 1305. Patel RC, Helm M, Shimizu I. Cutaneous alternariosis in an immunocompetent patient. *Dermatol*
5427 *Online J* 2016; **22**(10).

5428 1306. Patel VM, Kapadiya B, Shah V. Subcutaneous Phaeohyphomycosis caused by *Cladophialophora*
5429 *bantiana* after Abdominal Hernia Surgery. *J Assoc Physicians India* 2016; **64**(5): 79-80.

5430 1307. Pathengay A, Miller DM, Flynn HW, Jr., Dubovy SR. *Curvularia* endophthalmitis following open
5431 globe injuries. *Arch Ophthalmol* 2012; **130**(5): 652-4.

5432 1308. Patil S, Kulkarni S, Gadgil S, Joshi A. Corneal abscess caused by *Bipolaris spicifera*. *Indian J Pathol*
5433 *Microbiol* 2011; **54**(2): 408-10.

5434 1309. Patra S, Vij M, Kancharla R, Lingappa L, Rela M. Systemic *Wangiella dermatitidis* infection
5435 presenting as liver mass and obstructive cholangiopathy. *Trop Gastroenterol* 2013; **34**(4): 277-9.

5436 1310. Pereira RR, Nayak CS, Deshpande SD, Bhatt KD, Khatu SS, Dhurat RS. Subcutaneous
5437 phaeohyphomycosis caused by *Cladophialophora boppii*. *Indian J Dermatol Venereol Leprol* 2010; **76**(6):
5438 695-8.

5439 1311. Perin AF, Goyal S, Rosenbaum ER, Uwaydat SH. *Lysinibacillus* spp. Endophthalmitis: a First
5440 Reported Case. *Ann Clin Lab Sci* 2015; **45**(5): 607-8.

5441 1312. Persy B, Vrelust I, Gadsisseur A, Ieven M. *Phialemonium curvatum* fungaemia in an
5442 immunocompromised patient: case report. *Acta Clin Belg* 2011; **66**(5): 384-6.

5443 1313. Pikazis D, Xynos ID, Xila V, Velegraki A, Aroni K. Extended fungal skin infection due to
5444 *Aureobasidium pullulans*. *Clin Exp Dermatol* 2009; **34**(8): e892-4.

5445 1314. Pincus LB, Schwartz BS, Cunningham G, Saeed S, Berger TG. Cutaneous phaeohyphomycosis
5446 caused by *Cladophialophora bantiana* in a scar after treatment with intralesional corticosteroid
5447 injections. *Journal of the American Academy of Dermatology* 2009; **61**(3): 537-8.

5448 1315. Pinheiro RL, Cognialli RCR, Barros RC, et al. Peritonitis by *Exophiala dermatitidis* in a pediatric
5449 patient. *Medical mycology case reports* 2019; **24**: 18-22.

5450 1316. Pong DL, Marom T, Makishima T. *Phialemonium* infection complicating chronic suppurative
5451 otitis media. *Medical mycology case reports* 2014; **4**: 5-7.

5452 1317. Ponnuswamy K, Muthureddy Y, Sigamani K. Two cases of multiple subcutaneous cystic
5453 phaeohyphomycosis in immunocompromised patients with a rare causative organism. *Indian J Dermatol*
5454 2014; **59**(4): 421.

5455 1318. Posteraro B, Scarano E, La Sorda M, et al. Eosinophilic fungal rhinosinusitis due to the unusual
5456 pathogen *Curvularia inaequalis*. *Mycoses* 2010; **53**(1): 84-8.

5457 1319. Prigitano A, Cavanna C, Passera M, et al. Evolution of fungemia in an Italian region. *J Mycol Med*
5458 2019: 100906.

5459 1320. Qiu WY, Yao YF. Mycotic keratitis caused by concurrent infections of *Exserohilum mcginnisii* and
5460 *Candida parapsilosis*. *BMC Ophthalmol* 2013; **13**(1): 37.

5461 1321. Quintero-Estades JA, Walter S, Valenzuela F, Amescua G. Delayed-onset postoperative
5462 endophthalmitis secondary to *Exophiala*. *BMJ Case Rep* 2015; **2015**.

5463 1322. Qureshi ZA, Kwak EJ, Nguyen MH, Silveira FP. *Ochroconis gallopava*: a dematiaceous mold
5464 causing infections in transplant recipients. *Clin Transplant* 2012; **26**(1): E17-23.

5465 1323. Rachitskaya AV, Reddy AK, Miller D, et al. Prolonged *Curvularia* endophthalmitis due to organism
5466 sequestration. *JAMA Ophthalmol* 2014; **132**(9): 1123-6.

5467 1324. Radhakrishnan D, Jayalakshmi G, Madhumathy A, Banu ST, Geethalakshmi S, Sumathi G.
5468 Subcutaneous phaeohyphomycosis due to *Exophiala spinifera* in an immunocompromised host. *Indian J*
5469 *Med Microbiol* 2010; **28**(4): 396-9.

5470 1325. Rammaert B, Aguilar C, Bougnoux ME, et al. Success of posaconazole therapy in a heart
5471 transplanted patient with *Alternaria* infectoria cutaneous infection. *Medical mycology* 2012; **50**(5): 518-
5472 21.

5473 1326. Rao CY, Pachucki C, Cali S, et al. Contaminated product water as the source of *Phialemonium*
5474 *curvatum* bloodstream infection among patients undergoing hemodialysis. *Infect Control Hosp*
5475 *Epidemiol* 2009; **30**(9): 840-7.

5476 1327. Rathi H, Venugopal A, Rameshkumar G, Ramakrishnan R, Meenakshi R. Fungal Keratitis Caused
5477 by Exserohilum, An Emerging Pathogen. *Cornea* 2016; **35**(5): 644-6.

5478 1328. Rattanaumpawan P, Tantimavanich S, Tiengrim S, Aswapokee N. Disseminated
5479 Cladophialophora bantiana infection in an idiopathic thrombocytopenic purpura patient: a case report.
5480 *Mycoses* 2011; **54**(6): 544-8.

5481 1329. Ravisankar S, Chander RV. Cerebral phaeohyphomycosis: report of a rare case with review of
5482 literature. *Neurol India* 2013; **61**(5): 526-8.

5483 1330. Rawal YB, Kalmar JR. Intraoral phaeohyphomycosis. *Head Neck Pathol* 2012; **6**(4): 481-5.

5484 1331. Ray U, Dutta S, Chakravarty C. A Cladophialophora Brain Abscess in a Renal Transplant Recipient.
5485 *Southeast Asian J Trop Med Public Health* 2016; **47**(5): 1026-31.

5486 1332. Raza H, Khan RU, Anwar K, Muhammad K. Visceral phaeohyphomycosis caused by *Alternaria*
5487 *alternata* offering a diagnostic as well as a therapeutic challenge. *Saudi J Kidney Dis Transpl* 2015; **26**(2):
5488 339-43.

5489 1333. Reddy M, Venugopal R, Prakash PY, Kamath YS. Corneal ulcer due to a rare coelomycetes fungus
5490 *Chaetomium strumarium*: Case report and global review of *Chaetomium* keratomycosis. *Indian J*
5491 *Ophthalmol* 2017; **65**(9): 871-4.

5492 1334. Revankar SG. Cladophialophora bantiana brain abscess in an immunocompetent patient. *Can J*
5493 *Infect Dis Med Microbiol* 2011; **22**(4): 149-50.

5494 1335. Reynaud Q, Dupont D, Nove-Josserand R, et al. Rare and unusual presentation of
5495 Cladophialophora infection in a pulmonary transplant cystic fibrosis patient. *Transpl Infect Dis* 2017;
5496 **19**(6).

5497 1336. Richey PM, Radfar A, Damavandy AA. Ulcerative Pretibial Lesions in the Setting of Multifactorial
5498 Immunosuppression. *JAMA Dermatol* 2016; **152**(1): 85-6.

5499 1337. Rivero M, Hidalgo A, Alastruey-Izquierdo A, Cia M, Torroba L, Rodriguez-Tudela JL. Infections
5500 due to *Phialemonium* species: case report and review. *Medical mycology* 2009; **47**(7): 766-74.

5501 1338. Robert T, Talarmin JP, Leterrier M, et al. Phaeohyphomycosis due to *Alternaria* infectoria: a
5502 single-center experience with utility of PCR for diagnosis and species identification. *Medical mycology*
5503 2012; **50**(6): 594-600.

5504 1339. Roehm CE, Salazar JC, Hagstrom N, Valdez TA. *Phoma* and *Acremonium* invasive fungal
5505 rhinosinusitis in congenital acute lymphocytic leukemia and literature review. *Int J Pediatr*
5506 *Otorhinolaryngol* 2012; **76**(10): 1387-91.

5507 1340. Romo A, Fernandez G, Rodriguez JL, Silva JM. [Non-specific cutaneous lesion in a 17-year-old
5508 pregnant adolescent]. *Enferm Infecc Microbiol Clin* 2009; **27**(3): 189-90.

5509 1341. Rosow L, Jiang JX, Deuel T, et al. Cerebral phaeohyphomycosis caused by *Bipolaris spicifera* after
5510 heart transplantation. *Transpl Infect Dis* 2011; **13**(4): 419-23.

5511 1342. Rossetto AL, Dellatorre G, Persio RA, Romeiro JC, Cruz RC. Subcutaneous phaeohyphomycosis on
5512 the scrotum caused by *Exophiala jeanselmei*: case report. *An Bras Dermatol* 2010; **85**(4): 517-20.

5513 1343. Russo JP, Raffaelli R, Ingrassia SM, Rafti P, Mestroni S. Cutaneous and subcutaneous
5514 phaeohyphomycosis. *Skinmed* 2010; **8**(6): 366-9.

5515 1344. Lavergne RA, Cassaing S, Nocera T, et al. Simultaneous cutaneous infection due to *Paecilomyces*
5516 *lilacinus* and *Alternaria* in a heart transplant patient. *Transpl Infect Dis* 2012; **14**(6): E156-60.

5517 1345. Saeedi OJ, Iyer SA, Mohiuddin AZ, Hogan RN. *Exophiala jeanselmei* keratitis: case report and
5518 review of literature. *Eye Contact Lens* 2013; **39**(6): 410-2.

5519 1346. Saegeman VS, Dupont LJ, Verleden GM, Lagrou K. *Paecilomyces lilacinus* and *alternaria*
5520 *infectoria* cutaneous infections in a sarcoidosis patient after double-lung transplantation. *Acta Clin Belg*
5521 2012; **67**(3): 219-21.

5522 1347. Sakata Y, Kitayama A, Yoshimura R, et al. Case of cutaneous phaeohyphomycosis caused by
5523 *Phaeoacremonium* sp. in a renal transplant recipient. *J Dermatol* 2015; **42**(3): 263-6.

5524 1348. Salameire D. [Cutaneous neutrophils infiltrates. Case 4. Pseudo-tumoral cutaneous
5525 alternariosis]. *Ann Pathol* 2011; **31**(3): 183-8.

5526 1349. Salehi M, Zibafar E, Mahmoudi S, et al. First report of invasive pulmonary infection by *Didymella*
5527 *microchlamydospora* and successful treatment with voriconazole. *Clin Microbiol Infect* 2019; **25**(3): 392-
5528 3.

5529 1350. Salido-Vallejo R, Linares-Sicilia MJ, Garnacho-Saucedo G, et al. Subcutaneous
5530 phaeohyphomycosis due to *Alternaria* infectoria in a renal transplant patient: surgical treatment with no
5531 long-term relapse. *Rev Iberoam Micol* 2014; **31**(2): 149-51.

5532 1351. Sang H, Zheng XE, Kong QT, et al. A rare complication of ear piercing: a case of subcutaneous
5533 phaeohyphomycosis caused by *Veronea botryosa* in China. *Med Mycol* 2011; **49**(3): 296-302.

5534 1352. Ledwaba L, Tavel JA, Khabo P, et al. Pre-ART levels of inflammation and coagulation markers are
5535 strong predictors of death in a South African cohort with advanced HIV disease. *PLoS one* 2012; **7**(3):
5536 e24243.

5537 1353. Santiago F, Serra D, Vieira R, Brites MM, Figueiredo A. Successful cryotherapy for a cutaneous
5538 alternariosis in a renal transplant recipient. *Eur J Dermatol* 2010; **20**(6): 841.

5539 1354. Sato E, Togawa A, Masaki M, et al. Community-acquired Disseminated *Exophiala dermatitidis*
5540 Mycosis with Necrotizing Fasciitis in Chronic Graft-versus-host Disease. *Intern Med* 2019; **58**(6): 877-82.

5541 1355. Sato T, Yaguchi T. A case of phaeohyphomycosis of the face caused by *Exophiala oligosperma* in
5542 an immunocompromised host. *J Dtsch Dermatol Ges* 2013; **11**(11): 1087-9.

5543 1356. Satta R, Dore MP, Pes GM, Biondi G. Iatrogenic immunosuppression may favour *Alternaria* skin
5544 lesion flares. *BMJ Case Rep* 2018; **2018**.

5545 1357. Schuermans W, Hoet K, Stessens L, et al. Molecular Identification of Cutaneous Alternariosis in a
5546 Renal Transplant Patient. *Mycopathologia* 2017; **182**(9-10): 873-7.

5547 1358. Schweizer LA, Barlocher L, Graber A, Boggian K. Brain abscess caused by *Cladophialophora*
5548 *bantiana*: Total remission after full resection and short-course Voriconazole treatment. *Medical*
5549 *mycology case reports* 2019; **23**: 43-5.

5550 1359. Secnikova Z, Juzlova K, Vojackova N, et al. The rare case of *Alternaria alternata* cutaneous and
5551 pulmonary infection in a heart transplant recipient treated by azole antifungals. *Dermatol Ther* 2014;
5552 **27**(3): 140-3.

5553 1360. Segner S, Jouret F, Durant JF, Marot L, Kanaan N. Cutaneous infection by *Alternaria* infectoria in
5554 a renal transplant patient. *Transpl Infect Dis* 2009; **11**(4): 330-2.

5555 1361. Selvin SS, Korah SM, Michael JS, Raj PM, Jacob P. Series of five cases of *Papulaspora equi*
5556 keratomycosis. *Cornea* 2014; **33**(6): 640-3.

5557 1362. Seneviratne CJ, Fong PH, Wong SS, Lee VH. Antifungal susceptibility and phenotypic
5558 characterization of oral isolates of a black fungus from a nasopharyngeal carcinoma patient under
5559 radiotherapy. *BMC Oral Health* 2015; **15**: 39.

5560 1363. Shah SK, Parto P, Lombard GA, et al. Probable *Phaeoacremonium parasiticum* as a cause of
5561 cavitary native lung nodules after single lung transplantation. *Transpl Infect Dis* 2013; **15**(1): E9-13.

5562 1364. Sharifkashani B, Farshidpour M, Droudinia A, et al. Cutaneous alternariosis with trichosporon
5563 infection in a heart transplant recipient: a case report. *Exp Clin Transplant* 2013; **11**(5): 464-6.

5564 1365. Shen YC, Wang CY, Tsai HY, Lee HN. Intracameral voriconazole injection in the treatment of
5565 fungal endophthalmitis resulting from keratitis. *Am J Ophthalmol* 2010; **149**(6): 916-21.

5566 1366. Shi CR, Robinson SN, LaChance A, Mihm MC, Jr., Kroshinsky D. A 53-Year-Old Male with Relapsed
5567 Diffuse Large B-Cell Lymphoma on Chemotherapy with a New Leg Lesion. *Dermatopathology (Basel)*
5568 2017; **4**(1-4): 31-5.

5569 1367. Shi D, Lu G, Mei H, et al. Subcutaneous infection by *Ochroconis mirabilis* in an
5570 immunocompetent patient. *Medical mycology case reports* 2016; **11**: 44-7.

5571 1368. Shigemura T, Agematsu K, Yamazaki T, et al. Femoral osteomyelitis due to *Cladophialophora*
5572 *arxii* in a patient with chronic granulomatous disease. *Infection* 2009; **37**(5): 469-73.

5573 1369. Shimogawa T, Sayama T, Haga S, Akiyama T, Makihara K, Morioka T. [Brain Abscess due to
5574 Infection with Dematiaceous Fungi *Cladophialophora bantiana* Associated with
5575 Hypogammaglobulinemia Following Gastrectomy: A Case Report]. *No Shinkei Geka* 2016; **44**(1): 59-66.

5576 1370. Shirbur S, Telkar S, Goudar B, Mathew T. Recurrent phaeohyphomycosis: a case report. *J Clin*
5577 *Diagn Res* 2013; **7**(9): 2015-6.

- 5578 1371. Shrivastava A, Tadepalli K, Goel G, Gupta K, Kumar Gupta P. Melanized fungus as an Epidural
5579 abscess: A diagnostic and therapeutic challenge. *Medical mycology case reports* 2017; **16**: 20-4.
- 5580 1372. Shruti S, Singh A, Ramesh V, Siraj F. Phaeohyphomycosis of the Face Masquerading as Basal Cell
5581 Carcinoma in an Immunocompetent Patient. *Indian Dermatol Online J* 2017; **8**(4): 271-3.
- 5582 1373. Shukla A, Bansal M, Husain M, Chhabra DK. Central nervous system mycosis: analysis of 10
5583 cases. *Indian J Pathol Microbiol* 2014; **57**(4): 591-4.
- 5584 1374. Shukla M, Vidyarani, Mathews A, Pandey M. Phaeohyphomycosis masquerading as a palatal
5585 neoplasm in a patient who is immunocompetent. *BMJ Case Rep* 2009; **2009**.
- 5586 1375. Silva WC, Goncalves SS, Santos DW, Padovan AC, Bizerra FC, Melo AS. Species diversity,
5587 antifungal susceptibility and phenotypic and genotypic characterisation of *Exophiala* spp. infecting
5588 patients in different medical centres in Brazil. *Mycoses* 2017; **60**(5): 328-37.
- 5589 1376. Silveira CJ, Amaral J, Gorayeb RP, Cabral J, Pacheco T. Fungal meningoencephalitis caused by
5590 *Alternaria*: a clinical case. *Clin Drug Investig* 2013; **33 Suppl 1**: S27-31.
- 5591 1377. Singh S, Shrivastav A, Agarwal M, Gandhi A, Mayor R, Paul L. A rare case of scleral buckle
5592 infection with *Curvularia* species. *BMC Ophthalmol* 2018; **18**(1): 35.
- 5593 1378. Sisk RA, Smiddy WE, Dubovy SR, Miller D. Chronic *curvularia lunata* endophthalmitis following
5594 cataract extraction. *Retin Cases Brief Rep* 2009; **3**(4): 438-9.
- 5595 1379. Sivagnanam S, Chen SC, Halliday C, Packham D. *Thermomyces lanuginosus* infective
5596 endocarditis: Case report and a review of endocarditis due to uncommon moulds. *Medical mycology
5597 case reports* 2013; **2**: 152-5.
- 5598 1380. Skovrlj B, Haghighi M, Smethurst ME, Caridi J, Bederson JB. *Curvularia* abscess of the brainstem.
5599 *World Neurosurg* 2014; **82**(1-2): 241 e9-13.
- 5600 1381. Sladekova M, Poczova M, Gaspar M, et al. First case of systemic phaeohyphomycosis due to
5601 *Cladophialophora bantiana* in Slovakia. *JMM Case Rep* 2014; **1**(4): e002659.
- 5602 1382. Sood S, Vaid VK, Sharma M, Bhartiya H. Cerebral phaeohyphomycosis by *Exophiala dermatitidis*.
5603 *Indian J Med Microbiol* 2014; **32**(2): 188-90.
- 5604 1383. Sood V, Pattanashetti N, Gupta S, Rudramurthy SM, Ramachandran R, Gupta KL. Multiple
5605 cerebral abscesses in a renal transplant recipient: Two swords in one scabbard! *Medical mycology case
5606 reports* 2019; **23**: 50-2.
- 5607 1384. Spriet I, Lambrecht C, Lagrou K, Verhamme B. Successful eradication of *Scytalidium dimidiatum*-
5608 induced ungual and cutaneous infection with voriconazole. *Eur J Dermatol* 2012; **22**(2): 197-9.
- 5609 1385. Sribenjalux W, Chongtrakool P, Chayakulkeeree M. Disseminated phaeohyphomycosis with
5610 hepatic artery and portal vein thrombosis caused by *Pleurostomophora richardsiae* in a liver transplant
5611 recipient: A case report. *Transpl Infect Dis* 2019; **21**(3): e13075.
- 5612 1386. Stock RA, Bonamigo EL, Cadore E, Oechsler RA. Infectious crystalline keratopathy caused by
5613 *Cladosporium* sp. after penetrating keratoplasty: a case report. *Int Med Case Rep J* 2016; **9**: 267-71.
- 5614 1387. Studer M, Spingard B, Barbaud A, Beurey P, Schmutz JL. [Chronic ulceration of the dorsal hand].
5615 *Ann Dermatol Venereol* 2010; **137**(1): 60-2.
- 5616 1388. Suchanda B, Alugolu R, Purohit A, Lakshmi V, Sundaram C. A rare concomitant tubercular and
5617 *Fonsecaea pedrosoi* fungal infection of the skull base. *J Neurosci Rural Pract* 2012; **3**(2): 189-91.
- 5618 1389. Suda K, Yamashita T, Kawase Y, et al. Cutaneous phaeohyphomycosis caused by *Alternaria*
5619 *alternata* in an immunosuppressed patient. *J Dermatol* 2019.
- 5620 1390. Sun S, Yuan G, Zhao G, Chen H, Yu B. Endophthalmitis caused by *Phialophora verrucosa* and
5621 *Streptococcus intermedius*: a case report. *Medical mycology* 2010; **48**(8): 1108-11.
- 5622 1391. Sunada A, Asari S, Inoue Y, et al. [Multicenter Prospective Observational Study of Fungal
5623 Keratitis--Identification and Susceptibility Test of Fungi]. *Nippon Ganka Gakkai Zasshi* 2016; **120**(1): 17-
5624 27.
- 5625 1392. Suri P, Chhina DK, Kaushal V, Kaushal RK, Singh J. Cerebral Phaeohyphomycosis due to
5626 *Cladophialophora bantiana* - A Case Report and Review of Literature from India. *J Clin Diagn Res* 2014;
5627 **8**(4): DD01-5.

5628 1393. Suzuki K, Nakamura A, Fujieda A, Nakase K, Katayama N. Pulmonary infection caused by
5629 *Exophiala dermatitidis* in a patient with multiple myeloma: A case report and a review of the literature.
5630 *Medical mycology case reports* 2012; **1**(1): 95-8.

5631 1394. Suzuki Y, Ohto H, Togano T, Kume H. [Epidemiology of Visceral Mycoses in Autopsy Cases in
5632 2011]. *Med Mycol J* 2015; **56**(3): J99-J103.

5633 1395. Suzuki Y, Togano T, Ohto H, Kume H. Visceral Mycoses in Autopsied Cases in Japan from 1989 to
5634 2013. *Med Mycol J* 2018; **59**(4): E53-E62.

5635 1396. Tabbara KF, Wedin K, Al Haddab S. *Chaetomium retinitis*. *Retin Cases Brief Rep* 2010; **4**(1): 8-10.

5636 1397. Tabibian D, Richoz O, Riat A, Schrenzel J, Hafezi F. Accelerated photoactivated chromophore for
5637 keratitis-corneal collagen cross-linking as a first-line and sole treatment in early fungal keratitis. *J Refract*
5638 *Surg* 2014; **30**(12): 855-7.

5639 1398. Taechajongjintana M, Kasetsuwan N, Reinprayoon U, Sawanwattanakul S, Pisuchpen P.
5640 Effectiveness of voriconazole and corneal cross-linking on *Phialophora verrucosa* keratitis: a case report.
5641 *J Med Case Rep* 2018; **12**(1): 225.

5642 1399. Taj-Aldeen SJ, Almaslamani M, Alkhalaf A, et al. Cerebral phaeohyphomycosis due to
5643 *Rhinocladiella mackenziei* (formerly *Ramichloridium mackenziei*): a taxonomic update and review of the
5644 literature. *Medical mycology* 2010; **48**(3): 546-56.

5645 1400. Tambasco D, D'Ettoire M, Bracaglia R, et al. A suspected squamous cell carcinoma in a renal
5646 transplant recipient revealing a rare cutaneous phaeohyphomycosis by *Alternaria infectoria*. *J Cutan*
5647 *Med Surg* 2012; **16**(2): 131-4.

5648 1401. Tan Y, Song M, Peng H, et al. [A case of pulmonary alternariosis complicated with aspergillosis].
5649 *Zhong Nan Da Xue Xue Bao Yi Xue Ban* 2017; **42**(9): 1122-8.

5650 1402. Tanuskova D, Horakova J, Buzassyova D, et al. A case of *Exophiala dermatitidis* infection in a
5651 child after allogeneic stem cell transplantation: case report and literature review of paediatric cases.
5652 *JMM Case Rep* 2017; **4**(6): e005102.

5653 1403. Teixeira MMR, Assuncao CB, Lyon S, et al. A Case of Subcutaneous Phaeohyphomycosis
5654 Associated with Leprosy. *Infect Disord Drug Targets* 2017; **17**(3): 223-6.

5655 1404. Terada M, Ohki E, Yamagishi Y, et al. Fungal peritonitis associated with *Curvularia geniculata* and
5656 *Pithomyces* species in a patient with vulvar cancer who was successfully treated with oral voriconazole. *J*
5657 *Antibiot (Tokyo)* 2014; **67**(2): 191-3.

5658 1405. Teran CG, Downes K, Medows M. Fatal *Bipolaris spicifera* infection in an immunosuppressed
5659 child. *BMJ Case Rep* 2014; **2014**.

5660 1406. Thomas L, Carmichael AJ, Earl U, Darne S. Unusual ulcer in an immunocompromised host. *Clin*
5661 *Exp Dermatol* 2016; **41**(7): 825-7.

5662 1407. To KK, Lau SK, Wu AK, et al. Phaeoacremonium parasiticum invasive infections and airway
5663 colonization characterized by agar block smear and ITS and beta-tubulin gene sequencing. *Diagn*
5664 *Microbiol Infect Dis* 2012; **74**(2): 190-7.

5665 1408. Tokuhisa Y, Hagiya Y, Hiruma M, Nishimura K. Phaeohyphomycosis of the face caused by
5666 *Exophiala oligosperma*. *Mycoses* 2011; **54**(4): e240-3.

5667 1409. Tong Z, Chen SC, Chen L, et al. Generalized subcutaneous phaeohyphomycosis caused by
5668 *Phialophora verrucosa*: report of a case and review of literature. *Mycopathologia* 2013; **175**(3-4): 301-6.

5669 1410. Truffaut S, Bigaillon C, Leroy P, et al. Phaeohyphomycotic tenosynovitis after local steroid
5670 injection during methotrexate therapy for rheumatoid arthritis: A case-report. *Joint Bone Spine* 2017;
5671 **84**(6): 743-4.

5672 1411. Tsai SH, Lin YC, Hsu HC, Chen YM. Subconjunctival Injection of Fluconazole in the Treatment of
5673 Fungal *Alternaria* Keratitis. *Ocul Immunol Inflamm* 2016; **24**(1): 103-6.

5674 1412. Tsai WC, Lee CH, Wu WM, et al. Cutaneous manifestations of subcutaneous and systemic fungal
5675 infections in tropical regions: a retrospective study from a referral center in southern Taiwan. *Int J*
5676 *Dermatol* 2017; **56**(6): 623-9.

5677 1413. Tsang CC, Chan JF, Ip PP, et al. Subcutaneous phaeohyphomycotic nodule due to
5678 *Phialemoniopsis hongkongensis* sp. nov. *J Clin Microbiol* 2014; **52**(9): 3280-9.

5679 1414. Tsang CC, Chan JF, Trendell-Smith NJ, et al. Subcutaneous phaeohyphomycosis in a patient with
5680 IgG4-related sclerosing disease caused by a novel ascomycete, *Hongkongmyces pedis* gen. et sp. nov.:
5681 first report of human infection associated with the family Lindgomycetaceae. *Medical mycology* 2014;
5682 **52**(7): 736-47.

5683 1415. Tsujioka K, Tanaka R, Anzawa K, Ogura H. [A Case of Cutaneous Phaeohyphomycosis Caused by
5684 *Exophiala lecanii-corni* Showing a Seasonal Fluctuation of Skin Lesions]. *Med Mycol J* 2015; **56**(4): J117-
5685 21.

5686 1416. Tural-Kara T, Ozdemir H, Ince E, Ileri T, Ciftci E. *Fonsecaea pedrosoi*: A rare cause of dental
5687 infection and maxillary osteomyelitis in a child with acute lymphoblastic leukemia. *Turk J Pediatr* 2016;
5688 **58**(6): 679-82.

5689 1417. Umemoto N, Demitsu T, Kakurai M, et al. Two cases of cutaneous phaeohyphomycosis due to
5690 *Exophiala jeanselmei*: diagnostic significance of direct microscopical examination of the purulent
5691 discharge. *Clin Exp Dermatol* 2009; **34**(7): e351-3.

5692 1418. Unal A, Sipahioglu MH, Atalay MA, et al. Tenckhoff catheter obstruction without peritonitis
5693 caused by *Curvularia* species. *Mycoses* 2011; **54**(4): 363-4.

5694 1419. Urano S, Suzuki Y, Anzawa K, et al. [Phaeomycotic cyst caused by *Exophiala xenobiotica* in a
5695 patient with rheumatoid arthritis and lung cancer]. *Med Mycol J* 2014; **55**(4): J151-6.

5696 1420. Ursea R, Tavares LA, Feng MT, McColgin AZ, Snyder RW, Wolk DM. Non-traumatic *Alternaria*
5697 keratomycosis in a rigid gas-permeable contact lens patient. *Br J Ophthalmol* 2010; **94**(3): 389-90.

5698 1421. Usui T, Misawa Y, Honda N, Tomidokoro A, Yamagami S, Amano S. Nontraumatic keratomycosis
5699 caused by *Alternaria* in a glaucoma patient. *Int Ophthalmol* 2009; **29**(6): 529-31.

5700 1422. Vallabhaneni S, Purfield AE, Benedict K, et al. Cardiothoracic surgical site phaeohyphomycosis
5701 caused by *Bipolaris* mould, multiple US states, 2008-2013: a clinical description. *Medical mycology* 2016;
5702 **54**(3): 318-21.

5703 1423. Vaquerizo V, Ares O, Seijas R, Garcia F. [Hand phaeohyphomycosis in a kidney transplant
5704 patient]. *Enferm Infecc Microbiol Clin* 2010; **28**(9): 659-60.

5705 1424. Varughese S, David VG, Mathews MS, Tamilarasi V. A patient with amphotericin-resistant
5706 *Curvularia lunata* peritonitis. *Perit Dial Int* 2011; **31**(1): 108-9.

5707 1425. Vasikasin V, Nasomsong W, Srisuttiyakorn C, Mitthamsiri W, Oer-Areemitr N, Changpradub D.
5708 Disseminated Phaeohyphomycosis Caused by *Curvularia tuberculata* in a Previously Healthy Man.
5709 *Mycopathologia* 2019; **184**(2): 321-5.

5710 1426. Vasoo S, Yong LK, Sultania-Dudani P, et al. Phaeomycotic cysts caused by *Phoma* species. *Diagn*
5711 *Microbiol Infect Dis* 2011; **70**(4): 531-3.

5712 1427. Vasquez AM, Lake J, Ngai S, et al. Notes from the Field: Fungal Bloodstream Infections
5713 Associated with a Compounded Intravenous Medication at an Outpatient Oncology Clinic - New York
5714 City, 2016. *MMWR Morb Mortal Wkly Rep* 2016; **65**(45): 1274-5.

5715 1428. Vasquez-del-Mercado E, Lammoglia L, Arenas R. Subcutaneous phaeohyphomycosis due to
5716 *Curvularia lunata* in a renal transplant patient. *Rev Iberoam Micol* 2013; **30**(2): 116-8.

5717 1429. Venkateshwar S, Ambroise MM, Asir GJ, et al. A rare case report of subcutaneous
5718 phaeohyphomycotic cyst caused by *Exophiala oligosperma* in an immunocompetent host with literature
5719 review. *Mycopathologia* 2014; **178**(1-2): 117-21.

5720 1430. Verkley GJ, Gene J, Guarro J, et al. *Pyrenochaeta keratinophila* sp. nov., isolated from an ocular
5721 infection in Spain. *Rev Iberoam Micol* 2010; **27**(1): 22-4.

5722 1431. Verma R, Roy P, Vasudevan B, Bhatt P, Kharayat V, Kaur G. Subcutaneous phaeohyphomycosis
5723 caused by *Bipolaris hawaiiensis* in an immunocompetent patient. *Indian J Dermatol Venereol Leprol*
5724 2014; **80**(6): 554-6.

5725 1432. Vermeire SE, de Jonge H, Lagrou K, Kuypers DR. Cutaneous phaeohyphomycosis in renal
5726 allograft recipients: report of 2 cases and review of the literature. *Diagn Microbiol Infect Dis* 2010; **68**(2):
5727 177-80.

5728 1433. Vicente A, Pedrosa Domellof F, Bystrom B. *Exophiala phaeomuriformis* keratitis in a subarctic
5729 climate region: a case report. *Acta Ophthalmol* 2018; **96**(4): 425-8.

5730 1434. Vila A, Jahan C, Rivero C, Amadio C, Ampuero A, Pagella H. Central line associated blood stream
5731 infection (CLABSI) due to *Exophiala dermatitidis* in an adult patient: Case report and review. *Medical*
5732 *mycology case reports* 2019; **24**: 33-6.

5733 1435. Vinod Mootha V, Shahinpoor P, Sutton DA, Xin L, Najafzadeh MJ, de Hoog GS. Identification
5734 problems with sterile fungi, illustrated by a keratitis due to a non-sporulating *Chaetomium*-like species.
5735 *Medical mycology* 2012; **50**(4): 361-7.

5736 1436. Wang C, Xing H, Jiang X, et al. Cerebral Phaeohyphomycosis Caused by *Exophiala dermatitidis* in
5737 a Chinese CARD9-Deficient Patient: A Case Report and Literature Review. *Front Neurol* 2019; **10**: 938.

5738 1437. Wang CH, Chen WT, Ting SW, Sun PL. Subcutaneous Fungal Infection Caused by a Non-
5739 sporulating Strain of *Corynespora cassiicola* Successfully Treated with Terbinafine. *Mycopathologia*
5740 2019; **184**(5): 691-7.

5741 1438. Wang L, Al-Hatmi AM, Lai X, et al. *Bipolaris oryzae*, a novel fungal opportunist causing keratitis.
5742 *Diagn Microbiol Infect Dis* 2016; **85**(1): 61-5.

5743 1439. Wang L, She X, Lv G, et al. Cutaneous and mucosal phaeohyphomycosis caused by *Exophiala*
5744 *spinifera* in a pregnant patient: case report and literature review. *Mycopathologia* 2013; **175**(3-4): 331-
5745 8.

5746 1440. Wang L, Sun S, Jing Y, Han L, Zhang H, Yue J. Spectrum of fungal keratitis in central China. *Clin*
5747 *Exp Ophthalmol* 2009; **37**(8): 763-71.

5748 1441. Wang L, Wang C, Shen Y, et al. Phaeohyphomycosis caused by *Exophiala spinifera*: an increasing
5749 disease in young females in mainland China? Two case reports and review of five cases reported from
5750 mainland China. *Mycoses* 2015; **58**(3): 193-6.

5751 1442. Wang LY, Xu ZZ, Zhang JJ, et al. [Topical voriconazole as an effective treatment for fungal
5752 keratitis]. *Zhonghua Yan Ke Za Zhi* 2016; **52**(9): 657-62.

5753 1443. Wang SC, Lo HJ, Lin LJ, Chen CH. Port catheter-associated *Aureobasidium melanigenum*
5754 fungemia. *J Formos Med Assoc* 2018; **117**(4): 346-7.

5755 1444. Wang XX, Yu J. Severe progressive cutaneous infection caused by *Fonsecaea monophora* in a
5756 patient after trauma. *Infection* 2019; **47**(4): 681-2.

5757 1445. Waqas M, Waheed S, Mangrio SA, Rashid S, Qadeer M, Bari E. Confusing presentation of
5758 *Chaetomium* brain abscess. *Br J Neurosurg* 2014; **28**(6): 805-7.

5759 1446. Watanabe N, Gotoh A, Shirane S, et al. Breakthrough *Exophiala dermatitidis* infection during
5760 prophylactic administration of micafungin during second umbilical cord blood transplantation after graft
5761 failure. *Transpl Infect Dis* 2018; **20**(2): e12833.

5762 1447. Watanabe Y, Kobayashi T, Nakamura I, et al. A Case of Conjunctival Ulcer and Uveitis Caused by
5763 *Acrophialophora* Sp. in an Immunocompromised Patient: a Case Report and Riterature Review. *Jpn J*
5764 *Infect Dis* 2018; **71**(6): 467-9.

5765 1448. Wehrle-Wieland E, Affolter K, Goldenberger D, et al. Diagnosis of invasive mold diseases in
5766 patients with hematological malignancies using *Aspergillus*, *Mucorales*, and panfungal PCR in BAL.
5767 *Transpl Infect Dis* 2018; **20**(5): e12953.

5768 1449. Welfringer A, Vuong V, Argy N, et al. A rare fungal infection: Phaeohyphomycosis due to
5769 *Veronaea botryosa* and review of literature. *Medical mycology case reports* 2017; **15**: 21-4.

5770 1450. Werbel WA, Baroncelli R, Shoham S, Zhang SX. Angioinvasive, cutaneous infection due to
5771 *Colletotrichum siamense* in a stem cell transplant recipient: Report and review of prior cases. *Transpl*
5772 *Infect Dis* 2019; **21**(5): e13153.

5773 1451. Wong JS, Schousboe MI, Metcalf SS, et al. *Ochroconis gallopava* peritonitis in a cardiac
5774 transplant patient on continuous ambulatory peritoneal dialysis. *Transpl Infect Dis* 2010; **12**(5): 455-8.

5775 1452. Woo PC, Ngan AH, Tsang CC, et al. Clinical spectrum of *Exophiala* infections and a novel
5776 *Exophiala* species, *Exophiala hongkongensis*. *J Clin Microbiol* 2013; **51**(1): 260-7.

5777 1453. Wu JS, Chen SN, Hwang JF, Lin CJ. Endogenous mycotic endophthalmitis in an
5778 immunocompetent postpartum patient. *Retin Cases Brief Rep* 2011; **5**(1): 10-3.

5779 1454. Xie Z, Wu W, Meng D, et al. A case of Phaeohyphomycosis caused by *Corynespora cassiicola*
5780 infection. *BMC Infect Dis* 2018; **18**(1): 444.

5781 1455. Xu Y, Zhao D, Gao C, Zhou L, Pang G, Sun S. In vitro activity of phenylmercuric acetate against
5782 ocular pathogenic fungi. *J Antimicrob Chemother* 2012; **67**(8): 1941-4.

5783 1456. Yadav S, Agarwal R, Singh S, Goel S. Pyrenochaeta romeroi causing subcutaneous
5784 phaeohyphomycotic cyst in a diabetic female. *Medical mycology case reports* 2015; **8**: 47-9.

5785 1457. Yamada H, Takahashi N, Hori N, et al. Rare case of fungal keratitis caused by *Corynespora*
5786 *cassiicola*. *J Infect Chemother* 2013; **19**(6): 1167-9.

5787 1458. Yang H, Cai Q, Gao Z, et al. Subcutaneous Phaeohyphomycosis Caused by *Exophiala oligosperma*
5788 in an Immunocompetent Host: Case Report and Literature Review. *Mycopathologia* 2018; **183**(5): 815-
5789 20.

5790 1459. Yang SJ, Ng CY, Wu TS, Huang PY, Wu YM, Sun PL. Deep Cutaneous *Neoscytalidium dimidiatum*
5791 Infection: Successful Outcome with Amphotericin B Therapy. *Mycopathologia* 2019; **184**(1): 169-76.

5792 1460. Yasri S, Wiwanitkit V. *Cladophialophora bantiana* brain abscess in lung transplant recipient.
5793 *Transpl Infect Dis* 2019; **21**(2): e13057.

5794 1461. Yasui M, Hattori M, Ikegami N, Kaga M, Ogawa Y, Hiruma M. A case of alternariosis successfully
5795 treated with local hyperthermia. *Mycoses* 2011; **54**(5): e623-6.

5796 1462. Yoon YA, Park KS, Lee JH, Sung KS, Ki CS, Lee NY. Subcutaneous phaeohyphomycosis caused by
5797 *Exophiala salmonis*. *Ann Lab Med* 2012; **32**(6): 438-41.

5798 1463. Yoshida T, Tachita T, Fujinami H, et al. *Exophiala dermatitidis* Fungemia Diagnosed Using Time-
5799 of-flight Mass Spectrometry during Chemotherapy for Malignant Lymphoma and Successful Treatment
5800 with Voriconazole. *Intern Med* 2019; **58**(15): 2219-24.

5801 1464. Zhang H, Ran Y, Li D, et al. *Clavispora lusitaniae* and *Chaetomium atrobrunneum* as rare agents
5802 of cutaneous infection. *Mycopathologia* 2010; **169**(5): 373-80.

5803 1465. Zhao Y, Armeanu E, DiVerniero R, et al. Fungal DNA detected in blood samples of patients who
5804 received contaminated methylprednisolone injections reveals increased complexity of causative agents.
5805 *J Clin Microbiol* 2014; **52**(6): 2212-5.

5806 1466. Zhou X, Hu Y, Hu Y, et al. [Cutaneous and subcutaneous phaeohyphomycosis caused by
5807 *Exophiala jeanselmei* after renal transplantation: a case report]. *Nan Fang Yi Ke Da Xue Xue Bao* 2012;
5808 **32**(8): 1206-10.

5809 1467. Zhou YB, Chen P, Sun TT, Wang XJ, Li DM. Acne-Like Subcutaneous Phaeohyphomycosis Caused
5810 by *Cladosporium cladosporioides*: A Rare Case Report and Review of Published Literatures.
5811 *Mycopathologia* 2016; **181**(7-8): 567-73.

5812 1468. Pesic Z, Otasevic S, Mihailovic D, et al. *Alternaria*-Associated Fungus Ball of Orbit Nose and
5813 Paranasal Sinuses: Case Report of a Rare Clinical Entity. *Mycopathologia* 2015; **180**(1-2): 99-103.

5814 1469. Cristini A, Garcia-Hermoso D, Celard M, Albrand G, Lortholary O. Cerebral phaeohyphomycosis
5815 caused by *Rhinocladiella mackenziei* in a woman native to Afghanistan. *J Clin Microbiol* 2010; **48**(9):
5816 3451-4.

5817 1470. Garzoni C, Markham L, Bijlenga P, Garbino J. *Cladophialophora bantiana*: a rare cause of fungal
5818 brain abscess. Clinical aspects and new therapeutic options. *Medical mycology* 2008; **46**(5): 481-6.

5819 1471. Fraser M, Borman AM, Johnson EM. Rapid and Robust Identification of the Agents of Black-Grain
5820 Mycetoma by Matrix-Assisted Laser Desorption Ionization-Time of Flight Mass Spectrometry. *J Clin*
5821 *Microbiol* 2017; **55**(8): 2521-8.

5822 1472. Kondori N, Erhard M, Welinder-Olsson C, Groenewald M, Verkley G, Moore ER. Analyses of black
5823 fungi by matrix-assisted laser desorption/ionization time-of-flight mass spectrometry (MALDI-TOF MS):
5824 species-level identification of clinical isolates of *Exophiala dermatitidis*. *FEMS Microbiol Lett* 2015;
5825 **362**(1): 1-6.

5826 1473. Ozhak-Baysan B, Ogunc D, Dogen A, Ilkit M, de Hoog GS. MALDI-TOF MS-based identification of
5827 black yeasts of the genus *Exophiala*. *Medical mycology* 2015; **53**(4): 347-52.

5828 1474. Singh A, Singh PK, Kumar A, et al. Molecular and Matrix-Assisted Laser Desorption Ionization-
5829 Time of Flight Mass Spectrometry-Based Characterization of Clinically Significant Melanized Fungi in
5830 India. *J Clin Microbiol* 2017; **55**(4): 1090-103.

5831 1475. Rimawi BH, Rimawi RH, Mirdamadi M, et al. A case of *Exophiala oligosperma* successfully
5832 treated with voriconazole. *Med Mycol Case Rep* 2013; **2**: 144-7.

5833 1476. Schieffelin JS, Garcia-Diaz JB, Loss GE, Jr., et al. Phaeohyphomycosis fungal infections in solid
5834 organ transplant recipients: clinical presentation, pathology, and treatment. *Transpl Infect Dis* 2014;
5835 **16**(2): 270-8.

5836 1477. McCarty TP, Baddley JW, Walsh TJ, et al. Phaeohyphomycosis in transplant recipients: Results
5837 from the Transplant Associated Infection Surveillance Network (TRANSNET). *Medical mycology* 2015;
5838 **53**(5): 440-6.

5839 1478. Howlett S, Sullivan T, Abdolrasouli A, et al. A black mould death: A case of fatal cerebral
5840 phaeohyphomycosis caused by *Cladophialophora bantiana*. *Medical mycology case reports* 2019; **24**: 23-
5841 6.

5842 1479. Shi CR, Robinson SN, LaChance A, Mihm MC, Jr., Kroshinsky D. A 53-Year-Old Male with Relapsed
5843 Diffuse Large B-Cell Lymphoma on Chemotherapy with a New Leg Lesion. *Dermatopathology (Basel)*
5844 2017; **4**(1-4): 31-5.

5845 1480. Revankar SG. Phaeohyphomycosis in Transplant Patients. *Journal of fungi (Basel, Switzerland)*
5846 2015; **2**(1): 2.

5847 1481. Chowdhary A, Randhawa HS, Singh V, et al. *Bipolaris hawaiiensis* as etiologic agent of allergic
5848 bronchopulmonary mycosis: first case in a paediatric patient. *Medical mycology* 2011; **49**(7): 760-5.

5849 1482. El-Morsy SM, Khafagy YW, El-Naggar MM, Beih AA. Allergic fungal rhinosinusitis: detection of
5850 fungal DNA in sinus aspirate using polymerase chain reaction. *J Laryngol Otol* 2010; **124**(2): 152-60.

5851 1483. Gade L, Grgurich DE, Kerkering TM, Brandt ME, Litvintseva AP. Utility of real-time PCR for
5852 detection of *Exserohilum rostratum* in body and tissue fluids during the multistate outbreak of fungal
5853 meningitis and other infections. *J Clin Microbiol* 2015; **53**(2): 618-25.

5854 1484. Montone KT. Pathology of Fungal Rhinosinusitis: A Review. *Head Neck Pathol* 2016; **10**(1): 40-6.

5855 1485. Katragkou A, Pana ZD, Perlin DS, Kontoyiannis DP, Walsh TJ, Roilides E. *Exserohilum* infections:
5856 review of 48 cases before the 2012 United States outbreak. *Medical mycology* 2014; **52**(4): 376-86.

5857 1486. Ben-Ami R, Lewis RE, Raad, II, Kontoyiannis DP. Phaeohyphomycosis in a tertiary care cancer
5858 center. *Clinical infectious diseases : an official publication of the Infectious Diseases Society of America*
5859 2009; **48**(8): 1033-41.

5860 1487. Vasquez A, Zavasky D, Chow NA, et al. Management of an Outbreak of *Exophiala dermatitidis*
5861 Bloodstream Infections at an Outpatient Oncology Clinic. *Clinical infectious diseases : an official*
5862 *publication of the Infectious Diseases Society of America* 2018; **66**(6): 959-62.

5863 1488. Santos DW, Camargo LF, Goncalves SS, et al. Melanized fungal infections in kidney transplant
5864 recipients: contributions to optimize clinical management. *Clin Microbiol Infect* 2017; **23**(5): 333.e9-.e14.

5865 1489. Ogawa MM, Peternelli MP, Enokihara MM, Nishikaku AS, Goncalves SS, Tomimori J. Spectral
5866 Manifestation of Melanized Fungal Infections in Kidney Transplant Recipients: Report of Six Cases.
5867 *Mycopathologia* 2016; **181**(5-6): 379-85.

5868 1490. Thomas E, Bertolotti A, Barreau A, et al. From phaeohyphomycosis to disseminated
5869 chromoblastomycosis: A retrospective study of infections caused by dematiaceous fungi. *Med Mal Infect*
5870 2018; **48**(4): 278-85.

5871 1491. Crabol Y, Poiree S, Bougnoux ME, et al. Last generation triazoles for imported eumycetoma in
5872 eleven consecutive adults. *PLoS Negl Trop Dis* 2014; **8**(10): e3232.

5873 1492. Mouchalouat Mde F, Gutierrez Galhardo MC, Zancope-Oliveira RM, et al. Chromoblastomycosis:
5874 a clinical and molecular study of 18 cases in Rio de Janeiro, Brazil. *Int J Dermatol* 2011; **50**(8): 981-6.

5875 1493. Hofling-Lima AL, Freitas D, Fischman O, Yu CZ, Roizenblatt R, Belfort R, Jr. *Exophiala jeanselmei*
5876 causing late endophthalmitis after cataract surgery. *Am J Ophthalmol* 1999; **128**(4): 512-4.

5877 1494. Zayit-Soudry S, Neudorfer M, Barak A, Loewenstein A, Bash E, Siegman-Igra Y. Endogenous
5878 *Phialemonium curvatum* endophthalmitis. *Am J Ophthalmol* 2005; **140**(4): 755-7.

5879 1495. Chakrabarti A, Shivaprakash MR, Singh R, et al. Fungal endophthalmitis: fourteen years'
5880 experience from a center in India. *Retina (Philadelphia, Pa)* 2008; **28**(10): 1400-7.

5881 1496. Margo CE, Fitzgerald CR. Postoperative endophthalmitis caused by *Wangiella dermatitidis*. *Am J*
5882 *Ophthalmol* 1990; **110**(3): 322-3.

5883 1497. Pavan PR, Margo CE. Endogenous endophthalmitis caused by *Bipolaris hawaiiensis* in a patient
5884 with acquired immunodeficiency syndrome. *Am J Ophthalmol* 1993; **116**(5): 644-5.

5885 1498. Kaushik S, Ram J, Chakrabarty A, Dogra MR, Brar GS, Gupta A. *Curvularia lunata* endophthalmitis
5886 with secondary keratitis. *Am J Ophthalmol* 2001; **131**(1): 140-2.

5887 1499. Rao NA, Hidayat AA. Endogenous mycotic endophthalmitis: variations in clinical and
5888 histopathologic changes in candidiasis compared with aspergillosis. *American Journal of Ophthalmology*
5889 2001; **132**(2): 244-51.

5890 1500. Bagga R, Chattu VK. *Triadelphia pulvinata*: A rare invasive fungal infection in a diabetic patient.
5891 *Medical mycology case reports* 2018; **22**: 8-10.

5892 1501. Hagiya H, Maeda T, Kusakabe S, et al. A fatal case of *Exophiala dermatitidis* disseminated
5893 infection in an allogeneic hematopoietic stem cell transplant recipient during micafungin therapy. *J Infect*
5894 *Chemother* 2019; **25**(6): 463-6.

5895 1502. Edathodu J, Al-Abdely HM, Althawadi S, et al. Invasive fungal infection due to *Triadelphia*
5896 *pulvinata* in a patient with acute myeloid leukemia. *J Clin Microbiol* 2013; **51**(10): 3426-9.

5897 1503. Qiu Y, Zhang J, Tang Y, Zhong X, Deng J. Case report: Fever- pneumonia- lymphadenectasis-
5898 osteolytic- subcutaneous nodule: Disseminated chromoblastomycosis caused by *phialophora*. *J Infect*
5899 *Chemother* 2019; **25**(12): 1031-6.

5900 1504. Pundhir P, Tuda C, Vincentelli C, Morlote D, Rivera C. *Scolecobasidium granulomatous*
5901 pneumonia and abscess - an emerging opportunistic fungal pathogen: a case report. *Int J STD AIDS* 2017;
5902 **28**(1): 94-6.

5903 1505. Doymaz MZ, Seyithanoglu MF, Hakyemez I, Gultepe BS, Cevik S, Aslan T. A case of cerebral
5904 phaeohyphomycosis caused by *Fonsecaea monophora*, a neurotropic dematiaceous fungus, and a
5905 review of the literature. *Mycoses* 2015; **58**(3): 187-92.

5906 1506. Sládeková M, Póczová M, Gašpar M, et al. First case of systemic phaeohyphomycosis due to
5907 *Cladophialophora bantiana* in Slovakia. *JMM Case Rep* 2014; **1**(4): e002659-e.

5908 1507. Dalla Gasperina D, Lombardi D, Rovelli C, et al. Successful treatment with isavuconazole of
5909 subcutaneous phaeohyphomycosis in a kidney transplant recipient. *Transplant infectious disease : an*
5910 *official journal of the Transplantation Society* 2019; **21**(6): e13197-e.

5911 1508. Los-Arcos I, Royuela M, Martín-Gómez MT, et al. Phaeohyphomycosis caused by *Medicopsis*
5912 *romeroi* in solid organ transplant recipients: Report of two cases and comprehensive review of the
5913 literature. *Transplant infectious disease : an official journal of the Transplantation Society* 2019; **21**(3):
5914 e13072-e.

5915 1509. Crawford SJ, Chen SCA, Halliday C, Rangan GK, Gottlieb T, Reid AB. *Microsphaeropsis arundinis*
5916 skin and soft tissue infection in renal transplant recipients: three case reports and a review of the
5917 literature. *Transplant infectious disease : an official journal of the Transplantation Society* 2015; **17**(6):
5918 915-20.

5919 1510. Chan YYC, Tan AL, Tan BH. Subcutaneous abscess due to *Pyrenochaeta romeroi* in a renal
5920 transplant recipient. *Singapore medical journal* 2014; **55**(4): e64-e6.

5921 1511. Bohelay G, Robert S, Bouges-Michel C, et al. Subcutaneous phaeohyphomycosis caused by
5922 *Exophiala spinifera* in a European patient with lymphoma: a rare occurrence case report and literature
5923 review. *Mycoses* 2016; **59**(11): 691-6.

5924 1512. Sharma S, Capoor MR, Singh M, Kiran D, Mandal AK. Subcutaneous Phaeohyphomycosis Caused
5925 by *Pyrenochaeta romeroi* in a Rheumatoid Arthritis Patient: A Case Report with Review of the Literature.
5926 *Mycopathologia* 2016; **181**(9-10): 735-43.

5927 1513. Khader A, Ambooken B, Binitha MP, Francis S, Kuttiyil AK, Sureshan DN. Disseminated cutaneous
5928 phaeohyphomycosis due to *Cladophialophora bantiana*. *Indian J Dermatol Venereol Leprol* 2015; **81**(5):
5929 491-4.

5930 1514. Furudate S, Sasai S, Numata Y, Fujimura T, Aiba S. Phaeohyphomycosis Caused by
5931 *Phaeoacremonium rubrigenum* in an Immunosuppressive Patient: A Case Report and Review of the
5932 Literature. *Case Rep Dermatol* 2012; **4**(2): 119-24.

5933 1515. Chander J, Singla N, Kundu R, Handa U, Chowdhary A. Phaeohyphomycosis Caused by
5934 *Rhytidhysterion rufulum* and Review of Literature. *Mycopathologia* 2017; **182**(3-4): 403-7.

5935 1516. Chhonkar A, Kataria D, Tambe S, Nayak CS. Three rare cases of cutaneous phaeohyphomycosis.
5936 *Indian J Plast Surg* 2016; **49**(2): 271-4.

5937 1517. Mittal A, Agarwal N, Gupta LK, Khare AK. Chromoblastomycosis from a Non-endemic Area and
5938 Response to Itraconazole. *Indian J Dermatol* 2014; **59**(6): 606-8.

5939 1518. Parente JNT, Talhari C, Ginter-Hanselmayer G, et al. Subcutaneous phaeohyphomycosis in
5940 immunocompetent patients: two new cases caused by *Exophiala jeanselmei* and *Cladophialophora*
5941 *carrionii*. *Mycoses* 2011; **54**(3): 265-9.

5942 1519. Sang H, Zheng XE, Kong QT, et al. A rare complication of ear piercing: a case of subcutaneous
5943 phaeohyphomycosis caused by *Veronea botryosa* in China. *Medical mycology* 2011; **49**(3): 296-302.

5944 1520. Pereira RR, Nayak CS, Deshpande SD, Bhatt KD, Khatu SS, Dhurat RS. Subcutaneous
5945 phaeohyphomycosis caused by *Cladophialophora boppii*. *Indian J Dermatol Venereol Leprol* 2010; **76**(6):
5946 695-8.

5947 1521. Gunathilake R, Perera P, Sirimanna G. *Curvularia lunata*: a rare cause of black-grain
5948 eumycetoma. *Journal de mycologie medicale* 2014; **24**(2): 158-60.

5949 1522. Machmachi H, Godineau N, Develoux M, et al. Black grain mycetoma caused by *Leptosphaeria*
5950 *tompkinsii*. *Medical mycology* 2011; **49**(2): 186-9.

5951 1523. Nolêto RP, Santos IS, Amaro TG, Diebold D, Vettorato G, Daboit TC. *Phoma* (*Peyronellaea*) spp.:
5952 a phytopathogen as a cause of cystic phaeohyphomycosis in a diabetic patient. *Clinical microbiology and*
5953 *infection : the official publication of the European Society of Clinical Microbiology and Infectious Diseases*
5954 2020; **26**(2): 205-6.

5955 1524. Haridasan S, Parameswaran S, Bheemanathi SH, et al. Subcutaneous phaeohyphomycosis in
5956 kidney transplant recipients: A series of seven cases. *Transplant infectious disease : an official journal of*
5957 *the Transplantation Society* 2017; **19**(6): 10.1111/tid.12788.

5958 1525. Michelon M, Greenlaw S, O'Donnell P, Geist D, Levin NA. Multifocal cutaneous alternariosis in a
5959 70-year-old Kenyan renal transplant patient. *Dermatol Online J* 2014; **20**(7): 13030/qt45s7m4mk.

5960 1526. Galipothu S, Kalawat U, Ram R, et al. Cutaneous fungal infection in a renal transplantation
5961 patient due to a rare fungus belonging to order Pleosporales. *Indian journal of medical microbiology*
5962 2015; **33**(1): 165-7.

5963 1527. Balla A, Pierson J, Hugh J, Wojewoda C, Gibson P, Greene L. Disseminated cutaneous *Curvularia*
5964 infection in an immunocompromised host; diagnostic challenges and experience with voriconazole.
5965 *Journal of cutaneous pathology* 2016; **43**(4): 383-7.

5966 1528. Brokalaki EI, Sommerwerck U, von Heinegg EH, Hillen U. *Ochroconis gallopavum* infection in a
5967 lung transplant recipient: report of a case. *Transplantation proceedings* 2012; **44**(9): 2778-80.

5968 1529. Lief MH, Caplivski D, Bottone EJ, Lerner S, Vidal C, Huprikar S. *Exophiala jeanselmei* infection in
5969 solid organ transplant recipients: report of two cases and review of the literature. *Transplant infectious*
5970 *disease : an official journal of the Transplantation Society* 2011; **13**(1): 73-9.

5971 1530. Desoubeaux G, Millon A, Freychet B, et al. Eumycetoma of the foot caused by *Exophiala*
5972 *jeanselmei* in a Guinean woman. *Journal de mycologie medicale* 2013; **23**(3): 168-75.

5973 1531. Vermeire SEM, de Jonge H, Lagrou K, Kuypers DRJ. Cutaneous phaeohyphomycosis in renal
5974 allograft recipients: report of 2 cases and review of the literature. *Diagnostic microbiology and infectious*
5975 *disease* 2010; **68**(2): 177-80.

5976 1532. Mohammed A, Rahnama-Moghadam S. Following the Track to an Unexpected Diagnosis:
5977 Phaeohyphomycosis. *The American journal of medicine* 2019; **132**(9): 1047-9.

5978 1533. Radhakrishnan D, Jayalakshmi G, Madhumathy A, Banu ST, Geethalakshmi S, Sumathi G.
5979 Subcutaneous phaeohyphomycosis due to *Exophiala spinifera* in an immunocompromised host. *Indian*
5980 *journal of medical microbiology* 2010; **28**(4): 396-9.

5981 1534. Bao F, Wang Q, Yu C, et al. Case Report: Successful Treatment of Chromoblastomycosis Caused
5982 by *Fonsecaea monophora* in a Patient with Psoriasis Using Itraconazole and Acitretin. *Am J Trop Med*
5983 *Hyg* 2018; **99**(1): 124-6.

5984 1535. Label M, Karayan LC, De Hoog S, Afeltra J, Bustamante T, Vitale RG. Differential distribution
5985 patterns of *Fonsecaea* agents of chromoblastomycosis, exemplified by the first case due to *F.*
5986 *monophora* from Argentina. *Medical mycology case reports* 2017; **20**: 35-8.

5987 1536. Gomes NM, Bastos TC, Cruz KS, Francesconi F. Chromoblastomycosis: an exuberant case. *Anais*
5988 *brasileiros de dermatologia* 2014; **89**(2): 351-2.

5989 1537. Antonello VS, Appel da Silva MC, Cambuzzi E, Kliemann DA, Santos BR, Queiroz-Telles F.
5990 Treatment of severe chromoblastomycosis with itraconazole and 5-flucytosine association. *Rev Inst Med*
5991 *Trop Sao Paulo* 2010; **52**(6): 329-31.

5992 1538. Shi D, Zhang W, Lu G, et al. Chromoblastomycosis due to *Fonsecaea monophora* misdiagnosed
5993 as sporotrichosis and cutaneous tuberculosis in a pulmonary tuberculosis patient. *Medical mycology*
5994 *case reports* 2016; **11**: 57-60.

5995 1539. Dupont C, Duong TA, Mallet S, et al. Unusual presentation of chromoblastomycosis due to
5996 *Cladophialophora carrionii* in a renal and pancreas transplant recipient patient successfully treated with
5997 posaconazole and surgical excision. *Transplant infectious disease : an official journal of the*
5998 *Transplantation Society* 2010; **12**(2): 180-3.

5999 1540. Homa M, Manikandan P, Saravanan V, et al. *Exophiala dermatitidis* Endophthalmitis: Case
6000 Report and Literature Review. *Mycopathologia* 2018; **183**(3): 603-9.

6001 1541. Rao AG, Thool BA, Rao CV. Endogenous endophthalmitis due to *alternaria* in an
6002 immunocompetent host. *Retina (Philadelphia, Pa)* 2004; **24**(3): 478-81.

6003 1542. Weinberger M, Mahrshak I, Keller N, et al. Isolated endogenous endophthalmitis due to a
6004 sporodochial-forming *Phialemonium curvatum* acquired through intracavernous autoinjections. *Medical*
6005 *mycology* 2006; **44**(3): 253-9.

6006 1543. Dogra M, Dhingra D, Sharma SP, Bansal R. A rare case of *Lecythophora* endogenous
6007 endophthalmitis: Diagnostic and therapeutic challenge. *Indian J Ophthalmol* 2018; **66**(8): 1203-5.

6008 1544. Meriden Z, Marr KA, Lederman HM, et al. *Ochroconis gallopava* infection in a patient with
6009 chronic granulomatous disease: case report and review of the literature. *Medical mycology* 2012; **50**(8):
6010 883-9.

6011 1545. Sečniková Z, Jůzlová K, Vojáčková N, et al. The rare case of *Alternaria alternata* cutaneous and
6012 pulmonary infection in a heart transplant recipient treated by azole antifungals. *Dermatol Ther* 2014;
6013 **27**(3): 140-3.

6014 1546. Kulkarni M, Jamale T, Hase N, Ubale M, Keskar V, Jagadish PK. Subcutaneous
6015 *Phaeohiphomyces* Caused By *Pyrenochaeta Romeroi* in a Kidney Transplant Recipient: A Case Report.
6016 *Exp Clin Transplant* 2017; **15**(2): 226-7.

6017 1547. Garcia-Reyne A, López-Medrano F, Morales JM, et al. Cutaneous infection by *Phomopsis*
6018 *longicolla* in a renal transplant recipient from Guinea: first report of human infection by this fungus.
6019 *Transplant infectious disease : an official journal of the Transplantation Society* 2011; **13**(2): 204-7.

6020 1548. Mahajan VK, Sharma V, Prabha N, et al. A rare case of subcutaneous *phaeohyphomycosis*
6021 caused by a *Rhytidhysterium* species: a clinico-therapeutic experience. *International journal of*
6022 *dermatology* 2014; **53**(12): 1485-9.

6023 1549. Tawade Y, Gaikwad A, Deodhar A, et al. Uncommon presentation of chromoblastomycosis. *Cutis*
6024 2018; **101**(6): 442-8.

6025 1550. Tan H, Xu Y, Lan X-M, Wu Y-G, Zhou C-J, Yang X-C. Chromoblastomycosis due to *Fonsecaea*
6026 *monophora* in a man with nephritic syndrome. *Mycopathologia* 2015; **179**(5-6): 447-52.

6027 1551. Geltner C, Sorschag S, Willinger B, Jaritz T, Saric Z, Lass-Flörl C. Necrotizing mycosis due to
6028 *Verruconis gallopava* in an immunocompetent patient. *Infection* 2015; **43**(6): 743-6.

6029 1552. Maquiné GÁ, Rodrigues MHG, Schettini APM, Morais PMd, Frota MZM. Subcutaneous
6030 *phaeohyphomycosis* due to *Cladophialophora bantiana*: a first case report in an immunocompetent
6031 patient in Latin America and a brief literature review. *Rev Soc Bras Med Trop* 2019; **52**: e20180480-e.

6032 1553. Criado PR, Careta MF, Valente NYS, et al. Extensive long-standing chromomycosis due to
6033 *Fonsecaea pedrosoi*: three cases with relevant improvement under voriconazole therapy. *J Dermatolog*
6034 *Treat* 2011; **22**(3): 167-74.

6035 1554. Guarro J, Alves SH, Gene J, et al. Two cases of subcutaneous infection due to *Phaeoacremonium*
6036 spp. *J Clin Microbiol* 2003; **41**(3): 1332-6.

6037 1555. Yang Y, Hu Y, Zhang J, et al. A refractory case of chromoblastomycosis due to *Fonsecaea*
6038 *monophora* with improvement by photodynamic therapy. *Medical mycology* 2012; **50**(6): 649-53.

6039 1556. Gugnani HC, Ramesh V, Sood N, et al. Cutaneous *phaeohyphomycosis* caused by *Caldosporium*
6040 *oxysporum* and its treatment with potassium iodide. *Medical mycology* 2006; **44**(3): 285-8.

6041 1557. Torres-Rodriguez JM, Gonzalez MP, Corominas JM, Pujol RM. Successful thermotherapy for a
6042 subcutaneous infection due to *Alternaria alternata* in a renal transplant recipient. *Arch Dermatol* 2005;
6043 **141**(9): 1171-3.

6044 1558. Bonifaz A, Carrasco-Gerard E, Saul A. Chromoblastomycosis: clinical and mycologic experience of
6045 51 cases. *Mycoses* 2001; **44**(1-2): 1-7.

6046 1559. Castro LG, Pimentel ER, Lacaz CS. Treatment of chromomycosis by cryosurgery with liquid
6047 nitrogen: 15 years' experience. *Int J Dermatol* 2003; **42**(5): 408-12.

6048 1560. Kantarcioglu AS, Guarro J, De Hoog S, Apaydin H, Kiraz N. An updated comprehensive systematic
6049 review of *Cladophialophora bantiana* and analysis of epidemiology, clinical characteristics, and outcome
6050 of cerebral cases. *Medical mycology* 2017; **55**(6): 579-604.

6051 1561. Delfino D, De Hoog S, Polonelli L, et al. Survival of a neglected case of brain abscess caused by
6052 *Cladophialophora bantiana*. *Medical mycology* 2006; **44**(7): 651-4.

6053 1562. Halwig JM, Brueske DA, Greenberger PA, Dreisin RB, Sommers HM. Allergic bronchopulmonary
6054 curvulariosis. *Am Rev Respir Dis* 1985; **132**(1): 186-8.

6055 1563. Chowdhary A, Agarwal K, Randhawa HS, et al. A rare case of allergic bronchopulmonary mycosis
6056 caused by *Alternaria alternata*. *Medical mycology* 2012; **50**(8): 890-6.

6057 1564. Walsh TJ, Dixon DM, Polak A, Salkin IF. Comparative histopathology of *Dactylaria constricta*,
6058 *Fonsecaea pedrosoi*, *Wangiella dermatitidis*, and *Xylohypha bantiana* in experimental
6059 phaeohyphomycosis of the central nervous system. *Mykosen* 1987; **30**(5): 215-25.

6060 1565. Rinaldi MG, Phillips P, Schwartz JG, et al. Human *Curvularia* infections. Report of five cases and
6061 review of the literature. *Diagn Microbiol Infect Dis* 1987; **6**(1): 27-39.

6062 1566. Schieffelin JS, Garcia-Diaz JB, Loss GE, Jr., et al. Phaeohyphomycosis fungal infections in solid
6063 organ transplant recipients: clinical presentation, pathology, and treatment. *Transplant infectious
6064 disease : an official journal of the Transplantation Society* 2014; **16**(2): 270-8.

6065 1567. Nandedkar S, Bajpai T, Bhatambare GS, Sakhi P. Cerebral phaeohyphomycosis: A rare case from
6066 central India. *Asian journal of neurosurgery* 2015; **10**(2): 142-4.

6067 1568. Gan EC, Habib A-RR, Rajwani A, Javer AR. Omalizumab therapy for refractory allergic fungal
6068 rhinosinusitis patients with moderate or severe asthma. *Am J Otolaryngol* 2015; **36**(5): 672-7.

6069 1569. Chowdhary A, Randhawa HS, Singh V, et al. *Bipolaris hawaiiensis* as etiologic agent of allergic
6070 bronchopulmonary mycosis: first case in a paediatric patient. *Medical mycology* 2011; **49**(7): 760-5.

6071 1570. Chang X, Li R, Yu J, Bao X, Qin J. Phaeohyphomycosis of the central nervous system caused by
6072 *Exophiala dermatitidis* in a 3-year-old immunocompetent host. *J Child Neurol* 2009; **24**(3): 342-5.

6073 1571. Alabaz D, Kibar F, Arikan S, et al. Systemic phaeohyphomycosis due to *Exophiala* (*Wangiella*) in
6074 an immunocompetent child. *Medical mycology* 2009; **47**(6): 653-7.

6075 1572. Bay C, González T, Munoz G, Legarraga P, Vizcaya C, Abarca K. Nasal phaeohyphomycosis by
6076 *Curvularia spicifera* in pediatric patient with neutropenia and acute myeloid leukemia. *Rev Chilena
6077 Infectol* 2017; **34**(3): 280-6.

6078 1573. Saint-Jean M, St-Germain G, Laferrière C, Tapiero B. Hospital-acquired phaeohyphomycosis due
6079 to *Exserohilum rostratum* in a child with leukemia. *Can J Infect Dis Med Microbiol* 2007; **18**(3): 200-2.

6080 1574. Tanuskova D, Horakova J, Buzassyova D, et al. A case of *Exophiala dermatitidis* infection in a
6081 child after allogeneic stem cell transplantation: case report and literature review of paediatric cases.
6082 *JMM Case Rep* 2017; **4**(6): e005102-e.

6083 1575. El Feghaly RE, Sutton DA, Thompson EH, et al. *Graphium basitruncatum* fungemia in an
6084 immunosuppressed child post stem-cell transplantation. *Medical mycology case reports* 2012; **1**(1): 35-
6085 8.

6086 1576. Houbraken J, Spierenburg H, Frisvad JC. *Rasamsonia*, a new genus comprising thermotolerant
6087 and thermophilic *Talaromyces* and *Geosmithia* species. *Antonie van Leeuwenhoek* 2012; **101**(2): 403-21.

6088 1577. Marguet C, Favennec L, Matray O, et al. Clinical and microbiological efficacy of micafungin on
6089 *Geosmithia argillacea* infection in a cystic fibrosis patient. *Medical mycology case reports* 2012; **1**(1): 79-
6090 81.

6091 1578. Abdolrasouli A, Bercusson AC, Rhodes JL, et al. Airway persistence by the emerging multi-azole-
6092 resistant *Rasamsonia argillacea* complex in cystic fibrosis. *Mycoses* 2018; **61**(9): 665-73.

6093 1579. Babiker A, Gupta N, Gibas CFC, et al. Rasamsonia sp: An emerging infection amongst chronic
6094 granulomatous disease patients. A case of disseminated infection by a putatively novel Rasamsonia
6095 argillacea species complex involving the heart. *Med Mycol Case Rep* 2019; **24**: 54-7.
6096 1580. De Ravin SS, Challipalli M, Anderson V, et al. Geosmithia argillacea: an emerging cause of
6097 invasive mycosis in human chronic granulomatous disease. *Clin Infect Dis* 2011; **52**(6): e136-43.
6098 1581. Hong G, White M, Lechtzin N, et al. Fatal disseminated Rasamsonia infection in cystic fibrosis
6099 post-lung transplantation. *J Cyst Fibros* 2017; **16**(2): e3-e7.
6100 1582. Ishiwada N, Takeshita K, Yaguchi T, et al. The First Case of Invasive Mixed-Mold Infections Due to
6101 Emericella nidulans var. echinulata and Rasamsonia piperina in a Patient with Chronic Granulomatous
6102 Disease. *Mycopathologia* 2016; **181**(3-4): 305-9.
6103 1583. Machouart M, Garcia-Hermoso D, Rivier A, et al. Emergence of disseminated infections due to
6104 Geosmithia argillacea in patients with chronic granulomatous disease receiving long-term azole
6105 antifungal prophylaxis. *J Clin Microbiol* 2011; **49**(4): 1681-3.
6106 1584. Ocak I, Bollino G, Bering P, Sciortino C, Cavalcante J. Rasamsonia argillacea species complex
6107 myocarditis in a patient with chronic granulomatous disease. *Radiol Case Rep* 2019; **14**(6): 766-70.
6108 1585. Valentin T, Neumeister P, Pichler M, et al. Disseminated Geosmithia argillacea infection in a
6109 patient with gastrointestinal GvHD. *Bone Marrow Transplant* 2012; **47**(5): 734-6.
6110 1586. Giraud S, Favennec L, Bougnoux ME, Bouchara JP. Rasamsonia argillacea species complex:
6111 taxonomy, pathogenesis and clinical relevance. *Future Microbiol* 2013; **8**(8): 967-78.
6112 1587. Doyon JB, Sutton DA, Theodore P, et al. Rasamsonia argillacea pulmonary and aortic graft
6113 infection in an immune-competent patient. *J Clin Microbiol* 2013; **51**(2): 719-22.
6114 1588. Fujita Y, Ishiwada N, Takei H, et al. Usefulness of Gastric Aspirate Culture for Diagnosing
6115 Congenital Immunodeficiency in an Infant with Fungal Pneumonia Caused by Rasamsonia piperina.
6116 *Tohoku J Exp Med* 2019; **247**(4): 265-9.
6117 1589. Lamoth F, Chung SJ, Damonti L, Alexander BD. Changing Epidemiology of Invasive Mold
6118 Infections in Patients Receiving Azole Prophylaxis. *Clin Infect Dis* 2017; **64**(11): 1619-21.
6119 1590. Steinmann J, Dittmer S, Houbraken J, Buer J, Rath PM. In Vitro Activity of Isavuconazole against
6120 Rasamsonia Species. *Antimicrob Agents Chemother* 2016; **60**(11): 6890-1.
6121 1591. Giraud S, Pihet M, Razafimandimby B, et al. Geosmithia argillacea: an emerging pathogen in
6122 patients with cystic fibrosis. *J Clin Microbiol* 2010; **48**(7): 2381-6.
6123 1592. Matos T, Cerar T, Praprotnik M, Krivec U, Pirs M. First recovery of Rasamsonia argillacea species
6124 complex isolated in adolescent patient with cystic fibrosis in Slovenia--case report and review of
6125 literature. *Mycoses* 2015; **58**(8): 506-10.
6126 1593. Sohn JY, Jang MA, Lee JH, Park KS, Ki CS, Lee NY. Isolation and identification of Geosmithia
6127 argillacea from a fungal ball in the lung of a tuberculosis patient. *Ann Lab Med* 2013; **33**(2): 136-40.
6128 1594. Masoud-Landgraf L, Badura A, Eber E, Feierl G, Marth E, Buzina W. Modified culture method
6129 detects a high diversity of fungal species in cystic fibrosis patients. *Medical mycology* 2014; **52**(2): 179-
6130 86.
6131 1595. Prattes J, Koidl C, Eigl S, Krause R, Hoenigl M. Bronchoalveolar lavage fluid sample pretreatment
6132 with Sputasol((R)) significantly reduces galactomannan levels. *The Journal of infection* 2015; **70**(5): 541-
6133 3.
6134 1596. Steinmann J, Giraud S, Schmidt D, et al. Validation of a novel real-time PCR for detecting
6135 Rasamsonia argillacea species complex in respiratory secretions from cystic fibrosis patients. *New
6136 Microbes New Infect* 2014; **2**(3): 72-8.
6137 1597. Barker AP, Horan JL, Slechta ES, Alexander BD, Hanson KE. Complexities associated with the
6138 molecular and proteomic identification of Paecilomyces species in the clinical mycology laboratory.
6139 *Medical mycology* 2014; **52**(5): 537-45.
6140 1598. Houbraken J, Giraud S, Meijer M, et al. Taxonomy and antifungal susceptibility of clinically
6141 important Rasamsonia species. *J Clin Microbiol* 2013; **51**(1): 22-30.
6142 1599. Mouhajir A, Matray O, Giraud S, et al. Long-Term Rasamsonia argillacea Complex Species
6143 Colonization Revealed by PCR Amplification of Repetitive DNA Sequences in Cystic Fibrosis Patients. *J
6144 Clin Microbiol* 2016; **54**(11): 2804-12.

6145 1600. Grenouillet F, Cimon B, Pana-Katatali H, et al. Exophiala dermatitidis Revealing Cystic Fibrosis in
6146 Adult Patients with Chronic Pulmonary Disease. *Mycopathologia* 2018; **183**(1): 71-9.

6147 1601. Cummings JR, Jamison GR, Boudreaux JW, Howles MJ, Walsh TJ, Hayden RT. Cross-reactivity of
6148 non-Aspergillus fungal species in the Aspergillus galactomannan enzyme immunoassay. *Diagnostic*
6149 *microbiology and infectious disease* 2007; **59**(1): 113-5.

6150 1602. Giraud S, Favennec L, Bournoux M-E, Bouchara J-P. Rasamsonia argillacea species complex:
6151 taxonomy, pathogenesis and clinical relevance. *Future microbiology* 2013; **8**(8): 967-78.

6152 1603. Mouhajir A, Matray O, Giraud S, et al. Long-Term Rasamsonia argillacea Complex Species
6153 Colonization Revealed by PCR Amplification of Repetitive DNA Sequences in Cystic Fibrosis Patients.
6154 *Journal of clinical microbiology* 2016; **54**(11): 2804-12.

6155 1604. Guevara-Suarez M, Sutton DA, Cano-Lira JF, et al. Identification and Antifungal Susceptibility of
6156 Penicillium-Like Fungi from Clinical Samples in the United States. *J Clin Microbiol* 2016; **54**(8): 2155-61.

6157 1605. Abdolrasouli A, Bercusson AC, Rhodes JL, et al. Airway persistence by the emerging multi-azole-
6158 resistant Rasamsonia argillacea complex in cystic fibrosis. *Mycoses* 2018.

6159 1606. Michel J, Maubon D, Varoquaux DA, et al. Schizophyllum commune: an emergent or
6160 misdiagnosed fungal pathogen in rhinology? *Medical mycology* 2016; **54**(3): 301-9.

6161 1607. Shen Q, Yao YK, Yang Q, Zhou JY. Schizophyllum commune-induced Pulmonary Mycosis. *Chin*
6162 *Med J (Engl)* 2016; **129**(17): 2141-2.

6163 1608. Pekic S, Arsenijevic VA, Gazibara MS, et al. What lurks in the sellar? *Lancet (London, England)*
6164 2010; **375**(9712): 432-.

6165 1609. Hoenigl M, Aspeck E, Valentin T, et al. Sinusitis and frontal brain abscess in a diabetic patient
6166 caused by the basidiomycete Schizophyllum commune: case report and review of the literature.
6167 *Mycoses* 2013; **56**(3): 389-93.

6168 1610. Filipe R, Caldas JP, Soares N, et al. Schizophyllum commune sphenoidal sinusitis as presentation
6169 of a non-Hodgkin Lymphoma. *Medical Mycology Case Reports* 2020; **28**: 26-8.

6170 1611. Conen A, Weisser M, Hohler D, Frei R, Stern M. Hormographiella aspergillata: an emerging
6171 mould in acute leukaemia patients? *Clin Microbiol Infect* 2011; **17**(2): 273-7.

6172 1612. Godet C, Cateau E, Rammaert B, et al. Nebulized Liposomal Amphotericin B for Treatment of
6173 Pulmonary Infection Caused by Hormographiella aspergillata: Case Report and Literature Review.
6174 *Mycopathologia* 2017; **182**(7-8): 709-13.

6175 1613. Jain N, Jinagal J, Kaur H, et al. Ocular infection caused by Hormographiella aspergillata: A case
6176 report and review of literature. *J Mycol Med* 2019; **29**(1): 71-4.

6177 1614. Saha S, Sengupta J, Banerjee D, Khetan A, Mandal SM. Schizophyllum commune: a new
6178 organism in eye infection. *Mycopathologia* 2013; **175**(3-4): 357-60.

6179 1615. Reddy AK, Ashok R, Majety M, Chitta M, Narayen N. Fungal keratitis due to Schizophyllum
6180 commune: an emerging pathogenic fungus. *Mycoses* 2016; **59**(12): 757-9.

6181 1616. Chauhan A, Gruenberg J, Arbefeville S, Mettler T, Brent CH, Ferrieri P. Disseminated
6182 Hormographiella aspergillata Infection with Lung and Brain Involvement after Allogenic Hematopoietic
6183 Stem-Cell Transplantation in a 54-Year-Old Man. *Lab Med* 2019.

6184 1617. McNeil JC, Palazzi DL. Ustilago as a Cause of Fungal Peritonitis: Case Report and Review of the
6185 Literature. *J Pediatric Infect Dis Soc* 2012; **1**(4): 337-9.

6186 1618. Tone K, Fujisaki R, Hagiwara S, et al. Epidural abscess caused by Schizophyllum commune: A rare
6187 case of rhinogenic cranial complication by a filamentous basidiomycete. *Mycoses* 2018; **61**(3): 213-7.

6188 1619. McGhie TA, Huber TW, Kassis CE, Jinadatha C. Ustilago species as a cause of central line-related
6189 blood stream infection. *Am J Med Sci* 2013; **345**(3): 254-5.

6190 1620. Oliveira MME, Lemos AS, Goncalves MLC, et al. Fungemia associated with Schizophyllum
6191 commune in Brazil. *PLoS Negl Trop Dis* 2017; **11**(6): e0005549.

6192 1621. Chowdhary A, Randhawa HS, Gaur SN, et al. Schizophyllum commune as an emerging fungal
6193 pathogen: a review and report of two cases. *Mycoses* 2013; **56**(1): 1-10.

6194 1622. Greer EL, Kowalski TJ, Cole ML, Miller DV, Baddour LM. Truffle's revenge: a pig-eating fungus.
6195 *Cardiovasc Pathol* 2008; **17**(5): 342-3.

6196 1623. Abuali MM, Posada R, Del Toro G, et al. Rhizomucor variabilis var. regularior and
6197 Hormoglyphiella aspergillata infections in a leukemic bone marrow transplant recipient with refractory
6198 neutropenia. *J Clin Microbiol* 2009; **47**(12): 4176-9.

6199 1624. Adhikary R, Joshi S. Comment on: Schizophyllum commune sinusitis in an immunocompetent
6200 host. *Indian J Med Microbiol* 2012; **30**(2): 249.

6201 1625. Baron O, Cassaing S, Percodani J, et al. Nucleotide sequencing for diagnosis of sinus infection
6202 by Schizophyllum commune, an uncommon pathogenic fungus. *J Clin Microbiol* 2006; **44**(8): 3042-3.

6203 1626. Bartz-Schmidt KU, Tintelnot K, Steffen M, Ozel M, Kirchhof B, Heimann K. Chronic
6204 basidiomycetous endophthalmitis after extracapsular cataract extraction and intraocular lens
6205 implantation. *Graefes Arch Clin Exp Ophthalmol* 1996; **234**(9): 591-3.

6206 1627. Bojic M, Willinger B, Rath T, et al. Fatal skin and pulmonary infection caused by Hormoglyphiella
6207 aspergillata in a leukaemic patient: case report and literature overview. *Mycoses* 2013; **56**(6): 687-9.

6208 1628. Bulajic N, Cvijanovic V, Vukojevic J, Tomic D, Johnson E. Schizophyllum commune associated
6209 with bronchogenous cyst. *Mycoses* 2006; **49**(4): 343-5.

6210 1629. Buzina W, Lass-Flörl C, Kropshofer G, Freund MC, Marth E. The polypore mushroom Irpex
6211 lacteus, a new causative agent of fungal infections. *J Clin Microbiol* 2005; **43**(4): 2009-11.

6212 1630. Catalano P, Lawson W, Bottone E, Lebenger J. Basidiomycetous (mushroom) infection of the
6213 maxillary sinus. *Otolaryngol Head Neck Surg* 1990; **102**(2): 183-5.

6214 1631. Chan JF, Teng JL, Li IW, et al. Fatal empyema thoracis caused by Schizophyllum commune with
6215 cross-reactive cryptococcal antigenemia. *J Clin Microbiol* 2014; **52**(2): 683-7.

6216 1632. Chowdhary A, Agarwal K, Kathuria S, et al. Clinical significance of filamentous basidiomycetes
6217 illustrated by isolates of the novel opportunist Ceriporia lacerata from the human respiratory tract. *J Clin*
6218 *Microbiol* 2013; **51**(2): 585-90.

6219 1633. Correa-Martinez C, Brentrup A, Hess K, Becker K, Groll AH, Schaumburg F. First description of a
6220 local Coprinopsis cinerea skin and soft tissue infection. *New Microbes New Infect* 2018; **21**: 102-4.

6221 1634. Davis CM, Noroski LM, Dishop MK, et al. Basidiomycetous fungal Inonotus tropicalis sacral
6222 osteomyelitis in X-linked chronic granulomatous disease. *Pediatr Infect Dis J* 2007; **26**(7): 655-6.

6223 1635. Detporntewan P, Chindamporn A, Worasilchai N, Suankratay C. A case of invasive pulmonary
6224 infection caused by novel species of Perenniporia. *Mycoses* 2014; **57**(11): 703-5.

6225 1636. Dudeja L, Jeganathan L, Prajna NV, Prajna L. Fungal keratitis caused by Laetisaria arvalis. *Indian J*
6226 *Med Microbiol* 2018; **36**(1): 140-2.

6227 1637. Eghrari AO, Gibas C, Watkins T, et al. First Human Case of Fungal Keratitis Caused by a Putatively
6228 Novel Species of Lophotrichus. *J Clin Microbiol* 2015; **53**(9): 3063-7.

6229 1638. Fujii Y, Usui Y, Konno K, et al. [A case of hypersensitivity pneumonitis caused by smut spores of
6230 Ustilago esculenta]. *Nihon Kokyuki Gakkai Zasshi* 2007; **45**(4): 344-8.

6231 1639. Gauthier A, Jaubert J, Traversier N, et al. Trametes polyzona, an emerging filamentous
6232 basidiomycete in Reunion Island. *Mycoses* 2017; **60**(6): 412-5.

6233 1640. Hardin JS, Sutton DA, Wiederhold NP, Mele J, Goyal S. Fungal Keratitis Secondary to Trametes
6234 betulina: A Case Report and Review of Literature. *Mycopathologia* 2017; **182**(7-8): 755-9.

6235 1641. Heiblig M, Bozzoli V, Saison J, et al. Combined medico-surgical strategy for invasive sino-orbito-
6236 cerebral breakthrough fungal infection with Hormoglyphiella aspergillata in an acute leukaemia patient.
6237 *Mycoses* 2015; **58**(5): 308-12.

6238 1642. Katayama N, Fujimura M, Yasui M, Ogawa H, Nakao S. Hypersensitivity pneumonitis and
6239 bronchial asthma attacks caused by environmental fungi. *Allergol Int* 2008; **57**(3): 277-80.

6240 1643. Khan ZU, Randhawa HS, Kowshik T, Gaur SN, de Vries GA. The pathogenic potential of
6241 Sporotrichum pruinosum isolated from the human respiratory tract. *J Med Vet Mycol* 1988; **26**(3): 145-
6242 51.

6243 1644. Lagrou K, Massonet C, Theunissen K, et al. Fatal pulmonary infection in a leukaemic patient
6244 caused by Hormoglyphiella aspergillata. *J Med Microbiol* 2005; **54**(Pt 7): 685-8.

6245 1645. Marriott D, Kwong T, Harkness J, Ellis D. Cyclomyces tabacinus as a cause of deep tissue
6246 infection: the first case report. *Mycoses* 2006; **49**(2): 147-9.

6247 1646. Nanno S, Nakane T, Okamura H, et al. Disseminated *Hormographiella aspergillata* infection with
6248 involvement of the lung, brain, and small intestine following allogeneic hematopoietic stem cell
6249 transplantation: case report and literature review. *Transpl Infect Dis* 2016; **18**(4): 611-6.
6250 1647. Nenoff P, Friedrich T, Schwenke H, Mierzwa M, Horn LC, Hausteil UF. Rare fatal simultaneous
6251 mould infection of the lung caused by *Aspergillus flavus* and the basidiomycete *Coprinus* sp. in a
6252 leukemic patient. *J Med Vet Mycol* 1997; **35**(1): 65-9.
6253 1648. Nenoff P, Horn LC, Schwenke H, Mierzwa M, Rieske K, Hausteil UF. [Invasive mold infections in
6254 the university clinics of Leipzig in the period from 1992-1994]. *Mycoses* 1996; **39** Suppl 1: 107-12.
6255 1649. Patel R, Roberts GD, Kelly DG, Walker RC. Central venous catheter infection due to *Ustilago*
6256 species. *Clin Infect Dis* 1995; **21**(4): 1043-4.
6257 1650. Peric A, Vojvodic D, Zolotarevski L, Peric A. Nasal polyposis and fungal *Schizophyllum commune*
6258 infection: a case report. *Acta Medica (Hradec Kralove)* 2011; **54**(2): 83-6.
6259 1651. Premamalini T, Ambujavalli BT, Anitha S, Somu L, Kindo AJ. *Schizophyllum commune* a causative
6260 agent of fungal sinusitis: a case report. *Case Rep Infect Dis* 2011; **2011**: 821259.
6261 1652. Rihs JD, Padhye AA, Good CB. Brain abscess caused by *Schizophyllum commune*: an emerging
6262 basidiomycete pathogen. *J Clin Microbiol* 1996; **34**(7): 1628-32.
6263 1653. Roan JN, Hsieh HY, Tsai HW, et al. Pulmonary nodules caused by *Schizophyllum commune* after
6264 cardiac transplantation. *J Infect* 2009; **58**(2): 164-7.
6265 1654. Roh ML, Tuazon CU, Mandler R, Kwon-Chung KJ, Geist CE. Sphenocavernous syndrome
6266 associated with *Schizophyllum commune* infection of the sphenoid sinus. *Ophthalmic Plast Reconstr*
6267 *Surg* 2005; **21**(1): 71-4.
6268 1655. Rosenthal J, Katz R, DuBois DB, Morrissey A, Machicao A. Chronic maxillary sinusitis associated
6269 with the mushroom *Schizophyllum commune* in a patient with AIDS. *Clin Infect Dis* 1992; **14**(1): 46-8.
6270 1656. Sa HS, Ko KS, Woo KI, Peck KR, Kim YD. A case of sino-orbital infection caused by the
6271 *Schizophyllum commune*. *Diagn Microbiol Infect Dis* 2012; **73**(4): 376-7.
6272 1657. Salit RB, Shea YR, Gea-Banacloche J, et al. Death by edible mushroom: first report of *Volvariella*
6273 *volvacea* as an etiologic agent of invasive disease in a patient following double umbilical cord blood
6274 transplantation. *J Clin Microbiol* 2010; **48**(11): 4329-32.
6275 1658. Sigler L, Bartley JR, Parr DH, Morris AJ. Maxillary sinusitis caused by medusoid form of
6276 *Schizophyllum commune*. *J Clin Microbiol* 1999; **37**(10): 3395-8.
6277 1659. Sigler L, Estrada S, Montealegre NA, et al. Maxillary sinusitis caused by *Schizophyllum commune*
6278 and experience with treatment. *J Med Vet Mycol* 1997; **35**(5): 365-70.
6279 1660. Singh PK, Kathuria S, Agarwal K, Gaur SN, Meis JF, Chowdhary A. Clinical significance and
6280 molecular characterization of nonsporulating molds isolated from the respiratory tracts of
6281 bronchopulmonary mycosis patients with special reference to basidiomycetes. *J Clin Microbiol* 2013;
6282 **51**(10): 3331-7.
6283 1661. Singh SM, Singh M, Mukherjee S. Pathogenicity of *Sporotrichum pruninosum* and *Cladosporium*
6284 *oxysporum*, isolated from the bronchial secretions of a patient, for laboratory mice. *Mycopathologia*
6285 1992; **117**(3): 145-52.
6286 1662. Siqueira JP, Sutton D, Gene J, et al. *Schizophyllum radiatum*, an Emerging Fungus from Human
6287 Respiratory Tract. *J Clin Microbiol* 2016; **54**(10): 2491-7.
6288 1663. Speller DE, MacIver AG. Endocarditis caused by a *Coprinus* species: a fungus of the toadstool
6289 group. *J Med Microbiol* 1971; **4**(3): 370-4.
6290 1664. Stewart E, Waldman S, Sutton DA, et al. *Ustilago echinata*: Infection in a Mixed Martial Artist
6291 Following an Open Fracture. *Mycopathologia* 2016; **181**(3-4): 311-4.
6292 1665. Suarez F, Olivier G, Garcia-Hermoso D, et al. Breakthrough *Hormographiella aspergillata*
6293 infections arising in neutropenic patients treated empirically with caspofungin. *J Clin Microbiol* 2011;
6294 **49**(1): 461-5.
6295 1666. Surmont I, Van Aelst F, Verbanck J, De Hoog GS. A pulmonary infection caused by *Coprinus*
6296 *cinereus* (*Hormographiella aspergillata*) diagnosed after a neutropenic episode. *Medical mycology* 2002;
6297 **40**(2): 217-9.

6298 1667. Sutton DA, Thompson EH, Rinaldi MG, et al. Identification and first report of *Inonotus* (*Phellinus*)
6299 *tropicalis* as an etiologic agent in a patient with chronic granulomatous disease. *J Clin Microbiol* 2005;
6300 **43**(2): 982-7.

6301 1668. Swain B, Panigrahy R, Panigrahi D. *Schizophyllum commune* sinusitis in an immunocompetent
6302 host. *Indian J Med Microbiol* 2011; **29**(4): 439-42.

6303 1669. Toya T, Shinohara A, Tatsuno K, et al. A case of *Schizophyllum commune* sinusitis following
6304 unrelated cord blood transplantation for acute lymphoblastic leukemia. *Int J Hematol* 2013; **98**(2): 261-
6305 3.

6306 1670. Tullio V, Mandras N, Banche G, et al. *Schizophyllum commune*: an unusual of agent
6307 bronchopneumonia in an immunocompromised patient. *Medical mycology* 2008; **46**(7): 735-8.

6308 1671. Verma S, Gupta P, Singh D, Kanga A, Mohindroo NK, Jhobta A. *Schizophyllum commune* causing
6309 sinusitis with nasal polyposis in the sub-Himalayan region: first case report and review. *Mycopathologia*
6310 2014; **177**(1-2): 103-10.

6311 1672. Verweij PE, van Kasteren M, van de Nes J, de Hoog GS, de Pauw BE, Meis JF. Fatal pulmonary
6312 infection caused by the basidiomycete *Hormoglyphiella aspergillata*. *J Clin Microbiol* 1997; **35**(10): 2675-
6313 8.

6314 1673. Williamson D, Pandey S, Taylor S, et al. A case of infection caused by the basidiomycete
6315 *Phellinus undulatus*. *J Med Microbiol* 2011; **60**(Pt 2): 256-8.

6316 1674. Zuluaga A, Ospina-Medina J, Castano-Gallego I, Arango K, Gonzalez A. Frequency of fungal
6317 agents identified in sinus samples from patients with clinically suspected rhinosinusitis. *Diagn Microbiol*
6318 *Infect Dis* 2015; **81**(3): 208-12.

6319 1675. Haidar G, Zerbe CS, Cheng M, Zelazny AM, Holland SM, Sheridan KR. *Phellinus* species: An
6320 emerging cause of refractory fungal infections in patients with X-linked chronic granulomatous disease.
6321 *Mycoses* 2017; **60**(3): 155-60.

6322 1676. Shigemura T, Nakazawa Y, Amano Y, et al. Subcutaneous abscess due to the basidiomycete
6323 *Phellinus mori* in a patient with chronic granulomatous disease. *Infection* 2015; **43**(3): 371-5.

6324 1677. Chauhan A, Gruenberg J, Arbefeville S, Mettler T, Brent CH, Ferrieri P. Disseminated
6325 *Hormoglyphiella aspergillata* Infection with Lung and Brain Involvement after Allogenic Hematopoietic
6326 Stem-Cell Transplantation in a 54-Year-Old Man. *Lab Med* 2019; **50**(4): 426-31.

6327 1678. Buzina W, Lang-Loidolt D, Braun H, Freudenschuss K, Stammberger H. Development of
6328 molecular methods for identification of *Schizophyllum commune* from clinical samples. *Journal of*
6329 *clinical microbiology* 2001; **39**(7): 2391-6.

6330 1679. De Ravin SS, Parta M, Sutton DA, et al. Paravertebral mushroom: identification of a novel
6331 species of *Phellinus* as a human pathogen in chronic granulomatous disease. *J Clin Microbiol* 2014; **52**(7):
6332 2726-9.

6333 1680. Gonzalez GM, Sutton DA, Thompson E, Tijerina R, Rinaldi MG. In vitro activities of approved and
6334 investigational antifungal agents against 44 clinical isolates of basidiomycetous fungi. *Antimicrobial*
6335 *agents and chemotherapy* 2001; **45**(2): 633-5.

6336 1681. Chowdhary A, Kathuria S, Singh PK, et al. Molecular characterization and in vitro antifungal
6337 susceptibility profile of *Schizophyllum commune*, an emerging basidiomycete in bronchopulmonary
6338 mycoses. *Antimicrob Agents Chemother* 2013; **57**(6): 2845-8.

6339 1682. Ramesh M, Resnick E, Hui Y, et al. *Phellinus tropicalis* abscesses in a patient with chronic
6340 granulomatous disease. *J Clin Immunol* 2014; **34**(2): 130-3.

6341 1683. Toya T, Shinohara A, Tatsuno K, et al. A case of *Schizophyllum commune* sinusitis following
6342 unrelated cord blood transplantation for acute lymphoblastic leukemia. *International journal of*
6343 *hematology* 2013; **98**(2): 261-3.

6344 1684. Verma S, Gupta P, Singh D, Kanga A, Mohindroo NK, Jhobta A. *Schizophyllum commune* causing
6345 sinusitis with nasal polyposis in the sub-Himalayan region: first case report and review. *Mycopathologia*
6346 2014; **177**(1-2): 103-10.

6347 1685. Lim DS, Tan PL, Jureen R, Tan KB. Cutaneous Emboli of Invasive Basidiomycosis in a Child With
6348 Aplastic Anemia. *Am J Dermatopathol* 2017; **39**(3): 204-7.

- 6349 1686. Friman V, Gisslen M, Nikkari S, Stenlid J, Chryssanthou E, Petrini B. A fatal case of severe
6350 immunodeficiency associated with disseminated *Merulius tremellosus* infection. *Scand J Infect Dis* 2006;
6351 **38**(1): 76-8.
- 6352 1687. Gene J, Guillamon JM, Guarro J, Pujol I, Ulfing K. Molecular characterization, relatedness and
6353 antifungal susceptibility of the basidiomycetous *Hormographiella* species and *Coprinus cinereus* from
6354 clinical and environmental sources. *Antonie Van Leeuwenhoek* 1996; **70**(1): 49-57.
- 6355 1688. Koncan R, Nadali G. Invasive Fungal Infection by *Hormographyella aspergillata*: A Tricky
6356 Diagnosis Triggered by (1,3)-Beta-D-Glucan Assay. *Journal of Microbial & Biochemical Technology* 2016;
6357 **8**.
- 6358 1689. Won EJ, Shin JH, Lim SC, Shin MG, Suh SP, Ryang DW. Molecular identification of *Schizophyllum*
6359 *commune* as a cause of allergic fungal sinusitis. *Ann Lab Med* 2012; **32**(5): 375-9.
- 6360 1690. Correa-Martinez C, Brentrup A, Hess K, Becker K, Groll AH, Schaumburg F. First description of a
6361 local *Coprinopsis cinerea* skin and soft tissue infection. *New microbes and new infections* 2017; **21**: 102-
6362 4.
- 6363 1691. Chowdhary A, Kathuria S, Agarwal K, Meis JF. Recognizing filamentous basidiomycetes as agents
6364 of human disease: A review. *Medical mycology* 2014; **52**(8): 782-97.
- 6365 1692. Nguyen DK, Davis CM, Chinen J, Vallejo LM, Noroski LM. Basidiomycetous *Inonotus* (*Phellinus*)
6366 *tropicalis* Osteomyelitis in Pediatric and Adult X-linked Chronic Granulomatous Disease. *J ALLERGY CLIN*
6367 *IMMUNOL* 2009; **123**(2): S13.
- 6368 1693. Pérez-Cantero A, Guarro J. Current knowledge on the etiology and epidemiology of
6369 *Scopulariopsis* infections. *Medical mycology* 2020; **58**(2): 145-55.
- 6370 1694. Sandoval-Denis M, Gene J, Sutton DA, et al. Redefining *Microascus*, *Scopulariopsis* and allied
6371 genera. *Persoonia* 2016; **36**: 1-36.
- 6372 1695. Perez-Cantero A, Guarro J. Current knowledge on the etiology and epidemiology of
6373 *Scopulariopsis* infections. *Medical mycology* 2019.
- 6374 1696. Beltrame A, Sarmati L, Cudillo L, et al. A fatal case of invasive fungal sinusitis by *Scopulariopsis*
6375 *acremonium* in a bone marrow transplant recipient. *Int J Infect Dis* 2009; **13**(6): e488-92.
- 6376 1697. Helander L, Stark M. Fatal *Scopulariopsis brumptii* in a Pediatric Immunocompromised Host.
6377 *Fetal Pediatr Pathol* 2017; **36**(1): 82-6.
- 6378 1698. Kurata K, Nishimura S, Ichikawa H, et al. Invasive *Scopulariopsis alboflavescens* infection in
6379 patient with acute myeloid leukemia. *Int J Hematol* 2018; **108**(6): 658-64.
- 6380 1699. Martinez-Herrera EO, Arroyo-Camarena S, Tejada-Garcia DL, Porrás-Lopez CF, Arenas R.
6381 *Onychomycosis* due to opportunistic molds. *An Bras Dermatol* 2015; **90**(3): 334-7.
- 6382 1700. Macura AB, Skora M. 21-year retrospective study of the prevalence of *Scopulariopsis brevicaulis*
6383 in patients suspected of superficial mycoses. *Postepy Dermatol Alergol* 2015; **32**(3): 189-94.
- 6384 1701. Gavril D, Woerther PL, Ben Lakhdar A, et al. Invasive cutaneous infection due to *Scopulariopsis*
6385 *brevicaulis* unsuccessfully treated with high-dose micafungin in a neutropenic patient. *Infection* 2017;
6386 **45**(3): 361-3.
- 6387 1702. Kammoun S, Rekik M, Trabelsi H, Neji S, Feki J, Ayadi A. Orbital cellulitis secondary to a fungal
6388 sinusitis caused by *Scopulariopsis*: The first case in Tunisia. *J Mycol Med* 2018; **28**(2): 384-6.
- 6389 1703. Malecha MA. Fungal keratitis caused by *Scopulariopsis brevicaulis* treated successfully with
6390 natamycin. *Cornea* 2004; **23**(2): 201-3.
- 6391 1704. Oh BJ, Chae MJ, Cho D, et al. [Infection with *Scopulariopsis brevicaulis* after Cosmetic Surgery of
6392 the Face.]. *Korean J Lab Med* 2006; **26**(1): 32-5.
- 6393 1705. Kouyoumdjian GA, Forstot SL, Durairaj VD, Damiano RE. Infectious keratitis after laser refractive
6394 surgery. *Ophthalmology* 2001; **108**(7): 1266-8.
- 6395 1706. Salmon A, Debourgogne A, Vasbien M, et al. Disseminated *Scopulariopsis brevicaulis* infection in
6396 an allogeneic stem cell recipient: case report and review of the literature. *Clin Microbiol Infect* 2010;
6397 **16**(5): 508-12.
- 6398 1707. Ng KP, Soo-Hoo TS, Na SL, Gan GG, Sangkar JV, Teh AK. *Scopulariopsis brevicaulis* infection in a
6399 patient with acute myeloid leukemia. *Med J Malaysia* 2003; **58**(4): 608-12.

6400 1708. Jain D, Oberoi JK, Shahi SK, Shivnani G, Wattal C. Scopulariopsis brevicaulis infection of
6401 prosthetic valve resembling aspergilloma on histopathology. *Cardiovasc Pathol* 2011; **20**(6): 381-3.
6402 1709. Cawcutt K, Baddour LM, Burgess M. A Case of Scopulariopsis brevicaulis Endocarditis with
6403 Mycotic Aneurysm in an Immunocompetent Host. *Case Rep Med* 2015; **2015**: 872871.
6404 1710. Hagensee ME, Bauwens JE, Kjos B, Bowden RA. Brain abscess following marrow transplantation:
6405 experience at the Fred Hutchinson Cancer Research Center, 1984-1992. *Clin Infect Dis* 1994; **19**(3): 402-
6406 8.
6407 1711. Rose SR, Vallabhajosyula S, Velez MG, et al. The utility of bronchoalveolar lavage beta-D-glucan
6408 testing for the diagnosis of invasive fungal infections. *J Infect* 2014; **69**(3): 278-83.
6409 1712. Arroyo MA, Walls TB, Relich RF, Davis TE, Schmitt BH. The Brief Case: Scopulariopsis
6410 Endocarditis-a Case of Mistaken Takayasu's Arteritis. *J Clin Microbiol* 2017; **55**(9): 2567-72.
6411 1713. Aydin S, Ertugrul B, Gultekin B, Uyar G, Kir E. Treatment of two postoperative endophthalmitis
6412 cases due to Aspergillus flavus and Scopulariopsis spp. with local and systemic antifungal therapy. *BMC*
6413 *Infect Dis* 2007; **7**: 87.
6414 1714. Bruynzeel I, Starink TM. Granulomatous skin infection caused by Scopulariopsis brevicaulis.
6415 *Journal of the American Academy of Dermatology* 1998; **39**(2 Pt 2): 365-7.
6416 1715. Chen-Scarabelli C, Scarabelli TM. Fungal endocarditis due to Scopulariopsis. *Ann Intern Med*
6417 2003; **139**(9): W77.
6418 1716. Chung WK, Sung H, Kim MN, et al. Treatment-resistant Scopulariopsis brevicaulis infection after
6419 filler injection. *Acta Derm Venereol* 2009; **89**(6): 636-8.
6420 1717. Coley KC, Crain JL. Miconazole-induced fatal dysrhythmia. *Pharmacotherapy* 1997; **17**(2): 379-
6421 82.
6422 1718. Creus L, Umbert P, Torres-Rodriguez JM, Lopez-Gil F. Ulcerous granulomatous cheilitis with
6423 lymphatic invasion caused by Scopulariopsis brevicaulis infection. *Journal of the American Academy of*
6424 *Dermatology* 1994; **31**(5 Pt 2): 881-3.
6425 1719. Cuenca-Estrella M, Gomez-Lopez A, Buitrago MJ, Mellado E, Garcia-Effron G, Rodriguez-Tudela
6426 JL. In vitro activities of 10 combinations of antifungal agents against the multiresistant pathogen
6427 Scopulariopsis brevicaulis. *Antimicrob Agents Chemother* 2006; **50**(6): 2248-50.
6428 1720. de Miguel-Martinez I, Hernandez-Cabrera PM, Armesto-Fernandez MA, Martin-Sanchez AM.
6429 Necrotising otitis externa due to Scopulariopsis brevicaulis in a patient without predisposing factors.
6430 *Enferm Infecc Microbiol Clin* 2018; **36**(1): 62-4.
6431 1721. Del Prete A, Sepe G, Ferrante M, Loffredo C, Masciello M, Sebastiani A. Fungal keratitis due to
6432 Scopulariopsis brevicaulis in an eye previously suffering from herpetic keratitis. *Ophthalmologica* 1994;
6433 **208**(6): 333-5.
6434 1722. Ellison MD, Hung RT, Harris K, Campbell BH. Report of the first case of invasive fungal sinusitis
6435 caused by Scopulariopsis acremonium: review of scopulariopsis infections. *Arch Otolaryngol Head Neck*
6436 *Surg* 1998; **124**(9): 1014-6.
6437 1723. Gariano RF, Kalina RE. Posttraumatic fungal endophthalmitis resulting from Scopulariopsis
6438 brevicaulis. *Retina* 1997; **17**(3): 256-8.
6439 1724. Gentry LO, Nasser MM, Kielhofner M. Scopulariopsis endocarditis associated with Duran ring
6440 valvuloplasty. *Tex Heart Inst J* 1995; **22**(1): 81-5.
6441 1725. Ginarte M, Pereiro M, Jr., Fernandez-Redondo V, Toribio J. Plantar infection by Scopulariopsis
6442 brevicaulis. *Dermatology* 1996; **193**(2): 149-51.
6443 1726. Gluck O, Segal N, Yariv F, et al. Pediatric invasive sinonasal Scopulariopsis brevicaulis--a case
6444 report and literature review. *Int J Pediatr Otorhinolaryngol* 2011; **75**(7): 891-3.
6445 1727. Griebler HG, Rippon JW, Maliwan N, Daun V. Scopulariopsis and hypersensitivity pneumonitis
6446 in an addict. *Ann Intern Med* 1975; **83**(3): 326-9.
6447 1728. Guo-tao M, Qi M, Chao-ji Z, Li-hua C. Surgical removal of a giant vegetation on permanent
6448 endocavitary pacemaker wire and lead. *Chin Med Sci J* 2011; **26**(4): 251-3.
6449 1729. Hart AP, Sutton DA, McFeeley PJ, Kornfeld M. Cerebral phaeohyphomycosis caused by a
6450 dematiaceous scopulariopsis species. *Clin Neuropathol* 2001; **20**(5): 224-8.

6451 1730. Hennequin C, el-Bez M, Trotoux J, Simonet M. [Scopulariopsis brevicaulis otomycosis after
6452 tympanoplasty]. *Ann Otolaryngol Chir Cervicofac* 1994; **111**(6): 353-4.

6453 1731. Isidro AM, Amorosa V, Stopyra GA, Rutenberg HL, Pentz WH, Bridges CR. Fungal prosthetic
6454 mitral valve endocarditis caused by Scopulariopsis species: case report and review of the literature. *J*
6455 *Thorac Cardiovasc Surg* 2006; **131**(5): 1181-3.

6456 1732. Iwen PC, Schutte SD, Florescu DF, Noel-Hurst RK, Sigler L. Invasive Scopulariopsis brevicaulis
6457 infection in an immunocompromised patient and review of prior cases caused by Scopulariopsis and
6458 Microascus species. *Medical mycology* 2012; **50**(6): 561-9.

6459 1733. Jabor MA, Greer DL, Amedee RG. Scopulariopsis: an invasive nasal infection. *Am J Rhinol* 1998;
6460 **12**(5): 367-71.

6461 1734. Karam A, Hery G, Eveillard JR, et al. [Subcutaneous mycosis due to Scopulariopsis brevicaulis in
6462 an aplasic patient]. *Ann Dermatol Venereol* 2003; **130**(8-9 Pt 1): 783-6.

6463 1735. Kriesel JD, Adderson EE, Gooch WM, 3rd, Pavia AT. Invasive sinonasal disease due to
6464 Scopulariopsis candida: case report and review of scopulariopsosis. *Clinical infectious diseases : an*
6465 *official publication of the Infectious Diseases Society of America* 1994; **19**(2): 317-9.

6466 1736. Lotery AJ, Kerr JR, Page BA. Fungal keratitis caused by Scopulariopsis brevicaulis: successful
6467 treatment with topical amphotericin B and chloramphenicol without the need for surgical debridement.
6468 *Br J Ophthalmol* 1994; **78**(9): 730.

6469 1737. Martel J, Faisant M, Lebeau B, Pinel C, Feray C, Feuilhade M. [Subcutaneous mycosis due to
6470 Scopulariopsis brevicaulis in an immunocompromised patient]. *Ann Dermatol Venereol* 2001; **128**(2):
6471 130-3.

6472 1738. Migrino RQ, Hall GS, Longworth DL. Deep tissue infections caused by Scopulariopsis brevicaulis:
6473 report of a case of prosthetic valve endocarditis and review. *Clin Infect Dis* 1995; **21**(3): 672-4.

6474 1739. Mondal KK, Chattopadhyay C, Ray B, Das D, Biswas S, Banerjee P. Corneal ulcer with
6475 Scopulariopsis brevicaulis and Staphylococcus aureus--a rare case report. *J Indian Med Assoc* 2012;
6476 **110**(4): 253-4.

6477 1740. Morrison VA, Haake RJ, Weisdorf DJ. The spectrum of non-Candida fungal infections following
6478 bone marrow transplantation. *Medicine (Baltimore)* 1993; **72**(2): 78-89.

6479 1741. Muehrcke DD, Lytle BW, Cosgrove DM, 3rd. Surgical and long-term antifungal therapy for fungal
6480 prosthetic valve endocarditis. *Ann Thorac Surg* 1995; **60**(3): 538-43.

6481 1742. Nwabuisi C, Salami AK, Abdullahi NA, Agbede OO. Scopulariopsis associated meningitis in adult
6482 Nigerian AIDS patient--a case report. *West Afr J Med* 2003; **22**(4): 364-5.

6483 1743. Pate MJ, Hemmige V, Woc-Colburn L, Restrepo A. Successful eradication of invasive
6484 Scopulariopsis brumptii in a liver transplant recipient. *Transpl Infect Dis* 2016; **18**(2): 275-9.

6485 1744. Patel R, Gustaferrero CA, Krom RA, Wiesner RH, Roberts GD, Paya CV. Phaeohyphomycosis due to
6486 Scopulariopsis brumptii in a liver transplant recipient. *Clin Infect Dis* 1994; **19**(1): 198-200.

6487 1745. Petit A, Levine E, Epaud R, Le Pointe HD, Angoulvant A. Scopulariopsis brevicaulis abscess in a
6488 child treated for myeloblastic leukaemia. *The Lancet Infectious diseases* 2011; **11**(5): 416.

6489 1746. Phillips P, Wood WS, Phillips G, Rinaldi MG. Invasive hyalohyphomycosis caused by
6490 Scopulariopsis brevicaulis in a patient undergoing allogeneic bone marrow transplant. *Diagn Microbiol*
6491 *Infect Dis* 1989; **12**(5): 429-32.

6492 1747. Raevis JJ, Shaik N, Tseng J. Intravenous Drug Use-Associated Scopulariopsis Endophthalmitis
6493 Treated with Systemic and Intravitreal Voriconazole. *Case Rep Ophthalmol* 2018; **9**(1): 37-42.

6494 1748. Ragge NK, Hart JC, Easty DL, Tyers AG. A case of fungal keratitis caused by Scopulariopsis
6495 brevicaulis: treatment with antifungal agents and penetrating keratoplasty. *Br J Ophthalmol* 1990; **74**(9):
6496 561-2.

6497 1749. Rai S, Tiwari R, Sandhu SV, Rajkumar Y. Hyalohyphomycosis of maxillary antrum. *J Oral*
6498 *Maxillofac Pathol* 2012; **16**(1): 149-52.

6499 1750. Rakita RM, Lease ED, Edelman JD, Mulligan MS. Successful Treatment of Scopulariopsis Infection
6500 in a Lung Transplant Recipient. *Am J Transplant* 2015; **15**(7): 2010.

6501 1751. Sattler L, Sabou M, Ganeval-Stoll A, Dissaux C, Candolfi E, Letscher-Bru V. Sinusitis caused by
6502 Scopulariopsis brevicaulis: Case report and review of the literature. *Medical mycology case reports* 2014;
6503 5: 24-7.

6504 1752. Satyavani M, Viswanathan R, Harun NS, Mathew L. Pulmonary Scopulariopsis in a chronic
6505 tobacco smoker. *Singapore Med J* 2010; **51**(8): e137-9.

6506 1753. Sekhon AS, Willans DJ, Harvey JH. Deep scopulariopsosis: a case report and sensitivity studies. *J*
6507 *Clin Pathol* 1974; **27**(10): 837-43.

6508 1754. Sellier P, Monsuez JJ, Lacroix C, et al. Recurrent subcutaneous infection due to Scopulariopsis
6509 brevicaulis in a liver transplant recipient. *Clin Infect Dis* 2000; **30**(5): 820-3.

6510 1755. Shaver CM, Castilho JL, Cohen DN, et al. Fatal Scopulariopsis infection in a lung transplant
6511 recipient: lessons of organ procurement. *Am J Transplant* 2014; **14**(12): 2893-7.

6512 1756. Steinbach WJ, Schell WA, Miller JL, Perfect JR, Martin PL. Fatal Scopulariopsis brevicaulis
6513 infection in a paediatric stem-cell transplant patient treated with voriconazole and caspofungin and a
6514 review of Scopulariopsis infections in immunocompromised patients. *The Journal of infection* 2004;
6515 **48**(1): 112-6.

6516 1757. Swick BL, Reddy SC, Friedrichs A, Stone MS. Disseminated Scopulariopsis-culture is required to
6517 distinguish from other disseminated mould infections. *J Cutan Pathol* 2010; **37**(6): 687-91.

6518 1758. Szentel JA, Kam JK, Yohendran J, Morrissey O, Hall AJ. Presumed Scopulariopsis brevicaulis
6519 chorioretinitis in a stem cell transplant recipient. *Clin Exp Ophthalmol* 2010; **38**(3): 314-5.

6520 1759. Vaidya PS, Levine JF. Scopulariopsis peritonitis in a patient undergoing continuous ambulatory
6521 peritoneal dialysis. *Perit Dial Int* 1992; **12**(1): 78-9.

6522 1760. Vignon M, Michonneau D, Baixench MT, et al. Disseminated Scopulariopsis brevicaulis infection
6523 in an allogeneic stem cell recipient. *Bone Marrow Transplant* 2011; **46**(9): 1276-7.

6524 1761. Wagner D, Sander A, Bertz H, Finke J, Kern WV. Breakthrough invasive infection due to
6525 Debaryomyces hansenii (teleomorph Candida famata) and Scopulariopsis brevicaulis in a stem cell
6526 transplant patient receiving liposomal amphotericin B and caspofungin for suspected aspergillosis.
6527 *Infection* 2005; **33**(5-6): 397-400.

6528 1762. Wheat LJ, Bartlett M, Ciccarelli M, Smith JW. Opportunistic Scopulariopsis pneumonia in an
6529 immunocompromised host. *South Med J* 1984; **77**(12): 1608-9.

6530 1763. Wuyts WA, Molzahn H, Maertens J, et al. Fatal Scopulariopsis infection in a lung transplant
6531 recipient: a case report. *J Heart Lung Transplant* 2005; **24**(12): 2301-4.

6532 1764. Yang Q, Wei J, Chen Z. Fatal bronchial invasion of Scopulariopsis brevicaulis in an acute
6533 monocytic leukemia patient. *Diagn Microbiol Infect Dis* 2012; **73**(4): 369-71.

6534 1765. Arroyo MA, Walls TB, Relich RF, Davis TE, Schmitt BH. Closing the Brief Case: Scopulariopsis
6535 Endocarditis-a Case of Mistaken Takayasu's Arteritis. *J Clin Microbiol* 2017; **55**(9): 2872-3.

6536 1766. Miossec C, Morio F, Lepoivre T, et al. Fatal invasive infection with fungemia due to Microascus
6537 cirrosus after heart and lung transplantation in a patient with cystic fibrosis. *J Clin Microbiol* 2011; **49**(7):
6538 2743-7.

6539 1767. Kordalewska M, Jagielski T, Brillowska-Dabrowska A. Rapid Assays for Specific Detection of Fungi
6540 of Scopulariopsis and Microascus Genera and Scopulariopsis brevicaulis Species. *Mycopathologia* 2016;
6541 **181**(7-8): 465-74.

6542 1768. Bontems O, Hauser PM, Monod M. Evaluation of a polymerase chain reaction-restriction
6543 fragment length polymorphism assay for dermatophyte and nondermatophyte identification in
6544 onychomycosis. *Br J Dermatol* 2009; **161**(4): 791-6.

6545 1769. Kordalewska M, Brillowska-Dabrowska A. PCR Detection of Scopulariopsis brevicaulis. *Pol J*
6546 *Microbiol* 2015; **64**(1): 65-8.

6547 1770. Kordalewska M, Kalita J, Bakula Z, Brillowska-Dabrowska A, Jagielski T. PCR-RFLP assays for
6548 species-specific identification of fungi belonging to Scopulariopsis and related genera. *Medical mycology*
6549 2018.

6550 1771. Monod M, Bontems O, Zaugg C, Lechenne B, Fratti M, Panizzon R. Fast and reliable
6551 PCR/sequencing/RFLP assay for identification of fungi in onychomycoses. *J Med Microbiol* 2006; **55**(Pt
6552 9): 1211-6.

6553 1772. Woudenberg JHC, Meijer M, Houbraken J, Samson RA. Scopulariopsis and scopulariopsis-like
6554 species from indoor environments. *Stud Mycol* 2017; **88**: 1-35.

6555 1773. Rath S, Das SR, Padhy RN. Bayesian analysis of two methods MALDI-TOF-MS system and culture
6556 test in otomycosis infection. *World J Otorhinolaryngol Head Neck Surg* 2019; **5**(1): 6-13.

6557 1774. Aguilar C, Pujol I, Guarro J. In vitro antifungal susceptibilities of Scopulariopsis isolates.
6558 *Antimicrob Agents Chemother* 1999; **43**(6): 1520-2.

6559 1775. Cuenca-Estrella M, Gomez-Lopez A, Mellado E, Buitrago MJ, Monzon A, Rodriguez-Tudela JL.
6560 Scopulariopsis brevicaulis, a fungal pathogen resistant to broad-spectrum antifungal agents. *Antimicrob*
6561 *Agents Chemother* 2003; **47**(7): 2339-41.

6562 1776. Taton O, Bernier B, Etienne I, et al. Necrotizing Microascus tracheobronchitis in a bilateral lung
6563 transplant recipient. *Transpl Infect Dis* 2018; **20**(1).

6564 1777. Stavrakieva V, Kantardjiev T, Panaiotov S, Levterova V. PCR as a method for diagnosis of
6565 Scopulariopsis brevicaulis. *Probl Inf Parasit Dis* 2003; **31**: 14-6.

6566 1778. Jagielski T, Kosim K, Skora M, Macura AB, Bielecki J. Identification of Scopulariopsis species by
6567 partial 28S rRNA gene sequence analysis. *Pol J Microbiol* 2013; **62**(3): 303-6.

6568 1779. Yao L, Wan Z, Li R, Yu J. In Vitro Triple Combination of Antifungal Drugs against Clinical
6569 Scopulariopsis and Microascus Species. *Antimicrob Agents Chemother* 2015; **59**(8): 5040-3.

6570 1780. Skora M, Macura AB, Bulanda M. In vitro antifungal susceptibility of Scopulariopsis brevicaulis
6571 isolates. *Medical mycology* 2014; **52**(7): 723-7.

6572 1781. Skora M, Bulanda M, Jagielski T. In vitro activities of a wide panel of antifungal drugs against
6573 various Scopulariopsis and Microascus species. *Antimicrob Agents Chemother* 2015; **59**(9): 5827-9.

6574 1782. Martin-Vicente A, Guarro J, Capilla J. Does a triple combination have better activity than double
6575 combinations against multiresistant fungi? Experimental in vitro evaluation. *Int J Antimicrob Agents*
6576 2017; **49**(4): 422-6.

6577 1783. Baddley JW, Moser SA, Sutton DA, Pappas PG. Microascus cinereus (Anamorph scopulariopsis)
6578 brain abscess in a bone marrow transplant recipient. *J Clin Microbiol* 2000; **38**(1): 395-7.

6579 1784. Neglia JP, Hurd DD, Ferrieri P, Snover DC. Invasive Scopulariopsis in the immunocompromised
6580 host. *Am J Med* 1987; **83**(6): 1163-6.

6581 1785. Huang L, Chen W, Guo L, et al. Scopulariopsis/Microascus isolation in lung transplant recipients:
6582 A report of three cases and a review of the literature. *Mycoses* 2019; **62**(10): 883-92.

6583 1786. Mohammedi I, Piens MA, Audigier-Valette C, et al. Fatal Microascus trigonosporus (anamorph
6584 Scopulariopsis) pneumonia in a bone marrow transplant recipient. *Eur J Clin Microbiol Infect Dis* 2004;
6585 **23**(3): 215-7.

6586 1787. Celard M, Dannaoui E, Piens MA, et al. Early Microascus cinereus endocarditis of a prosthetic
6587 valve implanted after Staphylococcus aureus endocarditis of the native valve. *Clin Infect Dis* 1999; **29**(3):
6588 691-2.

6589 1788. Kimura U, Hiruma M, Kano R, Matsumoto T, Takamori K, Suga Y. Onychomycosis caused by
6590 Scopulariopsis brevicaulis: The third documented case in Japan. *J Dermatol* 2019; **46**(5): e167-e8.

6591 1789. Wilde C, Messina M, Moshiri T, Snape SE, Maharajan S. Interface Scopulariopsis gracilis fungal
6592 keratitis following Descemet's stripping automated endothelial keratoplasty (DSAEK) with a
6593 contaminated graft. *International ophthalmology* 2018; **38**(5): 2211-7.

6594 1790. Girmenia C, Iori AP. An update on the safety and interactions of antifungal drugs in stem cell
6595 transplant recipients. *Expert Opin Drug Saf* 2017; **16**(3): 329-39.

6596 1791. Krisher KK, Holdridge NB, Mustafa MM, Rinaldi MG, McGough DA. Disseminated Microascus
6597 cirrosus infection in pediatric bone marrow transplant recipient. *J Clin Microbiol* 1995; **33**(3): 735-7.

6598 1792. Houbraken J, Samson RA. Phylogeny of Penicillium and the segregation of Trichocomaceae into
6599 three families. *Stud Mycol* 2011; **70**(1): 1-51.

6600 1793. Ropars J, Cruaud C, Lacoste S, Dupont J. A taxonomic and ecological overview of cheese fungi.
6601 *Int J Food Microbiol* 2012; **155**(3): 199-210.

6602 1794. Clutterbuck PW, Lovell R, Raistrick H. Studies in the biochemistry of micro-organisms: The
6603 formation from glucose by members of the Penicillium chrysogenum series of a pigment, an alkali-
6604 soluble protein and penicillin-the antibacterial substance of Fleming. *Biochem J* 1932; **26**(6): 1907-18.

6605 1795. Marvisi M, Balzarini L, Mancini C, Mouzakiti P. A new type of Hypersensitivity Pneumonitis:
6606 salami brusher's disease. *Monaldi Arch Chest Dis* 2012; **77**(1): 35-7.

6607 1796. Mejia-Lozano P, Perez-Ortiz E. [Extrinsic allergic alveolitis in cheese scrubbers]. *Med Clin (Barc)*
6608 2014; **142**(8): 376-7.

6609 1797. Hoffman M, Bash E, Berger SA, Burke M, Yust I. Fatal necrotizing esophagitis due to *Penicillium*
6610 *chrysogenum* in a patient with acquired immunodeficiency syndrome. *European journal of clinical*
6611 *microbiology & infectious diseases : official publication of the European Society of Clinical Microbiology*
6612 1992; **11**(12): 1158-60.

6613 1798. Lyratzopoulos G, Ellis M, Nerringer R, Denning DW. Invasive infection due to *penicillium* species
6614 other than *P. marneffeii*. *The Journal of infection* 2002; **45**(3): 184-95.

6615 1799. Mok T, Koehler AP, Yu MY, Ellis DH, Johnson PJ, Wickham NW. Fatal *Penicillium citrinum*
6616 pneumonia with pericarditis in a patient with acute leukemia. *J Clin Microbiol* 1997; **35**(10): 2654-6.

6617 1800. Garg A, Stuart A, Fajgenbaum M, Laidlaw DA, Stanford M. Chronic postoperative fungal
6618 endophthalmitis caused by *Penicillium citrinum* after cataract surgery. *J Cataract Refract Surg* 2016;
6619 **42**(9): 1380-2.

6620 1801. Alvarez S. Systemic infection caused by *Penicillium decumbens* in a patient with acquired
6621 immunodeficiency syndrome. *The Journal of infectious diseases* 1990; **162**(1): 283-.

6622 1802. Huang SN, Harris LS. Acute disseminated penicilliosis: report of a case and review of pertinent
6623 literature. *Am J Clin Pathol* 1963; **39**: 167-74.

6624 1803. Chowdhary A, Kathuria S, Agarwal K, et al. Voriconazole-Resistant *Penicillium oxalicum*: An
6625 Emerging Pathogen in Immunocompromised Hosts. *Open Forum Infect Dis* 2014; **1**(2): ofu029.

6626 1804. Aviles-Robles M, Gomez-Ponce C, Resendiz-Sanchez J, Rodriguez-Tovar AV, Ceballos-Bocanegra
6627 A, Martinez-Rivera A. Disseminated penicilliosis due to *Penicillium chrysogenum* in a pediatric patient
6628 with Henoch-Schonlein syndrome. *Int J Infect Dis* 2016; **51**: 78-80.

6629 1805. Bohlke M, Souza PA, Menezes AM, Roth JM, Kramer LR. Peritonitis due to *Penicillium* and
6630 *Enterobacter* in a patient receiving continuous ambulatory peritoneal dialysis. *Braz J Infect Dis* 2007;
6631 **11**(1): 166-8.

6632 1806. Hodkin MJ, Gustus RC. Fungal Keratitis Associated With Airborne Organic Debris and Soft
6633 Contacts Lenses: Case Reports and Review of the Literature. *Eye Contact Lens* 2018; **44** Suppl 1: S16-S21.

6634 1807. DelRossi AJ, Morse D, Spagna PM, Lemole GM. Successful management of *Penicillium*
6635 endocarditis. *J Thorac Cardiovasc Surg* 1980; **80**(6): 945-7.

6636 1808. Swoboda-Kopec E, Wroblewska MM, Rokosz A, Luczak M. Mixed bloodstream infection with
6637 *Staphylococcus aureus* and *Penicillium chrysogenum* in an immunocompromised patient: case report
6638 and review of the literature. *Clin Microbiol Infect* 2003; **9**(11): 1116-7.

6639 1809. Zanatta R, Miniscalco B, Guarro J, et al. A case of disseminated mycosis in a German shepherd
6640 dog due to *Penicillium purpurogenum*. *Medical mycology* 2006; **44**(1): 93-7.

6641 1810. Alvarez S. Systemic infection caused by *Penicillium decumbens* in a patient with acquired
6642 immunodeficiency syndrome. *J Infect Dis* 1990; **162**(1): 283.

6643 1811. Ammerman E, Sweet SC, Fenchel M, et al. Risk and outcomes of pulmonary fungal infection
6644 after pediatric lung transplantation. *Clin Transplant* 2017; **31**(11).

6645 1812. Bates C, Read RC, Morice AH. A malicious mould. *Lancet* 1997; **349**(9065): 1598.

6646 1813. D'Antonio D, Violante B, Farina C, et al. Necrotizing pneumonia caused by *Penicillium*
6647 *chrysogenum*. *J Clin Microbiol* 1997; **35**(12): 3335-7.

6648 1814. de la Camara R, Pinilla I, Munoz E, Buendia B, Steegmann JL, Fernandez-Ranada JM. *Penicillium*
6649 *brevicompactum* as the cause of a necrotic lung ball in an allogeneic bone marrow transplant recipient.
6650 *Bone Marrow Transplant* 1996; **18**(6): 1189-93.

6651 1815. Dillard TA, Ortega I. Multiple endobronchial mycetomas with varied appearances and mixed
6652 fungal flora. *J Bronchology Interv Pulmonol* 2013; **20**(2): 147-9.

6653 1816. Equils O, Deville JG, Shapiro AM, Sanchez CP. *Penicillium* peritonitis in an adolescent receiving
6654 chronic peritoneal dialysis. *Pediatr Nephrol* 1999; **13**(9): 771-2.

6655 1817. Eschete ML, King JW, West BC, Oberle A. *Penicillium chrysogenum* endophthalmitis.
6656 *Mycopathologia* 1981; **74**(2): 125-7.

6657 1818. Fahhoum J, Gelfand MS. Peritonitis due to *Penicillium* sp in a patient receiving continuous
6658 ambulatory peritoneal dialysis. *South Med J* 1996; **89**(1): 87-8.

6659 1819. Galland F, le Goff L, Conrath J, Ridings B. [*Penicillium chrysogenum* endophthalmitis: a case
6660 report]. *J Fr Ophtalmol* 2004; **27**(3): 264-6.

6661 1820. Gelfand MS, Cole FH, Jr., Baskin RC. Invasive pulmonary penicilliosis: successful therapy with
6662 amphotericin B. *South Med J* 1990; **83**(6): 701-4.

6663 1821. Gilliam JS, Jr., Vest SA. *Penicillium* infection of the urinary tract. *J Urol* 1951; **65**(3): 484-9.

6664 1822. Gugnani HC, Gupta S, Talwar RS. Role of opportunistic fungi in ocular infections in Nigeria.
6665 *Mycopathologia* 1978; **65**(1-3): 155-66.

6666 1823. Hall WJ, 3rd. *Penicillium* endocarditis following open heart surgery and prosthetic valve
6667 insertion. *Am Heart J* 1974; **87**(4): 501-6.

6668 1824. Hesse SE, Luethy PM, Beigel JH, Zelazny AM. *Penicillium citrinum*: Opportunistic pathogen or
6669 idle bystander? A case analysis with demonstration of galactomannan cross-reactivity. *Med Mycol Case*
6670 *Rep* 2017; **17**: 8-10.

6671 1825. Hoffman M, Bash E, Berger SA, Burke M, Yust I. Fatal necrotizing esophagitis due to *Penicillium*
6672 *chrysogenum* in a patient with acquired immunodeficiency syndrome. *Eur J Clin Microbiol Infect Dis*
6673 1992; **11**(12): 1158-60.

6674 1826. Hofling-Lima AL, Forseto A, Duprat JP, et al. [Laboratory study of the mycotic infectious eye
6675 diseases and factors associated with keratitis]. *Arq Bras Oftalmol* 2005; **68**(1): 21-7.

6676 1827. Hove MG, Badalamenti J, Woods GL. *Penicillium* peritonitis in a patient receiving continuous
6677 ambulatory peritoneal dialysis. *Diagn Microbiol Infect Dis* 1996; **25**(2): 97-9.

6678 1828. Huang SN, Harris LS. Acute disseminated penicilliosis: report of a case and review of pertinent
6679 literature. *Am J Clin Pathol* 1963; **39**: 167-74.

6680 1829. Kantarcioglu AS, Apaydin H, Yucel A, et al. Central nervous system infection due to *Penicillium*
6681 *chrysogenum*. *Mycoses* 2004; **47**(5-6): 242-8.

6682 1830. Keceli S, Yegenaga I, Dagdelen N, Mutlu B, Uckardes H, Willke A. Case report: peritonitis by
6683 *Penicillium* spp. in a patient undergoing continuous ambulatory peritoneal dialysis. *Int Urol Nephrol*
6684 2005; **37**(1): 129-31.

6685 1831. Laguna TA, Sagel SD, Sontag MK, Accurso FJ. The clinical course of a Mexican female with cystic
6686 fibrosis and the novel genotype S531P/S531P. *J Cyst Fibros* 2008; **7**(5): 454-6.

6687 1832. Liebler GA, Magovern GJ, Sadighi P, Park SB, Cushing WJ. *Penicillium* granuloma of the lung
6688 presenting as a solitary pulmonary nodule. *JAMA* 1977; **237**(7): 671.

6689 1833. Lopez-Martinez R, Neumann L, Gonzalez-Mendoza A. Case report: cutaneous penicilliosis due to
6690 *Penicillium chrysogenum*. *Mycoses* 1999; **42**(4): 347-9.

6691 1834. Maddoux GL, Mohr JA, Muchmore HG. Pulmonary penicilliosis: a case presentation and a review
6692 of the literature. *J Okla State Med Assoc* 1972; **65**(10): 418-21.

6693 1835. Mancao MY, Figarola MS, Wilson FM, Mancini EA. Detection by CT scan of *Penicillium* sp. lesions
6694 in a patient with B-precursor acute lymphoblastic leukemia. *Pediatr Radiol* 2003; **33**(1): 66-8.

6695 1836. Miguelez S, Obrador P, Vila J. [Conjunctival infection due to *penicillium* SP]. *Arch Soc Esp*
6696 *Oftalmol* 2003; **78**(1): 55-7.

6697 1837. Morriss FH, Jr., Spock A. Intracranial aneurysm secondary to mycotic orbital and sinus infection.
6698 Report of a case implicating *penicillium* as an opportunistic fungus. *Am J Dis Child* 1970; **119**(4): 357-62.

6699 1838. Nouri ME. [Penicilliosis of the paranasal sinuses]. *Laryngol Rhinol Otol (Stuttg)* 1986; **65**(8):
6700 420-2.

6701 1839. Nunley DR, Gal AA, Vega JD, Perlino C, Smith P, Lawrence EC. Saprophytic fungal infections and
6702 complications involving the bronchial anastomosis following human lung transplantation. *Chest* 2002;
6703 **122**(4): 1185-91.

6704 1840. Pederson RT, Smith LG. *Penicillium* infection in man. *J Med Soc N J* 1974; **71**(2): 133-4.

6705 1841. Qadir MT, Cunha BA. *Penicillium* peritonitis in a patient receiving continuous ambulatory
6706 peritoneal dialysis. *Heart Lung* 1998; **27**(1): 67-8.

6707 1842. Safdar A, Singhal S, Mehta J. Clinical significance of non-Candida fungal blood isolation in
6708 patients undergoing high-risk allogeneic hematopoietic stem cell transplantation (1993-2001). *Cancer*
6709 2004; **100**(11): 2456-61.

6710 1843. Savir H, Henig E, Lehrer N. Exogenous mycotic infections of the eye and adnexia. *Ann*
6711 *Ophthalmol* 1978; **10**(8): 1013-8.

6712 1844. Shamberger RC, Weinstein HJ, Grier HE, Levey RH. The surgical management of fungal
6713 pulmonary infections in children with acute myelogenous leukemia. *J Pediatr Surg* 1985; **20**(6): 840-4.

6714 1845. Swan SK, Wagner RA, Myers JP, Cinelli AB. Mycotic endophthalmitis caused by *Penicillium* sp.
6715 after parenteral drug abuse. *Am J Ophthalmol* 1985; **100**(3): 408-10.

6716 1846. Theodore FH. Etiology and diagnosis of fungal postoperative endophthalmitis. *Ophthalmology*
6717 1978; **85**(4): 327-40.

6718 1847. Upshaw CB, Jr. *Penicillium* endocarditis of aortic valve prosthesis. *J Thorac Cardiovasc Surg*
6719 1974; **68**(3): 428-31.

6720 1848. Vasconcelos-Santos DV, Nehemy MB. Use of voriconazole in the surgical management of chronic
6721 postoperative fungal endophthalmitis. *Ophthalmic Surg Lasers Imaging* 2009; **40**(4): 425-31.

6722 1849. Wang LY, Yang ZJ, Yang XY, Sun ST. [Experimental study of fast diagnosis of mycotic keratitis
6723 using molecular biology technical]. *Zhonghua Yan Ke Za Zhi* 2007; **43**(3): 256-9.

6724 1850. Oshikata C, Tsurikisawa N, Saito A, et al. Fatal pneumonia caused by *Penicillium digitatum*: a
6725 case report. *BMC Pulm Med* 2013; **13**: 16-.

6726 1851. Cao C, Xi L, Chaturvedi V. Talaromycosis (*Penicilliosis*) Due to *Talaromyces* (*Penicillium*)
6727 *marneffeii*: Insights into the Clinical Trends of a Major Fungal Disease 60 Years After the Discovery of the
6728 Pathogen. *Mycopathologia* 2019; **184**(6): 709-20.

6729 1852. Ustianowski AP, Sieu TP, Day JN. *Penicillium marneffeii* infection in HIV. *Curr Opin Infect Dis*
6730 2008; **21**(1): 31-6.

6731 1853. Lee PP, Lau YL. Cellular and Molecular Defects Underlying Invasive Fungal Infections-Revelations
6732 from Endemic Mycoses. *Front Immunol* 2017; **8**: 735.

6733 1854. Radulesco T, Varoquaux A, Ranque S, Dessi P, Michel J, Cassagne C. A Case of Fungus Ball-Type
6734 Maxillary Sinusitis Due to *Penicillium Roqueforti*. *Mycopathologia* 2018; **183**(2): 439-43.

6735 1855. Vollmer T, Stormer M, Kleesiek K, Dreier J. Evaluation of novel broad-range real-time PCR assay
6736 for rapid detection of human pathogenic fungi in various clinical specimens. *J Clin Microbiol* 2008; **46**(6):
6737 1919-26.

6738 1856. Reboux G, Rocchi S, Vacheyrou M, Millon L. Identifying indoor air *Penicillium* species: a
6739 challenge for allergic patients. *J Med Microbiol* 2019; **68**(5): 812-21.

6740 1857. Prattes J, Lackner M, Eigl S, et al. Diagnostic accuracy of the *Aspergillus*-specific bronchoalveolar
6741 lavage lateral-flow assay in haematological malignancy patients. *Mycoses* 2015; **58**(8): 461-9.

6742 1858. Willinger B, Lackner M, Lass-Flörl C, et al. Bronchoalveolar Lavage Lateral-Flow Device Test for
6743 Invasive Pulmonary *Aspergillo*sis in Solid Organ Transplant Patients: A Semi-Prospective Multicenter
6744 Study. *Transplantation* 2014; **accepted manuscript**.

6745 1859. Swanink CM, Meis JF, Rijs AJ, Donnelly JP, Verweij PE. Specificity of a sandwich enzyme-linked
6746 immunosorbent assay for detecting *Aspergillus galactomannan*. *Journal of clinical microbiology* 1997;
6747 **35**(1): 257-60.

6748 1860. Odabasi Z, Mattiuzzi G, Estey E, et al. Beta-D-glucan as a diagnostic adjunct for invasive fungal
6749 infections: validation, cutoff development, and performance in patients with acute myelogenous
6750 leukemia and myelodysplastic syndrome. *Clinical infectious diseases : an official publication of the*
6751 *Infectious Diseases Society of America* 2004; **39**(2): 199-205.

6752 1861. Geltner C, Lass-Flörl C, Bonatti H, Müller L, Stelzmueller I. Invasive pulmonary mycosis due to
6753 *Penicillium chrysogenum*: a new invasive pathogen. *Transplantation* 2013; **95**(4): e21-3.

6754 1862. Iwasaki T, Matsuno K, Yamamoto M, Kawahata D, Keino H. *Penicillium* endophthalmitis in
6755 necrotizing scleritis treated with topical corticosteroid and cyclosporin A. *Jpn J Ophthalmol* 2008; **52**(6):
6756 506-8.

6757 1863. Visagie CM, Houbraken J, Frisvad JC, et al. Identification and nomenclature of the genus
6758 *Penicillium*. *Stud Mycol* 2014; **78**: 343-71.

6759 1864. Barcus AL, Burdette SD, Herchline TE. Intestinal invasion and disseminated disease associated
6760 with *Penicillium chrysogenum*. *Ann Clin Microbiol Antimicrob* 2005; **4**: 21.

6761 1865. Mennink-Kersten MA, Donnelly JP, Verweij PE. Detection of circulating galactomannan for the
6762 diagnosis and management of invasive aspergillosis. *Lancet Infect Dis* 2004; **4**(6): 349-57.

6763 1866. Lau SKP, Lam CSK, Ngan AHY, et al. Matrix-assisted laser desorption ionization time-of-flight
6764 mass spectrometry for rapid identification of mold and yeast cultures of *Penicillium marneffei*. *BMC*
6765 *Microbiol* 2016; **16**: 36-.

6766 1867. Mohammadi A, Hashemi SM, Abtahi SH, Lajevardi SM, Kianipour S, Mohammadi R. An
6767 investigation on non-invasive fungal sinusitis; Molecular identification of etiologic agents. *J Res Med Sci*
6768 2017; **22**: 67.

6769 1868. Oshikata C, Tsurikisawa N, Saito A, et al. Fatal pneumonia caused by *Penicillium digitatum*: a
6770 case report. *BMC Pulm Med* 2013; **13**: 16.

6771 1869. Chen M, Houbraken J, Pan W, et al. Pulmonary fungus ball caused by *Penicillium capsulatum* in a
6772 patient with type 2 diabetes: a case report. *BMC Infect Dis* 2013; **13**: 496.

6773 1870. Yoshida K, Hiraoka T, Ando M, Uchida K, Mohsenin V. *Penicillium decumbens*. A new cause of
6774 fungus ball. *Chest* 1992; **101**(4): 1152-3.

6775 1871. D'Antonio D, Violante B, Farina C, et al. Necrotizing pneumonia caused by *Penicillium*
6776 *chrysogenum*. *Journal of clinical microbiology* 1997; **35**(12): 3335-7.

6777 1872. Qiu Y, Zhang J, Liu G, et al. Retrospective analysis of 14 cases of disseminated *Penicillium*
6778 *marneffei* infection with osteolytic lesions. *BMC infectious diseases* 2015; **15**: 47-.

6779 1873. Beh CP, George J. Disseminated *Penicillium marneffei* infection. *The Medical journal of Malaysia*
6780 2009; **64**(1): 86-8.

6781 1874. Noritomi DT, Bub GL, Beer I, da Silva ASF, de Cleve R, Gama-Rodrigues JJ. Multiple brain
6782 abscesses due to *Penicillium* spp infection. *Rev Inst Med Trop Sao Paulo* 2005; **47**(3): 167-70.

6783 1875. Zhang Z, Tao F, Li Y, Xiao Y, Zhang Z, Liu J. Disseminated *Penicillium marneffei* infection
6784 recurrence in a non-acquired immune deficiency syndrome patient: A case report. *Mol Clin Oncol* 2016;
6785 **5**(6): 829-31.

6786 1876. Ye F, Luo Q, Zhou Y, et al. Disseminated penicilliosis *marneffei* in immunocompetent patients: a
6787 report of two cases. *Indian journal of medical microbiology* 2015; **33**(1): 161-5.

6788 1877. Cheng NC, Wong WW, Fung CP, Liu CY. Unusual pulmonary manifestations of disseminated
6789 *Penicillium marneffei* infection in three AIDS patients. *Medical mycology* 1998; **36**(6): 429-32.

6790 1878. Hung C-C, Chang S-Y, Sun H-Y, Hsueh P-R. Cavitory pneumonia due to *Penicillium marneffei* in an
6791 HIV-infected patient. *Am J Respir Crit Care Med* 2013; **187**(2): e3-e4.

6792 1879. Lu P-x, Zhu W-k, Liu Y, et al. Acquired immunodeficiency syndrome associated disseminated
6793 *Penicillium Marneffei* infection: report of 8 cases. *Chinese medical journal* 2005; **118**(16): 1395-9.

6794 1880. Yadav S, Gupta R, Anuradha S, Makkar AM. A rare case of disseminated penicilliosis - first of its
6795 kind from North India. *Indian J Pathol Microbiol* 2019; **62**(1): 156-8.

6796 1881. Sun HY, Chen MY, Hsiao CF, Hsieh SM, Hung CC, Chang SC. Endemic fungal infections caused by
6797 *Cryptococcus neoformans* and *Penicillium marneffei* in patients infected with human immunodeficiency
6798 virus and treated with highly active anti-retroviral therapy. *Clinical microbiology and infection : the*
6799 *official publication of the European Society of Clinical Microbiology and Infectious Diseases* 2006; **12**(4):
6800 381-8.

6801 1882. McShane H, Tang CM, Conlon CP. Disseminated *Penicillium marneffei* infection presenting as a
6802 right upper lobe mass in an HIV positive patient. *Thorax* 1998; **53**(10): 905-6.

6803 1883. Jung JY, Jo GH, Kim H-S, et al. Disseminated penicilliosis in a Korean human immunodeficiency
6804 virus infected patient from Laos. *J Korean Med Sci* 2012; **27**(6): 697-700.

6805 1884. Santos PE, Piontelli E, Shea YR, et al. *Penicillium piceum* infection: diagnosis and successful
6806 treatment in chronic granulomatous disease. *Medical mycology* 2006; **44**(8): 749-53.

6807 1885. Lin CY, Sun HY, Chen MY, et al. Aetiology of cavitory lung lesions in patients with HIV infection.
6808 *HIV Med* 2009; **10**(3): 191-8.

6809 1886. Wang Y-G, Cheng J-M, Ding H-B, et al. Study on the Clinical Features and Prognosis of
6810 Penicilliosis marneffei Without Human Immunodeficiency Virus Infection. *Mycopathologia* 2018; **183**(3):
6811 551-8.

6812 1887. George IA, Sudarsanam TD, Pulimood AB, Mathews MS. Acute abdomen: an unusual
6813 presentation of disseminated *Penicillium marneffei* infection. *Indian journal of medical microbiology*
6814 2008; **26**(2): 180-2.

6815 1888. Othman N, Yip CW, Intan HI, Zainuddin Z, Amran F. An abdominal mass owing to *Penicillium*
6816 *marneffei* in an HIV-infected 7-year-old boy: case report. *Ann Trop Paediatr* 2006; **26**(3): 259-62.

6817 1889. Chan YF, Woo KC. *Penicillium marneffei* osteomyelitis. *J Bone Joint Surg Br* 1990; **72**(3): 500-3.

6818 1890. Louthrenoo W, Thamprasert K, Sirisanthana T. Osteoarticular penicilliosis marneffei. A report of
6819 eight cases and review of the literature. *Br J Rheumatol* 1994; **33**(12): 1145-50.

6820 1891. Sudjaritruk T, Sirisanthana T, Sirisanthana V. Immune reconstitution inflammatory syndrome
6821 from *Penicillium marneffei* in an HIV-infected child: a case report and review of literature. *BMC*
6822 *infectious diseases* 2012; **12**: 28-.

6823 1892. Kanda K, Takayama K, Enoki T, Takeuchi M. Chronic postcataract endophthalmitis caused by
6824 *Penicillium* species in an immunocompetent patient. *Int Med Case Rep J* 2018; **11**: 259-62.

6825 1893. Villanueva-Lozano H, Trevino-Rangel RJ, Renpenning-Carrasco EW, Gonzalez GM. Successful
6826 treatment of *Talaromyces amestolkiae* pulmonary infection with voriconazole in an acute lymphoblastic
6827 leukemia patient. *J Infect Chemother* 2017; **23**(6): 400-2.

6828 1894. Atalay A, Koc AN, Akyol G, Cakir N, Kaynar L, Ulu-Kilic A. Pulmonary infection caused by
6829 *Talaromyces purpurogenus* in a patient with multiple myeloma. *Infez Med* 2016; **24**(2): 153-7.

6830 1895. Sili U, Bilgin H, Masania R, et al. Successful treatment of an invasive fungal infection caused by
6831 *Talaromyces* sp. with voriconazole. *Med Mycol Case Rep* 2015; **8**: 21-3.

6832 1896. Yilmaz N, Houbraken J, Hoekstra ES, Frisvad JC, Visagie CM, Samson RA. Delimitation and
6833 characterisation of *Talaromyces purpurogenus* and related species. *Persoonia* 2012; **29**: 39-54.

6834 1897. Horr e R, Gilges S, Breig P, et al. Case report. Fungaemia due to *Penicillium piceum*, a member of
6835 the *Penicillium marneffei* complex. *Mycoses* 2001; **44**(11-12): 502-4.

6836 1898. Breton P, Germaud P, Morin O, Audouin AF, Milpied N, Harousseau JL. [Rare pulmonary mycoses
6837 in patients with hematologic diseases]. *Rev Pneumol Clin* 1998; **54**(5): 253-7.

6838 1899. Zainudin L, Shariff R, Hanafiah M, Mohd Noh R, Yuhana Y, Awad S. Disseminated penicilliosis
6839 (non- *Penicillium marneffei*) in an immuno-competent individual in Malaysia. *Proceedings of Singapore*
6840 *Healthcare* 2017: 201010581773901.

6841 1900. Ryu M, Yoo I, Song D, Huh H, Ki C-S, Lee N. *Penicillium* Species Other Than *Talaromyces*
6842 *marneffei* Producing Red Pigment from Clinical Specimens: Isolation of *Talaromyces albobiverticillius*.
6843 *Laboratory Medicine Online* 2017; **7**: 211.

6844 1901. Urquhart AS, Mondo SJ, M kel  MR, et al. Genomic and Genetic Insights Into a Cosmopolitan
6845 Fungus, *Paecilomyces variotii* (Eurotiales). *Frontiers in microbiology* 2018; **9**: 3058-.

6846 1902. Lamagni TL, Campbell C, Pezzoli L, Johnson E. Unexplained increase in *Paecilomyces variotii*
6847 blood culture isolates in the UK. *Euro Surveill* 2006; **11**(11): E061116.2.

6848 1903. Feldman R, Cockerham L, Buchan BW, Lu Z, Huang AM. Treatment of *Paecilomyces variotii*
6849 pneumonia with posaconazole: case report and literature review. *Mycoses* 2016; **59**(12): 746-50.

6850 1904. Marques DP, Carvalho J, Rocha S, Domingos R. A Case of Pulmonary Mycetoma Caused by
6851 *Paecilomyces variotii*. *Eur J Case Rep Intern Med* 2019; **6**(2): 001040-.

6852 1905. Luangsa-Ard J, Houbraken J, van Doorn T, et al. *Purpureocillium*, a new genus for the medically
6853 important *Paecilomyces lilacinus*. *FEMS microbiology letters* 2011; **321**(2): 141-9.

6854 1906. Barker AP, Horan JL, Slechta ES, Alexander BD, Hanson KE. Complexities associated with the
6855 molecular and proteomic identification of *Paecilomyces* species in the clinical mycology laboratory. *Med*
6856 *Mycol* 2014; **52**(5): 537-45.

6857 1907. Bellanger AP, Cervoni JP, Faucher JF, et al. *Paecilomyces variotii* Fungemia in a Patient with
6858 Lymphoma Needing Liver Transplant. *Mycopathologia* 2017; **182**(7-8): 761-5.

6859 1908. Torres R, Gonzalez M, Sanhueza M, et al. Outbreak of Paecilomyces variotii peritonitis in
6860 peritoneal dialysis patients after the 2010 Chilean earthquake. *Peritoneal dialysis international : journal*
6861 *of the International Society for Peritoneal Dialysis* 2014; **34**(3): 322-5.

6862 1909. Tarkkanen A, Raivio V, Anttila V-J, et al. Fungal endophthalmitis caused by Paecilomyces variotii
6863 following cataract surgery: a presumed operating room air-conditioning system contamination. *Acta*
6864 *Ophthalmol Scand* 2004; **82**(2): 232-5.

6865 1910. Steiner B, Aquino VR, Paz AA, Silla LMdR, Zavascki A, Goldani LZ. Paecilomyces variotii as an
6866 Emergent Pathogenic Agent of Pneumonia. *Case reports in infectious diseases* 2013; **2013**: 273848-.

6867 1911. Salle V, Lecuyer E, Chouaki T, et al. Paecilomyces variotii fungemia in a patient with multiple
6868 myeloma: case report and literature review. *The Journal of infection* 2005; **51**(3): e93-e5.

6869 1912. Lee J, Yew WW, Chiu CSW, Wong PC, Wong CF, Wang EP. Delayed sternotomy wound infection
6870 due to Paecilomyces variotii in a lung transplant recipient. *The Journal of heart and lung transplantation*
6871 *: the official publication of the International Society for Heart Transplantation* 2002; **21**(10): 1131-4.

6872 1913. Eren D, Eroglu E, Ulu Kilic A, et al. Cutaneous ulcerations caused by Paecilomyces variotii in a
6873 renal transplant recipient. *Transplant infectious disease : an official journal of the Transplantation*
6874 *Society* 2018; **20**(3): e12871-e.

6875 1914. Cohen-Abbo A, Edwards KM. Multifocal osteomyelitis caused by Paecilomyces varioti in a
6876 patient with chronic granulomatous disease. *Infection* 1995; **23**(1): 55-7.

6877 1915. Abolghasemi S, Tabarsi P, Adimi P, Kiani A, Dolatshahi S, Mansouri D. Pulmonary Paecilomyces in
6878 a Diabetic Patient. *Tanaffos* 2015; **14**(4): 268-71.

6879 1916. Akhunov VM, Akhunova AM, Lavrent'eva TP. [Hypereosinophilic Syndrome Associated with
6880 Sepsis Due to Paecilomyces Fungi Disseminated into the Liver]. *Klin Med (Mosk)* 2016; **94**(2): 149-52.

6881 1917. Akhunova AM, Shustova VI. [Paecilomyces infection]. *Probl Tuberk* 1989; (8): 38-42.

6882 1918. Ali TK, Amescua G, Miller D, et al. Contact-Lens-Associated Purpureocillium Keratitis: Risk
6883 Factors, Microbiologic Characteristics, Clinical Course, and Outcomes. *Semin Ophthalmol* 2017; **32**(2):
6884 157-62.

6885 1919. Alkorta Gurrutxaga M, Saiz Camin M, Rodriguez Anton L. [Fungal endocarditis in a patient
6886 bearing a valve prosthesis]. *Enferm Infecc Microbiol Clin* 2007; **25**(8): 549-50.

6887 1920. Anita KB, Fernandez V, Rao R. Fungal endophthalmitis caused by Paecilomyces variotii, in an
6888 immunocompetent patient, following intraocular lens implantation. *Indian J Med Microbiol* 2010; **28**(3):
6889 253-4.

6890 1921. Athar MA, Sekhon AS, McGrath JV, Malone RM. Hyalohyphomycosis caused by Paecilomyces
6891 variotii in an obstetrical patient. *Eur J Epidemiol* 1996; **12**(1): 33-5.

6892 1922. Bibashi E, Kokolina E, Sigler L, et al. Three cases of uncommon fungal peritonitis in patients
6893 undergoing peritoneal dialysis. *Perit Dial Int* 2002; **22**(4): 523-5.

6894 1923. Byrd RP, Jr., Roy TM, Fields CL, Lynch JA. Paecilomyces varioti pneumonia in a patient with
6895 diabetes mellitus. *J Diabetes Complications* 1992; **6**(2): 150-3.

6896 1924. Chamilos G, Kontoyiannis DP. Voriconazole-resistant disseminated Paecilomyces variotii
6897 infection in a neutropenic patient with leukaemia on voriconazole prophylaxis. *J Infect* 2005; **51**(4):
6898 e225-8.

6899 1925. Chan TH, Koehler A, Li PK. Paecilomyces varioti peritonitis in patients on continuous ambulatory
6900 peritoneal dialysis. *Am J Kidney Dis* 1996; **27**(1): 138-42.

6901 1926. Chen YS, Liu YH, Teng SH, et al. Evaluation of the matrix-assisted laser desorption/ionization
6902 time-of-flight mass spectrometry Bruker Biotyper for identification of Penicillium marneffeii,
6903 Paecilomyces species, Fusarium solani, Rhizopus species, and Pseudallescheria boydii. *Frontiers in*
6904 *microbiology* 2015; **6**: 679.

6905 1927. Crompton CH, Balfe JW, Summerbell RC, Silver MM. Peritonitis with Paecilomyces complicating
6906 peritoneal dialysis. *Pediatr Infect Dis J* 1991; **10**(11): 869-71.

6907 1928. Das A, MacLaughlin EF, Ross LA, et al. Paecilomyces variotii in a pediatric patient with lung
6908 transplantation. *Pediatr Transplant* 2000; **4**(4): 328-32.

6909 1929. Dharmasena FM, Davies GS, Catovsky D. Paecilomyces varioti pneumonia complicating hairy cell
6910 leukaemia. *Br Med J (Clin Res Ed)* 1985; **290**(6473): 967-8.

6911 1930. Drogari-Apiranthitou M, Mantopoulou FD, Skiada A, et al. In vitro antifungal susceptibility of
6912 filamentous fungi causing rare infections: synergy testing of amphotericin B, posaconazole and
6913 anidulafungin in pairs. *J Antimicrob Chemother* 2012; **67**(8): 1937-40.

6914 1931. Eisinger RP, Weinstein MP. A bold mold? *Paecilomyces variotii* peritonitis during continuous
6915 ambulatory peritoneal dialysis. *Am J Kidney Dis* 1991; **18**(5): 606-8.

6916 1932. Eren D, Eroglu E, Ulu Kilic A, et al. Cutaneous ulcerations caused by *Paecilomyces variotii* in a
6917 renal transplant recipient. *Transpl Infect Dis* 2018; **20**(3): e12871.

6918 1933. Fagerburg R, Suh B, Buckley HR, Lorber B, Karian J. Cerebrospinal fluid shunt colonization and
6919 obstruction by *Paecilomyces variotii*. Case report. *J Neurosurg* 1981; **54**(2): 257-60.

6920 1934. Heshmatnia J, Marjani M, Mahdavian SA, et al. *Paecilomyces formosus* Infection in an Adult
6921 Patient with Undiagnosed Chronic Granulomatous Disease. *J Clin Immunol* 2017; **37**(4): 342-6.

6922 1935. Hirst LW, Choong K, Playford EG. Nontraumatic *paecilomyces* anterior segment infection: a
6923 pathognomonic clinical appearance. *Cornea* 2014; **33**(10): 1031-7.

6924 1936. Hsiue HC, Ruan SY, Kuo YL, Huang YT, Hsueh PR. Invasive infections caused by non-*Aspergillus*
6925 moulds identified by sequencing analysis at a tertiary care hospital in Taiwan, 2000-2008. *Clin Microbiol*
6926 *Infect* 2010; **16**(8): 1204-6.

6927 1937. Kalish SB, Goldschmidt R, Li C, et al. Infective endocarditis caused by *Paecilomyces varioti*. *Am J*
6928 *Clin Pathol* 1982; **78**(2): 249-52.

6929 1938. Kantarcioglu AS, Hatemi G, Yucel A, De Hoog GS, Mandel NM. *Paecilomyces variotii* central
6930 nervous system infection in a patient with cancer. *Mycoses* 2003; **46**(1-2): 45-50.

6931 1939. Kim JH, Williams K. Posaconazole salvage treatment for invasive fungal infection.
6932 *Mycopathologia* 2014; **178**(3-4): 259-65.

6933 1940. Korzets A, Weinberger M, Chagnac A, Goldschmied-Reouven A, Rinaldi MG, Sutton DA.
6934 Peritonitis due to *Thermoascus taitungiacus* (Anamorph *Paecilomyces taitungiacus*). *J Clin Microbiol*
6935 2001; **39**(2): 720-4.

6936 1941. Kovac D, Lindic J, Lejko-Zupanc T, et al. Treatment of severe *Paecilomyces varioti* peritonitis in a
6937 patient on continuous ambulatory peritoneal dialysis. *Nephrol Dial Transplant* 1998; **13**(11): 2943-6.

6938 1942. Kuboi T, Okazaki K, Inotani M, et al. A case of cutaneous *Paecilomyces formosus* infection in an
6939 extremely premature infant. *J Infect Chemother* 2016; **22**(5): 339-41.

6940 1943. Lam DS, Koehler AP, Fan DS, Cheuk W, Leung AT, Ng JS. Endogenous fungal endophthalmitis
6941 caused by *Paecilomyces variotii*. *Eye (Lond)* 1999; **13** (Pt 1): 113-6.

6942 1944. Lee J, Yew WW, Chiu CS, Wong PC, Wong CF, Wang EP. Delayed sternotomy wound infection
6943 due to *Paecilomyces variotii* in a lung transplant recipient. *J Heart Lung Transplant* 2002; **21**(10): 1131-4.

6944 1945. Liu K, Howell DN, Perfect JR, Schell WA. Morphologic criteria for the preliminary identification of
6945 *Fusarium*, *Paecilomyces*, and *Acremonium* species by histopathology. *Am J Clin Pathol* 1998; **109**(1): 45-
6946 54.

6947 1946. Mandarapu SB, Mukku KK, Raju SB, Chandragiri S. Successful catheter reinsertion in a case of
6948 *Paecilomyces varioti* peritonitis in a patient on continuous ambulatory peritoneal dialysis. *Indian J*
6949 *Nephrol* 2015; **25**(3): 177-9.

6950 1947. Marzec A, Heron LG, Pritchard RC, et al. *Paecilomyces variotii* in peritoneal dialysate. *J Clin*
6951 *Microbiol* 1993; **31**(9): 2392-5.

6952 1948. McClellan JR, Hamilton JD, Alexander JA, Wolfe WG, Reed JB. *Paecilomyces varioti* endocarditis
6953 on a prosthetic aortic valve. *J Thorac Cardiovasc Surg* 1976; **71**(3): 472-5.

6954 1949. Naidu J, Singh SM. Hyalohyphomycosis caused by *Paecilomyces variotii*: a case report, animal
6955 pathogenicity and 'in vitro' sensitivity. *Antonie Van Leeuwenhoek* 1992; **62**(3): 225-30.

6956 1950. Nankivell BJ, Pacey D, Gordon DL. Peritoneal eosinophilia associated with *Paecilomyces variotii*
6957 infection in continuous ambulatory peritoneal dialysis. *Am J Kidney Dis* 1991; **18**(5): 603-5.

6958 1951. Polat M, Kara SS, Tapisiz A, et al. Successful treatment of *Paecilomyces variotii* peritonitis in a
6959 liver transplant patient. *Mycopathologia* 2015; **179**(3-4): 317-20.

6960 1952. Rinaldi S, Fiscarelli E, Rizzoni G. *Paecilomyces variotii* peritonitis in an infant on automated
6961 peritoneal dialysis. *Pediatr Nephrol* 2000; **14**(5): 365-6.

6962 1953. Salle V, Lecuyer E, Chouaki T, et al. Paecilomyces variotii fungemia in a patient with multiple
6963 myeloma: case report and literature review. *J Infect* 2005; **51**(3): e93-5.

6964 1954. Sanchez Yepes M, Maiquez Richard J, San Juan Gadea MC. [Lung infection by Paecilomyces
6965 variotii in a patient with breast cancer]. *Med Clin (Barc)* 2007; **129**(11): 438.

6966 1955. Senior JM, Saldarriaga C. [Endocarditis due to infection by Paecilomyces variotii]. *Biomedica*
6967 2009; **29**(2): 177-80.

6968 1956. Sherwood JA, Dansky AS. Paecilomyces pyelonephritis complicating nephrolithiasis and review
6969 of Paecilomyces infections. *J Urol* 1983; **130**(3): 526-8.

6970 1957. Shing MM, Ip M, Li CK, Chik KW, Yuen PM. Paecilomyces varioti fungemia in a bone marrow
6971 transplant patient. *Bone Marrow Transplant* 1996; **17**(2): 281-3.

6972 1958. Silver MD, Tuffnell PG, Bigelow WG. Endocarditis caused by Paecilomyces varioti affecting an
6973 aortic valve allograft. *J Thorac Cardiovasc Surg* 1971; **61**(2): 278-81.

6974 1959. Sriram K, Mathews MS, Gopalakrishnan G. Paecilomyces pyelonephritis in a patient with
6975 urolithiasis. *Indian J Urol* 2007; **23**(2): 195-7.

6976 1960. Steiner B, Aquino VR, Paz AA, Silla LM, Zavascki A, Goldani LZ. Paecilomyces variotii as an
6977 Emergent Pathogenic Agent of Pneumonia. *Case Rep Infect Dis* 2013; **2013**: 273848.

6978 1961. Swami T, Pannu S, Kumar M, Gupta G. Chronic invasive fungal rhinosinusitis by Paecilomyces
6979 variotii: A rare case report. *Indian J Med Microbiol* 2016; **34**(1): 103-6.

6980 1962. Tarkkanen A, Raivio V, Anttila VJ, et al. Fungal endophthalmitis caused by Paecilomyces variotii
6981 following cataract surgery: a presumed operating room air-conditioning system contamination. *Acta*
6982 *Ophthalmol Scand* 2004; **82**(2): 232-5.

6983 1963. Thompson RF, Bode RB, Rhodes JC, Gluckman JL. Paecilomyces variotii. An unusual cause of
6984 isolated sphenoid sinusitis. *Arch Otolaryngol Head Neck Surg* 1988; **114**(5): 567-9.

6985 1964. Torres R, Gonzalez M, Sanhueza M, et al. Outbreak of Paecilomyces variotii peritonitis in
6986 peritoneal dialysis patients after the 2010 Chilean earthquake. *Perit Dial Int* 2014; **34**(3): 322-5.

6987 1965. Uzunoglu E, Sahin AM. Paecilomyces variotii peritonitis in a patient on continuous ambulatory
6988 peritoneal dialysis. *J Mycol Med* 2017; **27**(2): 277-80.

6989 1966. Vasudevan B, Hazra N, Verma R, Srinivas V, Vijendran P, Badad A. First reported case of
6990 subcutaneous hyalohyphomycosis caused by Paecilomyces variotii. *Int J Dermatol* 2013; **52**(6): 711-3.

6991 1967. Wang SM, Shieh CC, Liu CC. Successful treatment of Paecilomyces variotii splenic abscesses: a
6992 rare complication in a previously unrecognized chronic granulomatous disease child. *Diagn Microbiol*
6993 *Infect Dis* 2005; **53**(2): 149-52.

6994 1968. Williamson PR, Kwon-Chung KJ, Gallin JI. Successful treatment of Paecilomyces varioti infection
6995 in a patient with chronic granulomatous disease and a review of Paecilomyces species infections. *Clin*
6996 *Infect Dis* 1992; **14**(5): 1023-6.

6997 1969. Wright K, Popli S, Gandhi VC, Lentino JR, Reyes CV, Leehey DJ. Paecilomyces peritonitis: case
6998 report and review of the literature. *Clin Nephrol* 2003; **59**(4): 305-10.

6999 1970. Houbraken J, Verweij PE, Rijs AJ, Borman AM, Samson RA. Identification of Paecilomyces variotii
7000 in clinical samples and settings. *J Clin Microbiol* 2010; **48**(8): 2754-61.

7001 1971. Innocenti P, Pagani E, Vigl D, Hopfl R, Huemer HP, Larcher C. Persisting Paecilomyces lilacinus
7002 nail infection following pregnancy. *Mycoses* 2011; **54**(6): e880-2.

7003 1972. Antas PR, Brito MM, Peixoto E, Ponte CG, Borba CM. Neglected and emerging fungal infections:
7004 review of hyalohyphomycosis by Paecilomyces lilacinus focusing in disease burden, in vitro antifungal
7005 susceptibility and management. *Microbes Infect* 2012; **14**(1): 1-8.

7006 1973. Narita A, Seguchi J, Shiraga F. Paecilomyces lilacinus-induced Scleritis Following Bleb-associated
7007 Endophthalmitis after Trabeculectomy. *Acta Med Okayama* 2015; **69**(5): 313-8.

7008 1974. Castelli MV, Alastruey-Izquierdo A, Cuesta I, et al. Susceptibility testing and molecular
7009 classification of Paecilomyces spp. *Antimicrobial agents and chemotherapy* 2008; **52**(8): 2926-8.

7010 1975. Nagamoto E, Fujisawa A, Yoshino Y, et al. Case of Paecilomyces lilacinus infection occurring in
7011 necrotizing fasciitis-associated skin ulcers on the face and surrounding a tracheotomy stoma. *Med Mycol*
7012 *J* 2014; **55**(1): E21-7.

7013 1976. Todokoro D, Yamada N, Fukuchi M, Kishi S. Topical voriconazole therapy of Purpureocillium
7014 lilacinum keratitis that occurred in disposable soft contact lens wearers. *Int Ophthalmol* 2014; **34**(5):
7015 1159-63.

7016 1977. Marques DP, Carvalho J, Rocha S, Domingos R. A Case of Pulmonary Mycetoma Caused by
7017 Paecilomyces variotii. *Eur J Case Rep Intern Med* 2019; **6**(2): 001040.

7018 1978. Samson RA. Paecilomyces and some allied hyphomycetes. *Stud Mycol* 1974; **6**: 1-119.

7019 1979. Eren D, Eroglu E. Cutaneous ulcerations caused by Paecilomyces variotii in a renal transplant
7020 recipient. 2018; **20**(3): e12871.

7021 1980. Lamoth F, Kontoyiannis DP. Therapeutic Challenges of Non-Aspergillus Invasive Mold Infections
7022 in Immunosuppressed Patients. 2019; **63**(11).

7023 1981. Jacobs H, Gray SN, Crump DH. Interactions between nematophagous fungi and consequences
7024 for their potential as biological agents for the control of potato cyst nematodes. *Mycol Res* 2003; **107**(Pt
7025 1): 47-56.

7026 1982. Ali-Shtayeh MS, Khaleel T, Jamous RM. Ecology of dermatophytes and other keratinophilic fungi
7027 in swimming pools and polluted and unpolluted streams. *Mycopathologia* 2002; **156**(3): 193-205.

7028 1983. Pastor FJ, Guarro J. Clinical manifestations, treatment and outcome of Paecilomyces lilacinus
7029 infections. *Clin Microbiol Infect* 2006; **12**(10): 948-60.

7030 1984. Yuan X, Wilhelmus KR, Matoba AY, Alexandrakis G, Miller D, Huang AJ. Pathogenesis and
7031 outcome of Paecilomyces keratitis. *Am J Ophthalmol* 2009; **147**(4): 691-6 e3.

7032 1985. Yildiz EH, Ailani H, Hammersmith KM, Eagle RC, Jr., Rapuano CJ, Cohen EJ. Alternaria and
7033 paecilomyces keratitis associated with soft contact lens wear. *Cornea* 2010; **29**(5): 564-8.

7034 1986. Deng SX, Kamal KM, Hollander DA. The use of voriconazole in the management of post-
7035 penetrating keratoplasty Paecilomyces keratitis. *J Ocul Pharmacol Ther* 2009; **25**(2): 175-7.

7036 1987. Ono N, Sato K, Yokomise H, Tamura K. Lung abscess caused by Paecilomyces lilacinus.
7037 *Respiration* 1999; **66**(1): 85-7.

7038 1988. Keshtkar-Jahromi M, McTighe AH, Segalman KA, Fothergill AW, Campbell WN. Unusual case of
7039 cutaneous and synovial Paecilomyces lilacinus infection of hand successfully treated with voriconazole
7040 and review of published literature. *Mycopathologia* 2012; **174**(3): 255-8.

7041 1989. Silliman CC, Lawellin DW, Lohr JA, Rodgers BM, Donowitz LG. Paecilomyces lilacinus infection in
7042 a child with chronic granulomatous disease. *J Infect* 1992; **24**(2): 191-5.

7043 1990. Chang BP, Sun PL, Huang FY, et al. Paecilomyces lilacinus peritonitis complicating peritoneal
7044 dialysis cured by oral voriconazole and terbinafine combination therapy. *J Med Microbiol* 2008; **57**(Pt
7045 12): 1581-4.

7046 1991. Chan-Tack KM, Thio CL, Miller NS, Karp CL, Ho C, Merz WG. Paecilomyces lilacinus fungemia in
7047 an adult bone marrow transplant recipient. *Medical mycology* 1999; **37**(1): 57-60.

7048 1992. Labriola L, V B, Ercam, Swinne D, Jadoul M. Successful treatment with voriconazole of prolonged
7049 Paecilomyces lilacinus fungemia in a chronic hemodialyzed patient. *Clin Nephrol* 2009; **71**(3): 355-8.

7050 1993. Heinz T, Perfect J, Schell W, Ritter E, Ruff G, Serafin D. Soft-tissue fungal infections: surgical
7051 management of 12 immunocompromised patients. *Plast Reconstr Surg* 1996; **97**(7): 1391-9.

7052 1994. Martin CA, Roberts S, Greenberg RN. Voriconazole treatment of disseminated paecilomyces
7053 infection in a patient with acquired immunodeficiency syndrome. *Clin Infect Dis* 2002; **35**(7): e78-81.

7054 1995. Ding CH, Tzar MN, Rahman MM, Muttaqillah NA, Redzuan SR, Periyasamy P. Paecilomyces
7055 lilacinus fungaemia in an AIDS patient: the importance of mycological diagnosis. *Pak J Med Sci* 2014;
7056 **30**(4): 914-6.

7057 1996. Agrawal PK, Lal B, Wahab S, Srivastava OP, Misra SC. Orbital paecilomycosis due to Paecilomyces
7058 lilacinus (Thom) Samson. *Sabouraudia* 1979; **17**(4): 363-70.

7059 1997. Almeida Oliveira M, Carmo A, Rosa A, Murta J. Posaconazole in the treatment of refractory
7060 Purpureocillium lilacinum (former Paecilomyces lilacinus) keratitis: the salvation when nothing works.
7061 *BMJ Case Rep* 2019; **12**(4).

7062 1998. Anderson KL, Mitra S, Salouti R, Pham TA, Taylor HR. Fungal keratitis caused by Paecilomyces
7063 lilacinus associated with a retained intracorneal hair. *Cornea* 2004; **23**(5): 516-21.

7064 1999. Arnoldner MA, Kheirkhah A, Jakobiec FA, Durand ML, Hamrah P. Successful treatment of
7065 Paecilomyces lilacinus keratitis with oral posaconazole. *Cornea* 2014; **33**(7): 747-9.

7066 2000. Bassiri-Jahromi S. Cutaneous Paecilomyces lilacinus infections in immunocompromised and
7067 immunocompetent patients. *Indian J Dermatol Venereol Leprol* 2014; **80**(4): 331-4.

7068 2001. Blackwell V, Ahmed K, O'Docherty C, Hay RJ. Cutaneous hyalohyphomycosis caused by
7069 Paecilomyces lilacinus in a renal transplant patient. *Br J Dermatol* 2000; **143**(4): 873-5.

7070 2002. Carey J, D'Amico R, Sutton DA, Rinaldi MG. Paecilomyces lilacinus vaginitis in an immuno-
7071 competent patient. *Emerg Infect Dis* 2003; **9**(9): 1155-8.

7072 2003. Castro LG. Cutaneous Paecilomyces lilacinus infection. *Journal of the American Academy of*
7073 *Dermatology* 1998; **39**(3): 516-7.

7074 2004. Castro LG, Salebian A, Sotto MN. Hyalohyphomycosis by Paecilomyces lilacinus in a renal
7075 transplant patient and a review of human Paecilomyces species infections. *J Med Vet Mycol* 1990; **28**(1):
7076 15-26.

7077 2005. Chen WY, Lin SR, Hung SJ. Successful Treatment of Recurrent Cutaneous Purpureocillium
7078 lilacinum (Paecilomyces lilacinus) Infection with Posaconazole and Surgical Debridement. *Acta Derm*
7079 *Venereol* 2019.

7080 2006. Chung PC, Lin HC, Hwang YS, et al. Paecilomyces lilacinus scleritis with secondary keratitis.
7081 *Cornea* 2007; **26**(2): 232-4.

7082 2007. Cieccko SC, Scher R. Invasive fungal rhinitis caused by Paecilomyces lilacinus infection: Report of
7083 a case and a novel treatment. *Ear, nose, & throat journal* 2010; **89**(12): 594-5.

7084 2008. Clark NM. Paecilomyces lilacinus infection in a heart transplant recipient and successful
7085 treatment with terbinafine. *Clin Infect Dis* 1999; **28**(5): 1169-70.

7086 2009. Demitsu T, Nagashima K, Okabe T, et al. Subcutaneous hyalohyphomycosis due to
7087 Purpureocillium lilacinum in an immunocompromised patient after renal transplantation. *J Dermatol*
7088 2017; **44**(6): 725-6.

7089 2010. Diven DG, Newton RC, Sang JL, Beightler EL, McGinnis MR, Macdonald-Davidson E. Cutaneous
7090 hyalohyphomycosis caused by Paecilomyces lilacinus in a patient with lymphoma. *Journal of the*
7091 *American Academy of Dermatology* 1996; **35**(5 Pt 1): 779-81.

7092 2011. Domniz Y, Lawless M, Sutton GL, Rogers CM, Meagher LJ. Successful treatment of Paecilomyces
7093 lilacinus endophthalmitis after foreign body trauma to the cornea. *Cornea* 2001; **20**(1): 109-11.

7094 2012. Ezzedine K, Belin E, Guillet S, et al. Cutaneous hyphomycosis due to Paecilomyces lilacinus. *Acta*
7095 *Derm Venereol* 2012; **92**(2): 156-7.

7096 2013. Ford JG, Agee S, Greenhaw ST. Successful medical treatment of a case of Paecilomyces lilacinus
7097 keratitis. *Cornea* 2008; **27**(9): 1077-9.

7098 2014. Garbino J, Ondrusova A, Baglivo E, Lew D, Bouchuiguir-Wafa K, Rohner P. Successful treatment
7099 of Paecilomyces lilacinus endophthalmitis with voriconazole. *Scand J Infect Dis* 2002; **34**(9): 701-3.

7100 2015. Gordon MA, Norton SW. Corneal transplant infection by Paecilomyces lilacinus. *Sabouraudia*
7101 1985; **23**(4): 295-301.

7102 2016. Gottlieb T, Atkins BL. Case report. Successful treatment of cutaneous Paecilomyces lilacinus
7103 infection with oral itraconazole in an immune competent host. *Mycoses* 2001; **44**(11-12): 513-5.

7104 2017. Gracitelli CPB, Ferrar PV, Pereira CAP, Hirai FE, Freitas D. A case of recurrent keratitis caused by
7105 Paecilomyces lilacinus and treated by voriconazole. *Arq Bras Oftalmol* 2019; **82**(2): 152-4.

7106 2018. Gucalp R, Carlisle P, Gialanella P, Mitsudo S, McKittrick J, Dutcher J. Paecilomyces sinusitis in an
7107 immunocompromised adult patient: case report and review. *Clin Infect Dis* 1996; **23**(2): 391-3.

7108 2019. Guo LN, Wang H, Hsueh PR, Meis JF, Chen H, Xu YC. Endophthalmitis caused by Purpureocillium
7109 lilacinum. *J Microbiol Immunol Infect* 2019; **52**(1): 170-1.

7110 2020. Gupta A, Srinivasan R, Kaliaperumal S, Saha I. Post-traumatic fungal endophthalmitis--a
7111 prospective study. *Eye (Lond)* 2008; **22**(1): 13-7.

7112 2021. Gutierrez-Rodero F, Moragon M, Ortiz de la Tabla V, Mayol MJ, Martin C. Cutaneous
7113 hyalohyphomycosis caused by Paecilomyces lilacinus in an immunocompetent host successfully treated
7114 with itraconazole: case report and review. *Eur J Clin Microbiol Infect Dis* 1999; **18**(11): 814-8.

7115 2022. Hall VC, Goyal S, Davis MD, Walsh JS. Cutaneous hyalohyphomycosis caused by *Paecilomyces*
7116 *lilacinus*: report of three cases and review of the literature. *Int J Dermatol* 2004; **43**(9): 648-53.

7117 2023. Heard DJ, Cantor GH, Jacobson ER, Purich B, Ajello L, Padhye AA. Hyalohyphomycosis caused by
7118 *Paecilomyces lilacinus* in an Aldabra tortoise. *J Am Vet Med Assoc* 1986; **189**(9): 1143-5.

7119 2024. Hecker MS, Weinberg JM, Bagheri B, et al. Cutaneous *Paecilomyces lilacinus* infection: report of
7120 two novel cases. *Journal of the American Academy of Dermatology* 1997; **37**(2 Pt 1): 270-1.

7121 2025. Hilmarsdottir I, Thorsteinsson SB, Asmundsson P, Bodvarsson M, Arnadottir M. Cutaneous
7122 infection caused by *Paecilomyces lilacinus* in a renal transplant patient: treatment with voriconazole.
7123 *Scand J Infect Dis* 2000; **32**(3): 331-2.

7124 2026. Huang CY, Sun PL, Tseng HK. Cutaneous hyalohyphomycosis caused by *Paecilomyces lilacinus*
7125 successfully treated by oral voriconazole and nystatin packing. *Mycopathologia* 2011; **172**(2): 141-5.

7126 2027. Jackson ST, Smikle MF, Antoine MG, Roberts GD. *Paecilomyces lilacinus* fungemia in a Jamaican
7127 neonate. *West Indian Med J* 2006; **55**(5): 361.

7128 2028. Jade KB, Lyons MF, Gnann JW, Jr. *Paecilomyces lilacinus* cellulitis in an immunocompromised
7129 patient. *Arch Dermatol* 1986; **122**(10): 1169-70.

7130 2029. Juyal D, Pal S, Sharma M, Negi V, Adekhandi S, Tyagi M. Keratomycosis due to *Purpureocillium*
7131 *lilacinum*: A case report from Sub-Himalayan region of Uttarakhand. *Indian J Pathol Microbiol* 2018;
7132 **61**(4): 607-9.

7133 2030. Khalique Z, Hatipoglu S, Rosendahl U, Mohiaddin R. Unusual Complicated Fungal Endocarditis in
7134 a Patient With Vascular Ehlers-Danlos Syndrome. *Ann Thorac Surg* 2019; **107**(4): e269-e71.

7135 2031. Khan Z, Ahmad S, Al-Ghimlas F, et al. *Purpureocillium lilacinum* as a cause of cavitary pulmonary
7136 disease: a new clinical presentation and observations on atypical morphologic characteristics of the
7137 isolate. *J Clin Microbiol* 2012; **50**(5): 1800-4.

7138 2032. Kitami Y, Kagawa S, Iijima M. [A case of cutaneous *Paecilomyces lilacinus* infection on the face].
7139 *Nihon Ishinkin Gakkai Zasshi* 2005; **46**(4): 267-72.

7140 2033. Kozarsky AM, Stulting RD, Waring GO, 3rd, Cornell FM, Wilson LA, Cavanagh HD. Penetrating
7141 keratoplasty for exogenous *Paecilomyces* keratitis followed by postoperative endophthalmitis. *Am J*
7142 *Ophthalmol* 1984; **98**(5): 552-7.

7143 2034. Kurzai O, Vaeth T, Hamelmann W, et al. Combined surgical and antifungal treatment of a
7144 subcutaneous infection due to *Paecilomyces lilacinus*. *Medical mycology* 2003; **41**(3): 253-8.

7145 2035. Lau N, Hajjar Sese A, Augustin VA, et al. Fungal infection after endothelial keratoplasty:
7146 association with hypothermic corneal storage. *Br J Ophthalmol* 2019; **103**(10): 1487-90.

7147 2036. Legeais JM, Blanc V, Basset D, et al. [Severe keratomycosis. Diagnosis and treatment]. *J Fr*
7148 *Ophthalmol* 1994; **17**(10): 568-73.

7149 2037. Levin PS, Beebe WE, Abbott RL. Successful treatment of *Paecilomyces lilacinus* endophthalmitis
7150 following cataract extraction with intraocular lens implantation. *Ophthalmic Surg* 1987; **18**(3): 217-9.

7151 2038. Lin WL, Lin WC, Chiu CS. *Paecilomyces lilacinus* cutaneous infection associated with peripherally
7152 inserted central catheter insertion. *J Eur Acad Dermatol Venereol* 2008; **22**(10): 1267-8.

7153 2039. Lopez-Medrano R, Perez Madera A, Fuster Foz C. [Eye infections caused by *Purpureocillium*
7154 *lilacinum*: A case report and literature review]. *Rev Iberoam Micol* 2015; **32**(2): 111-4.

7155 2040. Lott ME, Sheehan DJ, Davis LS. *Paecilomyces lilacinus* infection with a sporotrichoid pattern in a
7156 renal transplant patient. *J Drugs Dermatol* 2007; **6**(4): 436-9.

7157 2041. Lovell RD, Moll M, Allen J, Cicci LG. Disseminated *Paecilomyces lilacinus* infection in a patient
7158 with AIDS. *AIDS Read* 2002; **12**(5): 212-3, 8, 21.

7159 2042. Maier AK, Reichenbach A, Rieck P. [*Paecilomyces lilacinus* keratitis]. *Ophthalmologe* 2011;
7160 **108**(10): 966-8.

7161 2043. Malecha MA, Tarigopula S, Malecha MJ. Successful treatment of *Paecilomyces lilacinus* keratitis
7162 in a patient with a history of herpes simplex virus keratitis. *Cornea* 2006; **25**(10): 1240-2.

7163 2044. Marangon FB, Miller D, Giacconi JA, Alfonso EC. In vitro investigation of voriconazole
7164 susceptibility for keratitis and endophthalmitis fungal pathogens. *Am J Ophthalmol* 2004; **137**(5): 820-5.

7165 2045. Marchese SM, Smoller BR. Cutaneous *Paecilomyces lilacinus* infection in a hospitalized patient
7166 taking corticosteroids. *Int J Dermatol* 1998; **37**(6): 438-41.

7167 2046. McIntock CA, Lee GA, Atkinson G. Management of recurrent Paecilomyces lilacinus keratitis.
7168 *Clinical & experimental optometry* 2013; **96**(3): 343-5.

7169 2047. Mihailovic N, Alnawaiseh M, Zumhagen L, Eter N. [Contact lens-associated Paecilomyces
7170 lilacinus keratitis]. *Ophthalmologe* 2017; **114**(1): 57-9.

7171 2048. Miller GR, Rebell G, Magoon RC, Kulvin SM, Forster RK. Intravitreal antimycotic therapy and the
7172 cure of mycotic endophthalmitis caused by a Paecilomyces lilacinus contaminated pseudophakos.
7173 *Ophthalmic Surg* 1978; **9**(6): 54-63.

7174 2049. Minogue MJ, Francis IC, Quatermass P, et al. Successful treatment of fungal keratitis caused by
7175 Paecilomyces lilacinus. *Am J Ophthalmol* 1984; **98**(5): 626-7.

7176 2050. Monden Y, Sugita M, Yamakawa R, Nishimura K. Clinical experience treating Paecilomyces
7177 lilacinus keratitis in four patients. *Clin Ophthalmol* 2012; **6**: 949-53.

7178 2051. Monno R, Alessio G, Guerriero S, et al. Paecilomyces lilacinus Keratitis in a Soft Contact Lens
7179 Wearer. *Eye Contact Lens* 2018; **44 Suppl 1**: S337-S40.

7180 2052. Mosier MA, Lusk B, Pettit TH, Howard DH, Rhodes J. Fungal endophthalmitis following
7181 intraocular lens implantation. *Am J Ophthalmol* 1977; **83**(1): 1-8.

7182 2053. Mullane K, Toor AA, Kalnicky C, Rodriguez T, Klein J, Stiff P. Posaconazole salvage therapy allows
7183 successful allogeneic hematopoietic stem cell transplantation in patients with refractory invasive mold
7184 infections. *Transpl Infect Dis* 2007; **9**(2): 89-96.

7185 2054. Muller H, Cikirikcioglu M, Lerch R. Subaortic aneurysm caused by Paecilomyces lilacinus
7186 endocarditis. *Arch Cardiovasc Dis* 2008; **101**(11-12): 803-4.

7187 2055. Murciano A, Domer J, Cohen I. Paecilomyces lilacinus infection in an immunocompromised
7188 patient. *J La State Med Soc* 1990; **142**(12): 35-7.

7189 2056. Naik AU, Gadewar SB. Paecilomyces Keratitis in Western India: A Case Report. *J Clin Diagn Res*
7190 2017; **11**(2): ND01-ND2.

7191 2057. Nayak DR, Balakrishnan R, Nainani S, Siddique S. Paecilomyces fungus infection of the paranasal
7192 sinuses. *Int J Pediatr Otorhinolaryngol* 2000; **52**(2): 183-7.

7193 2058. O'Day DM. Fungal endophthalmitis caused by Paecilomyces lilacinus after intraocular lens
7194 implantation. *Am J Ophthalmol* 1977; **83**(1): 130-1.

7195 2059. Ohkubo S, Torisaki M, Higashide T, Mochizuki K, Ishibashi Y. [Endophthalmitis caused by
7196 Paecilomyces lilacinus after cataract surgery: a case report]. *Nippon Ganka Gakkai Zasshi* 1994; **98**(1):
7197 103-10.

7198 2060. Okhravi N, Dart JK, Towler HM, Lightman S. Paecilomyces lilacinus endophthalmitis with
7199 secondary keratitis: a case report and literature review. *Arch Ophthalmol* 1997; **115**(10): 1320-4.

7200 2061. Okhravi N, Lightman S. Clinical manifestations, treatment and outcome of Paecilomyces lilacinus
7201 infections. *Clin Microbiol Infect* 2007; **13**(5): 554.

7202 2062. Orth B, Frei R, Itin PH, et al. Outbreak of invasive mycoses caused by Paecilomyces lilacinus from
7203 a contaminated skin lotion. *Ann Intern Med* 1996; **125**(10): 799-806.

7204 2063. Ounissi M, Abderrahim E, Trabelsi S, et al. Hyalohyphomycosis caused by Paecilomyces lilacinus
7205 after kidney transplantation. *Transplant Proc* 2009; **41**(7): 2917-9.

7206 2064. Permi HS, Sunil KY, Karnaker VK, Kishan PH, Teerthanath S, Bhandary SK. A Rare Case of Fungal
7207 Maxillary Sinusitis due to Paecilomyces lilacinus in an Immunocompetent Host, Presenting as a
7208 Subcutaneous Swelling. *J Lab Physicians* 2011; **3**(1): 46-8.

7209 2065. Pettit TH, Olson RJ, Foos RY, Martin WJ. Fungal endophthalmitis following intraocular lens
7210 implantation. A surgical epidemic. *Arch Ophthalmol* 1980; **98**(6): 1025-39.

7211 2066. Pinto E, Lago M, Branco L, Vale-Silva LA, Pinheiro MD. Evaluation of Etest performed in Mueller-
7212 Hinton agar supplemented with glucose for antifungal susceptibility testing of clinical isolates of
7213 filamentous fungi. *Mycopathologia* 2014; **177**(3-4): 157-66.

7214 2067. Pintor E, Martin M, Garcia P, Gonzalez M. [Endophthalmitis due to Paecilomyces lilacinus after
7215 non-surgical penetrating trauma]. *Enferm Infecc Microbiol Clin* 2001; **19**(7): 347-8.

7216 2068. Raghavan R, Chithra G, Fernandez S, Shamana Suryanarayana B, Singh R. An unusual case of
7217 hyalohyphomycosis due to Purpureocillium lilacinum in a patient with myasthenia gravis. *Curr Med*
7218 *Mycol* 2018; **4**(2): 36-9.

7219 2069. Rimawi RH, Carter Y, Ware T, Christie J, Siraj D. Use of voriconazole for the treatment of
7220 Paecilomyces lilacinus cutaneous infections: case presentation and review of published literature.
7221 *Mycopathologia* 2013; **175**(3-4): 345-9.

7222 2070. Rockhill RC, Klein MD. Paecilomyces lilacinus as the cause of chronic maxillary sinusitis. *J Clin*
7223 *Microbiol* 1980; **11**(6): 737-9.

7224 2071. Roque J, Navarro M, Toro G, Gonzalez I, Pimstein M, Venegas E. [Paecilomyces lilacinus systemic
7225 infection in an immunocompromised child]. *Rev Med Chil* 2003; **131**(1): 77-80.

7226 2072. Rosmaninho A, Torres T, Velho G, Lopes V, Amorim I, Selores M. Paecilomyces lilacinus in
7227 transplant patients: an emerging infection. *Eur J Dermatol* 2010; **20**(5): 643-4.

7228 2073. Saghrouni F, Saidi W, Ben Said Z, et al. Cutaneous hyalohyphomycosis caused by Purpureocillium
7229 lilacinum in an immunocompetent patient: case report and review. *Medical mycology* 2013; **51**(6): 664-
7230 8.

7231 2074. Schweitzer KM, Jr., Richard MJ, Leversedge FJ, Ruch DS. Paecilomyces lilacinus septic olecranon
7232 bursitis in an immunocompetent host. *American journal of orthopedics (Belle Mead, NJ)* 2012; **41**(5):
7233 E74-5.

7234 2075. Scott IU, Flynn HW, Jr., Miller D, Speights JW, Snip RC, Brod RD. Exogenous endophthalmitis
7235 caused by amphotericin B-resistant Paecilomyces lilacinus: treatment options and visual outcomes. *Arch*
7236 *Ophthalmol* 2001; **119**(6): 916-9.

7237 2076. Sharma V, Angrup A, Panwar P, Verma S, Singh D, Kanga A. Keratitis by Paecilomyces lilacinus: A
7238 case report from Sub-Himalayan region. *Indian J Med Microbiol* 2015; **33**(4): 585-7.

7239 2077. Shivaprasad A, Ravi GC, Shivapriya, Rama. A Rare Case of Nasal Septal Perforation Due to
7240 Purpureocillium lilacinum: Case Report and Review. *Indian J Otolaryngol Head Neck Surg* 2013; **65**(2):
7241 184-8.

7242 2078. Simmons SC, Budavari AI, Kusne S, Zhang N, Vikram HR, Blair JE. Culture-Proven Thorn-
7243 Associated Infections in Arizona: 10-Year Experience at Mayo Clinic. *Open Forum Infect Dis* 2017; **4**(1):
7244 ofx017.

7245 2079. Sotello D, Cappel M, Huff T, Meza D, Alvarez S, Libertin CR. Cutaneous fungal infection in an
7246 immunocompromised host. *JMM Case Rep* 2017; **4**(6): e005101.

7247 2080. Sponsel W, Chen N, Dang D, et al. Topical voriconazole as a novel treatment for fungal keratitis.
7248 *Antimicrob Agents Chemother* 2006; **50**(1): 262-8.

7249 2081. Starr MB. Paecilomyces lilacinus keratitis: two case reports in extended wear contact lens
7250 wearers. *CLAO J* 1987; **13**(2): 95-101.

7251 2082. Takayasu S, Akagi M, Shimizu Y. Cutaneous mycosis caused by Paecilomyces lilacinus. *Arch*
7252 *Dermatol* 1977; **113**(12): 1687-90.

7253 2083. Tan TQ, Ogden AK, Tillman J, Demmler GJ, Rinaldi MG. Paecilomyces lilacinus catheter-related
7254 fungemia in an immunocompromised pediatric patient. *J Clin Microbiol* 1992; **30**(9): 2479-83.

7255 2084. Trachsler S, Eberhard R, Kocher C, Fleischhauer J. Paecilomyces lilacinus endophthalmitis
7256 following cataract surgery: a therapeutic challenge. *Klin Monbl Augenheilkd* 2012; **229**(4): 441-2.

7257 2085. Trinh SA, Angarone MP. Purpureocillium lilacinum tattoo-related skin infection in a kidney
7258 transplant recipient. *Transpl Infect Dis* 2017; **19**(3).

7259 2086. Turner LD, Conrad D. Retrospective case-series of Paecilomyces lilacinus ocular mycoses in
7260 Queensland, Australia. *BMC research notes* 2015; **8**: 627.

7261 2087. Van Schooneveld T, Freifeld A, Lesiak B, Kalil A, Sutton DA, Iwen PC. Paecilomyces lilacinus
7262 infection in a liver transplant patient: case report and review of the literature. *Transpl Infect Dis* 2008;
7263 **10**(2): 117-22.

7264 2088. Volna F, Maderova E. [Paecilomyces lilacinus--sensitivity to disinfectants]. *Cesk Epidemiol*
7265 *Mikrobiol Imunol* 1990; **39**(5): 315-7.

7266 2089. Wessolossky M, Haran JP, Bagchi K. Paecilomyces lilacinus olecranon bursitis in an
7267 immunocompromised host: case report and review. *Diagn Microbiol Infect Dis* 2008; **61**(3): 354-7.

7268 2090. Westenfeld F, Alston WK, Winn WC. Complicated soft tissue infection with prepatellar bursitis
7269 caused by Paecilomyces lilacinus in an immunocompetent host: case report and review. *J Clin Microbiol*
7270 1996; **34**(6): 1559-62.

7271 2091. Wilhelmus KR, Robinson NM, Font RA, Hamill MB, Jones DB. Fungal keratitis in contact lens
7272 wearers. *Am J Ophthalmol* 1988; **106**(6): 708-14.

7273 2092. Wolley M, Collins J, Thomas M. Paecilomyces lilacinus peritonitis in a peritoneal dialysis patient.
7274 *Perit Dial Int* 2012; **32**(3): 364-5.

7275 2093. Wong G, Nash R, Barai K, Rathod R, Singh A. Paecilomyces lilacinus causing debilitating sinusitis
7276 in an immunocompetent patient: a case report. *J Med Case Rep* 2012; **6**: 86.

7277 2094. Wu PC, Lai CH, Tan HY, Ma DH, Hsiao CH. The successful medical treatment of a case of
7278 Paecilomyces lilacinus keratitis. *Cornea* 2010; **29**(3): 357-8.

7279 2095. Yoshida M, Yokokura S, Kunikata H, et al. Endophthalmitis associated with Purpureocillium
7280 lilacinum during infliximab treatment for surgically induced necrotizing scleritis, successfully treated
7281 with 27-gauge vitrectomy. *Int Ophthalmol* 2018; **38**(2): 841-7.

7282 2096. Zendri E, Martignoni G, Benecchi M, Fanti F, De Panfilis G. Paecilomyces lilacinus cutaneous
7283 infection associated with a dog bite. *Journal of the American Academy of Dermatology* 2006; **55**(2
7284 Suppl): S63-4.

7285 2097. Zhou HY, Ye JJ, Chen YY, Dong FT. [Research on the surgery treatment and etiology of fungal
7286 endophthalmitis]. *Zhonghua Yan Ke Za Zhi* 2018; **54**(4): 270-6.

7287 2098. Hobson S, Epelbaum O, Leytin, Md A. Paecilomyces lilacinus Pneumonia in a
7288 Neutropenic Patient; An Emerging Threat? *CHEST* 2013; **144**(4): 248A.

7289 2099. Huang C-Y, Sun P-L, Tseng H-K. Cutaneous hyalohyphomycosis caused by Paecilomyces lilacinus
7290 successfully treated by oral voriconazole and nystatin packing. *Mycopathologia* 2011; **172**(2): 141-5.

7291 2100. Hilmarsdóttir I, Thorsteinsson SB, Asmundsson P, Bödvarsson M, Arnadóttir M. Cutaneous
7292 infection caused by Paecilomyces lilacinus in a renal transplant patient: treatment with voriconazole.
7293 *Scandinavian journal of infectious diseases* 2000; **32**(3): 331-2.

7294 2101. Ounissi M, Abderrahim E, Trabelsi S, et al. Hyalohyphomycosis caused by Paecilomyces lilacinus
7295 after kidney transplantation. *Transplantation proceedings* 2009; **41**(7): 2917-9.

7296 2102. Walsh TJ, Groll AH. Emerging fungal pathogens: evolving challenges to immunocompromised
7297 patients for the twenty-first century. *Transplant infectious disease : an official journal of the*
7298 *Transplantation Society* 1999; **1**(4): 247-61.

7299 2103. Chew R, Dorman A, Woods ML. Purpureocillium lilacinum keratitis: a case series and review of
7300 the literature. *Can J Ophthalmol* 2016; **51**(5): 382-5.

7301 2104. Almeida Oliveira M, Carmo A, Rosa A, Murta J. Posaconazole in the treatment of refractory
7302 Purpureocillium lilacinum (former Paecilomyces lilacinus) keratitis: the salvation when nothing works.
7303 *BMJ Case Rep* 2019; **12**(4): e228645.

7304 2105. Wu P-C, Lai C-H, Tan H-Y, Ma DHK, Hsiao C-H. The successful medical treatment of a case of
7305 Paecilomyces lilacinus keratitis. *Cornea* 2010; **29**(3): 357-8.

7306 2106. Juyal D, Pal S, Sharma M, Negi V, Adekhandi S, Tyagi M. Keratomycosis due to Purpureocillium
7307 lilacinum: A case report from Sub-Himalayan region of Uttarakhand. *Indian J Pathol Microbiol* 2018;
7308 **61**(4): 607-9.

7309 2107. Trachsler S, Eberhard R, Kocher C, Fleischhauer J. Paecilomyces lilacinus endophthalmitis
7310 following cataract surgery: a therapeutic challenge. *Klin Monbl Augenheilkd* 2012; **229**(4): 441-2.

7311 2108. Yoshida M, Yokokura S, Kunikata H, et al. Endophthalmitis associated with Purpureocillium
7312 lilacinum during infliximab treatment for surgically induced necrotizing scleritis, successfully treated
7313 with 27-gauge vitrectomy. *International ophthalmology* 2018; **38**(2): 841-7.

7314 2109. Garbino J, Ondrusova A, Baglivo E, Lew D, Bouchuiguir-Wafa K, Rohner P. Successful treatment
7315 of Paecilomyces lilacinus endophthalmitis with voriconazole. *Scandinavian journal of infectious diseases*
7316 2002; **34**(9): 701-3.

7317 2110. Pontini P, Gorani A, Veraldi S. Onychomycosis by Paecilomyces lilacinus. *G Ital Dermatol*
7318 *Venerol* 2016; **151**(6): 706-9.

7319 2111. Sillevius Smitt JH, Leusen JH, Stas HG, Teeuw AH, Weening RS. Chronic bullous disease of
7320 childhood and a paecilomyces lung infection in chronic granulomatous disease. *Archives of disease in*
7321 *childhood* 1997; **77**(2): 150-2.

7322 2112. Jenks JD, Prattes J, Frank J, et al. Performance of the Bronchoalveolar Lavage Fluid Aspergillus
7323 Galactomannan Lateral Flow Assay with Cube Reader for Diagnosis of Invasive Pulmonary Aspergillosis: a
7324 Multicenter Cohort Study. *Clinical Infectious Diseases* 2020.

7325 2113. Gilgado F, Cano J, Gene J, Guarro J. Molecular phylogeny of the *Pseudallescheria boydii* species
7326 complex: proposal of two new species. *J Clin Microbiol* 2005; **43**(10): 4930-42.

7327 2114. de Hoog GS, Chaturvedi V, Denning DW, et al. Name changes in medically important fungi and
7328 their implications for clinical practice. *J Clin Microbiol* 2015; **53**(4): 1056-62.

7329 2115. Revankar SG. Dematiaceous fungi. *Mycoses* 2007; **50**(2): 91-101.

7330 2116. Al-Hatmi AM, Meis JF, de Hoog GS. Fusarium: Molecular Diversity and Intrinsic Drug Resistance.
7331 *PLoS Pathog* 2016; **12**(4): e1005464.

7332 2117. Poignon C, Blaize M, Vezinet C, Lampros A, Monsel A, Fekkar A. Invasive pulmonary fusariosis in
7333 an immunocompetent critically ill patient with severe COVID-19. *Clin Microbiol Infect* 2020.

7334 2118. Arastehfar A, Carvalho A, van de Veerdonk FL, et al. COVID-19 Associated Pulmonary
7335 Aspergillosis (CAPA)-From Immunology to Treatment. *J Fungi (Basel)* 2020; **6**(2).

7336 2119. Hoenigl M. Invasive Fungal Disease complicating COVID-19: when it rains it pours. *Clinical
7337 infectious diseases : an official publication of the Infectious Diseases Society of America* 2020.

7338 2120. Eigl S, Prattes J, Reinwald M, et al. Influence of mould-active antifungal treatment on the
7339 performance of the Aspergillus-specific bronchoalveolar lavage fluid lateral-flow device test.
7340 *International journal of antimicrobial agents* 2015.

7341 2121. Heldt S, Prattes J, Eigl S, et al. Diagnosis of Invasive Aspergillosis in Hematological Malignancy
7342 Patients: Performance of Cytokines, Asp LFD, and Aspergillus PCR in Same Day Blood and
7343 Bronchoalveolar Lavage Samples. *The Journal of infection* 2018.

7344 2122. Jenks JD, Mehta SR, Taplitz R, Aslam S, Reed SL, Hoenigl M. Point-of-care diagnosis of invasive
7345 aspergillosis in non-neutropenic patients: Aspergillus Galactomannan Lateral Flow Assay versus
7346 Aspergillus-specific Lateral Flow Device test in bronchoalveolar lavage. *Mycoses* 2019; **62**(3): 230-6.

7347 2123. Mercier T, Dunbar A, de Kort E, et al. Lateral flow assays for diagnosing invasive pulmonary
7348 aspergillosis in adult hematology patients: A comparative multicenter study. *Medical mycology* 2019:
7349 myz079.

7350 2124. Egger M, Jenks JD, Hoenigl M, Prattes J. Blood Aspergillus PCR: The Good, the Bad, and the Ugly.
7351 *Journal of fungi (Basel, Switzerland)* 2020; **6**(1): E18.

7352 2125. Mery A, Sendid B, Francois N, et al. Application of Mass Spectrometry Technology to Early
7353 Diagnosis of Invasive Fungal Infections. *Journal of clinical microbiology* 2016; **54**(11): 2786-97.

7354 2126. Koo S, Thomas HR, Daniels SD, et al. A breath fungal secondary metabolite signature to diagnose
7355 invasive aspergillosis. *Clinical infectious diseases : an official publication of the Infectious Diseases
7356 Society of America* 2014; **59**(12): 1733-40.

7357 2127. Parize P, Muth E, Richaud C, et al. Untargeted next-generation sequencing-based first-line
7358 diagnosis of infection in immunocompromised adults: a multicentre, blinded, prospective study. *Clinical
7359 microbiology and infection : the official publication of the European Society of Clinical Microbiology and
7360 Infectious Diseases* 2017; **23**(8): 574.e1-.e6.

7361 2128. Sinha M, Mack H, Coleman TP, Fraley SI. A High-Resolution Digital DNA Melting Platform for
7362 Robust Sequence Profiling and Enhanced Genotype Discrimination. *SLAS Technol* 2018; **23**(6): 580-91.

7363 2129. Arastehfar A, Wickes BL, Ilkit M, et al. Identification of Mycoses in Developing Countries. *J Fungi
7364 (Basel)* 2019; **5**(4).

7365 2130. Rolle AM, Hasenberg M, Thornton CR, et al. ImmunoPET/MR imaging allows specific detection
7366 of *Aspergillus fumigatus* lung infection in vivo. *Proc Natl Acad Sci U S A* 2016; **113**(8): E1026-33.

7367 2131. Petrik M, Haas H, Dobrozemsky G, et al. ⁶⁸Ga-siderophores for PET imaging of invasive
7368 pulmonary aspergillosis: proof of principle. *J Nucl Med* 2010; **51**(4): 639-45.

7369 2132. Rolle AM, Hasenberg M, Thornton CR, et al. ImmunoPET/MR imaging allows specific detection
7370 of *Aspergillus fumigatus* lung infection in vivo. *Proceedings of the National Academy of Sciences of the
7371 United States of America* 2016; **113**(8): E1026-33.

7372 2133. Rawlings SA, Heldt S, Prattes J, et al. Using Interleukin 6 and 8 in Blood and Bronchoalveolar
7373 Lavage Fluid to Predict Survival in Hematological Malignancy Patients With Suspected Pulmonary Mold
7374 Infection. *Front Immunol* 2019; **10**: 1798.

7375 2134. McCarthy MW, Kontoyiannis DP, Cornely OA, Perfect JR, Walsh TJ. Novel Agents and Drug
7376 Targets to Meet the Challenges of Resistant Fungi. *J Infect Dis* 2017; **216**: S474-S83.

7377 2135. Wiederhold NP, Law D, Birch M. Dihydroorotate dehydrogenase inhibitor F901318 has potent in
7378 vitro activity against *Scedosporium* species and *Lomentospora prolificans*. *J Antimicrob Chemother* 2017;
7379 **72**(7): 1977-80.

7380 2136. Jorgensen KM, Astvad KMT, Hare RK, Arendrup MC. EUCAST Determination of Olorofim
7381 (F901318) Susceptibility of Mold Species, Method Validation, and MICs. *Antimicrobial agents and
7382 chemotherapy* 2018; **62**(8).

7383 2137. Wiederhold NP, Patterson TF, Srinivasan A, et al. Repurposing auranofin as an antifungal: In vitro
7384 activity against a variety of medically important fungi. *Virulence* 2017; **8**(2): 138-42.

7385 2138. Miyazaki M, Horii T, Hata K, et al. In vitro activity of E1210, a novel antifungal, against clinically
7386 important yeasts and molds. *Antimicrobial agents and chemotherapy* 2011; **55**(10): 4652-8.

7387 2139. Hata K, Horii T, Miyazaki M, et al. Efficacy of oral E1210, a new broad-spectrum antifungal with a
7388 novel mechanism of action, in murine models of candidiasis, aspergillosis, and fusariosis. *Antimicrobial
7389 agents and chemotherapy* 2011; **55**(10): 4543-51.

7390 2140. Bernhardt A, Meyer W, Rickerts V, Aebischer T, Tintelnot K. Identification of 14-alpha-Lanosterol
7391 Demethylase (CYP51) in *Scedosporium* Species. *Antimicrobial agents and chemotherapy* 2018; **62**(8).

7392 2141. Lauruschkat CD, Einsele H, Loeffler J. Immunomodulation as a Therapy for *Aspergillus* Infection:
7393 Current Status and Future Perspectives. *J Fungi (Basel)* 2018; **4**(4).

7394 2142. Kumaresan PR, Manuri PR, Albert ND, et al. Bioengineering T cells to target carbohydrate to
7395 treat opportunistic fungal infection. *Proc Natl Acad Sci U S A* 2014; **111**(29): 10660-5.

7396 2143. Jones CN, Ellett F, Robertson AL, et al. Bifunctional Small Molecules Enhance Neutrophil
7397 Activities Against *Aspergillus fumigatus* in vivo and in vitro. *Frontiers in immunology* 2019; **10**: 644.

7398 2144. Jo JH, Kennedy EA, Kong HH. Topographical and physiological differences of the skin mycobiome
7399 in health and disease. *Virulence* 2017; **8**(3): 324-33.

7400 2145. Hoenigl M. Fungal Translocation: A driving force behind the Occurrence of non-AIDS Events?
7401 *Clinical infectious diseases : an official publication of the Infectious Diseases Society of America* 2019.

7402 2146. Richardson M, Bowyer P, Sabino R. The human lung and *Aspergillus*: You are what you breathe
7403 in? *Medical mycology* 2019; **57**(Supplement_2): S145-S54.

7404 2147. Richardson M, Bowyer P, Sabino R. The human lung and *Aspergillus*: You are what you breathe
7405 in? *Med Mycol* 2019; **57**(Supplement_2): S145-S54.

7406