

## KEY WORDS

Regenerative endodontics, regenerative medicine, clinical protocol, treatment outcome, calcium hydroxide, sodium hypochlorite, immature permanent tooth

## LEARNING OBJECTIVES

- To determine the outcomes of Regenerative Endodontic Procedures (REP) involving any disinfection irrigant together with a non-antibiotic intracanal medicament in immature permanent teeth
- To understand the fundamentals of REP
- To understand the evidence base concerning the outcomes of REP with a non-antibiotic protocol through a systematic review

## AUTHORS

**Adam S. Kharchi BDS, MSc (Endo)**  
Clinical teaching fellow, University of Leeds; Associate General Dental Practitioner with a Special Interest in Endodontology

**Nara Tagiyeva PhD, MPH, MD**  
Co-Director, MIPH, Lecturer (Epidemiology), Liverpool School of Tropical Medicine, University of Liverpool

**Shalini Kanagasingam BDS (Mal) MCLinDent Endodontology (Lon) MFDS RCS (Eng) MRD RCS (Edin) MFDS RCPS (Glasg) MRestDent RCPS (Glasg) FHEA**  
Senior Clinical Lecturer, Specialist Endodontist, Course Lead MSc & MCLinDent Endodontology; School of Dentistry, Faculty of Clinical and Biomedical Sciences, University of Central Lancashire, Preston, UK

ADAM S. KHARCHI, NARA TAGIYEVA-MILNE, SHALINI KANAGASINGAM

Prim Dent J. 2020;9(4):65-84

# REGENERATIVE ENDODONTIC PROCEDURES, DISINFECTANTS AND OUTCOMES: A SYSTEMATIC REVIEW

## ABSTRACT

**Aims:** This systematic review aims to identify and synthesise available evidence to determine the clinical and radiographic outcomes of REP involving any disinfection irrigant together with a non-antibiotic intracanal medicament.

**Methods:** Experimental and observational studies evaluating the outcomes of REP in immature non-vital permanent teeth in 6-16 year olds, where the protocol used any type of disinfectant irrigant together with a non-antibiotic intracanal medicament (non-setting calcium hydroxide) were included. Data was narratively synthesised and presented in respect to the primary outcome (elimination of symptoms and infection) and secondary outcomes (increase in root length/width; positive response to vitality testing; patient-reported outcomes; adverse effects).

**Main findings:** 1628 studies were identified, of which five met the eligibility criteria for inclusion in the review. Studies included one randomised control trial and four observational studies. All five studies showed an absence of clinical signs and symptoms for all teeth postoperatively with radiographic resolution or absence of pathology following the disinfection stages of the REP used. Choice of secondary outcomes were inconsistent but included further root development, coronal discolouration and root canal calcifications postoperatively. There was a high risk of bias in all five studies and subsequently the quality of the evidence base was judged to be low.

**Principle conclusions:** REP using a non-antibiotic disinfectant approach appears capable of providing satisfactory outcomes for a non-vital immature permanent tooth. Further high-quality research is required before solid recommendations towards clinical practice guidelines for the disinfection portion of REP can be implemented.

## Introduction

### Regenerative Endodontics

During tooth development, an erupting or erupted tooth may experience trauma, typically from an acute traumatic force or a chronic disease process, such as caries, which is sufficient to cause devitalisation of the pulp. As a sequelae of the pulp becoming non-vital, any further root development ceases, resulting in incomplete root formation. The tooth is then considered immature and pulpal necrosis develops leading to periapical pathology. Clinical signs can include pain, tenderness to percussion (TTP), mobility, swelling and a sinus.

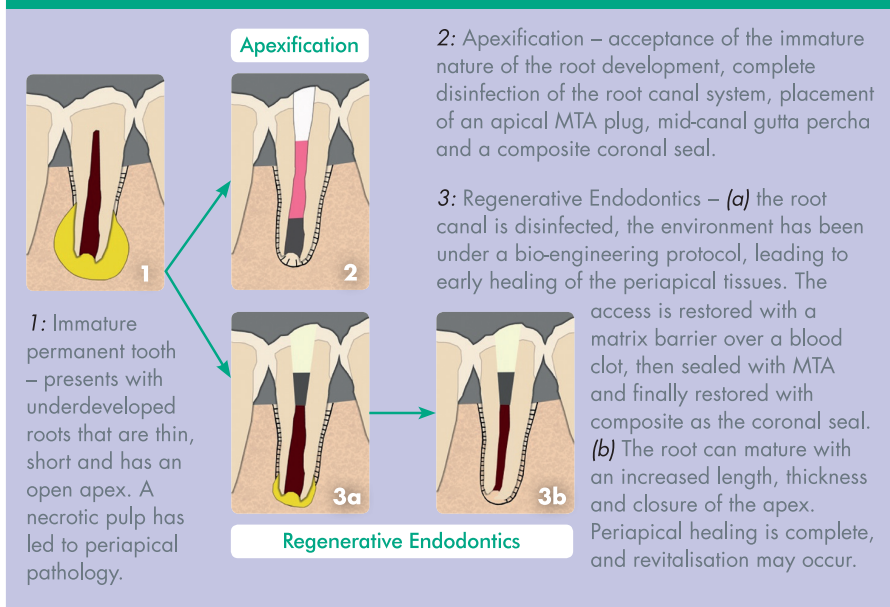
For an adolescent presenting with a non-vital immature tooth, the ideal management would prevent pain and infection, and retain the tooth for function and optimum dental development. This is particularly important for the psycho-social wellbeing of the patient if the traumatised tooth in question is in the anterior region.<sup>1</sup> The options for treatment of a non-vital immature tooth with periapical pathology<sup>2</sup> have historically included:

- No treatment – all patients have the option of no treatment, but the risks associated with this option include persistent pain and infection, and a greater chance of the tooth being lost in the future
- Apexification – the creation of an apical barrier, of the open apex, at the root end after complete disinfection of the root canal. Restorative materials to form the barrier include non-setting calcium hydroxide (Ca(OH)<sub>2</sub>) or mineral trioxide aggregate (MTA) (Figure 1)
- Extraction – the tooth is removed, which treats pain and infection but may lead to functional and aesthetic concerns
- Extraction and transplantation – a vital donor tooth, commonly a premolar tooth, is atraumatically extracted and immediately implanted into the site of the extracted non-vital immature tooth

It is now accepted that there is another option of treatment, termed regenerative endodontics (Figure 1), centred around the principles of tissue engineering.<sup>3</sup>

FIGURE 1

### DIAGRAMMATIC REPRESENTATION OF APEXIFICATION Vs. REGENERATIVE ENDODONTICS



The recommended protocol by the European Society of Endodontology consists of the provision of the procedure over two appointments and is briefly outlined:<sup>4</sup>

- Phase 1
  - Access to the non-vital pulp under local anaesthesia and aseptic techniques
  - Minimal mechanical disturbance of any pulp tissue in the canal
  - Disinfection by irrigants
  - Disinfection by intracanal medicaments (triple antibiotic paste or calcium hydroxide)
  - Provide a coronal seal
- Phase 2 – (2-4 weeks after phase 1)
  - Assess success of phase 1, i.e. asymptomatic and lack of signs of infection (swelling and sinus) – if unsuccessful then phase 1 is repeated with replenished intracanal medicaments

#### Confirmation of success of phase 1:

- Access to the pulp under local anaesthesia (without any vasoconstrictor component to allow bleeding induction) and aseptic techniques
- Irrigate with 17% EDTA solution (chelating agent)

- Induce bleeding, via instrumentation, through the apex to fill the root canal with blood
- Place a collagen matrix above the formed blood clot
- Seal with MTA followed by the placement of a resin composite

Phase 1 aims to create a disinfected environment within the root canal and allows an environment for initial periapical healing to occur. Phase 2 aims to recruit stem cells of the apical papillae (SCAP) directly next to the root tip within the periodontal ligament and bone from below the root apex to regenerate the dentine-pulp complex within the root canal.

Regenerative endodontics is not a completely new concept within dentistry. Experimental studies were conducted in 1961 by Nygaard-Ostby and clinically applied, based on later developed experiments, by Iwaya<sup>5</sup> and Branchs and Trope<sup>6</sup>. It is, however, continued to be practiced with little clinically proven evidence base or strict guidelines, with a wide range of REP techniques shown in the literature.<sup>7</sup>

The theoretical potential for this area of dentistry is great and this type of tissue

bioengineering could provide great benefits to the management of patients.

Increasing evidence of the healing potential of the pulp<sup>8</sup> suggests it is possible to induce biological replacement of cells of the dentine-pulp complex, regenerate the pulp tissues, promote continued development of the root structure and even revitalise the tooth.<sup>3</sup> The preservation of the tooth tissues results in maintenance of the tooth together with its sensory and protective functions.<sup>9,10</sup>

Regenerative endodontics provides a challenge not found within traditional non-surgical endodontics. The open root apex provides no barrier for control of instrumentation and disinfection, but this also facilitates the stimulation of stem cells, scaffolds and growth factors to provide the desired outcomes of REP.<sup>11</sup>

Ideally, the outcome of regenerative endodontics is maintenance of a functional tooth with completed root development, achieved through complete regeneration of all original tissues within the root canal system. Many interchangeable terms are used to describe the same endodontic process, including 'reparation', 'revitalisation' and 'revascularisation' as these describe different elements of outcome provision. Current histological evidence suggests the procedure can only achieve a 'reparative' outcome, as natural human tissues cannot regenerate once completely damaged.<sup>11,12</sup>

### Disinfection within REP

The current recommendation for regenerative endodontic procedures (REP) advocates sufficient disinfection of the pulp space,<sup>4,13</sup> provided through disinfection irrigants (solutions) and intracanal medicaments, which may be either non-setting calcium hydroxide or an antibiotic paste (double or triple antibiotic formula).<sup>4</sup> This protocol has resulted in favourable outcome rates that are comparable to apexification procedures, with the added potential benefit of the continued growth of the root structures and a return to positive vitality testing.<sup>13</sup>

In the absence of infective micro-organisms within the damaged pulp, healing of pulp and periapical tissues

can occur, as documented in the literature.<sup>14</sup> The disinfection process in REP provides an environment where the bio-engineering factors in the procedure can thrive: 'the concentration of both irrigants and medicaments are important to find the balance between disinfection of the canal, attraction of dentine matrix for release of growth factors and survival and proliferation of SCAP'.<sup>15</sup>

The disinfection process in REP starts with the use of irrigants, primarily sodium hypochlorite but it can also include saline, hydrogen peroxide or chlorhexidine. Sodium hypochlorite solution has excellent potency and antibacterial properties (bactericidal) with an effective concentration shown to be ideally 5.25% for non-surgical root canal treatments.<sup>16,17</sup> Disinfection continues with the use of an intracanal medicament placed in the root canal and sealed with a restorative material to permit its function for a period of time. Calcium hydroxide is one intracanal medicament used as a non-setting paste, which is antibacterial<sup>18</sup> and has the ability to further significantly reduce bacteria within root canals after a disinfection irrigant has been used previously.<sup>19</sup> Triple antibiotic paste (TAP) is another intracanal medicament that has been used historically in REPs and continues to be used due to its antibacterial properties.<sup>20</sup>

### Justification for this review

Worldwide concern about over-prescription of antibiotics and the associated risk of antibiotic resistance has led to guidelines from the National Institute of Health and Care Excellence to reduce the use of antibiotics within the UK.<sup>21,22</sup> These recommendations apply across healthcare, including dentistry, and have implications for antibiotic use in regenerative endodontics. The European Society of Endodontology (ESE) published a position statement in 2018 on the use of topical antibiotics in endodontics stating: 'Taking into account the lack of solid evidence supporting the use of antibiotics in REP, the use of calcium hydroxide should be preferred over tri-antibiotic paste'.<sup>23</sup> This emphasises dental professionals' responsibility to provide REP that use non-setting calcium hydroxide as the intracanal medicament instead of antibiotic pastes to create a disinfected

environment, after disinfectant irrigants, for the pulp space.

A scoping search was conducted on Google Scholar and two key endodontic journals, the *International Endodontic Journal* and the *Journal of Endodontics*. This highlighted two recent systematic reviews that had collated all studies examining REPs using different disinfection irrigants with either non-setting calcium hydroxide or antibiotic pastes as an intracanal medicament.<sup>24,25</sup> This means that intervention-specific outcome rates for REP protocol involving different disinfection irrigants, together with or without an antibiotic intracanal medicament, have not been identified and had the potential to be reviewed.

By identifying and synthesising relevant studies, this systematic review aims to distinguish intervention-specific outcomes for regenerative endodontic protocols containing specific disinfection factors. This important evidence synthesis is required to support evidence-based clinical guidelines for regenerative endodontic protocols. In addition, the review will identify future research priorities.

### Research question

This research intended to examine the effect of non-setting calcium hydroxide medicament together with disinfection adjuvants on regenerative endodontic clinical and radiographic outcomes in immature permanent non-vital teeth of adolescents aged 6-16 years old.

### Aims

To determine the clinical and radiographic outcomes of Regenerative Endodontic Procedures (REP) involving any disinfection irrigant together with a non-antibiotic intracanal medicament in immature permanent teeth.

### Objectives

1. To identify empirical studies examining outcomes for REP involving any disinfection irrigant together with a non-antibiotic intracanal medicament
2. To synthesise and quality assess the studies
3. To identify the clinical implications of a non-antibiotic medicament regenerative endodontics protocol on future clinical practice and current guidelines

## Methods

Prior to developing the review methods, PROSPERO was searched to identify any existing reviews in this area. PROSPERO is an international database of prospectively registered systematic reviews in health care.<sup>26</sup> No existing or planned reviews were identified.

## Design

A systematic review approach was selected as the most appropriate method to identify and summarise the best available evidence on the chosen topic. Explicit, systematic and reproducible methods with a clear objective are used to minimise bias.<sup>27</sup>

## Ethics

An ethics checklist was submitted to the University of Central Lancashire (UCLan) prior to commencing the review. The ethics committee provided confirmation that no ethical approval was required.

## Inclusion and exclusion criteria for study selection using the PICO model

**Population:** Humans with non-vital immature permanent teeth, age range of the population between 6-16 years old.

*Exclusions:* Animal studies.

**Intervention:** Studies using any disinfectant irrigant (any type or concentration) alongside non-setting calcium hydroxide as the intracanal medicament.

*Exclusions:* Studies using any form of antibiotic pastes as an intracanal medicament.

**Comparator:** No control; control of any other REP or endodontic treatment options such as apexification.

*Exclusions:* No exclusions.

**Outcomes:** Follow up of at least 6 months examining the following outcomes:

Primary: Elimination of clinical symptoms (pain, sinuses and swelling)

Reduction in radiographic evidence of the presence of pathology

Secondary: Increase in root length and width

Positive response to vitality testing by either a thermal (cold) test or an electric pulp test (EPT)

Patient reported outcomes

Adverse effects

TABLE 1

## KEY DATA EXTRACTED FROM THE INCLUDED STUDIES

Domain	Data extracted
Study information	<ul style="list-style-type: none"> <li>• Authors</li> <li>• Year of publication</li> <li>• Title of publication</li> <li>• Journal of publication</li> <li>• Demographic</li> <li>• Place of study – setting information</li> </ul>
Design	<ul style="list-style-type: none"> <li>• Study design</li> <li>• Aim of study</li> <li>• Ethical approval obtained</li> <li>• Funding</li> </ul>
Participants	<ul style="list-style-type: none"> <li>• Inclusion and exclusion criteria</li> <li>• Number of participants / teeth</li> <li>• Number of relevant participants/teeth (if more than one intervention group present in study)</li> <li>• Participant demographics: Age of patients (mean/range); Ratio of patient sex (M:F); Type/number of teeth (anterior, premolar, molar); Cause of teeth non-vitality (trauma, caries, developmental)</li> </ul>
	<ul style="list-style-type: none"> <li>• Pre-operative clinical signs (pain, swelling, sinus, tender to percussion (TTP) test, mobility, periodontal pocketing; number of teeth)</li> <li>• Pre-operative radiographic findings (periapical pathology (PAP) present, number of teeth)</li> <li>• Pre-operative vitality test response (cold or electric pulp (EPT) test; number of teeth responded to test)</li> </ul>
Recruitment	<ul style="list-style-type: none"> <li>• Number approached / enrolled / recruited</li> <li>• Randomization method (if applicable)</li> <li>• Loss of participants/teeth</li> </ul>
Intervention	<ul style="list-style-type: none"> <li>• Disinfection irrigant type and concentration</li> <li>• Duration of non-setting calcium hydroxide medicament used (days)</li> <li>• REP protocol (brief outline)</li> </ul>
Control (if applicable)	<ul style="list-style-type: none"> <li>• Summary of control procedure</li> </ul>
Follow up	<ul style="list-style-type: none"> <li>• Follow up period (range of months)</li> </ul>
Outcomes	<p><b>Primary outcomes</b></p> <ul style="list-style-type: none"> <li>○ Clinical signs (pain, swelling, sinus, TTP, tooth survival; number of teeth, p value where appropriate)</li> <li>○ Radiographical signs (PAP increased, no changes, reduction, absent; timing and description of measurements, number of teeth)</li> </ul> <p><b>Secondary outcomes</b></p> <ul style="list-style-type: none"> <li>○ Radiographical root development (root width/length increased/no changes, root apex closure; number of teeth and average percentages)</li> <li>○ Vitality – response to vitality testing (including type of test, number of teeth)</li> <li>○ Patient reported outcomes</li> <li>○ Clinical adverse outcomes</li> </ul>
Statistical analysis	<ul style="list-style-type: none"> <li>• Sample size calculation</li> <li>• Descriptive analysis</li> <li>• Inferential statistics</li> </ul>
Key findings	<ul style="list-style-type: none"> <li>• As described by authors</li> </ul>

Owing to the limited evidence-base in the scoping searches, a wide range of study designs were included: experimental studies (randomised controlled trials; non-randomised controlled trials) and observational studies including prospective and retrospective studies with or without a control group with at least >5 participants. Case reports or case series with 5 or fewer cases, and non-empirical evidence (review articles, letters, expert opinion) were excluded. No exclusions were made based on setting or language.

### Search strategy

Three popular academic databases for health care research were chosen for the searches to allow a comprehensive search of the available literature (MEDLine with full text, Dentistry and Oral Sciences sources, Embase). In addition, handsearching was performed via Google Scholar and reviewing reference lists of included studies.

Five key search terms, derived from the research question, were used as concepts forming the basis of the search strategy:

1. Regenerative endodontics
2. Immature permanent tooth
3. Calcium hydroxide
4. Disinfection
5. Outcomes

No limitations were made on language of any studies. The searches were restricted to 1<sup>st</sup> January 2004 to the day of the search (18<sup>th</sup> December 2018). Prior to 2004, greater variation was present within REPs but a key study by Branchs et al. in 2004<sup>6</sup> established a more standardised approach to REP, which subsequent studies largely followed. The search was performed on 18<sup>th</sup> December 2018 and updated on 24<sup>th</sup> April 2020.

### Study selection

Study identification and selection was performed by a single reviewer (AK). The records were imported into a reference management program, RefWorks (RefWorks, ProQuest LLC). A screening process of the search results included removal of duplicate studies, using the predefined inclusion and exclusion criteria by title, abstract and finally full text.

### Data extraction

Data extraction was performed by a single reviewer (AK). Key data was extracted and presented to allow synthesis across and within studies in a table in Microsoft Word v16.17 (Microsoft Corporation). The key information extracted from the records is presented (Table 1). Any missing data was managed by contacting the corresponding author.

### Data synthesis

Meta-analysis was planned for studies with adequate homogeneity in population, intervention and outcome measures. Where heterogeneity between studies precluded quantitative synthesis, a narrative synthesis was performed.

### Quality assessment

The tools used to assess the risk of bias are the Cochrane Risk of Bias Tool<sup>28</sup> for any randomised control trials and the Quality Assessment Tool for Quantitative Studies by the Effective Public Health Practice Project<sup>29</sup> for any observational studies.

## Results

### Study selection

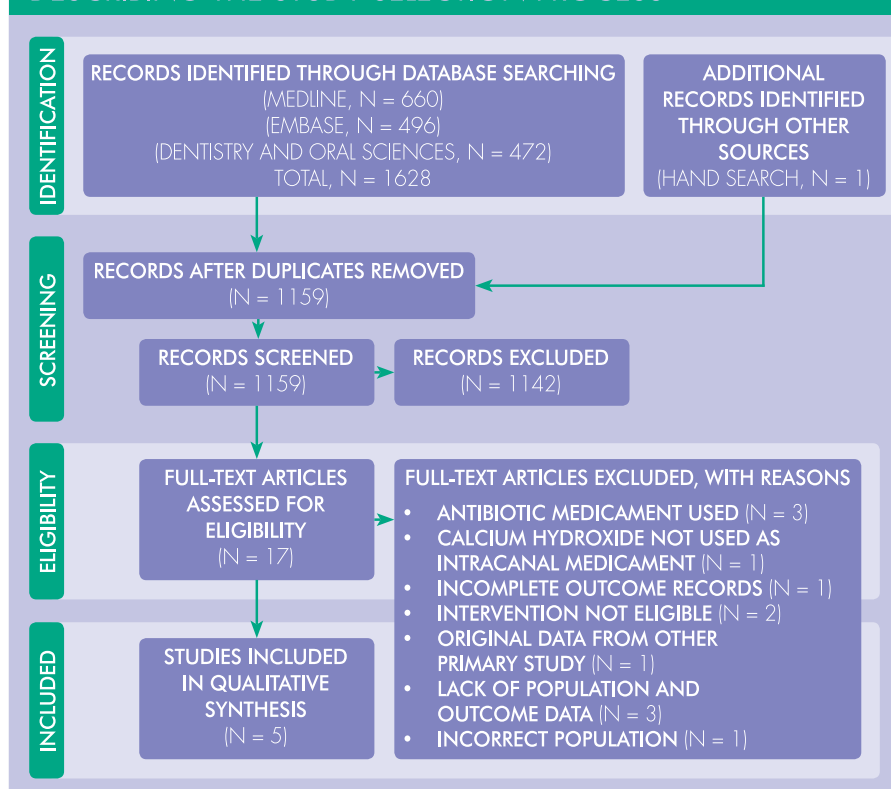
Searches of the three databases alongside handsearching provided a total of 1628 studies. The PRISMA flow chart showing study selection is given in Figure 2. Following de-duplication and exclusion by title and abstract, 17 studies were obtained for full text screening. Twelve studies we excluded with reasoning listed in Supplemental material 2. Five studies were included in the review.<sup>30,31,32,33,34</sup>

### Study characteristics

Key characteristics of the studies and the population details included in the review are summarised in Table 2 and 3.

The details of the intervention are summarised in Table 4. All four studies showed some similarities in the REP sequential stages including disinfection, review, re-disinfection and final coronal seal of the tooth using a mineral trioxide aggregate (MTA) restorative dental material. These steps were sufficient to classify the procedures as regenerative endodontics, however, there were other

**FIGURE 2**  
PRISMA FLOW DIAGRAM  
DESCRIBING THE STUDY SELECTION PROCESS





**TABLE 2**  
KEY CHARACTERISTICS OF THE INCLUDED STUDIES

Study	Cehreli et al.	Chen et al.	Chueh et al.	Nagata et al.	Song et al.
Year	2011	2012	2009	2014	2017
Country	Turkey	Taiwan & USA	Taiwan	Brazil	USA & South Korea
Design	Retrospective observational without control	Retrospective observational without control	Retrospective observational without control	Randomised controlled trial	Retrospective observational with control
Setting	Secondary care	Secondary care	Primary care	Secondary care	Secondary care

**TABLE 3**  
SUMMARY OF PARTICIPANTS IN THE INCLUDED STUDIES

Study	Cehreli et al.	Chen et al.	Chueh et al.	Nagata et al.	Song et al.
No. of participants	6	20	21	<i>Not reported</i>	10
Age (years)	Mean 9.3	Mean 10.2	Mean 10.6	7-17	Mean 12.2
Sex (M:F)	1:5	9:11	11:10	<i>Not reported</i>	6:4
Number of teeth	6	20	23	11	10
Type of teeth (N)					
anterior	0	10	1	11	3
premolar	0	10	21	0	6
molar	6	0	1	0	1
Cause of tooth non-vitality (n)					<i>3 unknowns</i>
caries	6	3	1	0	1
developmental	0	7	0	0	3
trauma	0	10	22	11	3

**TABLE 4**  
INTERVENTIONS AND COMPARATORS USED IN THE INCLUDED STUDIES  
(NAOCL = SODIUM HYPOCHLORITE, CHX = CHLORHEXIDINE GLUCONATE)

Study	Cehreli et al.	Chen et al.	Chueh et al.	Nagata et al.	Song et al.
Intervention					
Disinfection irrigant (type, concentration)	NaOCl, 2.5%	NaOCl, 5.25%	NaOCl, 2.5%	NaOCl, 6% CHX gel, 2%	NaOCl 2.5%
nsCa(OH) <sub>2</sub> duration (days)	21	28	28	21	24.7 mean
Control	None	None	None	TAP	TAP
Follow up, months	9-10	6-27	6-108	9-19	12-58

variations in the details of the REP demonstrating heterogeneity in the intervention between the studies.

Of the five studies only one<sup>34</sup> had quoted following the recommended guidelines from the American Association of Endodontists or European Society of Endodontology for REP.<sup>4,13</sup>

Due to heterogeneity in the study population, interventions, outcome

measures and follow up regimes, meta-analysis of data was not possible. Instead a narrative synthesis was used on the outcome data.

### Primary outcome

Pre-operatively, of the 70 teeth included across the five studies, 62 showed pre-treatment radiographic evidence of periapical pathology. 70 teeth were non-responsive to vitality testing, although two studies did not

report any quantitative vitality testing data.<sup>32,34</sup>

Post-operatively, the studies reported that all teeth had survived. Clinical signs indicative of infection (pain, swelling, sinus, TTP) were absent for all 70 teeth. There was a trend for reduction in periapical pathology size early in the REP (reported at 3-12 weeks) and complete absence of periapical pathology at 8-12 months (Table 5).<sup>30,32,33,34</sup>

**TABLE 5**

## PRIMARY OUTCOME DATA

Study	Primary outcomes				Tooth survival
	Clinical Signs		Periapical pathology (PAP)		
	Pre-operatively	Post-operatively	Pre-operatively	Post-operatively	
Cehreli et al. 2011 6 teeth	Pain – 0/6 Swelling – 0/6 Sinus – 0/6 TTP – <i>not reported</i> Mobility – normal 6/6 Periodontal pocketing – normal 6/6	Pain – 0/6 Swelling – 0/6 Sinus – 0/6 TTP – <i>not reported</i> Mobility – <i>not reported</i> Periodontal pocketing – <i>not reported</i>	PAP present 6/6	Reduction in PAP 6/6 at 3 weeks Absence of PAP 6/6 at 9 months	6/6
Chen et al. 2012 20 teeth	Pain – 0/20 Swelling – 5/20 Sinus – 11/20 TTP – <i>not reported</i> Mobility – <i>not reported</i> Periodontal pocketing – <i>not reported</i>	Pain – 0/20 Swelling – 0/20 Sinus – 0/20 TTP – <i>not reported</i> Mobility – <i>not reported</i> Periodontal pocketing – <i>not reported</i>	PAP present 20/20	Reduction in PAP 20/20 Timing of radiographs – <i>not reported</i>	20/20
Chueh et al. 2009 23 teeth	Pain – 9/23 Swelling – 10/23 Sinus – 9/23 TTP – <i>not reported</i> Mobility – <i>not reported</i> Periodontal pocketing – <i>not reported</i>	Pain – 0/23 Swelling – 0/23 Sinus – 0/23 TTP – <i>not reported</i> Mobility – <i>not reported</i> Periodontal pocketing – <i>not reported</i>	PAP present 23/23	Reduction in PAP 21/23 at 3±2 months Absence of PAP 23/23 at 8±5 months	23/23
Nagata et al. 2014 11 teeth	Pain – 10/11 Swelling – 0/11 Sinus – 2/11 TTP – 10/11 Mobility – <i>not reported</i> Periodontal pocketing – <i>not reported</i>	Pain – 0/11 Swelling – 0/11 Sinus – 0/11 TTP – 0/11 Mobility – <i>not reported</i> Periodontal pocketing – <i>not reported</i>	PAP present 5/11	PAP still present 1/5 – unreported exact status PAP absent 4/5 Timing of radiographs – <i>not reported</i>	11/11
Song et al. 2017 10 teeth	Pain – <i>not reported</i> Swelling – 0/10 Sinus – 3/10 TTP – 7/10 Mobility – 1/10 Periodontal pocketing – <i>not reported</i>	Pain – <i>not reported</i> Swelling – 0/10 Sinus – 0/10 TTP – 0/10 Mobility – <i>not reported</i> Periodontal pocketing – <i>not reported</i>	PAP present 8/10	PAP absent 10/10 Timing of radiographs – <i>not reported</i>	10/10

Key: TTP = tenderness to percussion (a clinical test to predict presence of periapical pathology), PAP = periapical pathology.

\*- p value showing significance between and pre and post-operative results

**TABLE 6**

**QUALITY ASSESSMENT OF QUANTITATIVE RETROSPECTIVE OBSERVATIONAL STUDIES USING THE EFFECTIVE PUBLIC HEALTH PRACTICE PROJECT TOOL (EPHPP)<sup>30</sup>**

	Study			
	Cehreli et al. (2011)	Chen et al. (2012)	Chueh et al. (2009)	Song et al. (2017)
Selection bias	●	●	●	●
Study design	●	●	●	●
Confounders	●	●	●	●
Blinding	●	●	●	●
Data collection methods	●	●	●	●
Withdrawal and dropouts	n/a	n/a	n/a	●
Global rating	●	●	●	●

Key: ● Strong ● Moderate ● Weak

**Methodological quality and risk of bias**

The five studies were quality assessed to estimate the overall quality of the evidence and confidence in the results (Table 6 and 7).

**Discussion**

**Primary outcomes**

Overall, the management of infection in all five studies resulted in survival of all teeth and elimination of all clinical signs of infection. The mean recall period for the 5 studies was 21.6 months (ranging from 9-108 months). Initial radiographic signs of pathology also showed signs of a reduction or absence within 6-9 months. Elimination of clinical signs of infection occurred even earlier, at 21-28 days, suggesting the healing period for a patient is relatively rapid and is comparable to other endodontic treatment options for managing non-vital teeth.

In all studies, disinfection was established by the combined use of a sodium hypochlorite irrigant (2.5-6%) and a non-setting calcium hydroxide intracanal medicament. One study used 2% chlorhexidine gel together with the sodium hypochlorite irrigant; the justification for this additional disinfectant is due to the ability to immediately reduce *E. faecalis* microbes by this combination of disinfectants.<sup>17</sup> Variation in the concentrations of the disinfectant irrigant and its delivery prevented direct comparisons between studies. Nonetheless, the studies consistently used a sodium hypochlorite irrigant and a non-setting calcium hydroxide intracanal medicament, suggesting this combination successfully creates the disinfected environment regardless of sodium hypochlorite concentration.

**Secondary outcomes**

Improvements in root development, which would be expected to have a clinical impact on the functionality and survival of the teeth, were demonstrated in the outcomes. It was not possible to directly compare root development to specific REP interventions. It can be postulated that regardless of the specific REP details, a sufficiently disinfected environment was created to allow a biological response with appropriate cells to support the continued root

**TABLE 7**

**QUALITY ASSESSMENT OF RANDOMIZED CONTROLLED TRIAL USING THE COCHRANE RISK OF BIAS TOOL<sup>29</sup>**

Study	Nagata et al. (2014)
<b>Domain of risk of bias tool</b>	<b>Risk of bias</b>
Randomization sequence generation (selection bias)	●
Allocation concealment (selection bias)	●
Blinding of participants and personnel (performance bias)	●
Blinding of outcome assessment (detection bias)	●
Incomplete outcome data (attrition bias)	●
Selective reporting (reporting bias)	●
Other bias	●

Key: ● Low risk ● Unclear risk ● High risk

**Secondary outcomes**

The secondary outcomes reported were variable and included:

- Increase in root length<sup>30,31,32,33,34</sup>
- Increase in root width<sup>30,31,32,33,34</sup>
- Apical closure of root tips<sup>31,33</sup>
- Complete root development<sup>32</sup>

- Re-establishment of vitality<sup>30,33</sup>
- Crown discolouration<sup>31,33</sup>
- Partial or complete canal obliteration<sup>31,32,34</sup>

No studies reported any patient-reported outcomes.



development. This is supported by previous research which indicates that the single most important variable for further root development in REP is the disinfected root canal.<sup>35</sup>

Discolouration found after REP can be attributed to either one of the intracanal medicaments (triple antibiotic paste (TAP) or non-setting calcium hydroxide) or the coronal seal restorative material (MTA). However, it is difficult to control the effect of TAP on discolouration and this is suggested as a reason to remove TAP from REP.<sup>20,38</sup> It may be beneficial to recommend the use of a non-antibiotic intracanal medicament in a REP to limit the chances of discolouration, particularly for anterior teeth and teeth that have suffered trauma causing devitalisation.

Partial or complete root canal obliteration as a result of regenerative endodontic procedures is referred to as 'revascularization associated intracanal calcifications' (RAIC).<sup>34</sup> One of the studies showed that a thin calcific barrier (partial obliteration or blockage) within the pulp canal tends to be present after regenerative endodontic procedures, more so than partial obliteration or atresia (total blockage). The prevalence of RAIC (62.1%) is increased with an intracanal medicament of non-setting calcium hydroxide use rather than TAP.<sup>34</sup> This is supported by evidence that non-setting calcium hydroxide can be used in apexification procedures where a calcific barrier outcome at the incomplete apex of an immature tooth is desirable.<sup>2</sup>

The overall prevalence of canal obliterations in this review is close to that quoted by Song *et al.* (2017).<sup>34</sup> This is clinically relevant if the regenerative endodontic approach was to fail as further treatment options would be non-viable with the presence of RAIC. This may then actually be considered a contraindication for a non-antibiotic medicament use in REP.

### Irrigant recommendations

The use of sodium hypochlorite in endodontics has a long and proven history of efficacy to create a desired disinfected environment in root canals.<sup>16,17</sup> The ideal concentration of sodium hypochlorite has been shown to be 1.5-3% for regenerative endodontic

procedures and is reflected in recommended REP guidelines.<sup>4</sup> This effectively disinfects but also allows the survival and differentiation of SCAP.<sup>37</sup>

This review provides no evidence to contradict maintenance of the recommended guidelines of 1.5-3% sodium hypochlorite use, but this review also cannot support or make advancements to the guidelines.

It is recognised that as an adjunct to the use of sodium hypochlorite, the use of EDTA 17% solution is indicated and provides the final irrigation. Evidence shows EDTAs importance in the conditioning of dentine and exposing growth factors that aids cellular migration, adhesion and differentiation within REP.<sup>38</sup>

### Intracanal medicament recommendations

The debate over which intracanal medicament to use in REPs currently appears to carry greater weight and importance than the type of disinfectant irrigant to use in REPs.<sup>4,39</sup> The ESE position statement has advocated a non-antibiotic intracanal medicament regime in regenerative endodontics due to the lack of evidence for using topical antibiotics in REPs.<sup>23</sup> Evidence suggests the disadvantages of topical antibiotics and advantages of non-setting calcium hydroxide as the intracanal medicament include:

- Reduces antibiotic use to avoid antibiotic resistance<sup>4,39</sup>
- MTA retention, as an ideal restorative coronal sealing material after REP, is best with the use of non-setting calcium hydroxide as an intracanal medicament<sup>40</sup>
- Non-setting calcium hydroxide shows no detrimental effect on the survival of SCAP that are key to the bio-engineering process of regenerative endodontics<sup>41</sup>
- Statistically insignificant differences in bacterial reduction when comparing non-setting calcium hydroxide to a clinically used concentration of 0.1 mg/ml of TAP. Only a concentration of 10mg/ml of TAP significantly reduced bacterial numbers, yet coronal discolouration is credited to TAP, especially at these higher concentrations<sup>20</sup>

- Too low concentration of TAP (<1 mg/ml) reduced its antibacterial efficacy<sup>35</sup>

This evidence above originates from ex-vivo studies and there is a lack of clinical, in-vivo studies that can be used to guide appropriate clinical recommendations for the implementation of regenerative endodontic procedures.

This review confirms the evidence available for the use of non-setting calcium hydroxide as the only intracanal medicament in REPs is weak. Still, it could be argued that where evidence is equivocal but non-setting calcium hydroxide does not possess the disadvantages of TAP, it may be practical to use a non-antibiotic intracanal medicament.

### Strengths and limitations

The strengths of this systematic review are:

- Development of a clinically relevant question and the thorough review process used
- Use of a strict inclusion and exclusion criteria
- Application of a rigorous search strategy
- Validated risk of bias tools were used to assess the validity and reliability of the studies

This systematic review has some limitations which then reflects on the restriction of the clinical application of the review findings:

- Search bias – limitation of the number of databases searched
- Reviewer bias – only one reviewer was implemented
- Publication bias
- Missing data – lack of retrievable data from two studies, which had to be subsequently excluded, due to non-communication from authors
- Lack of standardisation in the intervention or outcome measure of the studies
- Level of bias in the included studies

The inclusion of only four retrospective observational studies and one randomised control trial judged to be at high risk of bias means the results need to be interpreted with caution. Small sample sizes with selection bias, a lack of clarity in the intervention and outcome

# REGENERATIVE ENDODONTIC PROCEDURES, DISINFECTANTS AND OUTCOMES: A SYSTEMATIC REVIEW

measures, a high risk of confounders and lack of blinding for analysis contribute to the high levels of bias.

## Current and future research

The level of evidence in regenerative endodontics has been previously judged to be low.<sup>7</sup> Current guidelines recommend that apexification should be the first option when considering the presentation of a non-vital tooth with incomplete root formation and periapical pathology, unless the roots were too small to be functional post-treatment of which extraction is the best option.<sup>42</sup>

This review, alongside the previously cited reviews<sup>24,25,42</sup> agree that future research in REP is required. Long-term robust double-blinded randomised control trials with large sample sizes

are essential to measure the true impact of REP and their outcomes. This would include controlled comparisons of different interventions, such as non-setting calcium hydroxide versus TAP, or different types and concentrations of disinfectant irrigants while maintaining a consistency in the intracanal medicament used in the REP. This will support agreements on a preferred evidence-based REP, which can then be compared to all options of non-vital immature permanent teeth in subsequent studies.

## Conclusion

1. With the limitations of this study, it may be concluded that REP using a disinfectant irrigant of sodium hypochlorite together with an intracanal medicament of non-setting

calcium hydroxide is capable of providing a disinfected environment in a non-vital immature permanent tooth root canal to eliminate clinical signs and symptoms and reduce or eliminate radiographic signs of pathology. However, the evidence base currently is weak.

2. REP is an advancing area of dentistry with great potential, but more long-term, robust and high levels of evidence are required to provide further recommendations to regenerative endodontics and support the position statements of the ESE.<sup>23</sup>

## ACKNOWLEDGEMENTS

Illustrations courtesy of S Batty (Senior Lecturer BA (Hons) Interior Architecture & Design, MA Design (Interior), Sheffield Hallam University).

## REFERENCES

- Lee JY, Divaris K. Hidden Consequences of Dental Trauma: The Social and Psychological Effects. *Ped Dent.* 2009;31(2):96-101.
- Trope M. Treatment of immature teeth with non-vital pulps and apical periodontitis. *Endod Topics.* 2006;14(1):51-59.
- Murray PE, Garcia-Godoy F, Hargreaves KM. Regenerative endodontics: a review of current status and a call for action. *J Endod.* 2007;33(4):377-390.
- Galler KM, Krastl G, Simon S, et al. European society of endodontists position statement: revitalization procedures. *Int Endod J.* 2016;49(8):717-23
- Iwaya S, Ikawa M, Kubota M. Revascularization of an immature permanent tooth with apical periodontitis and sinus tract. *Dent Traumatol.* 2001 Aug;17(4):185-7.
- Branches F, Trope M. Revascularization of immature permanent teeth with apical periodontitis: New treatment protocol? *J Endod.* 2004 Apr;30(4):196-200.
- Kontakiotis EG, Filippatos CG, Agrafioti A. Levels of Evidence for the Outcome of Regenerative Endodontic Therapy. *J Endod.* 2014 Aug;40(8):1045-53.
- Riccucci D, Loghin S, Siqueira JF. Correlation between clinical and histologic pulp diagnoses. *J Endod.* 2014. Dec;40(12):1932-9.
- Hargreaves KM, Diogenes A, Teixeira FB. Treatment options: biological basis of regenerative endodontic procedures. *J Endod.* 2013 Mar;39(3 Suppl):S30-S43.
- Law AS. Considerations for regeneration procedures. *J Endod.* 2013 Mar;39(3 Suppl):S44-S56.
- Kim SG, Malek M, Sigurdsson A, et al. Regenerative endodontics: a comprehensive review. *Int Endod J.* 2018 Dec;51(12):1367-1388.
- Simon SRJ, Tomson PL, Berdal A. Regenerative Endodontics: Regeneration or Repair? *J Endod.* 2014 Apr;40(4 Suppl):S70-S.
- American Association of Endodontists. Endodontics: colleagues for excellence newsletter, regenerative endodontics. [Internet]. New York: American Association of Endodontists; 2016. Available at <https://www.aae.org/specialty/wp-content/uploads/sites/2/2017/06/ecfespring2013.pdf> [Accessed 20th March 2020].
- Takehashi S, Stanley HR, Fitzgerald RJ. The effects of surgical exposures of dental pulps in germ-free and conventional laboratory rats. *Oral Surg Oral Med Oral Pathol.* 1965 Sep;20:340-9.
- Lin LM, Kahler B. A review of regenerative endodontics: current protocols and future directions. *J Istanbul Univ Fac Dent.* 2017; 51(3 Suppl 1): S41-S51.
- Byström A, Claesson R, Sundqvist G. The antibacterial effect of camphorated paramonochlorophenol, camphorated phenol and calcium hydroxide in the treatment of infected root canals. *Endod Dent Traumatol.* 1985 Oct;1(5):170-5.
- Mohammadi Z. Sodium hypochlorite in endodontics: an update review. *Int Dent J.* 2008;58(6):329-341.
- Sjögren U, Figdor D, Spangberg L, et al. The antimicrobial effect of calcium hydroxide as a short-term intracanal dressing. *Int Endod J.* 1991 May;24(3):119-25.
- Siqueira José F Jr, Magalhães KM, Rôças IN. Bacterial Reduction in Infected Root Canals Treated With 2.5% NaOCl as an Irrigant and Calcium Hydroxide/Camphorated Paramonochlorophenol Paste as an Intracanal Dressing. *Endod J.* 2007 Jun;33(6):667-72.
- Latham J, Fong H, Jewett A, et al. Disinfection Efficacy of Current Regenerative Endodontic Protocols in Simulated Necrotic Immature Permanent Teeth. *J Endod.* 2016 Aug;42(8):1218-25.
- National Institute for Health and Care Excellence (NICE), Public Health England (PHE). Antimicrobial stewardship: changing risk related behaviours in the general population. [Internet]. London: NICE and PHE; 2017. Available at <https://www.nice.org.uk/guidance/ng63> [Accessed 21st February 2020].
- National Institute for Health and Care Excellence (NICE), Public Health England (PHE). Managing common infections: antimicrobial prescribing guidelines. [Internet]. London: NICE and PHE; 2018. Available at <https://www.nice.org.uk/guidance/gid-ng10050/documents/final-scope-2> [Accessed 21st February 2020].
- Montero-Mirallas P, Martin-Gonzalez J, Alonzo-Espeleta O, et al. Effectiveness and clinical implications of the use of topical antibiotics in regenerative endodontic procedures: a review. *Int Endod J.* 2018;51:981-988.
- Tong HJ, Rajan S, Bhujel N, et al. Regenerative endodontic therapy in the management of immature nonvital permanent teeth: A systematic review – outcome evaluation and meta-analysis. *J Endod.* 2017 Sep;43(9):1453-1464.
- Torabinejad M, Nosrat A, Verma P, et al. Regenerative endodontic treatment or mineral trioxide aggregate apical plug in teeth with necrotic pulps and open apices: A systematic review and meta-analysis. *J Endod.* 2017 Nov;43(11):1806-1820.
- Higgins JP, Altman DG, Sterne JAC. (Eds). *Cochrane Handbook for Systematic Reviews of Interventions.* London, UK: The Cochrane Collaboration; 2011.
- Centre for Reviews and Dissemination (CRD), University of York. PROSPERO: International prospective register of systematic reviews. [Internet]. London: CRD and University of York; 2018. Available at <https://www.crd.york.ac.uk/prosperto/> [Accessed September 2018].
- Higgins JPT, Sterne JAC, Savović J, et al. A revised tool for assessing risk of bias in randomized trials. In: Chandler J, McKenzie J, Boutron I, et al. (Eds). *Cochrane Methods. Cochrane Database of Systematic Reviews.* 2016(100):Suppl 1).
- Effective Public Health Practice Project (EPHPP). Quality Assessment Tool for Quantitative Studies. [Internet]. London: EPHPP; 2010. Available at <https://merst.ca/wp-content/uploads/>

2018/02/quality-assessment-tool\_2010.pdf [Accessed February 2020].

30 Cehreli ZC, Isbitiren B, Sara S, et al. Regenerative endodontic treatment (revascularization) of immature necrotic molars medicated with calcium hydroxide: a case series. *J Endod.* 2011 Sep;37(9):1327-1330.

31 Chen MYH, Chen KL, Chen CA, et al. Responses of immature permanent teeth with infected necrotic pulp tissue and apical periodontitis/abscess to revascularization procedures. *Int Endod J.* 2012 Mar;45(3):294-305.

32 Chueh LH, Ho YC, Kuo TC, et al. Regenerative endodontic treatment for necrotic immature permanent teeth. *J Endod.* 2009 Feb;35(2):160-4.

33 Nagata JY, de Almeida Gomes BPF, Lima TFR, et al. Traumatized immature teeth treated with 2 protocols of pulp revascularization. *J Endod.* 2014 May;40(5):606-12.

34 Song M, Cao Y, Shin S, et al. Revascularization-associated Intracanal Calcification: Assessment of Prevalence and Contributing Factors. *J Endod.* 2017 Dec;43(12):2025-2033.

35 Fouad AF. Microbial Factors and Antimicrobial Strategies in Dental Pulp Regeneration. *J Endod.* 2017 Sep;43(9S):S46-S50.

36 Ahmed HMA, Abbott PV. Discolouration potential of endodontic procedures and materials: a review. *Int Endod J.* 2012 Oct;45(10):883-97.

37 Martin DE, De Almeida J, Flavio A, et al. Concentration-dependent Effect of Sodium Hypochlorite on Stem Cells of Apical Papilla Survival and Differentiation. *J Endod.* 2014 Jan;40(1):51-5.

38 Galler KM, Widbiller M, Buchalla W, et al. EDTA conditioning of dentine promotes adhesion, migration and differentiation of dental pulp stem cells. *Int Endod J.* 2016 Jun;49(6):581-90.

39 Segura-Egea J, Gould K, Şen BH, et al. Antibiotics in Endodontics: a review. *Int Endod J.* 2017 Dec;50(12):1169-1184.

40 Amin SAW, Gawdat SI. Retention of BioAggregate and MTA as coronal plugs after intracanal medication for regenerative endodontic procedures: an ex vivo study. *Restor Dent Endod.* 2018 Apr 26;43(3):e18.

41 Ruparel NB, Teixeira FB, Ferraz CCR, et al. Direct Effect of Intracanal Medicaments on Survival of Stem Cells of the Apical Papilla. *J Endod.* 2012 Oct;38(10):1372-5.

42 Duggal M, Tong HJ, Al-Ansary M, et al. Interventions for the endodontic management of non-vital traumatised immature permanent anterior teeth in children and adolescents: a systematic review of the evidence and guidelines of the European Academy of Paediatric Dentistry. *Eur Arch Paediatr Dent.* 2017 Jun;18(3):139-151.

## Supplemental material

### Supplemental Tables 1: Database search results

#### SUPPLEMENTAL TABLE 1A

DATABASE PROVIDED BY MEDLINE WITH FULL TEXT (EBSCOHOST) – UPDATED SEARCH AS OF APRIL 2020

Search ID	Search Terms	Results
S1	AB regeneration OR AB revitali#ation OR AB revasculari#ation OR AB regenerative	(190,764)
S2	AB endodontic*	(13,949)
S3	AB treatment OR AB therapy OR AB procedure OR AB protocol OR AB therapeutic*	(5,993,554)
S4	AB regenerative endodontic*	(435)
S5	AB "regenerative endodontic"	(395)
S6	(MH "Endodontics") AND (MH "Regenerative Medicine")	(17)
S7	AB REP OR AB RET	(13,188)
S8	AB pulp	(26,982)
S9	AB dental OR tooth OR teeth	(233,311)
S10	AB non vital OR AB necrotic	(41,375)
S11	AB immature OR AB open ap*	(101,471)
S12	MH "Tooth, Nonvital"	(2,057)
S13	MH "Dental Pulp Necrosis"	(2,258)
S14	AB "non setting calcium hydroxide"	(20)
S15	AB "calcium hydroxide paste"	(273)
S16	AB calcium hydroxide	(3,562)

## REGENERATIVE ENDODONTIC PROCEDURES, DISINFECTANTS AND OUTCOMES: A SYSTEMATIC REVIEW

Search ID	Search Terms	Results
S17	AB CaOH2	(13)
S18	AB ca (oh) 2	(1,964)
S19	(MH "Calcium Hydroxide")	(4,318)
S20	TX Multi-Cal	(5)
S21	TX Hypo-Cal	(3)
S22	TX Apexcal	(10)
S23	TX UltraCal	(34)
S24	TX Pulpdent	(82)
S25	TX Calxyl	(46)
S26	TX Odontocide	(2)
S27	TX Calcicur	(11)
S28	S1 OR S2 OR S3 OR S4 OR S5 OR S6 OR S7	(6,109,718)
S29	S9 AND (S8 OR S10 OR S11 OR S12 OR S13)	(16,789)
S30	S14 OR S15 OR S16 OR S17 OR S18 OR S19 OR S20 OR S21 OR S22 OR S23 OR S24 OR S25 OR S26 OR S27	(7,181)
S31	S28 AND S29 AND S30	(900)
S32	S28 AND S29 AND S30	(660)
Limiters - Publication Date: 2004/01/01-2018/12/18 Human		

### SUPPLEMENTAL TABLE 1B

DATABASE PROVIDED BY DENTISTRY & ORAL SCIENCES SOURCE (EBSCOHOST) –  
SEARCHED DECEMBER 2018

Search ID	Search Terms	Results
S1	AB regeneration OR AB revitali#ation OR AB revasculari#ation OR AB regenerative	(6,328)
S2	AB endodontic*	(11,734)
S3	AB treatment OR AB therapy OR AB procedure OR AB protocol OR AB therapeutic*	(96,267)
S4	AB regenerative endodontic*	(288)
S5	AB "regenerative endodontic**"	(264)
S6	(DE "Endodontics") AND ((DE "Regenerative Medicine") OR (DE "Regeneration (biology)"))	(137)
S7	AB REP OR AB RET	(84)
S8	AB pulp	(7,556)
S9	AB dental OR tooth OR teeth	(151,373)
S10	AB non vital OR AB necrotic	(1,320)
S11	AB immature OR AB open ap*	(1,515)

Search ID	Search Terms	Results
S12	DE "Dental pulp diseases"	(1,115)
S13	AB "non setting calcium hydroxide"	(18)
S14	AB "calcium hydroxide paste"	(186)
S15	AB calcium hydroxide	(1,877)
S16	AB CaOH2	(4)
S17	AB ca (oh) 2	(358)
S18	DE "Calcium Hydroxide"	(1,298)
S19	TX Multi-Cal	(6)
S20	TX Hypo-Cal	(17)
S21	TX Apexcal	(34)
S22	TX UltraCal	(117)
S23	TX Pulpdent	(621)
S24	TX Calxyl	(113)
S25	TX Odontocide	(0)
S26	TX Calcicur	(39)
S27	S1 OR S2 OR S3 OR S4 OR S5 OR S6 OR S7	(103,818)
S28	S9 AND (S8 OR S10 OR S11 OR S12)	(7,611)
S29	S13 OR S14 OR S15 OR S16 OR S17 OR S18 OR S19 OR S20 OR S21 OR S22 OR S23 OR S24 OR S25 OR S26	(2,808)
S30	S27 AND S28 AND S29	(602)
S31	S25 AND S26 AND S27	(472)

**Limiters** - Publication Date: 2004/01/01-2019/1/1

### SUPPLEMENTAL TABLE 1C

#### DATABASE 3 PROVIDED BY EMBASE (OVID) – UPDATED SEARCH AS OF APRIL 2020

Search ID	Search Terms	Results
S1	AB regeneration OR AB revitali#ation OR AB revasculari#ation OR AB regenerative	(229,858)
S2	AB endodontic*	(12,158)
S3	AB treatment OR AB therapy OR AB procedure OR AB protocol OR AB therapeutic*	(6,787,829)
S4	AB regenerative endodontic*	(362)
S5	AB "regenerative endodontic**"	(362)
S6	AB REP OR AB RET	(18,487)
S7	AB tooth OR AB teeth OR AB dental	(207811)
S8	AB pulp	(24,106)



## REGENERATIVE ENDODONTIC PROCEDURES, DISINFECTANTS AND OUTCOMES: A SYSTEMATIC REVIEW

Search ID	Search Terms	Results
S9	AB non vital OR AB necrotic	(44,641)
S10	AB immature OR AB open ap*	(75,269)
S11	AB "non setting calcium hydroxide"	(20)
S12	AB "calcium hydroxide paste"	(240)
S13	AB calcium hydroxide	(2,683)
S14	AB CaOH <sub>2</sub>	(14)
S15	TX Multi-Cal	(3)
S16	TX Hypo-Cal	(1)
S17	TX Apexcal	(5)
S18	TX UltraCal	(49)
S19	TX Pulpdent	(51)
S20	TX Calxyl	(13)
S21	TX Odontocide	(0)
S22	TX Calciur	(11)
S23	S1 OR S2 OR S3 OR S4 OR S5 OR S6	(6,927,003)
S24	S7 AND (S8 OR S9 OR S10)	(12,457)
S25	S11 OR S12 OR S13 OR S14 OR S15 OR S16 OR S17 OR S18 OR S19 OR S20 OR S21 OR S22	(2,764)
S26	S23 AND S24 AND S25	(559)
S27	S26	(496)

**Limiters** - Publication Date: 2004/01/01-2020/4/27

### SUPPLEMENTAL TABLE 2

#### STUDIES EXCLUDED FOLLOWING REVIEW OF THE FULL TEXT WITH REASON FOR EXCLUSION

Author	Date	Journal	Title	Reason for exclusion
Alobaid et al.	2014	<i>Journal of Endodontics</i>	Radiographic and clinical outcomes of the treatment of immature permanent teeth by revascularization or apexification: a pilot retrospective cohort study.	Lack of population and outcome data. *
Bose et al.	2009	<i>Journal of Endodontics</i>	A retrospective evaluation of radiographic outcomes in immature teeth with necrotic root canal systems treated with regenerative endodontic procedures.	Data used in study originated in another primary study, which has already been selected for review.
Brizuela et al.	2020	<i>Journal of Dental Research</i>	Cell-based regenerative endodontics for treatment of periapical lesions: a randomized, controlled phase I/II clinical trial.	Incorrect population.
Huang et al.	2013	<i>Nan Fang Yi Ke Da Xue Bao (Journal of Southern Medical University)</i>	Effect of revascularization treatment of immature permanent teeth with endodontic infection.	Antibiotic intracanal medicament used.

Author	Date	Journal	Title	Reason for exclusion
Jeeruphan et al. 2012		<i>Journal of Endodontics</i>	Mahidol study 1: comparison of radiographic and survival outcomes of immature teeth treated with either regenerative endodontic or apexification methods: a retrospective study.	Antibiotic intracanal medicament used.
Lee et al.	2015	<i>Journal of Formosan Medical Association</i>	Comparison of clinical outcomes for 40 necrotic immature permanent incisors treated with calcium hydroxide or mineral trioxide aggregate apexification/apexogenesis.	Intervention not eligible.
Nagata et al.	2014	<i>Journal of Endodontics</i>	Microbial evaluation of traumatized teeth treated with triple antibiotic paste or calcium hydroxide with 2% chlorhexidine gel in pulp revascularization.	Incomplete outcome records.
Sabharwal et al.	2019	<i>Journal of International Society of Preventive and Community Dentistry</i>	An In vivo study to compare antimicrobial activity of triantibiotic paste, 2% chlorhexidine gel, and calcium hydroxide on microorganisms in the root canal of immature teeth.	Intervention not eligible.
Shah et al.	2008	<i>Journal of Endodontics</i>	Efficacy of revascularization to induce apexification/apexogenesis in infected, nonvital, immature teeth: A pilot clinical study.	Calcium hydroxide not used as intracanal medicament.
Shivashankar et al.	2017	<i>Journal of Clinical and Diagnostic Research</i>	Comparison of the effect of PRP, PRF and induced bleeding in the revascularization of teeth with necrotic pulp and open apex: A triple blind randomized clinical trial.	Antibiotic intracanal medicament used.
Silujjai et al.	2017	<i>Journal of Endodontics</i>	Treatment outcomes of apexification or revascularization in nonvital immature permanent teeth: a retrospective study.	Lack of population and outcome data. *
Zhang et al.	2020	<i>Pakistan Journal of Pharmaceutical Sciences</i>	Efficacy of calcium hydroxide and chlorhexidine in pulp revascularization after trauma in young permanent teeth.	Lack of population and outcome data.

\* - studies in which authors were contacted for original data.

### SUPPLEMENTAL TABLE 3

#### DATA EXTRACTION

	Study 1	Study 2	Study 3	Study 4	Study 5
Authors	Cehreli et al.	Chen et al.	Chueh et al.	Nagata et al.	Song et al.
Year of publication	2011	2012	2009	2014	2017
Title of publication	Regenerative endodontic treatment (revascularization) of immature necrotic molars medicated with calcium hydroxide: a case series.	Responses of immature permanent teeth with infected necrotic pulp tissue and apical periodontitis/abscess to revascularization procedures.	Regenerative endodontic treatment for necrotic immature permanent teeth.	Traumatized immature teeth treated with 2 protocols of pulp revascularization.	Revascularization-associated Intracanal Calcification: Assessment of Prevalence and Contributing Factors

## REGENERATIVE ENDODONTIC PROCEDURES, DISINFECTANTS AND OUTCOMES: A SYSTEMATIC REVIEW

	Study 1	Study 2	Study 3	Study 4	Study 5
Journal of publication	Journal of Endodontics	International Endodontic Journal	Journal of Endodontics	Journal of Endodontics	Journal of Endodontics
Demographic	Turkey	Unclear – either Tainan, Taiwan or New York, USA. (Ethics from both).	Taiwan	Brazil	LA, USA; South Korea.
Place of study	Paediatric dept, Faculty of Dentistry, Hacettepe Univerisity, Ankara.	Unclear – as above.	Primary care, data collected by questionnaire sent to endodontists.	Piracicaba Dental School, UNICAMP and the Faculty of São Leopoldo Mandic.	UCLA School of Dentistry, Seoul Univeristy School of Dentistry and Yonsei Universtoy School of Dentistry.
Type of study	Retrospective observational case series	Retrospective observational case series	Retrospective observational case series	Randomized controlled trial	Retrospective observational case series
Ethical approval	<i>not reported</i>	Achieved – Institutional review board of Chi Mei Medical Center, Tainan, Taiwan and New York University School of medicine, New York, USA.	Achieved – hospital review board.	Achieved – research ethics committee of Piracicaba Dental School, UNICAMP and the Faculty of São Leopoldo Mandic.	<i>not reported</i>
Study aims	Present case series demonstrating outcomes of revascularization treatment with intracanal medicament calcium hydroxide in immature necrotic molars.	Report several types of response of immature permanent teeth with infected necrotic pulp tissue and either apical periodontitis or abscess to revascularization procedures.	To search for a standardized protocol to treat immature open-apex permanent teeth with pulp necrosis and apical pathosis.	Conduct a prospective clinical evaluation to compare triple antibiotic paste (TAP) and the combination of calcium hydroxide and 2% chlorhexidine gel as intracanal medications for pulp revascularization in traumatized teeth.	To determinether frequency and pattern of intracanal calcification in cases treated by revascularization and to identify the contributing factors.
Quality assessment	weak	weak	weak	unclear	weak
Inclusion criteria	<i>not reported</i>	<i>not reported</i>	Tooth with necrotic pulp showing symptoms/signs of infection, radiographically had open apex and PAP, REP performed, primary and secondary outcomes recorded, follow up >6 months.	Immature nonvital maxillary anterior teeth, pulp necrosis caused by hard tissue trauma and/ or some severe luxation, with or without PAP.	Patients undergoing/gone revascularization procedures between 2010-2014
Exclusion criteria	<i>not reported</i>	<i>not reported</i>	<i>not reported</i>	<i>not reported</i>	Lack of clinical exam and/or documentation in regard to induced bleeding during revascularization

	Study 1	Study 2	Study 3	Study 4	Study 5
Randomization method	-	-	-	Into two groups, 12 = TAP, 11 = nsCa(OH) <sub>2</sub> + 2% CHX gel, no discussion of exact method.	-
Number of participants	6	20	21	<i>not reported</i>	37
Number of teeth studied	6	20	23	23	29 (29 cases that had at least 1 year follow up, 8 cases did not)
Number of teeth to review (if more than one intervention group present in study)	6	20	23	11 – number of teeth in nsCa(OH) <sub>2</sub> + 2% CHX gel group	10 – number of teeth in nsCa(OH) <sub>2</sub> group
Loss of participants/teeth	0	0	0	<i>not reported</i>	8
Age of patients (mean/range)	9.3	10.2	10.6	7-17 range – unable to calculate mean due to lack of data	12.2
Ratio of patient sex (M:F)	1:5	9:11	11:10	<i>not reported</i>	6:4
Type of teeth, n					
anterior		10	1	11	3
premolar		10	21		6
molar	6		1		1
Cause of teeth non-vitality, n					(3 unknown cause)
trauma		10	22	11	3
caries	6	3	1		1
developmental		7			3
Disinfection irrigant type	2.5% NaOCl	5.25% NaOCl	2.5% NaOCl	6% NaOCl, 2% CHX	2.5% NaOCl
Duration of nsCa(OH) <sub>2</sub> used (days)	21	28	28	21 (including 2% CHX gel)	24.7

## REGENERATIVE ENDODONTIC PROCEDURES, DISINFECTANTS AND OUTCOMES: A SYSTEMATIC REVIEW

	Study 1	Study 2	Study 3	Study 4	Study 5
REP protocol	LA + adren', rubberdam, 10ml 2.5% NaOCl, nsCa(OH) <sub>2</sub> , Cavit seal, 3 week review. LA plain, rubberdam, 2.5% NaOCl, 10ml sterile saline, blood clot scaffold to 2-3mm of CEJ – some blood transferred from largest canal into other canals, MTA, GIC. 3-4 weeks later final restoration of amalgam (1/6) or composite (5/6) to replace GIC.	no LA, rubber dam (5% iodine), 3ml 5.25% NaOCl, LA given after working length calculation if patient had pain, nsCa(OH) <sub>2</sub> , IRM seal. 4 week review, 5.25% NaOCl, blood clot scaffold only 14/20 teeth, 6/20 no scaffolds), MTA, IRM. 2-3 days later final restoration of composite to replace IRM.	rubberdam, 'large' amount of 2.5% NaOCl, no instrumentation, nsCa(OH) <sub>2</sub> , Caviton/IRM seal. No induction of bleeding for a scaffold. 'Common protocol' findings lacking details of LA use or not. A range of permeant restorative seals including MTA +/- GP/amalgam and recall periods.	LA + adren', rubberdam, 20ml 6% NaOCl, inactivated with 5ml 5% sodium thiosulfate for 1 min, 10ml saline, 10ml 2% CHX, neutralized by 5% Tween 80 + 0.07% soy lecithin (reduce CHX carry over and cytotoxicity of CHX), apical 1/3 received no irrigation, nsCa(OH) <sub>2</sub> paste and 2% CHX gel placed as 1:1 3mm short of WL, sealed with coltosol and composite. LA + adren, saline, 3ml 17% EDTA solution 3 min, saline, induction of bleeding, Collocote scaffold, white MTA, sealed by coltosol and composite.	Access under rubberdam, (no mention of LA), irrigated with 2.5% NaOCl, intracanal medicament placed (TAP/DAP or nsCa(OH) <sub>2</sub> ), sealed with Caviton or IRM; review of clinical signs and symptoms – if still present intracanal medicament replenished, if not LA without vasoconstrictor, 2.5% NaOCl irrigation, dried canal, induced bleeding with endo file #10, MTA barrier over clot, temp restored; 3 <sup>rd</sup> apt for review, confirmed setting MTA and composite placed.
Follow up period (range of months)	9-10	6-26	6-108 Ranging follow up periods: group 1 - 7/23 teeth, 2 months average to treat and 15 months average follow up. group 2 – 16/23 teeth, 12 months average to treat and 32 months average follow up.	9-19 Recall periods specified as 1, 3, 6, 9, 12, 15 and 19 months but no specific details linking primary or secondary outcomes to timing of recall.	21.3 average (12-58)
Statistical evaluation	-	-	-	BioEstat 5.0 program at 5% significance level. McNemar test for clinical and radiographic parameters before and after REP (p = <0.05). Fisher exact test to evaluate difference between group TAP and nsCa(OH) <sub>2</sub> .	-



	Study 1	Study 2	Study 3	Study 4	Study 5
Radiographic analysis	Conversion of radiographs to 32-bit digital files, Turbo-reg program used to transform nonstandardized preoperative and postoperative radiographs into mathematically aligned pairs of images.	<i>not reported</i>	<i>not reported</i>	Subjectively – 2 endodontic specialists blinded to results, negatoscope at 4x magnification. PA films placed in silicone moulds for standardized positions.	Performed by 2 independent endodontists – however this was specific to assessing calcifications
Pre-operative results					
Pre-operative clinical signs (pain, swelling, sinus, TTP test, mobility, periodontal pocketing; number of teeth)	pain – 0/6 swelling – 0/6 sinus – 0/6 TTP – <i>not reported</i> mobility – normal physiological 6/6 perio' pocketing – normal physiological 6/6	pain – 0/20 swelling – 5/20 sinus – 11/20 TTP – <i>not reported</i> mobility – <i>not reported</i> perio' pocketing – <i>not reported</i>	pain – 9/23 swelling – 10/23 sinus – 9/23 TTP – <i>not reported</i> mobility – <i>not reported</i> perio' pocketing – <i>not reported</i> (9/23 combination of signs; 2/23 nil signs/symptoms)	pain – 10/11 swelling – 0/11 sinus – 2/11 TTP – 10/11 mobility – <i>not reported</i> perio' pocketing – <i>not reported</i>	Pain – <i>not reported</i> Swelling – 0/10 Sinus – 3/10 TTP – 7/10 Mobility – 1/10 Perio pocketing – <i>not reported</i>
Pre-operative radiographic findings (PAP present, number of teeth)	PAP present – 6/6	PAP present – 20/20	PAP present – 23/23	PAP present – 5/11	PAP present 8/10
Pre-operative vitality test response (cold or electric (EPT) test; number of teeth responded to test)	Cold – 0/6 EPT – 0/6	Cold – 0/20 EPT – 0/20	<i>not reported</i>	Cold – 0/11 EPT – 0/11	<i>Not reported although indicated had done narratively</i>
Post-operative results					
Primary outcomes					
Clinical signs (pain, swelling, sinus, TTP, tooth survival; number of teeth, p value where appropriate)	pain – 0/6 swelling – 0/6 sinus – 0/6 tooth survival – 6/6	pain – 0/20 swelling – 0/20 sinus – 0/20 tooth survival – 20/20	pain – 0/23 swelling – 0/23 sinus – 0/23 tooth survival – 23/23	pain – 0/11 (p = 0.625) swelling – 0/11 (p = 1) sinus – 0/11 (p = 0.5) TTP – 0/11 tooth survival – 11/11 (p = 1) (McNemar test P = < 0.05, leads to statistical significant reduction)	Pain – <i>not reported</i> Swelling – 0/10 Sinus – 0/10 Tooth survival 10/10

# REGENERATIVE ENDODONTIC PROCEDURES, DISINFECTANTS AND OUTCOMES: A SYSTEMATIC REVIEW

	Study 1	Study 2	Study 3	Study 4	Study 5
<b>Radiographical signs</b> (PAP increased, no changes, reduction, absent; timing and description of measurements, number of teeth)	3 weeks – reduction of PAP 6/6 9 months – complete absent PAP 6/6 Measurements – not reported	reduction of PAP 20/20 Measurements – not reported Timings – not reported	3 month (average $\pm 2$ ) – reduction of PAP 21/23 8 month (average $\pm 5$ ) – PAP absent 23/23 Measurements – not reported	4/5 teeth with pre-operatively PAP were absent of PAP post-operatively ( $p = 0.21$ ) 1/5 PAP still present but unclear status Measurements – subjective with standardized positioning Timings – not reported	10/10 PAP resolved completely Measurements – not reported Timings – at 2 <sup>nd</sup> review stage after intracanal med used
<b>Secondary outcomes</b>					
<b>Radiographical root development</b> (root width/length increased/no changes, root apex closure; number of teeth and average percentages)	average 7.71% root length increase (range 2.23-18.09) average 26.50% root width increase (variation 14.83-38.47) Both recorded at 9-10 months.	increased root length 15/20 (average 19.6 month review) increased root thickening 20/20 (average 19.6 month review) blunt root tip formation 5/20 (average 16.4 month review)	increased root width or length 22/23 (average 5.3 months) complete development 21/23 (average 16 month) blunt : conical root tip formation (of the 21 teeth completed development) – 7:14	increased root length 3/11 ( $p = 0.25$ ), increased root width 5/11 ( $p = 0.2188$ ) apical closure 6/11 ( $p = 0.0313$ ) Older patients showing slower development. (No p values).	Root development was present in terms of increased length and width No measurements reported
<b>Vitality – response to vitality testing</b> (including type of test, number of teeth)	9 months – response to cold test 2/6	not reported	not reported	no response 11/11	Not reported
<b>Patient reported outcomes</b>	not reported	not reported	not reported	not reported	Not reported
<b>Clinical adverse outcomes</b>	not reported	crown discolouration (2/20) radiographically canal obliteration 4/20 teeth (average 16 months)	radiographical canal obliteration – total obliteration 2/23 teeth, partial apical obliteration 21/23 teeth	crown discolouration 3/11 teeth (statistical significant between that and TAP group $p = 0.002$ ; $p = 0.25$ for nsCa(OH) <sub>2</sub> group)	RAIC – complete obliterations 7/10 - Partial obliterations 2/10 - None 1/10 Prevalence of whole study 62.1% Prevalence of nscaoh2 group 76.9% Prevalence of TAP/DAP group 46.2%
<b>Overall outcome of study (RCT)</b>	-	-	-	Comparable clinical and radiographic outcomes of two groups (TAP vs nsCa(OH) <sub>2</sub> ) but with aesthetic concerns significantly in TAP group due to crown discolouration.	-

Abbreviations - nsCa(OH)<sub>2</sub> = non-setting calcium hydroxide, TTP = tenderness to percussion test, PAP = periapical pathology, NaOCl = sodium hypochlorite, CHX = chlorhexidine gluconate, n/a = data not available, LA + adren' = local anaesthesia and adrenaline.