

PEARLS


Immune correlates of HIV-associated cryptococcal meningitis

Mark W. Tenforde^{1,2☯*}, James E. Scriven^{3☯}, Thomas S. Harrison^{4,5,6}, Joseph N. Jarvis^{7,8,9}

1 Division of Allergy and Infectious Diseases, University of Washington School of Medicine, Seattle, Washington, United States of America, **2** Department of Epidemiology, University of Washington School of Public Health, Seattle, Washington, United States of America, **3** Liverpool School of Tropical Medicine, Liverpool, United Kingdom, **4** Institute for Infection and Immunity, St George's, University of London, London, United Kingdom, **5** St George's University Hospitals NHS Foundation Trust, London, United Kingdom, **6** Institute of Infectious Diseases and Molecular Medicine, University of Cape Town, Cape Town, South Africa, **7** Botswana-UPenn Partnership, Gaborone, Botswana, **8** Perelman School of Medicine, University of Pennsylvania, Philadelphia, Pennsylvania, United States of America, **9** Department of Clinical Research, Faculty of Infectious Diseases and Tropical Medicine, London School of Hygiene and Tropical Medicine, London, United Kingdom

☯ These authors contributed equally to this work.

* mark.tenforde@gmail.com



Introduction

Cryptococcal meningitis (CM) is the leading cause of meningitis in much of sub-Saharan Africa, where it causes up to 20% of all deaths in human immunodeficiency virus (HIV)-infected cohorts [1, 2]. It is primarily caused by infection with *Cryptococcus neoformans*, an encapsulated yeast found widely in the environment. CM may also be caused by *C. gattii*, a related organism with a more limited geographic distribution but with the capacity to cause disease in nonimmunocompromised hosts [3]. Following inhalation of spores or desiccated yeast cells, an asymptomatic pulmonary infection occurs in the vast majority of immunocompetent hosts, with detectable antibody responses to *Cryptococcus* protein extract by early childhood [4, 5]. The host immune response leads to clearance of infection or to latent infection with yeast encased within pulmonary granulomata [6, 7]. If the host immune response is impaired, however, yeasts may survive and disseminate through the body hematogenously, resulting in a severe meningoencephalitis (Fig 1) [3].

The host immune response is central to the pathogenesis of cryptococcosis. Not only does an impaired immune response predispose to the condition but variations in the phenotype of the immune response also appear to influence the outcome. Additionally, efforts to reverse the severe immune deficiency through the initiation of antiretroviral therapy (ART) may be complicated by aberrant proinflammatory reactions such as the immune reconstitution inflammatory syndrome (IRIS).

What is the normal host immune response to *Cryptococcus*?

Alveolar macrophages constitute a primary first-line host defense and recognize *Cryptococcus* spores via Dectin-1 receptors [5]. Phagocytosis occurs through antibody- and complement-mediated, opsonin-dependent pathways and non-opsonin-dependent interaction of cryptococcus surface epitopes with receptors including mannose, dectin-1, CD14, and Toll-like receptor 4 [8, 9]. Once internalized, yeast-containing phagosomes fuse with lysosomes, and intracellular killing may occur under the influence of interferon- γ (IFN- γ) produced by natural killer cells and CD4 T cells [10]. However, in some circumstances and in the absence of appropriate macrophage activation, cryptococci can survive and replicate within the phagolysosome,

OPEN ACCESS

Citation: Tenforde MW, Scriven JE, Harrison TS, Jarvis JN (2017) Immune correlates of HIV-associated cryptococcal meningitis. PLoS Pathog 13(3): e1006207. <https://doi.org/10.1371/journal.ppat.1006207>

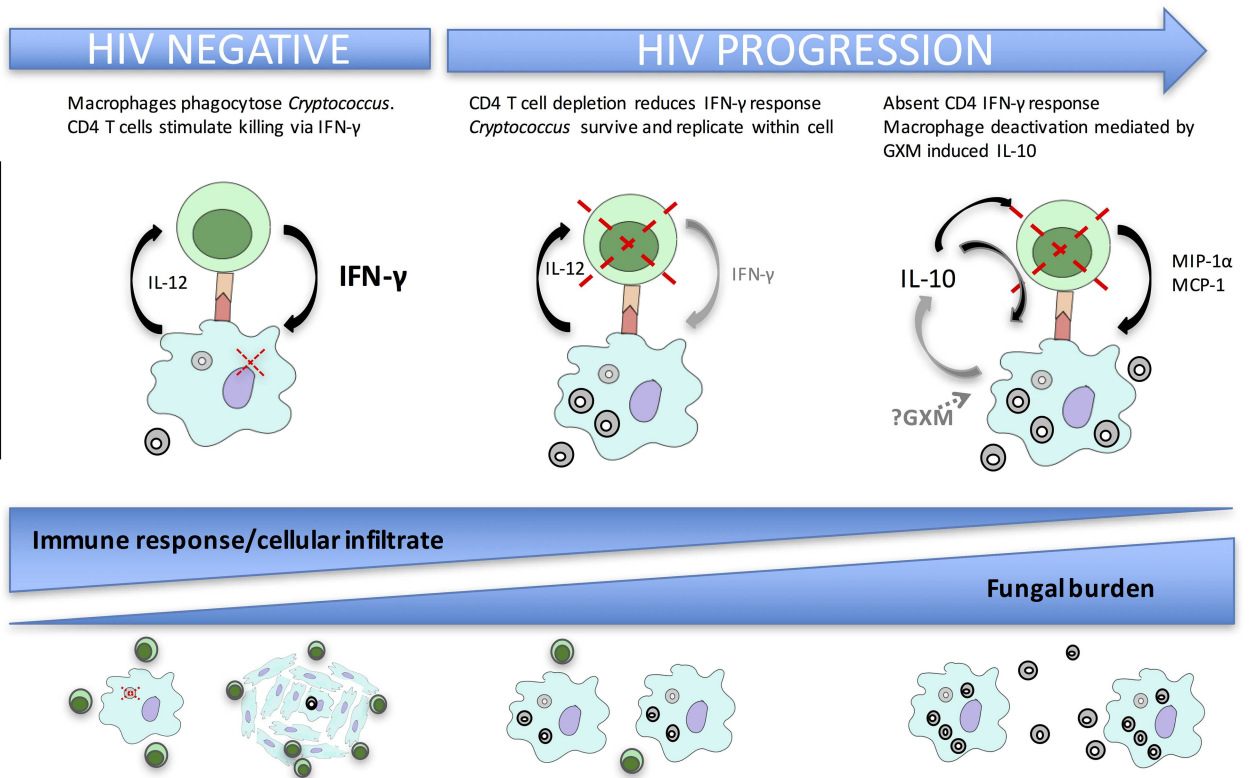
Editor: Donald C. Sheppard, McGill University, CANADA

Published: March 23, 2017

Copyright: © 2017 Tenforde et al. This is an open access article distributed under the terms of the [Creative Commons Attribution License](https://creativecommons.org/licenses/by/4.0/), which permits unrestricted use, distribution, and reproduction in any medium, provided the original author and source are credited.

Funding: This publication was made possible through core services and support from the Penn Center for AIDS Research (CFAR), an NIH-funded program (P30 AI 045008), to JNJ. The funders had no role in study design, data collection and analysis, decision to publish, or preparation of the manuscript.

Competing interests: The authors have declared that no competing interests exist.



Pathology	Complement-mediated phagocytosis by alveolar macrophages via interactions with TLR4, CD14, and dectin-1 Initial evasion of intracellular killing by cryptococci due to virulence factors including capsular protection, melanin synthesis, and non-lytic exocytosis Robust T cell infiltrate and granuloma formation Efficient intra-macrophage killing / containment	Poor T cell infiltrate and impaired T cell response with reduction in Th1 type cytokine production Impaired macrophage killing Impaired or absent granuloma formation Cryptococci survive and traffic to CNS (likely inside macrophages) Risk of dissemination dependent on pathogen factors (including capsular phenotype and laccase activity) and host factors in addition to CD4 depletion (still poorly understood, but likely to include polymorphisms in pattern recognition receptor genes, and genes involved in macrophage processing of intracellular pathogens and CD4 T cell function)	Very limited T cell infiltrate and granuloma formation CD4 T cell dysfunction characterized by decreased production of IFN γ and TNF α and increased chemokine production including MIP1 α Monocyte deactivation phenotype with decreased HLA-DR expression and impaired TNF α production Uncontrolled cryptococcal replication Excessive CNS chemokine production including MIP1 α and MCP-1 due to high fungal burden and inadequate CD4 T cell response
Clinical features	Asymptomatic infection and clearance Latent infection	Disseminated disease (lung, blood, CNS) Asymptomatic cryptococcal antigenemia (cryptococcal polysaccharide capsular components detectable in blood) Meningitis with moderate fungal burden, some CSF pleocytosis	Severe cryptococcal meningitis High fungal burden Poor CSF cellular infiltrate
Treatment response	No treatment required	Effective killing of Cryptococci with antifungal therapy Survival Lower risk of IRIS following ART initiation	Slower response to anti-fungal treatment High acute mortality High risk of IRIS following ART initiation Potential benefit from adjunctive IFN- γ or other immunomodulatory agents aimed at enhancing effective phagocyte mediated killing of Cryptococci

ART - antiretroviral therapy, CNS - central nervous system, GXM - glucuronoxylomannan, IRIS - immune reconstitution inflammatory syndrome, TLR4 - toll-like receptor 4

Fig 1. Summary of immune responses to *Cryptococcus* in immune competent hosts and in HIV-infected individuals.

<https://doi.org/10.1371/journal.ppat.1006207.g001>

protected through a variety of mechanisms, including expansion of its thick polysaccharide capsule and laccase-induced melanin synthesis that may neutralize free radicals. Cryptococci eventually exit the macrophage through cell lysis, actin-dependent direct cell-to-cell transfer, or non-lytic exocytosis [11–13]. Parasitism of macrophages facilitate replication and may also facilitate migration of yeast to the central nervous system (CNS) [8, 14].

What are major susceptibility factors for the development of cryptococcal meningitis in humans?

Cryptococcosis occurs almost exclusively in individuals with impaired cell-mediated immunity. The vast majority of cases worldwide are associated with advanced HIV infection, illustrating the vital importance of CD4 T cells in the human host response [15, 16]. Other risk factors include solid organ transplantation, long-term use of immunosuppressive drugs, diabetes mellitus, rheumatological diseases, advanced liver and renal disease, and hematological malignancies [17]. In addition, a number of rare genetic conditions have been linked to cryptococcosis in non-HIV-infected patients [18].

Despite presumed frequent environmental exposure, not all individuals with deficient cell-mediated immunity, as found in late-stage HIV infection, develop disseminated cryptococcosis. This suggests there may be additional factors that influence host susceptibility. Phagocytic Fcγ receptor 3A 158 F/V polymorphisms have recently been found to be a risk factor for cryptococcal disease, with FcγR3A VV homozygosity conferring higher risk, as have the presence of autoantibodies against granulocyte macrophage colony stimulating factor (GM-CSF) [18–20]. Additional genetic studies comparing DNA from patients with HIV-associated cryptococcal meningitis with that from population and CD4 cell count-matched individuals without evidence of cryptococcal infection are underway. Among exposed individuals, heterogeneity in *Cryptococcus* sequence type, genotype, and phenotype also influence the ability of yeast to disseminate and the clinical outcome [21, 22].

How does the immune phenotype in HIV-associated cryptococcal meningitis influence outcome?

Proinflammatory and Th1-type immune responses are beneficial among patients with HIV-associated CM, while a lack of immune response is detrimental. Studies from cohorts of patients with HIV-associated CM have shown that higher baseline concentrations of IFN-γ, TNF-α, and IL-6 in the CSF are associated with lower CSF fungal burden, faster fungal clearance on antifungal therapy, and improved survival [23–26]. However, this does not appear to simply be a correlate of a higher CD4 T cell count. Flow-cytometric analyses have suggested that the CD4 T cell phenotype, rather than just the number of circulating CD4 cells, is important in determining the outcome of CM. Following stimulation with cryptococcal mannoprotein, patients with IFN-γ- and/or TNF-α-producing CD4 T cells had corresponding higher CSF lymphocyte counts and CSF cytokine levels, along with lower CSF fungal burden and improved two-week survival odds [27].

Further study has shown that the impaired Th1 response observed in nonsurvivors is not an isolated immune defect but one component of a widespread systemic deactivation of the immune system characterized by monocyte deactivation (decreased human leukocyte antigen [HLA]-DR expression and decreased production of TNF-α following stimulation with lipopolysaccharide); raised IL-10, IL-6, and CXCL10; and increased circulating neutrophils [28]. This immune signature was an independent predictor of two-week mortality and correlated with plasma concentrations of the cryptococcal polysaccharide antigen glucuronoxylomannan (GXM), suggesting that the immune deactivation observed in nonsurvivors may be the result

of immunomodulatory actions of *Cryptococcus*. This hypothesis is supported by in vitro studies demonstrating that GXM impairs monocyte activation and antigen presentation and subsequent T cell responses via an IL-10-dependent mechanism [29].

Findings in humans are broadly consistent with animal studies demonstrating protective effects of Th1 immune responses, characterized by IFN- γ production and classically activated macrophages, and detrimental effects of Th2-type responses [30, 31]. However, human studies have not convincingly demonstrated the Th1/Th2 dichotomy found in murine studies. Th2 cytokines (IL-4, IL-13) are less readily detectable in the CSF and are often closely correlated with Th1 cytokines (IFN- γ). [26, 27] This may simply be due to biological differences between species. However, it may also reflect the time course of the immune response. Murine studies typically evaluate the acute immune response following pulmonary inoculation with *Cryptococcus*, whereas human studies represent patients with subacute infection who have a dynamic and evolving host response.

Does modulation of the immune response improve outcome in CM?

Two main strategies have been adopted to improve host immune response in HIV-associated CM. The first is the use of adjunctive immunotherapy alongside antifungal therapy. IFN- γ has been tested in two phase-2 trials and was found to be safe and associated with a faster rate of CSF fungal clearance. [32, 33] Subgroup analyses suggested that the greatest benefit was gained among patients with a lack of cryptococcus-specific IFN- γ /TNF- α T cell responses. [27]. Neither of these phase-2 trials were sufficiently powered to examine mortality differences; and larger phase-3 trials to determine the mortality benefits of adjunctive IFN- γ therapy, while justified, have not yet been conducted. The second strategy is augmentation of the immune response through earlier initiation of ART. Despite success in the setting of other opportunistic infections [34], this appears not to be beneficial in CM. Two randomized clinical trials have shown increased mortality with early ART. The first showed increased mortality when ART was initiated at 72 hours compared to 10 weeks following CM diagnosis in fluconazole-treated patients [35]. The second, conducted in Uganda and South Africa using amphotericin B-based antifungal therapy, showed increased mortality with ART initiation at 7–13 days compared to 5–6 weeks following CM diagnosis [23]. It was hypothesized that the increased mortality might have been due the development of undiagnosed IRIS.

Immune modulation with adjunctive dexamethasone has also been tested for treatment of CM in a phase-3 trial [36]. This study was terminated early after dexamethasone use was associated with slower fungal clearance from the CSF, higher rates of disability, and a trend toward higher mortality. The immunological mechanisms underlying these findings are not yet known.

What is cryptococcal immune reconstitution inflammatory syndrome?

IRIS is defined as “a paradoxical deterioration in clinical status attributable to the recovery of the immune system” and in HIV typically manifests as inflammatory reactions at the site of previously treated or previously unrecognized opportunistic infections following the initiation of ART [37]. Cryptococcal IRIS (C-IRIS) is reported to occur in 10%–20% of individuals with HIV-associated CM at a median of 4–9 weeks following ART initiation and has been identified as an independent predictor of mortality [25, 38–40]. The usual presentation is with a recurrence of signs and symptoms of meningitis [41]. Immunological studies have reported a CSF immune response characterized by a CD4 T cell infiltrate, a proinflammatory monocyte

phenotype, and increased concentrations of proinflammatory cytokines (TNF- α , IFN- γ , granulocyte colony stimulating factor) [42, 43].

The risk of developing C-IRIS appears to be closely related to the host immune response during the initial episode of CM. Individuals with a lack of inflammation in their CSF during the initial episode of CM, characterized by low CSF white cells (<5/ μ L), low CSF concentrations of proinflammatory cytokines (IFN- γ , TNF- α , IL-6, IL-8), and increased concentrations of CSF chemokines (CCL2/MCP-1, CCL3/MIP-1 α) are at high risk of developing IRIS following ART initiation [43, 44]. Pre-ART cryptococcus-induced IFN- γ production from whole blood is also reduced in those who go on to develop C-IRIS [45]. This paucity of immune response is associated with a higher CSF fungal burden at baseline, slower fungal clearance on antifungal therapy, and increased CSF fungal burdens at the end of antifungal therapy [43, 46]. This increased residual cryptococcal antigen load probably drives C-IRIS during CD4 recovery on ART, with the elevated chemokine levels leading to excessive trafficking of immune cells into the CSF [43, 44, 46–49].

Although no increase in cases of IRIS was observed in the early ART trials, it is probable that the excess mortality was immunologically mediated. The increased mortality associated with early ART was primarily driven by individuals with a CSF white cell count (WCC) <5/ μ L at randomization—the same group found to be at the highest risk of developing IRIS [23]. Further analysis has shown that early ART was associated with an influx of inflammatory cells into the CSF, with significantly more patients in the early ART arm developing CSF pleocytosis (WCC \geq 5/ μ L) by day 14 (after a median of six days of ART), accompanied by increased CSF concentrations of soluble CD14 and CD163, suggesting increased macrophage activation in the CSF [49].

Conclusion

Cryptococcal meningitis has emerged as a leading cause of death in individuals with impaired CD4 T cell-mediated immunity. Recent human data suggests that an absence of an effective Th1 response, characterized by IFN- γ and TNF- α production, leads to monocyte deactivation, excessive CNS chemokine production, and poor clearance of infection with increased risk of IRIS and death. Immunomodulation with steroid therapy increases the risk of a poor outcome, whereas augmentation with IFN- γ has demonstrated benefits in faster fungal clearance when coupled with effective antifungal therapy.

References

1. Jarvis JN, Meintjes G, Williams A, Brown Y, Crede T, Harrison TS. Adult meningitis in a setting of high HIV and TB prevalence: findings from 4961 suspected cases. *BMC Infect Dis*. 2010; 10:67. PMID: 3161361. <https://doi.org/10.1186/1471-2334-10-67> PMID: 20230635
2. Lawn SD, Harries AD, Anglaret X, Myer L, Wood R. Early mortality among adults accessing antiretroviral treatment programmes in sub-Saharan Africa. *Aids*. 2008; 22(15):1897–908. PMID: PMC3816249. <https://doi.org/10.1097/QAD.0b013e32830007cd> PMID: 18784453
3. Jarvis JN, Harrison TS. HIV-associated cryptococcal meningitis. *AIDS* (London, England). 2007; 21(16):2119–29.
4. Goldman DL, Khine H, Abadi J, Lindenberg DJ, Pirofski La, Niang R, Casadevall A. Serologic evidence for *Cryptococcus neoformans* infection in early childhood. *Pediatrics*. 2001; 107(5):E66. PMID: 11331716
5. Giles SS, Dagenais TR, Botts MR, Keller NP, Hull CM. Elucidating the pathogenesis of spores from the human fungal pathogen *Cryptococcus neoformans*. *Infection and immunity*. 2009; 77(8):3491–500. Epub 2009/05/20. PMID: 2715683. <https://doi.org/10.1128/IAI.00334-09> PMID: 19451235
6. Goldman DL, Lee SC, Mednick AJ, Montella L, Casadevall A. Persistent *Cryptococcus neoformans* pulmonary infection in the rat is associated with intracellular parasitism, decreased inducible nitric oxide

- synthase expression, and altered antibody responsiveness to cryptococcal polysaccharide. *Infection and immunity*. 2000; 68(2):832–8. PMID: [10639453](#)
7. Baker RD. The primary pulmonary lymph node complex of cryptococcosis. *American journal of clinical pathology*. 1976; 65(1):83–92. PMID: [1246992](#)
 8. García-Rodas R, Zaragoza O. Catch me if you can: phagocytosis and killing avoidance by *Cryptococcus neoformans*. *FEMS Immunol Med Microbiol*. 2012; 64(2):147–61. <https://doi.org/10.1111/j.1574-695X.2011.00871.x> PMID: [22029633](#)
 9. Levitz SM. Innate recognition of fungal cell walls. *PLoS Pathog*. 2010; 6(4):e1000758. PMCID: [PMC2858700](#). <https://doi.org/10.1371/journal.ppat.1000758> PMID: [20421940](#)
 10. Kawakami K, Kohno S, Kadota J, Tohyama M, Teruya K, Kudeken N, Saito A, Hara K. T cell-dependent activation of macrophages and enhancement of their phagocytic activity in the lungs of mice inoculated with heat-killed *Cryptococcus neoformans*: involvement of IFN-gamma and its protective effect against cryptococcal infection. *Microbiol Immunol*. 1995; 39(2):135–43. PMID: [7783686](#)
 11. Johnston SA, May RC. *Cryptococcus* interactions with macrophages: evasion and manipulation of the phagosome by a fungal pathogen. *Cell Microbiol*. 2013; 15(3):403–11. <https://doi.org/10.1111/cmi.12067> PMID: [23127124](#)
 12. Brown SM, Campbell LT, Lodge JK. *Cryptococcus neoformans*, a fungus under stress. *Curr Opin Microbiol*. 2007; 10(4):320–5. PMCID: [PMC2570326](#). <https://doi.org/10.1016/j.mib.2007.05.014> PMID: [17707685](#)
 13. Levitz SM, Nong SH, Seetoo KF, Harrison TS, Speizer RA, Simons ER. *Cryptococcus neoformans* resides in an acidic phagolysosome of human macrophages. *Infection and immunity*. 1999; 67(2):885–90. PMCID: [PMC96400](#). PMID: [9916104](#)
 14. Sabiiti W, Robertson E, Beale MA, Johnston SA, Brouwer AE, Loyse A, Jarvis JN, Gilbert AS, Fisher MC, Harrison TS, May RC, Bicanic T. Efficient phagocytosis and laccase activity affect the outcome of HIV-associated cryptococcosis. *J Clin Invest*. 2014; 124(5):2000–8. PMCID: [4001551](#). <https://doi.org/10.1172/JCI72950> PMID: [24743149](#)
 15. Park BJ, Wannemuehler KA, Marston BJ, Govender N, Pappas PG, Chiller TM. Estimation of the current global burden of cryptococcal meningitis among persons living with HIV/AIDS. *AIDS (London, England)*. 2009; 23(4):525–30.
 16. Neofytos D, Fishman JA, Horn D, Anaissie E, Chang CH, Olyaei A, Pfaller M, Steinbach WJ, Webster KM, Marr KA. Epidemiology and outcome of invasive fungal infections in solid organ transplant recipients. *Transplant infectious disease: an official journal of the Transplantation Society*. 2010; 12(3):220–9.
 17. Pappas PG, Perfect JR, Cloud GA, Larsen RA, Pankey GA, Lancaster DJ, Henderson H, Kauffman CA, Haas DW, Saccante M, Hamill RJ, Holloway MS, Warren RM, Dismukes WE. Cryptococcosis in human immunodeficiency virus-negative patients in the era of effective azole therapy. *Clin Infect Dis*. 2001; 33(5):690–9. <https://doi.org/10.1086/322597> PMID: [11477526](#)
 18. Rosen LB, Freeman AF, Yang LM, Jutivorakool K, Olivier KN, Angkasekwinai N, Suputtamongkol Y, Bennett JE, Pyrgos V, Williamson PR, Ding L, Holland SM, Browne SK. Anti-GM-CSF autoantibodies in patients with cryptococcal meningitis. *J Immunol*. 2013; 190(8):3959–66. PMCID: [PMC3675663](#). <https://doi.org/10.4049/jimmunol.1202526> PMID: [23509356](#)
 19. Rohatgi S, Gohil S, Kuniholm MH, Schultz H, Dufaud C, Armour KL, Badri S, Mailliard RB, Pirofski LA. Fc gamma receptor 3A polymorphism and risk for HIV-associated cryptococcal disease. *MBio*. 2013; 4(5):e00573–13. PMCID: [PMC3760251](#). <https://doi.org/10.1128/mBio.00573-13> PMID: [23982074](#)
 20. Saijo T, Chen J, Chen SC, Rosen LB, Yi J, Sorrell TC, Bennett JE, Holland SM, Browne SK, Kwon-Chung KJ. Anti-granulocyte-macrophage colony-stimulating factor autoantibodies are a risk factor for central nervous system infection by *Cryptococcus gattii* in otherwise immunocompetent patients. *MBio*. 2014; 5(2):e00912–14. PMCID: [PMC3967522](#). <https://doi.org/10.1128/mBio.00912-14> PMID: [24643864](#)
 21. Alanio A, Desnos-Ollivier M, Dromer F. Dynamics of *Cryptococcus neoformans*-macrophage interactions reveal that fungal background influences outcome during cryptococcal meningoencephalitis in humans. *MBio*. 2011; 2(4). PMCID: [PMC3149853](#).
 22. Beale MA, Sabiiti W, Robertson EJ, Fuentes-Cabrejo KM, O'Hanlon SJ, Jarvis JN, Loyse A, Meintjes G, Harrison TS, May RC, Fisher MC, Bicanic T. Genotypic Diversity Is Associated with Clinical Outcome and Phenotype in Cryptococcal Meningitis across Southern Africa. *PLoS Negl Trop Dis*. 2015; 9(6):e0003847. PMCID: [PMC4482434](#). <https://doi.org/10.1371/journal.pntd.0003847> PMID: [26110902](#)
 23. Boulware DR, Meya DB, Muzoora C, Rolfes MA, Huppler Hullsiek K, Musubire A, Taseera K, Nabeta HW, Schutz C, Williams DA, Rajasingham R, Rhein J, Thienemann F, Lo MW, Nielsen K, Bergemann TL, Kambugu A, Manabe YC, Janoff EN, Bohjanen PR, Meintjes G, Team CT. Timing of antiretroviral therapy after diagnosis of cryptococcal meningitis. *The New England journal of medicine*. 2014; 370

(26):2487–98. 24963568; PMID: 4127879. <https://doi.org/10.1056/NEJMoa1312884> PMID: 24963568

24. Kambugu A, Meya DB, Rhein J, O'Brien M, Janoff EN, Ronald AR, Kanya MR, Mayanja-Kizza H, Sande MA, Bohjanen PR, Boulware DR. Outcomes of cryptococcal meningitis in Uganda before and after the availability of highly active antiretroviral therapy. *Clinical infectious diseases: an official publication of the Infectious Diseases Society of America*. 2008; 46(11):1694–701. PMID: PMC2593910.
25. Jarvis JN, Bicanic T, Loyse A, Namarika D, Jackson A, Nussbaum JC, Longley N, Muzoora C, Phulusa J, Taseera K, Kanyembe C, Wilson D, Hosseinipour MC, Brouwer AE, Limmathurotsakul D, White N, van der Horst C, Wood R, Meintjes G, Bradley J, Jaffar S, Harrison T. Determinants of mortality in a combined cohort of 501 patients with HIV-associated Cryptococcal meningitis: implications for improving outcomes. *Clin Infect Dis*. 2014; 58(5):736–45. PMID: 3922213. <https://doi.org/10.1093/cid/cit794> PMID: 24319084
26. Siddiqui AA, Brouwer AE, Wuthiekanun V, Jaffar S, Shattock R, Irving D, Sheldon J, Chierakul W, Peacock S, Day N, White NJ, Harrison TS. IFN-gamma at the site of infection determines rate of clearance of infection in cryptococcal meningitis. *J Immunol*. 2005; 174(3):1746–50. PMID: 15661940
27. Jarvis JN, Casazza JP, Stone HH, Meintjes G, Lawn SD, Levitz SM, Harrison TS, Koup RA. The phenotype of the Cryptococcus-specific CD4+ memory T-cell response is associated with disease severity and outcome in HIV-associated cryptococcal meningitis. *J Infect Dis*. 2013; 207(12):1817–28. PMID: PMC3654748. <https://doi.org/10.1093/infdis/jit099> PMID: 23493728
28. Scriven JE, Graham LM, Schutz C, Scriba TJ, Wilkinson KA, Wilkinson RJ, Boulware DR, Urban BC, Lalloo DG, Meintjes G. A Glucuronoxylomannan-Associated Immune Signature, Characterized by Monocyte Deactivation and an Increased Interleukin 10 Level, Is a Predictor of Death in Cryptococcal Meningitis. *J Infect Dis*. 2016; 213(11):1725–34. PMID: PMC4857465. <https://doi.org/10.1093/infdis/jiw007> PMID: 26768248
29. Retini C, Vecchiarelli A, Monari C, Bistoni F, Koziel TR. Encapsulation of Cryptococcus neoformans with glucuronoxylomannan inhibits the antigen-presenting capacity of monocytes. *Infect Immun*. 1998; 66(2):664–9. PMID: PMC107954. PMID: 9453624
30. Müller U, Piehler D, Stenzel W, Köhler G, Frey O, Held J, Grahner T, Richter T, Eschke M, Kamradt T, Brombacher F, Alber G. Lack of IL-4 receptor expression on T helper cells reduces T helper 2 cell polyfunctionality and confers resistance in allergic bronchopulmonary mycosis. *Mucosal Immunol*. 2012; 5(3):299–310. <https://doi.org/10.1038/mi.2012.9> PMID: 22333910
31. Stenzel W, Müller U, Köhler G, Heppner FL, Blessing M, McKenzie AN, Brombacher F, Alber G. IL-4/IL-13-dependent alternative activation of macrophages but not microglial cells is associated with uncontrolled cerebral cryptococcosis. *The American journal of pathology*. 2009; 174(2):486–96. PMID: PMC2630557. <https://doi.org/10.2353/ajpath.2009.080598> PMID: 19147811
32. Jarvis JN, Meintjes G, Rebe K, Williams GN, Bicanic T, Williams A, Schutz C, Bekker LG, Wood R, Harrison TS. Adjunctive interferon-γ immunotherapy for the treatment of HIV-associated cryptococcal meningitis: a randomized controlled trial. *Aids*. 2012; 26(9):1105–13. PMID: PMC3640254. <https://doi.org/10.1097/QAD.0b013e3283536a93> PMID: 22421244
33. Pappas PG, Bustamante B, Ticona E, Hamill RJ, Johnson PC, Reboli A, Aberg J, Hasbun R, Hsu HH. Recombinant interferon-γ as adjunctive therapy for AIDS-related acute cryptococcal meningitis. *The Journal of infectious diseases*. 2004; 189(12):2185–91. <https://doi.org/10.1086/420829> PMID: 15181565
34. Abdool Karim SS, Naidoo K, Grobler A, Padayatchi N, Baxter C, Gray A, Gengiah T, Nair G, Bamber S, Singh A, Khan M, Pienaar J, El-Sadr W, Friedland G, Abdool Karim Q. Timing of initiation of antiretroviral drugs during tuberculosis therapy. *The New England journal of medicine*. 2010; 362(8):697–706. PMID: PMC3076221. <https://doi.org/10.1056/NEJMoa0905848> PMID: 20181971
35. Makadzange AT, Ndhlovu CE, Takarinda K, Reid M, Kurangwa M, Gona P, Hakim JG. Early versus delayed initiation of antiretroviral therapy for concurrent HIV infection and cryptococcal meningitis in sub-saharan Africa. *Clin Infect Dis*. 2010; 50(11):1532–8. Epub 2010/04/27. <https://doi.org/10.1086/652652> PMID: 20415574
36. Beardsley J, Wolbers M, Kibengo FM, Ggayi AB, Kamali A, Cuc NT, Binh TQ, Chau NV, Farrar J, Merson L, Phuong L, Thwaites G, Van Kinh N, Thuy PT, Chierakul W, Siriboon S, Thiansukhon E, Onsanit S, Supphamongkolchaikul W, Chan AK, Heyderman R, Mwinjiwa E, van Oosterhout JJ, Imran D, Basri H, Mayxay M, Dance D, Phimmasone P, Rattanavong S, Lalloo DG, Day JN, Investigators C. Adjunctive Dexamethasone in HIV-Associated Cryptococcal Meningitis. *The New England journal of medicine*. 2016; 374(6):542–54. PMID: PMC4778268. <https://doi.org/10.1056/NEJMoa1509024> PMID: 26863355
37. Shelburne SA, Hamill RJ, Rodriguez-Barradas MC, Greenberg SB, Atmar RL, Musher DW, Gathe JC, Visnegarwala F, Trautner BW. Immune reconstitution inflammatory syndrome: emergence of a unique syndrome during highly active antiretroviral therapy. *Medicine (Baltimore)*. 2002; 81(3):213–27.

38. Bicanic T, Meintjes G, Rebe K, Williams A, Loyse A, Wood R, Hayes M, Jaffar S, Harrison T. Immune reconstitution inflammatory syndrome in HIV-associated cryptococcal meningitis: a prospective study. *Journal of acquired immune deficiency syndromes (1999)*. 2009; 51(2):130–4.
39. Shelburne SA, Darcourt J, White AC, Greenberg SB, Hamill RJ, Atmar RL, Visnegarwala F. The role of immune reconstitution inflammatory syndrome in AIDS-related *Cryptococcus neoformans* disease in the era of highly active antiretroviral therapy. *Clinical infectious diseases: an official publication of the Infectious Diseases Society of America*. 2005; 40(7):1049–52.
40. Sungkanuparph S, Filler SG, Chetchotisakd P, Pappas PG, Nolen TL, Manosuthi W, Anekthananon T, Morris MI, Supparatpinyo K, Kopetskie H, Kendrick AS, Johnson PC, Sobel JD, Larsen RA. Cryptococcal immune reconstitution inflammatory syndrome after antiretroviral therapy in AIDS patients with cryptococcal meningitis: a prospective multicenter study. *Clin Infect Dis*. 2009; 49(6):931–4. Epub 2009/08/18. <https://doi.org/10.1086/605497> PMID: 19681708
41. Haddow LJ, Colebunders R, Meintjes G, Lawn SD, Elliott JH, Manabe YC, Bohjanen PR, Sungkanuparph S, Easterbrook PJ, French MA, Boulware DR, (INSHI) INftSoH-al. Cryptococcal immune reconstitution inflammatory syndrome in HIV-1-infected individuals: proposed clinical case definitions. *Lancet Infect Dis*. 2010; 10(11):791–802. PMID: PMC3026057. [https://doi.org/10.1016/S1473-3099\(10\)70170-5](https://doi.org/10.1016/S1473-3099(10)70170-5) PMID: 21029993
42. Meya DB, Okurut S, Zziwa G, Rolfes MA, Kelsey M, Cose S, Joloba M, Naluyima P, Palmer BE, Kambugu A, Mayanja-Kizza H, Bohjanen PR, Eller MA, Wahi SM, Boulware DR, Manabe YC, Janoff EN. Cellular immune activation in cerebrospinal fluid from ugandans with cryptococcal meningitis and immune reconstitution inflammatory syndrome. *J Infect Dis*. 2015; 211(10):1597–606. <https://doi.org/10.1093/infdis/jiu664> PMID: 25492918
43. Boulware DR, Bonham SC, Meya DB, Wiesner DL, Park GS, Kambugu A, Janoff EN, Bohjanen PR. Paucity of initial cerebrospinal fluid inflammation in cryptococcal meningitis is associated with subsequent immune reconstitution inflammatory syndrome. *The Journal of infectious diseases*. 2010; 202(6):962–70. Epub 2010/08/04. PMID: 2924457. <https://doi.org/10.1086/655785> PMID: 20677939
44. Jarvis JN, Meintjes G, Bicanic T, Buffa V, Hogan L, Mo S, Tomlinson G, Kropf P, Noursadeghi M, Harrison TS. Cerebrospinal fluid cytokine profiles predict risk of early mortality and immune reconstitution inflammatory syndrome in HIV-associated cryptococcal meningitis. *PLoS Pathog*. 2015; 11(4): e1004754. PMID: 4390200. <https://doi.org/10.1371/journal.ppat.1004754> PMID: 25853653
45. Chang CC, Lim A, Omarjee S, Levitz SM, Gosnell BI, Spelman T, Elliott JH, Carr WH, Moosa MY, Ndung'u T, Lewin SR, French MA. Cryptococcosis-IRIS is associated with lower cryptococcus-specific IFN- γ responses before antiretroviral therapy but not higher T-cell responses during therapy. *The Journal of infectious diseases*. 2013; 208(6):898–906. PMID: PMC3749010. <https://doi.org/10.1093/infdis/jit271> PMID: 23766525
46. Chang CC, Dorasamy AA, Gosnell BI, Elliott JH, Spelman T, Omarjee S, Naranbhai V, Coovadia Y, Ndung'u T, Moosa MY, Lewin SR, French MA. Clinical and mycological predictors of cryptococcosis-associated immune reconstitution inflammatory syndrome. *Aids*. 2013; 27(13):2089–99. <https://doi.org/10.1097/QAD.0b013e3283614a8d> PMID: 23525034
47. Boulware DR, Meya DB, Bergemann TL, Wiesner DL, Rhein J, Musubire A, Lee SJ, Kambugu A, Janoff EN, Bohjanen PR. Clinical features and serum biomarkers in HIV immune reconstitution inflammatory syndrome after cryptococcal meningitis: a prospective cohort study. *PLoS Med*. 2010; 7(12):e1000384. Epub 2011/01/22. PMID: 3014618. <https://doi.org/10.1371/journal.pmed.1000384> PMID: 21253011
48. Chang CC, Omarjee S, Lim A, Spelman T, Gosnell BI, Carr WH, Elliott JH, Moosa MY, Ndung'u T, French MA, Lewin SR. Chemokine Levels and Chemokine Receptor Expression in the Blood and the Cerebrospinal Fluid of HIV-Infected Patients With Cryptococcal Meningitis and Cryptococcosis-Associated Immune Reconstitution Inflammatory Syndrome. *The Journal of infectious diseases*. 2013; 208(10):1604–12. PMID: PMC3805241. <https://doi.org/10.1093/infdis/jit388> PMID: 23908492
49. Scriven JE, Rhein J, Hullsiek KH, von Hohenberg M, Linder G, Rolfes MA, Williams DA, Taseera K, Meya DB, Meintjes G, Boulware DR, Team C. Early ART After Cryptococcal Meningitis Is Associated With Cerebrospinal Fluid Pleocytosis and Macrophage Activation in a Multisite Randomized Trial. *J Infect Dis*. 2015.